

ANGIOGRAPHIC FOLLOW-UP AFTER PLACEMENT OF A SELF-EXPANDING CORONARY-ARTERY STENT

PATRICK W. SERRUYS, M.D., BRADLEY H. STRAUSS, M.D., KEVIN J. BEATT, M.B., B.S.,
MICHEL E. BERTRAND, M.D., JACQUES PUEL, M.D., ANTHONY F. RICKARDS, M.B., B.S.,
BERNHARD MEIER, M.D., JEAN-JACQUES GOY, M.D., PIERRE VOGT, M.D., LUKAS KAPPENBERGER, M.D.,
AND ULRICH SIGWART, M.D.

Abstract Background. The placement of stents in coronary arteries after coronary angioplasty has been investigated as a way of treating abrupt coronary-artery occlusion related to the angioplasty and of reducing the late intimal hyperplasia responsible for gradual restenosis of the dilated lesion.

Methods. From March 1986 to January 1988, we implanted 117 self-expanding, stainless-steel endovascular stents (Wallstent) in the native coronary arteries (94 stents) or saphenous-vein bypass grafts (23 stents) of 105 patients. Angiograms were obtained immediately before and after placement of the stent and at follow-up at least one month later (unless symptoms required angiography sooner). The mortality after one year was 7.6 percent (8 patients). Follow-up angiograms (after a mean [\pm SD] of 5.7 ± 4.4 months) were obtained in 95 patients with 105 stents and were analyzed quantitatively by a computer-assisted system of cardiovascular angiographic analysis. The 10 patients without follow-up angiograms included 4 who died.

Results. Complete occlusion occurred in 27 stents in

TWO major limitations of coronary angioplasty are acute occlusion and late restenosis. The concept of implanting an endoluminal stent in the coronary arteries after balloon dilation to circumvent these problems was first suggested in 1964.¹ This procedure was successfully performed in patients in 1986.² In May 1988, the five European centers testing this device agreed to set up a core laboratory for quantitative angiographic analysis to assess the results objectively. The early follow-up results reported by the core laboratory showed that immediately after stent implantation, there was an additional increase in the minimal luminal diameter of the vessel and a decrease in the percentage of stenosis of the diameter.³ However, after three months slight but diffuse narrowing was observed in the artery containing the stent.⁴ In the present study, we have focused on the results

From the Catheterization Laboratory, Erasmus University, Rotterdam, the Netherlands (P.W.S., B.H.S., K.J.B.); the Division of Cardiology, Department of Medicine, Centre Hospitalier Universitaire Vaudois, Lausanne, Switzerland (J.-J.G., P.V., L.K.); the Department of Clinical and Experimental Cardiology, Centre Hospitalier Regional Universitaire, Rangueil, Toulouse, France (J.P.); the Department of Clinical Measurement, National Heart Institute, London (A.F.R., U.S.); the Cardiology Center, University Hospital, Geneva (B.M.); and the Department of Cardiology, Hôpital Cardiologique, Lille, France (M.E.B.). Address reprint requests to Dr. Serruys at the Catheterization Laboratory, Erasmus University, P.O. Box 1738, 3000 DR Rotterdam, the Netherlands.

Supported in part by grants from the Dutch Ministry of Science and Education, The Hague (87159), and from the Swiss National Fund (3,835,083). Dr. Strauss is the recipient of a Research Fellowship from the Canadian Heart Foundation. Dr. Beatt is the recipient of a Research Fellowship from the British and Netherlands Heart Foundation.

25 patients (24 percent); 21 occlusions were documented within the first 14 days after implantation. Overall, immediately after placement of the stent there was a significant increase in the minimal luminal diameter and a significant decrease in the percentage of the diameter with stenosis (changing from a mean [\pm SD] of 1.88 ± 0.43 to 2.48 ± 0.51 mm and from 37 ± 12 to 21 ± 10 percent, respectively; $P < 0.0001$). Later, however, there was a significant decrease in the minimal luminal diameter and a significant increase in the stenosis of the segment with the stent (1.68 ± 1.78 mm and 48 ± 34 percent at follow-up). Significant restenosis, as indicated by a reduction of 0.72 mm in the minimal luminal diameter or by an increase in the percentage of stenosis to ≥ 50 percent, occurred in 32 percent and 14 percent of patent stents, respectively.

Conclusions. Early occlusion remains an important limitation of this coronary-artery stent. Even when the early effects are beneficial, there are frequently late occlusions or restenosis. The place of this form of treatment for coronary artery disease remains to be determined. (N Engl J Med 1991; 324:13-7.)

of long-term angiographic follow-up of the initial 117 stent implantations.

METHODS

Study Patients

One hundred five patients gave informed consent and were enrolled at participating study centers between March 1986 and January 1988. The study protocol was approved by the ethics committees of the individual hospitals. The clinical characteristics of the patients are shown in Table 1. Ninety-five patients received one stent, and 10 received more than one (Table 1). Seven of the 10 patients who received multiple stents required two overlapping ("telescoping") stents to cover long lesions adequately, and the other 3 required stents in multiple vessels or in different locations in the same vessel. The sites of stent placement are shown in Table 1. Seventy-one stents were implanted after redilation of a restenosis, 14 were placed as an emergency procedure during an angioplasty complicated by acute occlusion, 5 were placed after angioplasty for chronic occlusion, and 27 were placed as an adjunct procedure to primary percutaneous transluminal coronary angioplasty (PTCA). Some of the patients who received stents for bypass grafting or abrupt closure have been included in previous reports.^{5,6}

In this trial, the endovascular prosthesis Wallstent (Medinvent, Lausanne, Switzerland) was used. The method of implantation and a description of this stent have been previously reported.² This stent is a self-expanding, stainless-steel, woven-mesh prosthesis that can be positioned in the coronary artery with an 8-French or 9-French guiding catheter, according to the standard over-the-wire technique. The device is constructed of 16 wire filaments, each 0.08 mm wide. It is constrained in an elongated configuration on a delivery catheter 1.57 mm in diameter; the distal end of the prosthesis is covered by a removable plastic sleeve. As the sleeve is withdrawn, the constrained device returns to its original, larger diameter and becomes anchored against the vessel wall. The diameter of the prosthesis ranges from 2.5 to 6 mm when the stent is unconstrained.

Table 1. Clinical Characteristics of the Study Patients.

No. of patients	105
Age (yr)*	57±9
Sex (M/F)	91/14
No. of stents	117
Site of stent implantation (no. of stents)	
Left anterior descending artery	62
Circumflex artery	6
Right coronary artery	26
Bypass graft	23
Indication for implantation (no. of stents)	
Restenosis	71
PTCA with acute occlusion	14
PTCA as adjunct procedure	27
Chronic occlusion	5
Time to angiographic follow-up (mo)*	
All patients	5.7±4.4
Patients with patent stents	7.2±3.6
No. of stents per patient (no. of patients)	
One	95
Two	8
Three	2

*Means ±SD.

We selected a diameter 0.50 mm larger than the reference diameter of the stenosed vessel.

Anticoagulation regimens evolved throughout the study period, and different protocols were used at the various centers. In the first 23 of the 32 patients treated in Toulouse, heparin was administered subcutaneously three times a day to maintain the activated cephalin-kaolin time (an index of coagulation status) at twice the control value, starting three to five days before the procedure and continuing for six weeks afterward. During the procedure, the 7th through the 32nd patients received an additional 10,000 units of heparin intravenously and 20,000 to 50,000 units of streptokinase by intracoronary infusion. Aspirin (100 mg) and dipyridamole (300 mg) were given daily by mouth, starting 24 hours before the procedure. The 24th through the 32nd patients treated in Toulouse received a vitamin K antagonist (warfarin or acenocoumarol) by mouth, started on the day of the procedure and continued for three to six months. The subcutaneous heparin injections were stopped after a therapeutic level of oral anticoagulant was reached (International Normalized Ratio, ≥ 2.3). In the other centers, aspirin (1 g orally) was started one day before the procedure. Heparin (10,000 to 15,000 units) and urokinase (100,000 units by intracoronary infusion) were administered during the procedure. Heparin was given intravenously, and then the vitamin K antagonist by mouth for three to six months as described above. Aspirin (initially 1 g daily and later 100 mg daily), dipyridamole (300 to 450 mg daily), and in some patients sulfinpyrazone (400 mg daily) were also administered. The first four patients treated in Rotterdam did not receive aspirin.

Quantitative Coronary Arteriography

All cineangiograms were analyzed at the core laboratory in Rotterdam by means of a computer-assisted cardiovascular-angiography analysis system, discussed in detail elsewhere.^{7,8} The important steps will be briefly described. Selected areas of the cine frame encompassing the desired arterial segment were optically magnified, displayed in a video format, and then digitally converted. Vessel contour was determined automatically on the basis of the weighted sum of the first and second derivative functions applied to the digitized information on brightness. A computer-derived estimation of the original dimensions of the artery at the site of the obstruction was used to determine interpolated reference values for arterial diameter and area. The absolute diameter of the segment with stenosis as well as the reference diameter was measured by the computer, which used the diameter of the guiding catheter as a calibration factor, after correcting for pincushion distortion. The interpolated percentage of stenosis of the narrowed segment was

then derived by assuming a circular model and comparing the observed value for stenosis with the reference value. The minimal luminal diameter of each segment immediately proximal and distal to the stent was also measured. The angiographic analysis was performed before and after angioplasty, immediately after stent implantation, and at long-term follow-up evaluation in all patients, with the use of the average of multiple matched views with orthogonal projections whenever possible.

Restenosis

Two different sets of criteria were applied to determine the rate of restenosis. We have found a reduction of 0.72 mm or more in the minimal luminal diameter to be a reliable indicator of angiographic progression of vessel narrowing.⁷⁻⁹ This value takes into account the limitations of coronary angiographic measurements and represents twice the long-term variability of repeat measurements of a coronary-artery obstruction with the cardiovascular-angiography analysis system. The other criterion for restenosis was an increase in the percentage of stenosis from less than 50 percent after stent implantation to 50 percent or more at follow-up evaluation. This criterion was selected since common clinical practice has continued to express lesion severity as a percentage of stenosis.

Statistical Analysis

Values obtained by quantitative angiographic analysis are expressed as means ±SD. The means for each angiographic variable before PTCA, after PTCA, immediately after placement of the stent, and at follow-up were compared by analysis of variance. If significant differences were found, two-tailed t-tests were applied to paired data. A statistical probability of less than 0.05 was considered to indicate significance.

The results of angiographic and clinical follow-up were expressed in a life-table format according to the Kaplan-Meier method.¹⁰ Stent occlusions, cardiac deaths (which were assumed to be due to occlusion, for statistical purposes), and restenosis as defined by the two criteria were considered angiographic end points. The following events were considered clinical end points: death, myocardial infarction, bypass surgery, and nonsurgical revascularization (PTCA or atherectomy). The life table was constructed according to the initial clinical event.

RESULTS

The overall mortality after one year was 7.6 percent (eight deaths) (Table 2). The mean (±SD) period of angiographic follow-up was 5.7±4.4 months in all patients and 7.2±3.6 months in patients whose stents were patent at follow-up. Angiographic follow-up (Fig. 1) was performed in 95 patients (90 percent) with 105 stents (90 percent); 78 stents were patent, and 27 were occluded (Table 3). Angiographic follow-up could not be obtained in 10 patients for the following reasons: 4 patients died, 4 refused follow-up angiography, and 2 had follow-up angiograms that were technically inadequate for analysis (but did not show total occlusion). Twenty angiograms were obtained during the first month after stent implantation; all were obtained because clinical symptoms had occurred, and all showed occlusions. Angiograms obtained after the first month were part of the routine follow-up evaluation; all showed patent stents except in five patients with stent occlusions. Overall, the minimal luminal diameter increased from 1.21±0.56 mm to 1.88±0.43 mm after PTCA and then further, to 2.48±0.51 mm, immediately after stent implantation ($P < 0.0001$) because of the intrinsic dilator function of

the device (Table 4). At follow-up the diameter was found to have decreased to 1.68 ± 1.20 mm. The percentage of stenosis changed similarly, with an initial decrease from 61 ± 14 to 37 ± 12 percent after angioplasty and an additional decrease to 21 ± 10 percent immediately after stent placement ($P < 0.0001$). However, at follow-up the percentage of stenosis had increased to 48 ± 34 ($P < 0.0001$). When only patent stents were included in the analysis of late follow-up, the minimal luminal diameter and the percentage of stenosis were 2.26 ± 0.78 mm and 30 ± 17 percent, respectively. A small, nonsignificant increase occurred in the reference diameter after stent placement (from 3.15 ± 0.54 to 3.22 ± 0.79 mm). During the study, no significant change was seen in the minimal luminal diameter of the proximal or distal segments adjacent to the stent.

The incidence of restenosis (Fig. 2) depended on the definition of stenosis (Fig. 3). When a change of ≥ 0.72 mm in minimal luminal diameter was used as a criterion, restenosis was observed within the patent stent in 17 patients (19 stents), in the proximal segment adjacent to the stent in 3 patients, in the segment immediately distal to the stent in 2 patients, and in both proximal and distal regions in 1 patient. Therefore, the total rate of restenosis was 32 percent among stents and 33 percent among patients. At follow-up the percentage of stenosis had increased to ≥ 50 percent within 10 stents (13 percent) in 9 patients (13 percent) and in the segment proximal to the stent in 1 stent in 1 patient, for a total rate of 14 percent. After one year of clinical follow-up, two of the patients with resteno-

Table 2. Deaths after Stent Implantation.

PATIENT No.	TIME AFTER IMPLANTATION	CAUSE OF DEATH
1	<24 hr	Stent occlusion after vessel closure during PTCA
2	48 hr	Sudden death
3	2 days	Stent occlusion after 24 hr, followed by emergency bypass procedure
4	8 days	Stent occlusion during implantation, myocardial infarction, shock
5	11 days	Sudden death
6	1½ mo	Sudden death
7	2½ mo	Surgery for new lesion of left main artery, after bypass procedure
8	6 mo	Chronic congestive heart failure

sis underwent repeat balloon angioplasty, one patient (two stents) underwent atherectomy, performed within the narrowed stent, and six patients underwent coronary bypass surgery. Death or myocardial infarction did not occur in any of these nine patients.

DISCUSSION

The data from the six European centers at which the coronary-artery stent described above was used show a stent-occlusion rate of 24 percent. The antico-

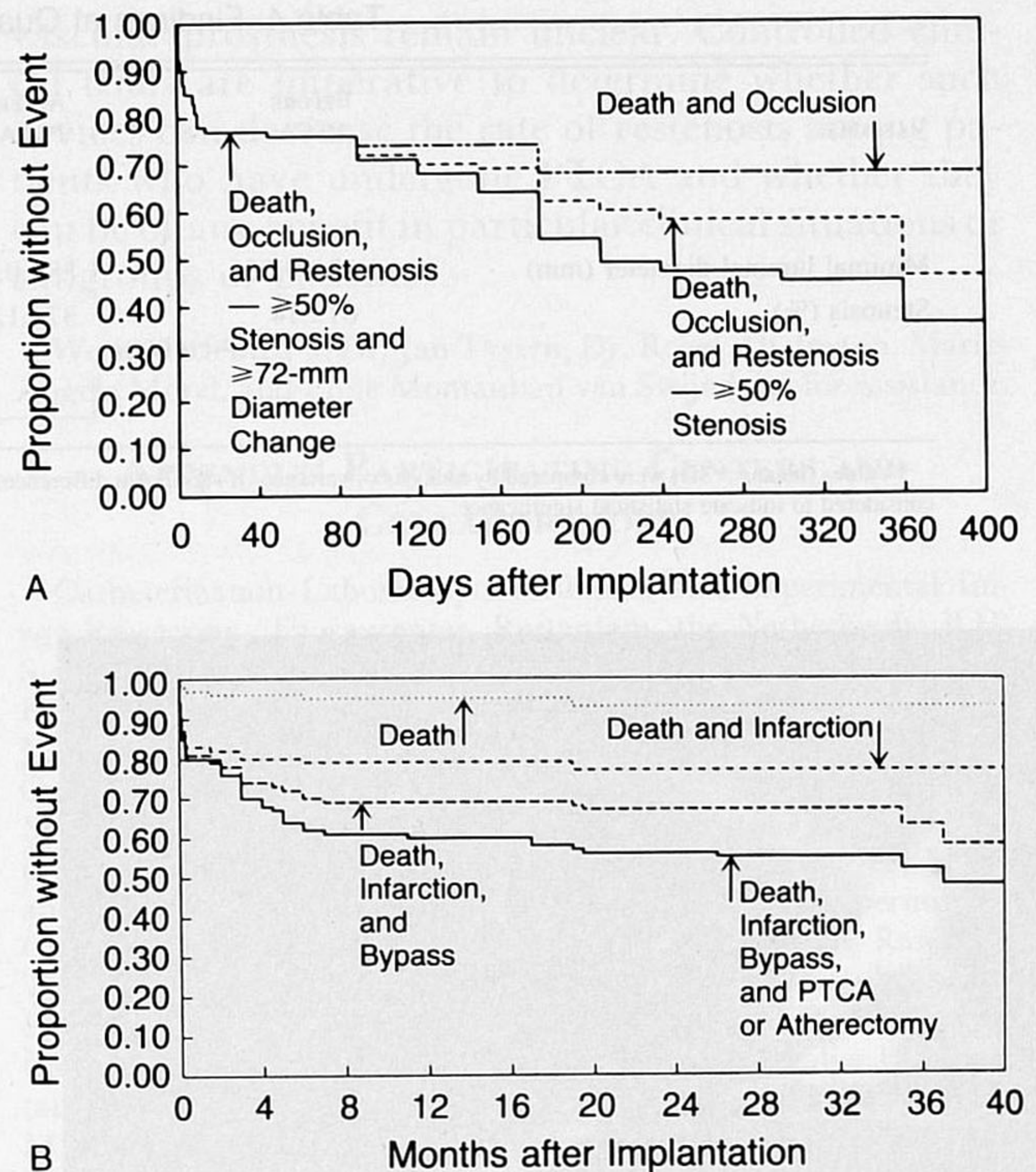


Figure 1. Angiographic and Clinical Follow-up in 95 Patients Who Received 105 Stents.

Occlusion of the stent, cardiac death, and restenosis as determined by either or both of the criteria used (≥ 50 percent stenosis of the vessel and a change of ≥ 72 mm in the minimal luminal diameter) were considered angiographic end points (Panel A). Death, myocardial infarction, bypass surgery, and PTCA or atherectomy were considered clinical end points (Panel B).

agulation regimens and methods for selecting patients differed among the centers, which may explain some of the variability in the occlusion rates between centers. The highest occlusion rate (39 percent) was observed at the Toulouse center, where the initial patients were treated with long-term subcutaneous heparin after placement of the stent, instead of a vitamin K antagonist. The clinical factors that contributed to the occlusions could be identified in 11 patients — i.e., disorders of the coronary artery that are associated with thrombosis (unstable angina, recent myocardial infarction, and chronic occlusion) in 5 patients, technical problems in stent placement in 3 patients, interruption of anticoagulation because of

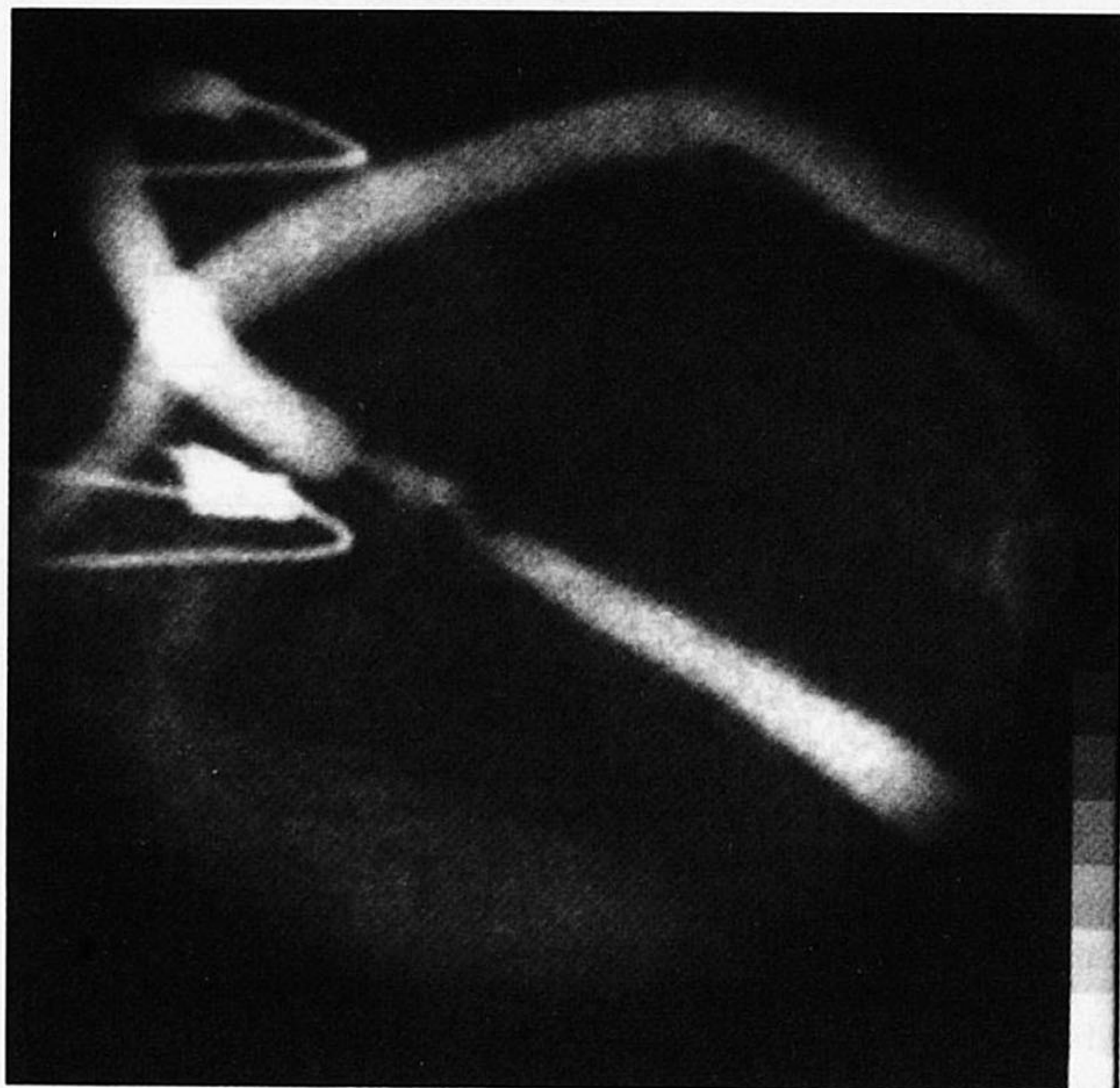
Table 3. Findings at Angiographic Follow-up.

FINDING	NO. OF STENTS (N = 117)	NO. OF PATIENTS (N = 105)
	<i>number (percent)</i>	
Patent stent	78 (67)	70 (67)
Occluded stent	27 (23)	25 (24)
No follow-up angiography		
Death	6 (5)	4 (4)
Refusal	4 (3)	4 (4)
Inadequate study	2 (2)	2 (2)

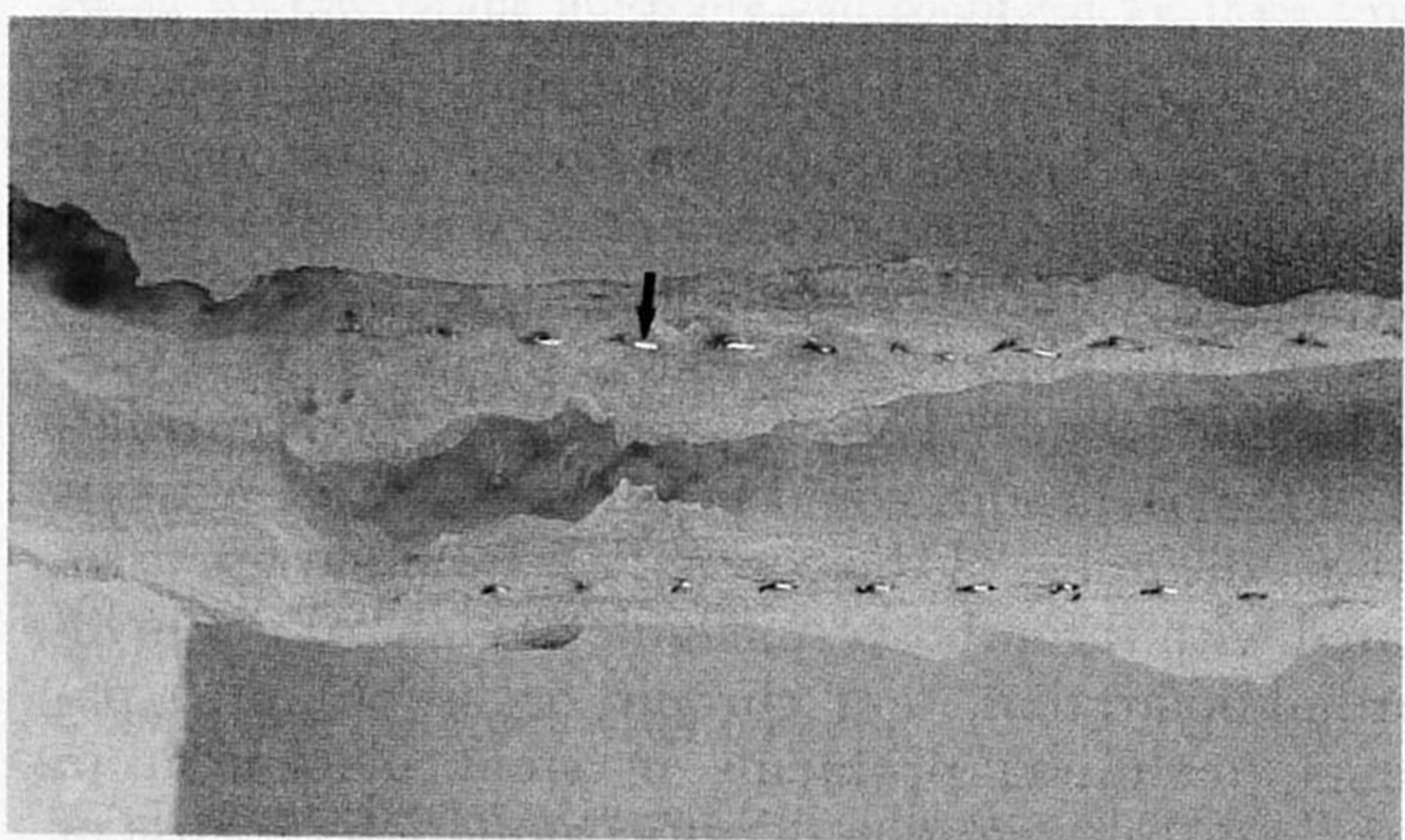
Table 4. Findings at Quantitative Angiography.*

VARIABLE	BEFORE PTCA	AFTER PTCA	AFTER STENT IMPLANTATION	AT FOLLOW-UP	
				PATENT STENTS	ALL STENTS
Minimal luminal diameter (mm)	1.21±0.56	1.88±0.43	2.48±0.51	2.26±0.78	1.68±1.20
Stenosis (%)	61±14	37±12	21±10	30±17	48±34
		P<0.0001	P<0.0001	P<0.0001	
			P<0.002		

*Values (means ±SD) were compared by analysis of variance. If significant differences were found, two-tailed t-tests were applied to pairs of data. A probability of 0.05 was considered to indicate statistical significance.



A



B

Figure 2. Restenosis Six Months after Implantation of a Stent in a Bypass Graft.

In the follow-up angiogram (Panel A), the outline of the stent appears slightly radiopaque and hyperplasia has resulted in a complex narrowing within the vessel segment containing the stent.

In the gross specimen (Panel B) of the surgically retrieved bypass graft containing the segment shown in Panel A, the longitudinal cross section of the vessel shows the stent filaments (arrow) protruding from the wall. The striking similarity between the angiographic contours of the vessel and its actual appearance is evident.

bleeding problems in 2 patients, and hemodynamic compromise before placement of the stent in 1 patient with cardiogenic shock. In view of the early experience with stent occlusion, the investigators agreed to avoid placing stents in patients with acute coronary artery disorders and chronic occlusions or in patients with poor distal runoff (vessels with collateral flow, small vessels less than 3 mm in diameter, or vessels supplying akinetic or severely hypokinetic myocardium). In addition, four patients with six stents died before undergoing angiographic follow-up. Some of these deaths were sudden, suggesting possible stent occlusion. It was difficult to determine whether late occlusion (after 14 days) was superimposed on marked restenosis. Therefore, the rates of occlusion and restenosis may have been underestimated.

The patients in this study underwent two serial interventions, balloon dilation and then stent implantation. Quantitative coronary angiography showed that the initial effect of angioplasty in these patients was similar to that observed in previous angiographic studies,^{8,11} and moreover, the result immediately after placement of the stent was markedly improved. However, the minimal luminal diameter in the entire study group at follow-up (including patients known to have occlusions) was 1.68 mm, which is comparable but not superior to values previously documented in late follow-up studies of coronary balloon angioplasty (1.69 to 1.82 mm).^{8,11} The rate of restenosis in patent stents, when based on a change of ≥ 0.72 mm in the minimal luminal diameter, was 23 percent among segments within the stent and 8 percent among segments adjacent to the stent, for a total rate of 31 percent. When the alternative criterion, ≥ 50 percent stenosis of the luminal diameter, was used, the rate of restenosis was 13 percent among segments within the stent and 1 percent among segments adjacent to the stent. Two previous studies that used similar quantitative methods for late follow-up evaluation after coronary balloon angioplasty have been published. In one study,⁸ the restenosis rate for angiograms obtained at four months was 25.5 percent when the criterion of a change of 0.72 mm was used, and 13.2 percent when the criterion of 50 percent stenosis was used. In the other

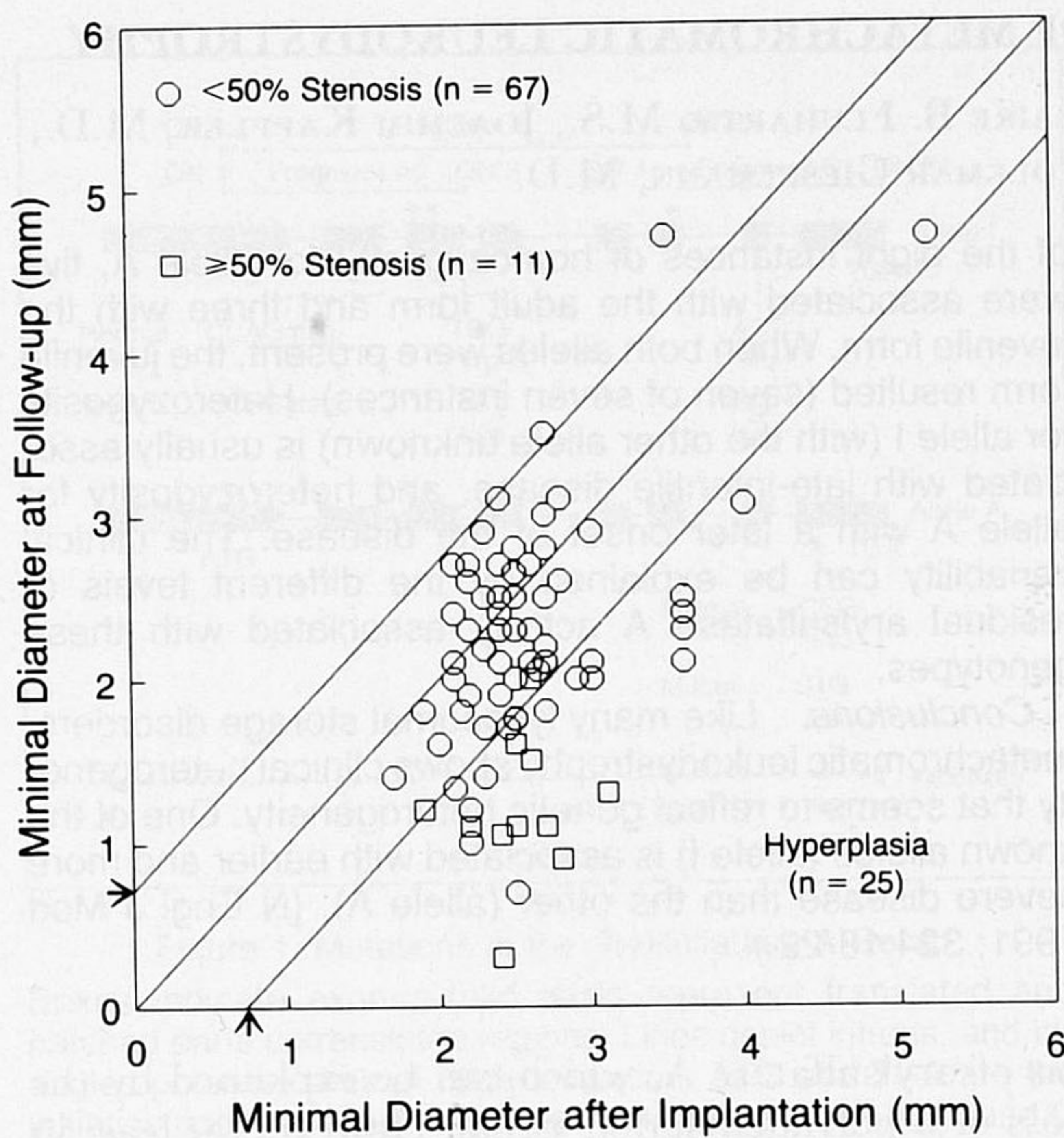


Figure 3. Change in the Minimal Luminal Diameter of 78 Patent Stents between Stent Implantation and Angiographic Follow-up. The diameter of each segment immediately after implantation is plotted against the diameter at follow-up. The lines on each side of the identity line (diagonal) represent the limits of long-term variability of repeat measurements (a change of ≥ 0.72 mm [arrows]). The symbols below the right-hand line represent stents with involvement by severe hyperplasia.

study,¹² when the criterion of 50 percent stenosis was used, the restenosis rate was 37 percent for angiograms obtained four to seven months after angioplasty.

Studies in animals have confirmed that fibrointimal hyperplasia may develop in arterial segments containing stents. Within one week after stents (Wallstent) were implanted in normal porcine arteries, the prostheses became completely covered by endothelium and the vessel lumen had diffuse narrowing, varying in thickness from 60 to 125 μm .^{13,14} By six months, the thickness of the neointima increased from 50 to 400 μm ,¹⁵ corresponding to a decrease of 0.1 to 0.8 mm in the vessel diameter.

Early thrombotic occlusion remains a serious clinical problem with this prosthesis despite anticoagulation. It remains to be determined whether increased experience of operators, changes in the anticoagulation regimen, or selection of patients will circumvent this limitation. New biologic coatings that may make the stent less thrombogenic are currently under investigation. Angiographically detectable narrowing, probably due to fibrointimal hyperplasia, occurs to a marked degree in patients whose stents are patent at late follow-up. Although six months is assumed to be the time frame for the development of restenosis after angioplasty, this may not be true of stent implantation. The clinical indications for the use of an endo-

vascular prosthesis remain unclear. Controlled clinical trials are imperative to determine whether such devices can decrease the rate of restenosis among patients who have undergone PTCA and whether they can be of any benefit in particular clinical situations or subgroups of patients.

We are indebted to Dr. Jan Tyssen, Dr. Roger Thalmann, Marie-Angèle Morel, and Eline Montauban van Swijndregt for assistance.

APPENDIX: PARTICIPATING CENTERS AND COLLABORATORS

Catheterization Laboratory for Clinical and Experimental Image Processing, Thoraxcenter, Rotterdam, the Netherlands: B.H. Strauss, M.D., K.J. Beatt, M.B., B.S., M. v.d. Brand, M.D., P.J. de Feyter, M.D., H. Suryapranata, M.D., I.K. de Scheerder, M.D., J.R.T.C. Roelandt, M.D., and P.W. Serruys, M.D.; Department of Cardiology, Hôpital Cardiologique, Lille, France: M.E. Bertrand, M.D., and J.M. Lablanche, M.D.; Department of Clinical Measurement, National Heart Institute, London: A.F. Rickards, M.D., and U. Sigwart, M.D.; Department of Clinical and Experimental Cardiology, Centre Hospitalier Régional Universitaire, Rangueil, Toulouse, France: J.P. Bounhoure, M.D., A. Courtault, M.D., F. Joffre, M.D., J. Puel, M.D., and H. Rousseau, M.D.; Division of Cardiology, Department of Medicine, Centre Hospitalier Universitaire Vaudois, Lausanne, Switzerland: P. Vogt, M.D., J.-J. Goy, M.D., J.-C. Stauffer, M.D., U. Kaufmann, M.D., L. Kappenberg, M.D., and P. Urban, M.D.

REFERENCES

- Dotter CT, Judkins MP. Transluminal treatment of arteriosclerotic obstruction: description of a new technique and a preliminary report of its application. *Circulation* 1964; 30:654-70.
- Sigwart U, Puel J, Mirkovitch V, Joffre F, Kappenberg L. Intravascular stents to prevent occlusion and restenosis after transluminal angioplasty. *N Engl J Med* 1987; 316:701-6.
- Serruys PW, Juilliere Y, Bertrand ME, Puel J, Rickards AF, Sigwart U. Additional improvement of stenosis geometry in human coronary arteries by stenting after balloon dilatation. *Am J Cardiol* 1988; 61:71G-76G.
- Puel J, Juilliere Y, Bertrand ME, Rickards AF, Sigwart U, Serruys PW. Early and late assessment of stenosis geometry after coronary arterial stenting. *Am J Cardiol* 1988; 61:546-53.
- Sigwart U, Urban P, Golf S, et al. Emergency stenting for acute occlusion after coronary balloon angioplasty. *Circulation* 1988; 78:1121-7.
- Urban P, Sigwart U, Golf S, Kaufmann U, Sadeghi H, Kappenberg L. Intravascular stenting for stenosis of aortocoronary venous bypass grafts. *J Am Coll Cardiol* 1989; 13:1085-91.
- Reiber JHC, Serruys PW, Kooijman CJ, et al. Assessment of short-, medium-, and long-term variations in arterial dimensions from computer-assisted quantitation of coronary cineangiograms. *Circulation* 1985; 71:280-8.
- Serruys PW, Luijten HE, Beatt KJ, et al. Incidence of restenosis after successful coronary angioplasty: a time-related phenomenon. *Circulation* 1988; 77:361-71.
- Beatt KJ, Luijten HE, de Feyter PJ, van den Brand M, Reiber JHC, Serruys PW. Change in diameter of coronary artery segments adjacent to stenosis after percutaneous transluminal coronary angioplasty: failure of percent diameter stenosis measurement to reflect morphologic changes induced by balloon dilation. *J Am Coll Cardiol* 1988; 12:315-23.
- Kaplan EL, Meier P. Nonparametric estimation from incomplete observations. *J Am Stat Assoc* 1958; 53:457-81.
- Koning R, Luijten HE, Beatt KJ, et al. Incidence et chronologie de la resténose coronaire après angioplastie coronaire transluminale percutanée. *Arch Mal Coeur* 1989; 82:177-84.
- Schwartz L, Bourassa MG, Lespérance J, et al. Aspirin and dipyridamole in the prevention of restenosis after percutaneous transluminal coronary angioplasty. *N Engl J Med* 1988; 318:1714-9.
- van der Giessen WJ, Serruys PW, Visser WJ, Verdouw PD, van Schalkwijk WP, Jongkind JF. Endothelialization of intravascular stents. *J Interv Cardiol* 1988; 1:109-20.
- Serruys PW, Beatt KJ, van der Giessen WJ. Stenting of coronary arteries: are we the sorcerer's apprentice? *Eur Heart J* 1989; 10:774-82.
- Rousseau H, Puel J, Joffre F, et al. Self-expanding endovascular prosthesis: an experimental study. *Radiology* 1987; 164:709-14.