

Anisodamine hydrobromide ameliorates cardiac damage after resuscitation

GUI-JUAN DONG, JUN YANG, XIN ZHAO and SHU-BIN GUO

Emergency Medicine Clinical Research Center, Beijing Chaoyang Hospital Affiliated to Capital Medical University, Beijing Key Laboratory of Cardiopulmonary Cerebral Resuscitation, Beijing 100020, P.R. China

Received February 8, 2022; Accepted April 14, 2022

DOI: 10.3892/etm.2022.11349

Abstract. The microcirculation is correlated with the prognosis of patients with cardiac arrest and changes after resuscitation. In the present study, the effects of anisodamine hydrobromide (AH) on microcirculation was investigated and its potential mechanisms were explored. A total of 24 pigs were randomly grouped into three groups (n=8): Sham, Saline and AH group. After pigs were anesthetized, intubated and mechanically ventilated, ventricular fibrillation was induced by electrical stimulation. After 8 min, cardiopulmonary resuscitation was given to the restoration of spontaneous circulation (ROSC). Arteriovenous blood was collected at baseline and 0, 1, 2, 4 and 6 h after ROSC to measure blood gas and cytokines. Perfused vessel density (PVD) and microvascular flow index (MFI) were measured to reflect the microcirculation. Continuous cardiac output and global ejection fraction were measured to indicate hemodynamics. Compared with Sham group, PVD and MFI in the intestines and the sublingual regions decreased significantly after resuscitation. The microcirculation recovered faster in the AH group than the SA group. The decrease of intestinal microcirculatory blood flow was closely related to the decrease of sublingual microcirculatory blood flow. The cardiac function was impaired after resuscitation, and a decrease of IFN- γ as well as IL-2 and an increase of IL-4 as well as IL-10 suggested the immune imbalance. The microcirculation changes in sublingual regions were closely related to the changes in intestines. AH could improve the immune imbalance after resuscitation and was beneficial to the recovery of cardiac function.

Introduction

Although the success rate of resuscitation from cardiac arrest can reach 50% after the implementation of high-quality cardiopulmonary resuscitation (CPR), only 5-15% of cases can survive to discharge due to the poor prognosis (1). The syndrome shown by myocardial dysfunction, cerebral injury and systemic organic ischemia-reperfusion injury (IRI) which could be illustrated as IRI and due to the systemic inflammatory responses is the core characteristic of post-resuscitation syndrome (2). Studies have confirmed that the intestines may be the most sensitive parts to IRI. Cardiac arrest leads to a continuous decrease in intestinal blood flow and an increase in intestinal permeability, subsequently triggering systemic inflammatory responses, which could be the underlying mechanism to cause the sepsis (3-5). Inflammatory cytokines are elevated after CPR on the occurrence of sepsis. However, it remains unclear whether the post-resuscitation syndrome will affect intestinal circulatory function. The microcirculation is important in the treatment for patients in need of critical care since it plays a pivotal role in the oxygen supply and the nutritional supplementation of tissues (6).

It has been reported that there is an inconsistency between systemic blood flow and tissue perfusion in patients with cardiac arrest (7,8), but the microcirculation is correlated with the prognosis of patients (7,9-11). Therefore, microcirculatory dysfunction could be decisive in the prognosis of circulatory failure (12,13). Microcirculation varies greatly among different organs, particularly under low-flow conditions (3,8,14). It is easy to detect the microcirculation in sublingual region as a perfect part for evaluating microcirculation (15). However, it is unclear whether it can fully reflect the visceral microcirculation.

Anisodamine, a commonly used anti-shock drug, is an anticholinergic drug extracted from the Chinese herbal medicine *Anisodus tonguticus* with numerous beneficial effects. Anisodamine was reported to increase intestinal perfusion during the electric shock (16), but there are few studies on its effects on intestinal mucosal blood flow and metabolism. In the present study, the intestinal and sublingual microcirculation was evaluated in CPR pig model, and changes in hemodynamic indicators and inflammatory cytokines were detected to identify the relationship between microcirculatory changes and inflammatory responses. Furthermore, anisodamine hydrobromide (AH) was administered to evaluate its protective effects.

Correspondence to: Dr Shu-Bin Guo, Emergency Medicine Clinical Research Center, Beijing Chaoyang Hospital Affiliated to Capital Medical University, Beijing Key Laboratory of Cardiopulmonary Cerebral Resuscitation, 8 Gongren Tiyuchang South Road, Beijing 100020, P.R. China
E-mail: crownstar1982@yeah.net

Key words: cardiopulmonary resuscitation, microcirculation, anisodamine hydrobromide, hemodynamics

Materials and methods

Chemicals and reagents. Interleukin 4 (IL-4; cat. no. ELP-IL4-1), IL-2 (cat. no. ELP-IL2-1), IL-10 (cat. no. KSC0102) and interferon- γ (IFN- γ , cat. no. KSC4021) assay kits were purchased from Sunbio Biotech Co. Ltd. AH was purchased from the National Institutes for Food and Drug Control (Beijing, China) with more than 99% purity. AH was dissolved in saline for treatment.

Experimental procedures and treatment. A total of 24 male Beijing white pigs (12-14 months old, 30 \pm 2 kg) were purchased from the Institute of Zoology, Chinese Academy of Sciences (Beijing, China). All animals were housed in a specific pathogen-free environment at 23 \pm 2°C and 40-70% humidity under a 12-h light/dark cycle. Pigs had free access to food and water during the experimental period. All procedures were performed following the Animal Care Guidelines of the Institutional Animal Care and Use Committee of Capital Medical University (Beijing, China; approval no. 2020-3-18-92). Pigs were fasted overnight but were allowed free access to water before the experiment.

After an intramuscular injection of midazolam (0.5 mg/kg; Sinopharm Chemical Reagent Co., Ltd.), anesthesia was induced by the intravenous injection of propofol (1.0 mg/kg, Sinopharm Chemical Reagent Co. Ltd.) and maintained with intravenous infusion of pentobarbital (8 mg/kg/h; Sinopharm Chemical Reagent Co. Ltd.). Heart rate and electrocardiogram measurements were monitored using a four-channel physical recorder (BL-420F Data Acquisition & Analysis System; TME Technology Co. Ltd.). A cuffed 6.5 mm cannula was advanced into the trachea. Pigs were ventilated with a volume-controlled ventilator (Servo 900C; Siemens AG) with a fraction of inspiration O₂ (FiO₂) at 0.35 and a respiratory frequency of 12 breaths/min using a tidal volume of 15 ml/kg. The aortic pressure was measured by an angiographic catheter inserting from the femoral artery into the aortic arch. All hemodynamic parameters were monitored by the M1165 system (Hewlett-Packard).

Prior to the induction of cardiac arrest, pigs were allowed to equilibrate for 30 min to reach the stable level after anesthesia. The conductor of temporary pacemaker was inserted into the right ventricle through the right sheath and connected to an electrical stimulator (GY-600A; Kaifeng Huanan Equipment Co., Ltd.) with the SIS2 mode (300/200 ms; 40 V), which provided the continuous electrical stimulation with a proportion of 8:1 and a step length of 10 ms, until ventricular fibrillation (VF) occurred (17) and the mean aortic pressure suddenly dropped to zero.

Ventilation was withheld for 8 min after the onset of VF. Manual CPR was then conducted at a frequency of 100 compressions/min with ventilation at FiO₂ of 100% and a compression-to-ventilation ratio of 30:2. The quality of chest compressions was controlled by a HeartStart MRx Monitor/Defibrillator with Q-CPR (Philips Medical Systems, The Netherlands). If the spontaneous circulation was not restored, defibrillation was attempted with the mode of 150 J.

Restoration of spontaneous circulation (ROSC) was defined by the systolic blood pressure >50 mm Hg for more than 10 min. If spontaneous circulation was not restored within

30 min, the pig was considered dead (18). Immediately after successful CPR, pigs were randomly divided into 2 groups (n=8): Saline and AH. Saline or AH (4 mg/kg) was administered via central venous injection. The same procedures without VF initiation were conducted in the Sham group. At the end of the study, pigs were euthanized with an overdose of pentobarbital (150 mg/kg) via the femoral artery.

Outcome measurement. Both the real-time mean arterial blood pressure and central venous pressure were measured. Continuous cardiac output and global ejection fraction were determined through a pulmonary artery catheter.

Arterial blood gas. Arterial blood was collected at baseline and 0, 1, 2, 4 and 6 h after ROSC, and arterial blood gas and lactate levels were measured using the blood gas analyzer (GEM Premier 3000; Instrumentation Laboratory S.P.A.).

Measurement of cytokines. Heart tissue lysate was harvested with the Mammalian Cell Lysis Kit (cat. no. MCL1-1KT; MilliporeSigma). IL-2, IL-4, IL-10 as well as IFN- γ in the serum and heart tissue lysate were evaluated using enzyme-linked immunosorbent assay in accordance with the manufacturer's protocols.

Caspase activity measurement. The caspase 3 and caspase 9 activities in the heart tissue lysate were determined using the colorimetric assay kits (cat. no. ABIN6965464 for caspase 3 and cat no. ABIN6965484 for caspase 9; Antibodies-online, Inc.) by the microplate reader, according to the manufacturer's protocol.

Pathological analysis. Heart tissues were fixed in 2.5% glutaraldehyde for 3 h at room temperature and then rinsed three times with PBS. Tissues were then fixed in 1% osmium tetroxide for 2 h at room temperature. After rinsing three times with PBS, tissues were processed through a graded series of ethanol (50% for 15 min, 70% for 15 min and 90% for 15 min) at 4°C and finally processed in 100% acetone for 15 min at room temperature. After being embedded in EMBED 812 epoxy (Electron Microscopy Sciences), samples were polymerized at 60°C for 24 h. Sections (50-nm thick) were cut sagittally with LKB ultramicrotomy. The ultrastructural changes were observed by transmission electron microscopy (JEOL Ltd.).

Western blot analysis. The heart tissues were harvested, washed in PBS three times and then homogenized with Mammalian Cell Lysis Kit (cat. no. MCL1-1KT; MilliporeSigma). Protein concentration was determined by bicinchoninic acid assay. Samples with 50 μ g protein were separated on a 10% sodium dodecyl sulfate-polyacrylamide gel, and proteins were electro-transferred onto PVDF membranes. The membranes were blocked with 5% non-fat milk in PBS for 1 h at room temperature and then incubated with primary antibodies (anti-Bax rabbit pAb, cat. no. ab104156, 1:500; anti-Bcl-2 rabbit pAb, cat. no. BS-4563R, 1:1,000; and anti- β -actin rabbit pAb, cat. no. ab8227; 1:3,000) at 4°C overnight. After washing, blots were washed with PBS, and then incubated with the horseradish peroxidase-conjugated secondary antibody (goat

Table I. Baseline characteristics.

Characteristics	Sham (n=8)	Saline (n=8)	Anisodamine hydrobromide (n=8)
Weight (kg)	23.75±0.96	24.13±1.96	24.0±1.41
Heart rate (bpm)	101.75±5.85	102.30±6.63	101.60±5.53
Mean arterial pressure (mm Hg)	99.50±11.94	100.70±12.38	99.45±11.63
Cardiac output (l/min)	3.60±0.22	3.65±0.28	3.68±0.28
pH	7.41±0.06	7.38±0.09	7.34±0.09
Lactate (mmol/l)	2.15±0.44	2.17±0.57	2.14±0.55

Table II. Characteristics at 6 h post-resuscitation.

Group	Sham (n=8)	Saline (n=8)	Anisodamine hydrobromide (n=8)
Heart rate (bpm)	102.5±6.61	128.25±8.83 ^c	110.0±7.80 ^d
Mean arterial pressure (mm Hg)	90.25±4.28	105.38±6.22 ^a	97.58±5.91 ^b
Cardiac output (l/min)	3.64±0.17	2.77±0.23 ^a	3.34±0.33 ^d
pH	7.38±0.03	7.05±0.13 ^a	7.28±0.12 ^b
Lactate (mmol/l)	1.98±0.31	4.79±0.41 ^c	3.11±0.38 ^b

^aP<0.05 vs. Sham group; ^bP<0.05 vs. SA group; ^cP<0.01 vs. Sham group; ^dP<0.01 vs. SA group.

anti-rabbit IgG H&L HRP, cat. no. ab205718, 1:3,000) for 1 h at room temperature. Signals were detected using an ECL kit (Bio-Rad Laboratories, Inc.) according to the manufacturer's protocol. The densitometric analysis was performed with ImageJ software (Version 1.53n; National Institutes of Health).

Microcirculation. A video microscope, namely the side-stream dark field imaging (MicroScan; MicroVision Medical) was used for the observation of the microcirculation. Shortly, a handheld video microscope emits stroboscopic green light, which is absorbed by the erythrocytic hemoglobin and released back immediately. The images of the erythrocytes moving in the micro-vessels are transmitted to the camera through the microscope, thereby obtaining a non-invasive real-time image of the microcirculation. The microcirculation of the experimental animals at 0, 1, 2, 4 and 6 h after ROSC was recorded by manual operation. In order to observe the intestinal microcirculation, 2-3 cm segment of jejunum was isolated. Additionally, it was coated with gauze soaked in warm saline. The mesentery on the serosal side was used as an observing region to evaluate intestinal microcirculation. After the observation, the intestine was back to the peritoneal cavity. The abdominal wall was sutured, and the skin incision was closed through the mode of a wound clip. The images were stored and analyzed offline using AVA-Automated Vascular Analysis 3.1 (Microvision Medical) to obtain perfused vessel density (PVD) and microvascular flow index (MFI) parameters. These parameters were calculated for microvessels ($\leq 20 \mu\text{m}$ in diameter). For PVD, microvessels were classified as either perfused (hyperdynamic, continuous or slow blood flow in the vessels) or non-perfused (intermittent or no blood flow) based on the microcirculation. For

the quantification of MFI, the images were placed into four parts. In addition, the microcirculatory condition was shown in a scheduled scale.

Statistical analysis. Data were presented as the mean \pm SD and analyzed by SPSS 17.0 (SPSS, Inc.). Data were analyzed using one-way analysis of variance followed by Tukey's post hoc test. The correlation analysis was performed with Pearson's analysis. P<0.05 was considered to indicate a statistically significant difference.

Results

AH Treatment promotes the recovery of cardiac function. No distinct variation could be observed in body weight, hemodynamic indexes and blood parameters at baseline between groups (Table I). All animals induced by VF had been resuscitated in a favourable condition. There was no variation of defibrillation and the time of resuscitation between Saline and AH group. With the comparative analysis of baseline group, the cardiac function had been seriously impaired after CPR. The recovery was gradual with the duration, and the cardiac function in the AH group recovered faster than the SA group (Fig. 1 and Table II).

AH treatment decreases myocardial tissue damage. After treatment, hearts were harvested for histopathological analysis. Obvious pathological changes were observed in the saline group. However, myocardial tissue damage was markedly ameliorated after AH treatment. AH treatment significantly decreased the activities of caspase 3/9 compared with the saline group. Moreover, Pro-apoptotic protein Bax expression

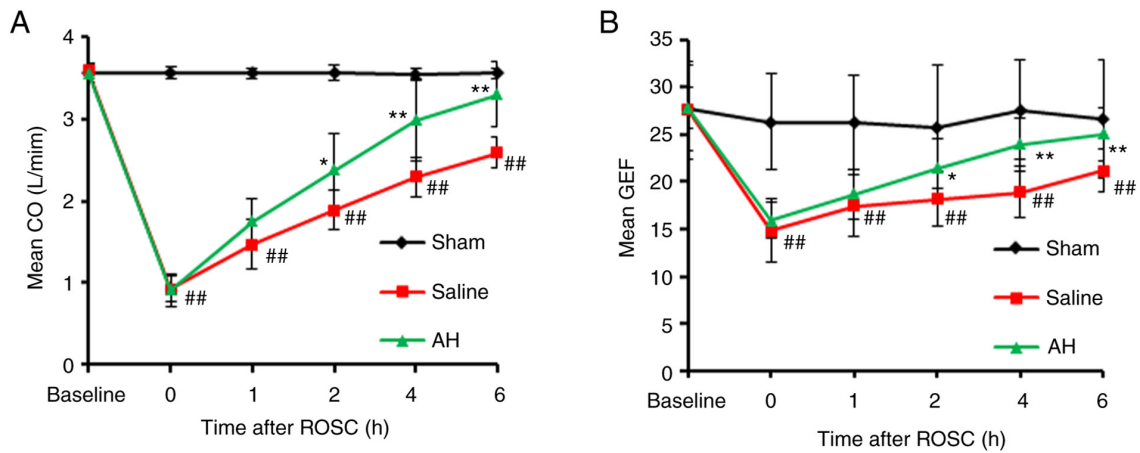


Figure 1. AH treatment promotes the recovery of cardiac function. (A) CO and (B) GEF were recorded at 0, 1, 2, 4 and 6 h after ROSC. CO and GEF decreased significantly, compared with the Sham group. However, CO and GEF recovered faster in the AH group than the Saline group. Data were expressed as the mean \pm SD (n=8). ##P<0.01 vs. the Sham group; *P<0.05 and **P<0.01 vs. the Saline group. AH, anisodamine hydrobromide; CO, cardiac output; GEF, global ejection fraction; ROSC, restoration of spontaneous circulation.

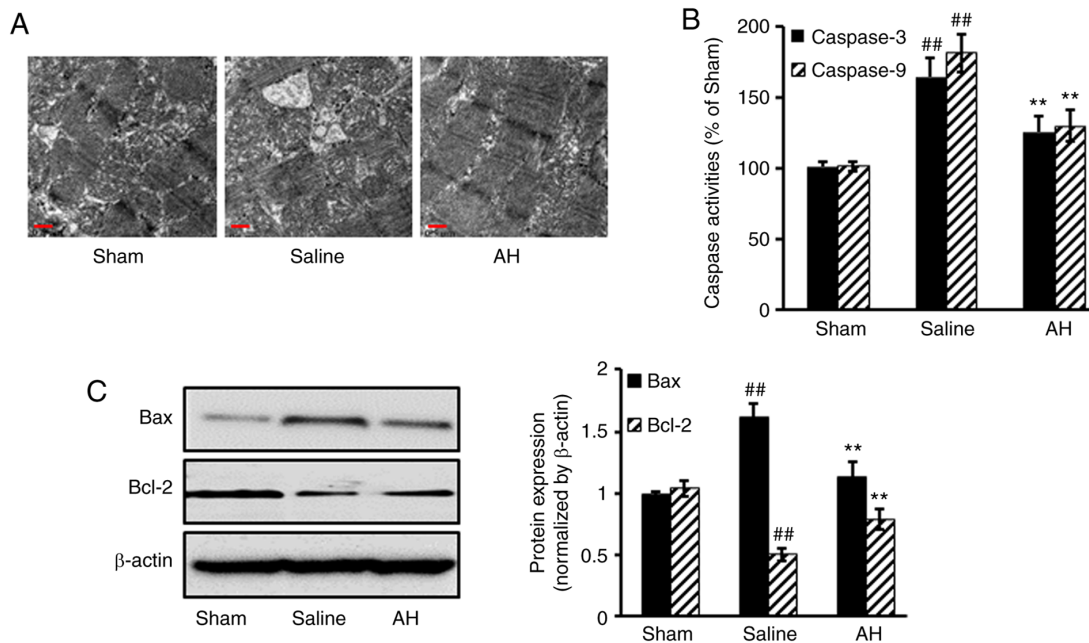


Figure 2. AH treatment decreases myocardial tissue damage. (A) Ultrastructure of the myocardial tissue was observed by transmission electron microscopy (magnification, $\times 200$; scale bar=0.5 μ m). (B) AH treatment also decreased activities of caspase 3/9 in myocardial tissues compared with the Saline group. (C) Furthermore, AH treatment decreased pro-apoptotic protein Bax expression, whereas it increased anti-apoptotic protein Bcl-2 expression compared with the Saline group. Data were expressed as the mean \pm SD (n=8). ##P<0.01 vs. the Sham group; **P<0.01 vs. the Saline group. AH, anisodamine hydrobromide.

decreased, but anti-apoptotic protein Bcl-2 increased after AH treatment compared with the saline group (Fig. 2).

AH treatment improves the microcirculation. After resuscitation, PVD and MFI decreased significantly in the intestines and the sublingual region compared with the Sham group. Afterwards, PVD and MFI gradually recovered with time. However, these microcirculatory indexes recovered faster in the AH group than the Saline group. At 2, 4 and 6 h after resuscitation, there were significant differences of PVD and MFI in both intestines and the sublingual region between two groups. Moreover, the microcirculatory indexes (PVD and

MFI) had a strong correlation between the intestines and the sublingual regions (Figs. 3 and 4).

AH treatment inhibits the transformation of Th1 to Th2. IL-2, IL-4, IL-10 and IFN- γ levels were determined in serum and heart tissue lysate. The results showed that IL-4 and IL-10 secretion significantly increased after ROSC, but IFN- γ and IL-2 levels significantly decreased. However, AH treatment significantly decreased the IL-4 as well as IL-10 levels and increased the IFN- γ as well as the IL-2 levels (Fig. 5). These data indicated that ROSC promoted Th1 to Th2 transformation, but was largely inhibited by AH treatment.

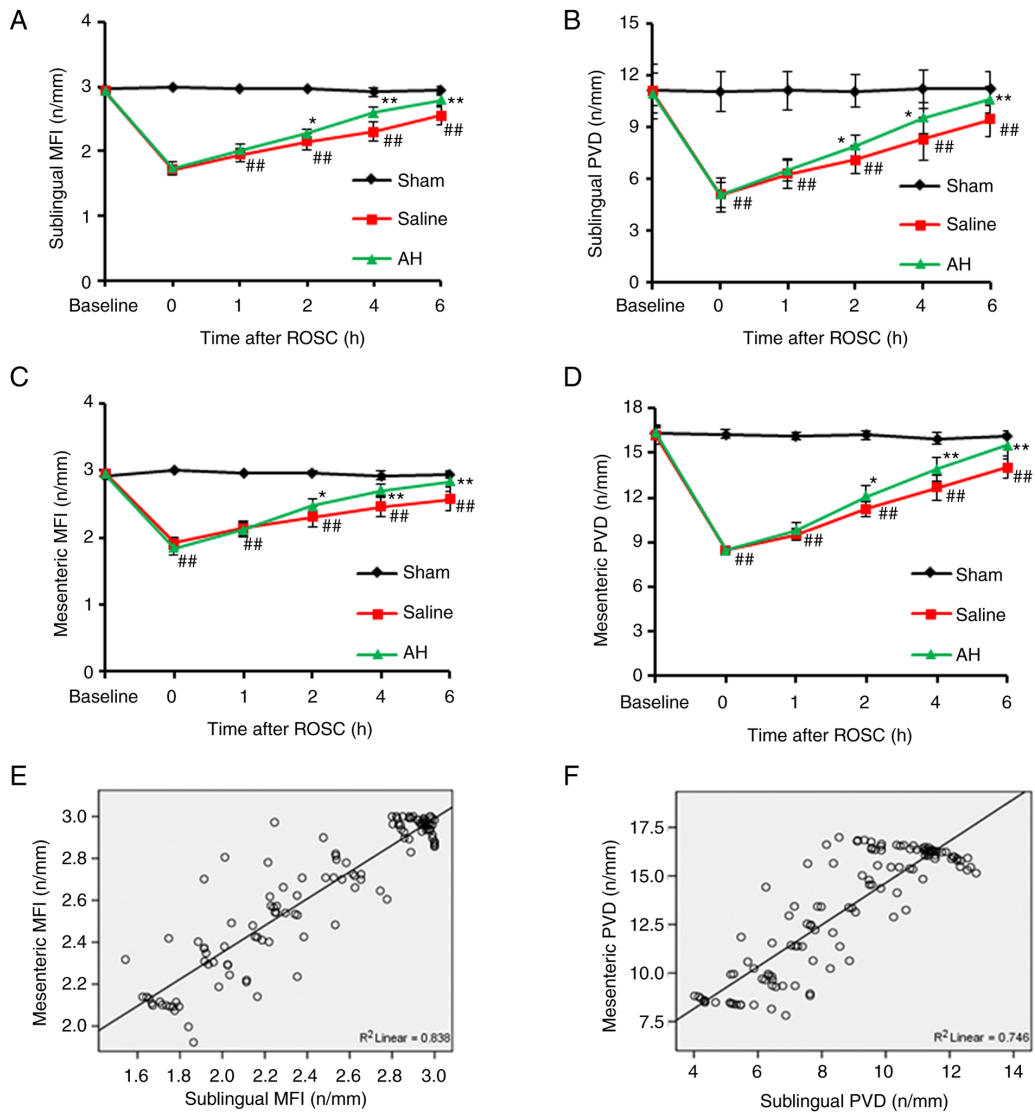


Figure 3. AH treatment improves the microcirculation. (A-D) PVD and MFI in the intestines and the sublingual regions were recorded at 0, 1, 2, 4 and 6 h after ROSC. PVD and MFI decreased significantly compared with the Sham group. However, these microcirculatory indexes recovered faster in the AH group than the Saline group. (E and F) Moreover, the microcirculatory indexes (PVD and MFI) had a strong correlation between the intestines and the sublingual regions. Data were expressed as the mean \pm SD (n=8). ##P<0.01 vs. Sham group; *P<0.05, **P<0.01 vs. Saline group. AH, anisodamine hydrobromide; PVD, Perfused vessel density; MFI, microvascular flow index; ROSC, restoration of spontaneous circulation.

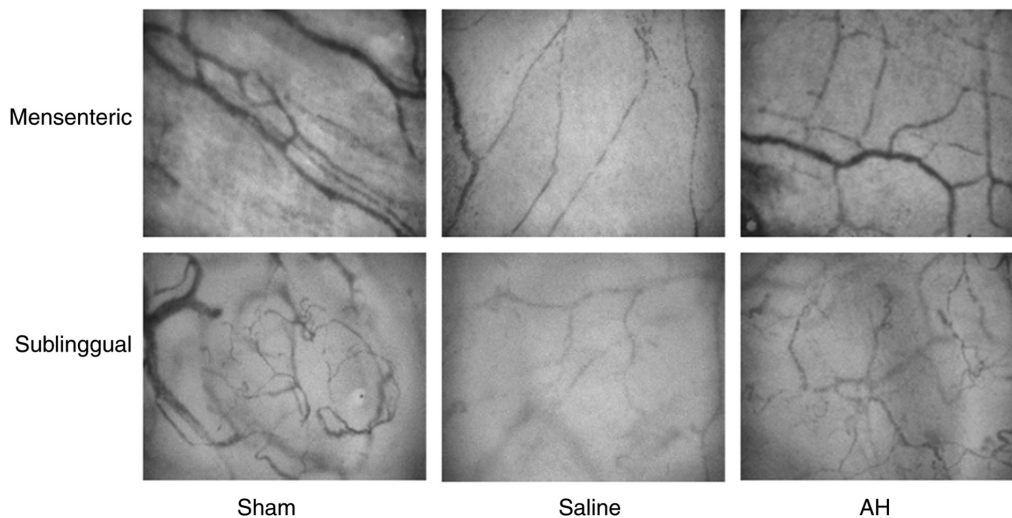


Figure 4. AH treatment improves the microcirculation. Images of microcirculation in the intestines and the sublingual regions were captured 6 h after restoration of spontaneous circulation. AH treatment significantly improved the microcirculation both in the intestines and the sublingual regions. AH, anisodamine hydrobromide.

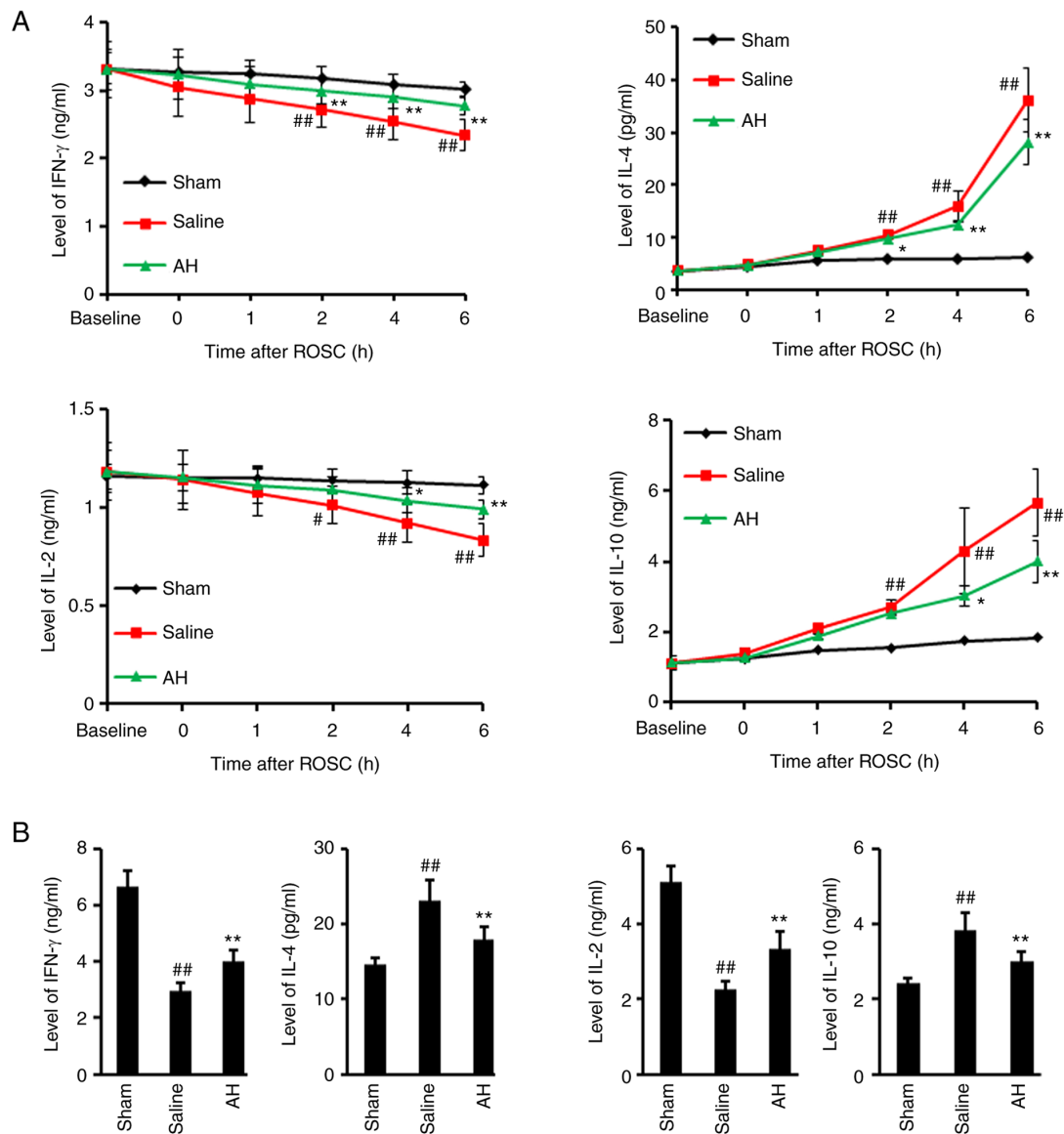


Figure 5. AH treatment inhibits Th1-Th2 transformation in the blood and myocardial tissues. (A and B) Blood samples were collected at baseline, 0, 1, 2, 4 and 6 h after ROSC. Compared with the Saline group, AH treatment significantly increased IFN- γ as well as IL-2 levels, and decreased IL-4 as well as IL-10 levels in serum and myocardial tissues. Data were expressed as the mean \pm SD (n=8). #P<0.05 and ##P<0.01 vs. the Sham group; *P<0.05 and **P<0.01 vs. the Saline group. AH, anisodamine hydrobromide; ROSC, restoration of spontaneous circulation.

Discussion

The present study demonstrated that the intestinal and sublingual microcirculatory blood flow declined dramatically after cardiac arrest and successful CPR. The correlation analysis between the microcirculatory indexes and the hemodynamic indexes showed that intestinal microcirculatory dysfunction has a favourable relationship with the serious situation of post-resuscitation syndrome. In addition, variations in sublingual microcirculation have been key to the changes in the intestinal microcirculation. AH treatment can help the recovery of hemodynamic function and the maintenance of immune balance, and had protective effects after resuscitation.

The sublingual region is the easiest part for the measurement of microcirculation. Previously, the sublingual microcirculation has been regarded as a surrogate index for visceral blood flow. Studies have proposed that non-invasive sublingual CO₂

detection can be used as an alternative measurement of gastric pressure in case of microcirculatory disturbance (19-22). The present study showed that the sublingual microcirculation had a similar performance to the intestinal microcirculation in the early post-resuscitation stage by the visualized method. This result was consistent not only with previous studies on microcirculatory disturbance, but also with studies on endotoxin and septic shock, indicating that the microcirculatory changes in severity and process are similar between sublingual and intestinal region (23-25). Nevertheless, some controversies remain. A clinical study proposed that the microcirculatory changes in the two parts were not parallel on the first day after the occurrence of sepsis (26). Another animal study showed that the correlation of the microcirculation in the two parts disappeared with time (27). It is hypothesized that certain of the treatment measures given in the two aforementioned studies may affect the intestinal microcirculation, leading to different

conclusions of these two studies. In addition, sepsis itself is highly heterogeneous (28).

The abnormal manifestations after resuscitation resemble those of sepsis, and cardiac dysfunction shall be one of the main features. The process of the cardiac function after CPR causes a decrease in visceral blood flow. However, the changes in microcirculation are not exactly equivalent to the variations expressed in the blood flow. In addition, there are various points between visceral organs, in particular notes, in the situation of low flow (29). The correlation between the microcirculation and the cardiac function in the early post-resuscitation stage was confirmed in the present study. The parameters of the intestinal microcirculation after resuscitation showed a tendency to recover, which was considered to have a certain relationship with the automatic regulation and the treatment measures of the body. Actually, it could be observed that the control of microcirculatory blood flow concerning the intestinal wall was too complex.

In terms of both systemic and local factors could make contribution to the intestinal microcirculation, including but not limited to inflammatory cytokines and vasomotor function. In the present study, the parameters of sublingual and intestinal microcirculation and the hemodynamic parameters indicated that the cardiac function of animals was improved in the AH group compared with the Saline group, suggesting that AH can help improve the microcirculation and the cardiac function, and has protective effects after resuscitation.

The integrity of the intestinal mucosal barrier takes a proactive function in the progress of systemic inflammatory response syndrome sepsis as well as multiple organ failures. Th1 lymphocytes produce pro-inflammatory cytokines, such as IFN- γ and IL-2, which mainly contribute to cell-mediated immune responses. Th2 lymphocytes secrete anti-inflammatory cytokines, such as IL-4 and IL-10, for host defence against invasion by exogenous pathogens (30,31). The balance between Th1 and Th2 cells plays a vital role in maintaining normal immune function. In previous ROSC studies on cardiac arrest models, abnormal Th1/Th2 ratios were identified in spleen, lung and myocardium (32,33). It was revealed in the present study that after resuscitation, levels of serum IFN- γ and IL-2 continued to decrease, meanwhile, levels of serum IL-4 and IL-10 increased significantly. Furthermore, levels of IFN- γ and IL-2 were significantly lower, but levels of IL-4 and IL-10 were significantly higher in myocardial tissues after resuscitation. These data were consistent with previous observations in individuals and animal models of cardiac arrest undergoing CPR (6). AH treatment significantly decreased levels of Th2 cytokines IL-4 and IL-10, but increased levels of Th1 cytokines IFN- γ and IL-2. Although Th1/Th2 subtypes were not detected at the cellular level, the present data suggested the relationship between the two cytokine profiles and indicated that AH alleviated the transformation of Th1 to Th2, and improved the immune imbalance induced by IRI. The inflammatory cell infiltration and Th1/Th2 subtypes at the cellular level may be useful to be examined in future studies.

Clinically, intestinal injury after cardiac arrest may be underestimated after successful CPR due to non-specific and delayed manifestations, although it may lead to fatal complications (34). It is not clinically feasible to observe the intestinal microcirculation directly *in vivo*, thus the early detection is difficult. The present study demonstrated the variations in the process of sublingual microcirculation after resuscitation that could indicate

the variations in the process of intestinal microcirculation. In addition, to certain extent, the changes in the cardiac function, suggested that the sublingual microcirculation may be a new alternative for bedside monitoring of post-resuscitation patients.

Acknowledgements

Not applicable.

Funding

No funding was received.

Availability of data and materials

The datasets used and/or analyzed during the current study are available from the corresponding author upon reasonable request.

Authors' contributions

GJD and SBG substantially contributed to the conception and the design of the study. GJD, JY and XZ were responsible for the acquisition, analysis and interpretation of the data. GJD and SBG confirm the authenticity of all the raw data. GJD contributed to manuscript drafting. All authors read and approved the final manuscript.

Ethics approval and consent to participate

All procedures were performed following the Animal Care Guidelines of the Institutional Animal Care and Use Committee of Capital Medical University (Beijing, China; approval no. 2020-3-18-92).

Patient consent for publication

Not applicable.

Competing interests

The authors declare that they have no competing interests.

References

- Goldberger ZD, Chan PS, Berg RA, Kronick SL, Cooke CR, Lu M, Banerjee M, Hayward RA, Krumholz HM and Nallamothu BK; American Heart Association Get With The Guidelines-Resuscitation (formerly National Registry of Cardiopulmonary Resuscitation) Investigators: Duration of resuscitation efforts and survival after in-hospital cardiac arrest: An observational study. *Lancet* 380: 1473-1481, 2012.
- Neumar RW, Nolan JP, Adrie C, Aibiki M, Berg RA, Böttiger BW, Callaway C, Clark RS, Geocadin RG, Jauch EC, *et al*: Post-cardiac arrest syndrome: Epidemiology, pathophysiology, treatment, and prognostication. A consensus statement from the International Liaison Committee on Resuscitation (American Heart Association, Australian and New Zealand Council on Resuscitation, European Resuscitation Council, Heart and Stroke Foundation of Canada, InterAmerican Heart Foundation, Resuscitation Council of Asia, and the Resuscitation Council of Southern Africa); the American Heart Association Emergency Cardiovascular Care Committee; the Council on Cardiovascular Surgery and Anesthesia; the Council on Cardiopulmonary, Perioperative, and Critical Care; the Council on Clinical Cardiology; and the Stroke Council. *Circulation* 118: 2452-2483, 2008.

3. Korth U, Krieter H, Denz C, Janke C, Ellinger K, Bertsch T, Henn C and Klein J: Intestinal ischaemia during cardiac arrest and resuscitation: Comparative analysis of extracellular metabolites by microdialysis. *Resuscitation* 58: 209-217, 2003.
4. Stallion A, Kou TD, Latifi SQ, Miller KA, Dahms BB, Dudgeon DL and Levine AD: Ischemia/reperfusion: A clinically relevant model of intestinal injury yielding systemic inflammation. *J Pediatr Surg* 40: 470-477, 2005.
5. Coopersmith CM, Stromberg PE, Dunne WM, Davis CG, Amiot DM II, Buchman TG, Karl IE and Hotchkiss RS: Inhibition of intestinal epithelial apoptosis and survival in a murine model of pneumonia-induced sepsis. *JAMA* 287: 1716-1721, 2002.
6. Adrie C, Adib-Conquy M, Laurent I, Monchi M, Vinsonneau C, Fitting C, Fraise F, Dinh-Xuan AT, Carli P, Spaulding C, *et al*: Successful cardiopulmonary resuscitation after cardiac arrest as a 'sepsis-like' syndrome. *Circulation* 106: 562-568, 2002.
7. van Genderen ME, Lima A, Akkerhuis M, Bakker J and van Bommel L: Persistent peripheral and microcirculatory perfusion alterations after out-of-hospital cardiac arrest are associated with poor survival. *Crit Care Med* 40: 2287-2294, 2012.
8. Donadello K, Favory R, Salgado-Ribeiro D, Vincent JL, Gottin L, Sciolletta S, Creteur J, De Backer D and Taccone FS: Sublingual and muscular microcirculatory alterations after cardiac arrest: A pilot study. *Resuscitation* 82: 690-695, 2011.
9. Qian J, Yang Z, Cahoon J, Xu J, Zhu C, Yang M, Hu X, Sun S and Tang W: Post-resuscitation intestinal microcirculation: Its relationship with sublingual microcirculation and the severity of post-resuscitation syndrome. *Resuscitation* 85: 833-839, 2014.
10. Buijs EA, Verboom EM, Top AP, Andrinopoulou ER, Buysse CM, Ince C and Tibboel D: Early microcirculatory impairment during therapeutic hypothermia is associated with poor outcome in post-cardiac arrest children: A prospective observational cohort study. *Resuscitation* 85: 397-404, 2014.
11. Omar YG, Massey M, Andersen LW, Giberson TA, Berg K, Cocchi MN, Shapiro NI and Donnino MW: Sublingual microcirculation is impaired in post-cardiac arrest patients. *Resuscitation* 84: 1717-1722, 2013.
12. Top AP, Ince C, de Meij N, van Dijk M and Tibboel D: Persistent low microcirculatory vessel density in nonsurvivors of sepsis in pediatric intensive care. *Crit Care Med* 39: 8-13, 2011.
13. De Backer D, Donadello K, Sakr Y, Ospina-Tascon G, Salgado D, Sciolletta S and Vincent JL: Microcirculatory alterations in patients with severe sepsis: Impact of time of assessment and relationship with outcome. *Crit Care Med* 41: 791-799, 2013.
14. Yu J, Ramadeen A, Tsui AK, Hu X, Zou L, Wilson DF, Esipova TV, Vinogradov SA, Leong-Poi H, Zamiri N, *et al*: Quantitative assessment of brain microvascular and tissue oxygenation during cardiac arrest and resuscitation in pigs. *Anaesthesia* 68: 723-735, 2013.
15. Massey MJ and Shapiro NI: A guide to human in vivo microcirculatory flow image analysis. *Crit Care* 20: 35, 2016.
16. Sheng CY, Gao WY, Guo ZR and He LX: Anisodamine restores bowel circulation in burn shock. *Burns* 23: 142-146, 1997.
17. Wang S, Li C, Ji X, Yang L, Su Z and Wu J: Effect of continuous compressions and 30:2 cardiopulmonary resuscitation on global ventilation/perfusion values during resuscitation in a porcine model. *Crit Care Med* 38: 2024-2030, 2010.
18. Valenzuela TD, Roe DJ, Cretin S, Spaite DW and Larsen MP: Estimating effectiveness of cardiac arrest interventions: A logistic regression survival model. *Circulation* 96: 3308-3313, 1997.
19. Goedhart PT, Khalilzada M, Bezemer R, Merza J and Ince C: Sidestream Dark Field (SDF) imaging: A novel stroboscopic LED ring-based imaging modality for clinical assessment of the microcirculation. *Opt Express* 15: 15101-15114, 2007.
20. Weil MH, Nakagawa Y, Tang W, Sato Y, Ercoli F, Finegan R, Grayman G and Bisera J: Sublingual capnometry: A new noninvasive measurement for diagnosis and quantitation of severity of circulatory shock. *Crit Care Med* 27: 1225-1229, 1999.
21. Povoas HP, Weil MH, Tang W, Moran B, Kamohara T and Bisera J: Comparisons between sublingual and gastric tonometry during hemorrhagic shock. *Chest* 118: 1127-1132, 2000.
22. Creteur J, De Backer D, Sakr Y, Koch M and Vincent JL: Sublingual capnometry tracks microcirculatory changes in septic patients. *Intensive Care Med* 32: 516-523, 2006.
23. Verdant CL, De Backer D, Bruhn A, Clausi CM, Su F, Wang Z, Rodriguez H, Pries AR and Vincent JL: Evaluation of sublingual and gut mucosal microcirculation in sepsis: A quantitative analysis. *Crit Care Med* 37: 2875-2881, 2009.
24. Dubin A, Edul VS, Pozo MO, Murias G, Canullán CM, Martins EF, Ferrara G, Canales HS, Laporte M, Estenssoro E and Ince C: Persistent villi hypoperfusion explains intramucosal acidosis in sheep endotoxemia. *Crit Care Med* 36: 535-542, 2008.
25. Fries M, Weil MH, Sun S, Huang L, Fang X, Cammarata G, Castillo C and Tang W: Increases in tissue Pco₂ during circulatory shock reflect selective decreases in capillary blood flow. *Crit Care Med* 34: 446-452, 2006.
26. Boerma EC, van der Voort PH, Spronk PE and Ince C: Relationship between sublingual and intestinal microcirculatory perfusion in patients with abdominal sepsis. *Crit Care Med* 35: 1055-1060, 2007.
27. Pranskunas A, Pilvinis V, Dambrauskas Z, Rasimaviciute R, Planciuniene R, Dobožinskas P, Veikutis V, Vaitkaitis D and Boerma EC: Early course of microcirculatory perfusion in eye and digestive tract during hypodynamic sepsis. *Crit Care* 16: R83, 2012.
28. Nacul FE, Guia IL, Lessa MA and Tibiriçá E: The effects of vasoactive drugs on intestinal functional capillary density in endotoxemic rats: Intravital video-microscopy analysis. *Anesth Analg* 110: 547-554, 2010.
29. Hildebrand LB, Krejci V, Banic A, Erni D, Wheatley AM and Sigurdsson GH: Dynamic study of the distribution of microcirculatory blood flow in multiple splanchnic organs in septic shock. *Crit Care Med* 28: 3233-3241, 2000.
30. Bretscher PA: On the mechanism determining the TH1/TH2 phenotype of an immune response, and its pertinence to strategies for the prevention, and treatment, of certain infectious diseases. *Scand J Immunol* 79: 361-376, 2014.
31. Paul WE and Zhu J: How are T(H)2-type immune responses initiated and amplified? *Nat Rev Immunol* 10: 225-235, 2010.
32. Gu W, Zhang Q and Li CS: Effect of splenic regulatory T-cell apoptosis on the postresuscitation immune dysfunction in a porcine model. *Chin Med J (Engl)* 129: 1577-1583, 2016.
33. Gu W, Li C, Yin W and Hou X: Effects of Shenfu injection on the expression of transcription factors T-bet/GATA-3 in pigs with post-resuscitation myocardial dysfunction. *Zhonghua Wei Zhong Bing Ji Jiu Yi Xue* 27: 190-196, 2015 (In Chinese).
34. Katsoulis IE, Balanika A, Sakalidou M, Gogoulou I, Stathoulopoulos A and Digalakis MK: Extensive colonic necrosis following cardiac arrest and successful cardiopulmonary resuscitation: Report of a case and literature review. *World J Emerg Surg* 7: 35, 2012.



This work is licensed under a Creative Commons Attribution-NonCommercial-NoDerivatives 4.0 International (CC BY-NC-ND 4.0) License.