

Anomalous formation of the circulus arteriosus and its clinico-anatomical significance

PP Poudel and C Bhattarai

Department of Anatomy, Manipal College of Medical Sciences, Pokhara, Nepal

Corresponding author: Phanindra Prasad Poudel, Lecturer, Department of Anatomy, Manipal College of Medical Sciences, Pokhara, Nepal; e-mail: phani_anat@yahoo.com

ABSTRACT

Circulus arteriosus (Circle of Willis) is an anastomotic ring which unites the internal carotid and vertebrobasilar systems. It slows down the blood before it reaches the brain and helps in collateral circulation. Anatomic study reveals the variation in the pattern and calibre of vessels which make up the circulus arteriosus. The greatest variation in calibre occurs in the posterior communicating artery. The posterior cerebral artery is divided into three portions by the posterior communicating artery; these are- P_1 , P_2 , and P_3 . Three basic configurations of the posterior communicating artery has been described; foetal, transitional and adult. In foetal configuration: the diameter of the P_1 segment of posterior cerebral artery is less than the diameter of posterior communicating artery so that the blood supply to the occipital lobes is mainly via the internal carotid arteries. Thirty five circulus arteriosus of the formalin embalmed brains were studied during the period of three years. Posterior cerebral and posterior communicating arteries were traced from their origins to terminations. It is revealed that in 8.6% of cases the formation of the circulus arteriosus was anomalous. The calibre of the pre communicating (P_1) segment of posterior cerebral artery was smaller than the posterior communicating artery. It appeared that the posterior cerebral artery is the continuation of posterior communicating artery, thus the branch of the internal carotid artery. Anomalies of the formation of circulus arteriosus leads to stroke. The neurosurgical importance of this study lies during the exposure of the region for different purposes. Knowledge of the vascular variations will increase the success of the procedure.

Keywords: Circulus arteriosus (Circle of Willis), Posterior cerebral artery, Posterior communicating artery, Stroke, Neurosurgical.

INTRODUCTION

The circulus arteriosus (Circle of Willis) is a large arterial anastomotic ring, of the brain, which unites the internal carotid and vertebrobasilar systems, lying in the subarachnoid space within the deep interpeduncular cistern.¹ This anastomosis assists to slow down the blood before it reaches the brain and helps in collateral circulation. The pulsations of the arteries also help in drainage of the cerebrospinal fluid in the interpeduncular cistern.²

Anatomic study reveals the considerable individual variation in the pattern and calibre of vessels which make up the circulus arteriosus. Although a complete circular channel almost always exists, one vessel is usually sufficiently narrowed to reduce its role as a collateral route. Cerebral and communicating arteries individually may all be absent, variably hypoplastic, double or even triple. The circle is rarely functionally complete. The haemodynamics of the circle is influenced by variations in the calibre of communicating arteries and in the segments of the anterior and posterior cerebral arteries which lie between their origins and their junctions with the corresponding communicating arteries.¹ The greatest

variation in calibre between individuals occurs in the posterior communicating artery. Sometimes, the diameter of the precommunicating part of the posterior cerebral artery is smaller than that of posterior communicating artery, in which case blood supply to the occipital lobes is mainly from the internal carotids via the posterior communicating arteries.¹ Anatomic variations of circle of willis can also be the result of embryological anomalies.³ Prematurity is associated with more complete circle of willis and fewer anatomic variation; more variations involved major arterial segment, but few variations occur in communicating arteries.⁴ In some instances internal carotid artery provide the major supply to posterior cerebral artery.⁵ Anomalies of the branches of internal carotid artery can lead to serious clinical conditions like stroke.²

The posterior cerebral artery is divided into three segments by the posterior communicating artery, the proximal portion is the pre communicating (P_1) segment, then the portion up to the perimesencephalic cistern is the post communicating (P_2) segment, and the rest of the portion running in the calcarine fissure is the P_3 segment.^{1,4} Three basic configurations of the posterior

communicating artery has been described: foetal, transitional and adult.⁶ In the foetal configuration, the diameter of the ipsilateral P₁ segment of posterior cerebral artery is less than the diameter of posterior communicating artery so that the blood supply to the occipital lobes is mainly via the internal carotid arteries. In transitional configuration, the posterior communicating artery is equal in diameter to the P₁ segment of the posterior cerebral artery. In the adult configuration, P₁ has a diameter larger than the posterior communicating artery so that the blood supply to the occipital lobes is mainly via the vertebrobasilar system. Such anatomical variations may have clinical significance as it makes it possible for thrombotic material arising in atherosclerotic lesions in the internal carotid artery to be dislodged into the posterior cerebral artery via the larger diameter posterior communicating artery.⁶

It is important to emphasize the anomalies of the cerebral circulation, as they are not rare and may have profound clinical implications.^{7,8} Cerebral-vascular diseases present one of the leading problems of the modern mankind. They are followed by the risk of high mortality rate, and as such cause high level of disability with people who survive cerebral-vascular incident (stroke, apoplexy).⁹ The knowledge of cerebrovascular variants is essential in education, training, diagnosis and treatment. After the occlusion of an internal carotid artery the principal source of collateral flow is through the arteries of the circle of Willis, but the size and patency of these arteries are quite variable. Study of the anatomy of the collateral pathways in patients with internal-carotid-artery occlusion with or without infarction in the watershed area of the deep white matter may identify patterns that afford protection from ischemic infarction.¹⁰

MATERIALS AND METHODS

Thirty five circulus arteriosus on the formalin embalmed brains were studied during the period of three years, in the dissection Hall of Manipal College of Medical Sciences, Pokhara, Nepal. The formation and branches of circulus arteriosus was observed with the aid of a magnifying lens by removing the arachnoid mater carefully in the interpeduncular cistern. Posterior cerebral artery was traced from its origin to the termination, posterior communicating artery was also observed. The variations encountered were noted. And the photograph of the best observed anomalous circulus arteriosus was taken.

RESULTS

Out of 35 circulus arteriosus, anomalous formation was found in 3 cases, 8.6%, Fig. 1. In rest, 32 cases, 91.4%,

the formation of circle of willis was normal, the diameter of the precommunicating (P₁) segment of posterior cerebral artery was larger than that of posterior communicating artery. In all variant 3 cases, anomalous structures were found bilaterally. It was observed pre communicating (P₁) segment of the posterior cerebral artery was comparatively very small in calibre than the posterior communicating artery and post communicating (P₂) and P₃ segments of posterior cerebral artery on both sides. It was appeared that the posterior cerebral artery was the continuation of posterior communicating artery, branch of internal carotid artery. P₁ segments of posterior cerebral arteries of two sides are small and appear to be of same caliber. It was also observed that the superior cerebellar artery, branch of distal portion of basilar artery, was of more caliber than the P₁ segment of the posterior cerebral artery.

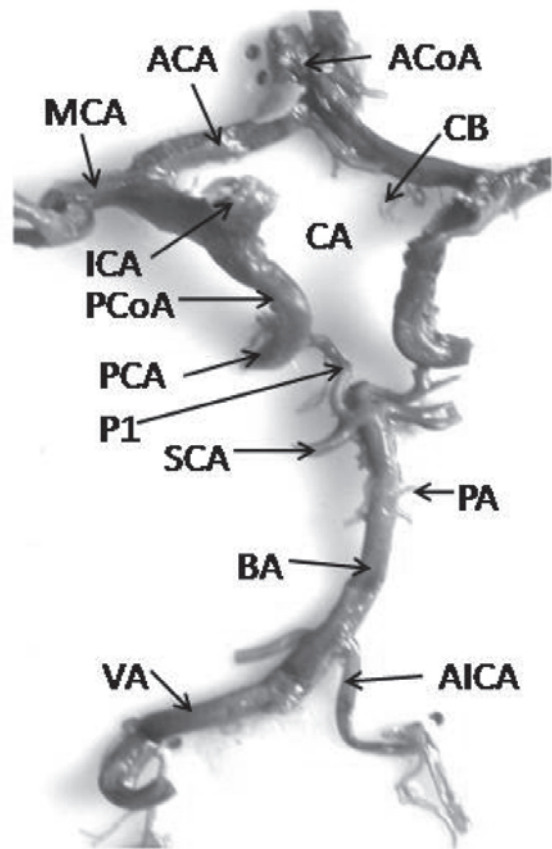


Fig.1. Anomalous formation of the circulus arteriosus (Circle of Willis)

VA= Vertebral artery, BA= Basilar artery, AICA= Anterior inferior cerebellar artery, PA= Pontine artery, SCA= Superior cerebellar artery, P= Pre communicating segment of posterior cerebral artery, PCA= Posterior cerebral artery, PCoA= Posterior communicating artery, ICA= Internal carotid artery, MCA= Middle cerebral artery,

ACA= Anterior cerebral artery, ACoA= Anterior communicating artery, CB= Central branches, CA= Circulus arteriosus (Circle of Willis)

DISCUSSION

In 1962, Thomas Willis was the first scientist to describe the circulus arteriosus, the major blood supply to the brain.¹¹ Since then many anatomical variations have been reported on the different branches forming the circulus arteriosus by various authors pertaining to the formation, development and size of the principal arteries.¹²⁻¹⁴ The majority of vessels contributing to the formation of the circulus arteriosus are the anterior cerebral, middle cerebral and posterior cerebral. Most of the anatomical variations have been reported on the posterior cerebral and posterior communicating arteries.¹¹

Variations in the origin, termination and distribution of the arteries at the base of the brain are common. The disappearance of the vessels that normally persist or the persistence of the vessels that normally disappear or formation of new vessels due to hemodynamic factors is the probable reason for the anomalies. In most of the arterial variations the brain function may not be affected due to the collateral circulation and compensation from the arteries of the other side.¹⁵ In a report by Kapoor *et al*, the circulus arteriosus showed variations in 54.8% of cases.¹⁶ In the same study different patterns of variations were observed regarding posterior cerebral and posterior communicating arteries. Multiplication of posterior cerebral artery was observed in 2.4% cases while it was hypoplastic in 10.6% brains; posterior communicating artery was absent in 1.0% of cases.¹⁶ In a study on the Northwest Indian brains, the posterior communicating artery showed aneurysms in 0.9% of cases.¹⁷ In a study by Merkkola *et al*, left posterior communicating arteries were absent in 46.0% of cases. In such cases there was defective perfusion of blood into the left hemisphere.¹⁸ In a report by Nayak SB, left posterior communicating artery was absent.¹⁹ In a study by Caruso *et al*, it showed the 3.0% of variations on the posterior cerebral artery. The variations they noted include the duplication of its pre communicating (P₁) segment, its fenestration and a common trunk for the origin of itself and superior cerebellar artery.²⁰ Very rarely the proximal segment of the posterior cerebral artery may be reduced in size.²¹ In such cases, the distal part of the artery will be replaced or reinforced by the posterior communicating artery, which will be very large as in the present study.

Three basic configurations of the posterior communicating artery have been described: foetal, transitional and adult.⁶ In the foetal configuration, the diameter of the ipsilateral P₁ segment of posterior cerebral artery is less than the diameter of posterior communicating artery so that the blood supply to the occipital lobe is mainly via the internal carotid arteries, as observed in the present study. Foetal type variation

may have clinical significance as it makes it possible for thrombotic material arising in atherosclerotic lesions in the internal carotid artery to be dislodged into the posterior cerebral artery via the larger diameter posterior communicating artery. The middle cerebral artery almost always arises from the internal carotid artery, but in about 10-40%, the internal carotid artery is responsible for the majority of blood flow in the posterior cerebral artery as well.⁶ This is in support of the present study.

Classic embryology books state that the cranial vessel plexuses first appear in the embryo undergo various morphological modifications with the growth of brain and related parts. Arterial abnormalities of the foetal or adult circulus arteriosus are associated with this variations.²² Posterior cerebral artery is embryologically a continuation of posterior communicating artery; hence persistence of the pattern is embryonic type. The anomalous posterior cerebral and posterior communicating arteries are not uncommon. The type which is found in 8.57% of the cases, in the present study, is scarce in literature and not consistent. Moreover, it has reported the variation of such anomalies varying from 6.0-40.0%,¹⁴ hypoplastic posterior cerebral artery in 10.6% of cases.¹⁶ It is worthwhile to know these variations to the neurosurgeons. In these, the internal carotid arteries are the major source of blood to the almost all parts of the cerebrum. Thus this pattern of variation may be momentous in the clinico-anatomical explanation.

REFERENCES

1. Standring S, Crossman AR, Collins P. Vascular supply of the brain. In: Standring S, editor. *Grays Anatomy*. 39th ed. New York: Elsevier Churchill Livingstone; 2001; 300-1.
2. Nayak SB, Somayaji SN, Soumya KV. Variant arteries at the base of brain. *Int'l J Anat Variations* 2009; 2: 60-1.
3. Puchades-Orts, Nombela-Gomez M, Ortuno-Pacheco G. Variation in form of circle of Willis: some anatomical and embryological considerations. *Anat Rec* 1975; 185: 119-24.
4. Malamateniou C, Adams ME, Srinivasan L *et al*. The anatomic variations of the circle of Willis in preterm-at-term and term-born infants: an MR angiography study at 3T. *Amer J Neuroradiol* 2009; 30: 1955-62.
5. De Silva KRD, Silva TRN, Gunasekera WSL *et al*. Variation in the origin of the posterior cerebral artery in adult Sri Lankans. *Neurol India* 2009; 57: 46-9.
6. Saeki N, Rhoton ALJ. Microsurgical anatomy of the upper basilar artery and the posterior circle of Willis. *J Neurosurg* 1977; 46: 563-78.
7. Serizawa T, Saeki N, Yamaura A. Microsurgical anatomy and clinical significance of the anterior communicating artery and its perforating branches. *Neurosurg* 1997; 40: 211-6.
8. Matsumura M, Nojiri K. Ruptured anterior communicating artery aneurysms associated with fenestration of the anterior cerebral artery. *Surg Neurol* 1984; 22: 371-6.
9. Voljevic A, Kulenovic A, Kapur E *et al*. Angiography analysis of variations of the posterior segment of the circle of willis. *Bosn J Basic Med Sci* 2005; 5: 30-4.

10. Gurdal E, Cakmak O, Yalcinkaya M *et al*. Two variations of the anterior communicating artery: a clinical reminder. *Neuroanat* 2004; 3: 32-4.
11. Paul S, Mishra S. Variations of the Anterior Cerebral Artery in human cadavers: A dissection study. *J Anat Soc India* 2004; 53: 15-8.
12. Orlando GE, Ruggiero S, Orlandin SZ *et al*. Blood vessel size of circulus arteriosus cerebri (Circle of Willis): A statistical research on 100 human subjects. *Acta Anatomica* 1985; 123: 72-6.
13. Kamath S. Observations on the length and diameter of vessels forming the circle of Willis. *J Anat* 1981; 133: 419-23.
14. Van Overbeeke JJ, Hillen B, Tulleken CA. A comparative study of the circle of Willis in fetal and adult life. The configuration of the posterior communicating artery. *J Anat* 1991; 176: 45-54.
15. Stehbens WE. Aneurysms and anatomical variation of the cerebral arteries. *Arch Pathol* 1963; 75: 45-63.
16. Kapoor K, Singh B, Dewan LI. Variations in the configuration of the circle of Willis. *Anat Sci Int'l* 2008; 83: 96-106.
17. Sahni D, Jit I, Lal V. Variations and anomalies of the posterior communicating artery in Northwest Indian brains. *Surg Neurol* 2007; 68: 449-53.
18. Merkkola P, Tulla H, Ronkainen A *et al*. Incomplete circle of Willis and right axillary artery perfusion. *Ann Thorac Surg* 2006; 82: 74-9.
19. Nayak SB. Anomalous arteries at the base of the brain: a case report. *Neuroanat* 2008; 7: 45-6.
20. Caruso G, Vincentelli F, Rabehanta P *et al*. Anomalies of the P₁ segment of the posterior cerebral artery: early bifurcation or duplication, fenestration, common trunk with the superior cerebellar artery. *Acta Neurochir* 1991; 109: 66-71.
21. Bergman RA, Afifi AK, Miyauchi R. Posterior Cerebral Artery. Illustrated Encyclopedia of Human Anatomic Variation: Opus II: Cardiovascular System: Arteries: Head, Neck, and Thorax. <http://www.anatomyatlases.org/AnatomicVariants/Cardiovascular/Text/Arteries/CerebralPosterior.shtml>. Jan 2009.
22. Ljiljana V, Milenkovic Z, Pavlovic S. Comparative morphological variations and abnormalities of circle of Willis: a mini review including two personal cases. *Neuro Surge Rev* 2002; 25: 247-51.