

Anomalous origin of the right coronary artery from the left anterior descending artery: Review of the literature

Mustafa Yurtdaş¹, Oktay Gülen²

¹Department of Cardiology, Medisina Hospital, Van, Turkey

²Department of Nuclear Medicine, Medisina Hospital, Van, Turkey

Abstract

Coronary artery anomalies that take place during fetal development are determined in approximately 1.3% of coronary angiograms. The right coronary artery originating from the left coronary system is an extremely rare variation of the single coronary artery anomaly in which the prognosis is usually benign provided that the anomalous vessel does not pass between the aorta and the pulmonary artery. Anomalous right coronary artery anomaly has been rarely associated with other congenital cardiovascular anomalies such as transposition of the great vessels and tetralogy of Fallot.

To date, a few attempts at classification have been made for coronary artery anomalies, but none of them seems comprehensive or practical for clinicians. The clinical significance of coronary anomalies is usually determined by underlying anatomic features of the wrong coronary origin and/or coronary atherosclerosis. Although coronary angiography is an important diagnostic method, new non-invasive methods such as coronary computed tomography angiography and cardiac magnetic resonance imaging have important roles to play in characterizing this coronary anomaly. It should be noted that the management strategy of these patients may vary based on clinical presentation, anatomical details and additional findings. (Cardiol J 2012; 19, 2: 122–129)

Key words: anomalous right coronary artery, diagnosis, angiography, therapy

Case presentation

A 65 year-old man was admitted to our hospital complaining of chest pain. His medical history consisted of hypertension and hyperlipidemia. He was a non-smoker and he had a one month history of chest pain, which was sometimes precipitated by effort. On admission, his ECG and cardiac enzyme levels were normal. Telecardiography and transthoracic echocardiography were within normal limits. Treadmill exercise electrocardiogram showed 1 mm ST segment depression in inferior leads. Cardiac

catheterization was performed. Cannulation of the left main coronary artery (LMCA) displayed normal courses of the LMCA, dominant left circumflex (LCX), and left anterior descending artery (LAD) (Fig. 1). An anomalous right coronary artery (RCA) as a separate small branch arose from the mid LAD close to the third diagonal branch, then coursed anteriorly down the right atrioventricular (AV) groove (Figs. 2, 3). Attempts to cannulate the RCA with the right Judkins catheter were unsuccessful. Left ventriculography was normal, with an ejection fraction of 64%. Neither aortography nor pulmonary

Address for correspondence: Mustafa Yurtdaş, MD, Medisina Van Hastanesi, Kardiyoloji Bölümü, 65200, Van, Turkey, tel: 090 432 214 68 68, fax: 090 432 212 10 08, e-mail: mustafayurtdas@yahoo.com

Received: 18.11.2011

Accepted: 13.12.2011

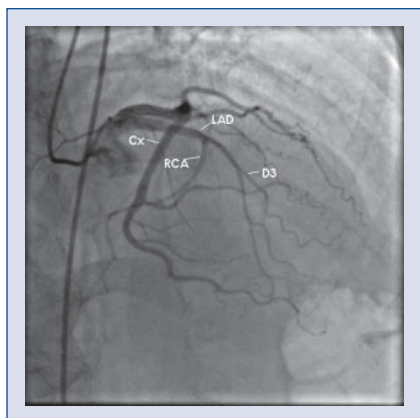


Figure 1. Right anterior oblique cranial view of left coronary injection showing origin of the right coronary artery (RCA) from the mid left anterior descending artery (LAD); CX — circumflex artery; D3 — diagonal 3.

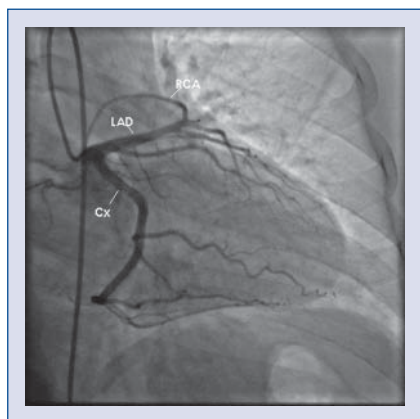


Figure 2. Right anterior oblique caudal view of left coronary injection showing origin of the right coronary artery (RCA) from the mid left anterior descending artery (LAD); CX — circumflex artery.

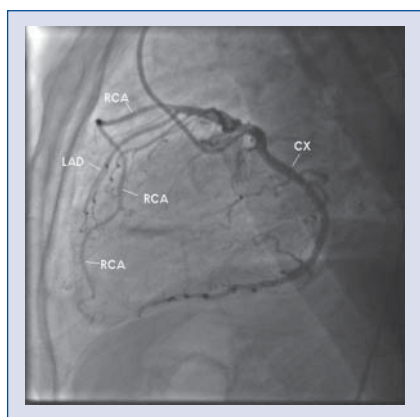

Figure 3. Left lateral view showing angle causing the anomalous right coronary artery (RCA) to turn toward the right atrioventricular groove; LAD — left anterior descending artery; CX — circumflex artery.

artery (PA) angiography showed the presence of an origin of a supplementary RCA from another site, such as the PA and the aorta. This was concluded to be a benign anomaly from the data of a nuclear medical study that did not show any hypoperfused region in the myocardium. Therefore, the patient was only given long-term medical therapy for hyperlipidemia and hypertension. At follow-up, it was observed that the patient had an asymptomatic clinical status.

Incidence

Coronary artery anomalies (CAAs) proceed from disorders that come about during the third week of fetal development. CAAs are defined as variants of the normal coronary artery. CAAs are found in 0.6% to 5.6% of patients undergoing diagnostic coronary angiography, and in approximately 1% of routine autopsy examinations (Table 1). The commonest CAA is a separate origin of the LAD and LCX, with an incidence of 0.41%, followed by the LCX arising from the RCA, with an incidence of 0.37%. CAAs result from several anatomic aspects according to their origin, course and distribution. The incidence of anomalous RCA originating from the left coronary system ranges from 0.1% to 0.9%. The origin of an anomalous RCA may be from the left sinus of Valsalva, the posterior sinus of Valsalva, the ascending aorta, the PA, the left ventricle, the LMCA, the LCX or the LAD (Table 2) [1–24]. The origin of an anomalous RCA may also be viewed as an extension of the second diagonal branch or as a limb of the first septal perforator [25–27]. A report by Kaul et al. [28] identified that three different anomalous arteries originating from the mid LAD corresponded with the district of RCA. Cases of anomalous RCA from the LAD have only been rarely reported in the literature. We were able to find just under 30 cases related to this specific anomaly in PubMed. Some of these patients are delineated in Table 3. In the majority of the cases published, anomalous RCA stems from the proximal or mid segment of the LAD and usually courses anterior to the PA to reach the right AV groove or in between the great vessels, and rarely crosses posterior to the aorta (Figs. 4–6) [1–32, 52, 53].

The distribution of an anomalous RCA typically corresponds to the region supplied by the RCA that derives from the normal right aortic sinus, except for the case of an anomalous RCA arising from the LAD with a coexisting proximal RCA. In such a case, while the area of proximal RCA is served by a separate branch originating in the normal right

Table 1. Incidence of coronary artery anomalies.

Authors [reference]	Total number of patients	Number of anomalies	Angiographic incidence (%)
Yamanaka and Hobbs [1]	126.595	1.686	1.3
Engel et al. [3]	4.250	51	1.2
Chaitman et al. [4]	3.750	31	0.83
Kimbiris et al. [5]	7.000	45	0.64
Donaldson et al. [6]	9.153	82	0.9
Hobbs et al. [7]	38.703	601	1.55
Wilkins et al. [8]	10.661	83	0.78
Aydinlar et al. [9]	12.059	100	0.8
Topaz et al. [11]	13.010	80	0.61
Angelini et al. [12]	1.950	110	5.64

Table 2. Isolated coronary anomaly (Modified Lipton classification).

	Number	Incidence (%)	Anomalies (%)
BENIGN			
Separate origin of LAD and CX in LSV	513	0.41	30.4
CX from RSV or RCA	467	0.37	27.7
Coronary artery from PSV			
1. LMT from PSV	1	0.0008	0.06
2. RCA from PSV	4	0.003	0.24
Anomalous origin from ascending aorta			
1. LMT from aorta	16	0.013	0.95
2. RCA from aorta	188	0.15	11.2
Absent LCX (superdominant RCA)	4	0.003	0.24
Intercoronary communication	3	0.002	0.18
Small coronary artery fistulae	163	0.12	9.7
Total	1,359	1.07	80.6
POTENTIALLY SERIOUS			
Coronary artery from PA			
1. LMT from PA	10	0.008	0.59
2. LAD from PA	1	0.0008	0.06
3. RCA from PA	2	0.002	0.12
Coronary origin from opposite aortic sinus			
1. LMT from RSV	22	0.017	1.3
2. LAD from RSV	38	0.03	2.3
3. RCA from LSV	136	0.107	8.1
Single coronary artery			
1. R-I	1	0.0008	0.06
2. R-II	19	0.015	1.1
3. R-III	5	0.004	0.3
4. L-I	20	0.016	1.2
5. L-II	11	0.009	0.65
Multiple or large sized fistulae	62	0.05	3.7
Total	327	0.26	19.4

LAD — left anterior descending; CX — circumflex; RCA — right coronary artery; PA — pulmonary artery; LMT — left main trunk; LSV — left sinus of Valsalva; RSV — right sinus of Valsalva; PSV — posterior sinus of Valsalva; R — right; L — left

Table 3. Overview of published reports defining patients with anomalous right coronary artery originating from the left coronary system.

Author [reference]	Age	Sex	Symptom	ECG	Origin of RCA	Course of RCA	CAD	Treatment
Hughes [13]	77	M	Exertional angina	Posterior infarction pattern	Prox LAD	NA	LAD 50%, CX 100%, anomalous RCA 70%	Medical
Rath and Battler [14]	77	M	Exertional fatigue	Normal	Mid LAD	Anterior to PA	Non-critical	Medical
Akcay et al. [15]	35	M	Angina	ST-T wave changes	Prox LAD	NA	No	Medical
Teragawa et al. [16]	88	F	Hoarseness	NA	Prox LAD	Anterior to PA	No	Medical
Jammula et al. [17]	45	F	Exertional angina	Normal	Mid LAD	NA	Non-critical	Medical
Bayram et al. [20]	51	M	Angina	Normal	Mid LAD	Anterior to PA	NA	Medical
Amasyali et al. [25]	62	M	Angina	Normal	LAD S1	Intraseptally	Anomalous RCA	Medical
Meyers et al. [26]	50	F	Angina	Normal	LAD S1	Intraseptally	No	Medical
Iyisoy et al. [29]	53	M	Angina	Normal	Mid LAD	Posterior to Ao	No	Unknown
Wann and Schuchard [30]	49	M	Epigastric pain	NA	LCC	Between the great arteries	No	Medical
Kamran and Bogal [31]	39	M	Symptoms related to endocarditis	NA	Mid LAD	Anterior to PA	No	Medical
Saravanan et al. [34]	59	F	Angina	Normal	Mid LAD	Anterior to PA	No	Medical
Erdogan et al. [35]	44	F	Angina	Normal	Mid LAD	Anterior to PA	CX	Medical
Hsueh et al. [27]	72	F	Angina	ST-T wave changes	Mid LAD	NA	LAD 95%	PCI
Calalbro et al. [36]	53	M	Angina	Normal	Mid LAD	NA	LAD	PCI
Takano et al. [39]	35	M	Angina	ST-T wave changes	Mid LAD	Anterior to PA	LAD severe	PCI
Kaul and Javangula [28]	57	M	Unstable angina	NA	Three different branch from mid LAD	Anterior	LAD and CX	Surgery (CABG)
Smith [32]	66	F	Lethargy, slurring of speech	NA	Prox LAD	Anterior to PA	Non-critical	Death due to non-cardiac causes
Izumiyama et al. [42]	57	M	Angina	Infarction pattern	Prox LAD	Anterior to PA	LAD	Surgery (CABG)
Izumiyama et al. [42]	52	M	Angina	Normal	Prox LAD	Anterior to PA	Anomalous RCA	Surgery (CABG)
Simkoff et al. [43]	56	M	Angina	Infarction pattern	Prox LAD	NA	LAD 70% RCA diffuse	Surgery (CABG)
Goena et al. [52]	31	M	Exertional angina	Normal	LCC	Between the great arteries	No	Surgery (reimplantation)
Tsang et al. [53]	45	F	Exertional angina	Normal	LCC	Between the great arteries	No	Surgery (ostio-plasty, CABG)

M — male; F — female; RCA — right coronary artery; CAD — coronary artery disease; LAD — left anterior descending artery; S1 — septal 1; CX — circumflex artery; Ao — aorta; PA — pulmonary artery; LCC — left coronary cusp; PCI — percutaneous coronary intervention; CABG — coronary artery bypass graft; Prox — proximal; NA — not available

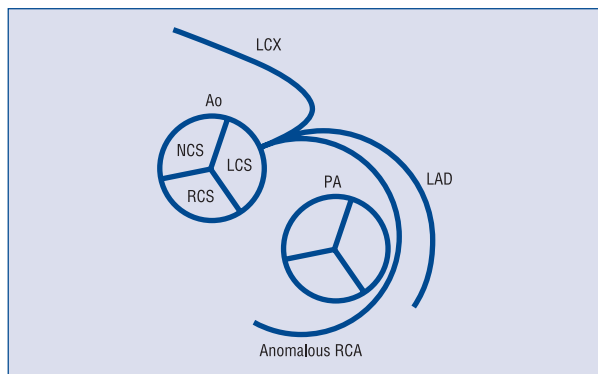


Figure 4. An anomalous right coronary artery (RCA) arising from the proximal portion of the left anterior descending artery (LAD) passes anterior to the pulmonary artery (PA) before reaching the right atrioventricular groove; LCX — left circumflex artery; Ao — aorta; LCS — left coronary sinus; RCS — right coronary sinus; NCS — non coronary sinus.

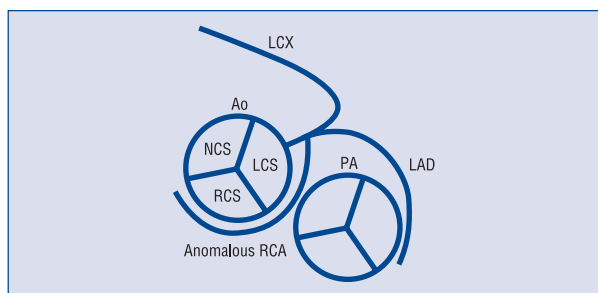


Figure 5. An anomalous right coronary artery (RCA) arising from the proximal portion of the left anterior descending artery (LAD) passes between the aorta (Ao) and pulmonary artery (PA) before reaching the right atrioventricular groove; LCX — left circumflex artery; LCS — left coronary sinus; RCS — right coronary sinus; NCS — non coronary sinus.

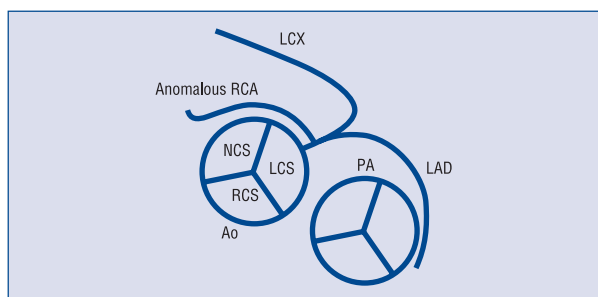


Figure 6. An anomalous right coronary artery (RCA) arising from the proximal portion of the left anterior descending artery (LAD) passes posterior to the Ao before reaching the atrioventricular groove; LCX — left circumflex artery; Ao — aorta; PA — pulmonary artery; LCS — left coronary sinus; RCS — right coronary sinus; NCS — non coronary sinus.

Table 4. Congenital cardiovascular defects in patients with single coronary artery (including anomalous right coronary artery from left coronary system).

Transposition of the great vessels
Coronary arteriovenous fistula
Bicuspid aortic valve
Tetralogy of Fallot
Origin from the pulmonary artery
Truncus arteriosus
Ventricular septal defect
Patent ductus arteriosus
Patent foramen ovale

aortic trunk, an anomalous artery from the LAD serves the distal RCA region [31]. The RCA originating from the LAD is an extremely rare variation of isolated single coronary artery (SCA), which is a very rare congenital anomaly appearing in approximately 0.024–0.066% of the general population undergoing coronary angiography (Table 2) [1–21, 25–29]. In these cases, one coronary artery stems from a single coronary ostium from the aortic trunk that nourishes the entire myocardium. Several cases have been reported in the literature. It is well known that SCA is commonly associated with other congenital cardiovascular anomalies such as transposition of the great vessels, coronary arteriovenous fistula, bicuspid aortic valve, and tetralogy of Fallot. The commonest co-existing cardiac anomaly with SCA is transposition of the great vessels (Table 4). The great majority of cases of SCA with anomalous RCA from the LAD are less frequently associated with other congenital cardiovascular defects [1–21, 25–29, 32–34].

Classification

Angiographic identification of anomalous coronary arteries is crucial for the appropriate diagnosis and management of patients. Hence, attempts at classifications have been made by several authors [1, 2, 4–11, 32]. For example, Smith defined three different types of SCA. Yamanaka and Hobbs in 1990 further modified the classification previously described by Lipton et al. in 1979 [2]. Based on the modified Lipton classification, cases of anomalous RCA originating from the LAD correspond to an LII anomaly. However, anomalous RCA stemming from the mid LAD cannot be assigned an actual location according to these classifications. This is because

group II anomalies have been only designed for “those arising from the proximal part of the normal right or left coronary artery”, and it has not been precisely defined for a coronary artery anomaly that derives from the mid-section of the LAD. For this reason, the real number of cases of RCA stemming from the mid LAD may have been misreported.

Clinical importance

There is no consensus as to the clinical significance of coronary anomalies. The commonest clinically important coronary anomaly is a coronary artery that generates from the opposite aortic trunk, i.e. the left coronary system from the right aortic trunk or the right coronary system from the left aortic trunk. The prognosis of anomalous RCA from the LAD is usually benign, and does not interfere with coronary perfusion. However, if an abnormal coronary artery crosses between the PA and the aorta, myocardial ischemia and sudden death may occur [1–12, 23, 30, 37]. The clinical relevance of this coronary anomaly may be due to underlying coronary atherosclerosis. It has been proposed that abnormal origin and course of anomalous coronary arteries could make them more prone to atherosclerosis [36]. Coronary atherosclerosis or stenosis requiring medical, percutaneous or surgical revascularization has been observed in about 40% of reported cases [13, 14, 19, 21, 25, 27, 28, 36–47]. In the minority of patients with CCAs (nearly 15%), myocardial ischemia can develop even in the absence of atherosclerosis (Table 5).

Several potential mechanisms have been proposed to explain myocardial ischemia and sudden death in patients with CAAs: i) spasm of the anomalous coronary artery, possibly as a result of endothelial injury or ischemia caused by its long distance of traveling; ii) the acute angle of take off of the anomalous vessel; iii) slit-like orifice; iv) intramural course of the anomalous vessel; and v) compression of the anomalous artery between the pulmonary and aortic trunks, particularly during or immediately after exercise, which leads to expansion of the aortic root and pulmonary trunk, creating external coronary artery expression and possibly increasing the pre-existing angulations of the coronary artery take off, with a reduction in the luminal diameter in the proximal portion of the anomalous coronary artery. The clinical significance and risk of a coronary anomaly usually depend on the place and course of the wrong coronary artery origin, and the degree and localization of the culprit stenotic or atherosclerotic lesion [1–12, 23, 24, 37, 39–46].

Table 5. Non-atherosclerotic causes of myocardial ischemia in coronary anomaly.

Coronary vasospasm
Acute angle take off
Slit-like orifice
Intramural course
Compression by the great vessels

Clinical symptoms

The clinical presentation of a patient with a coronary anomaly can include chest pain, dyspnea, palpitations, syncope, sudden death, ventricular fibrillation, and myocardial infarction, especially following exercise. Yet coronary anomalies may also be asymptomatic. Taylor et al. [37], in their study of 52 patients with anomalous origin of the RCA, noted that 25% had died suddenly and in most cases asymptotically. CAAs may give rise to symptoms of ventricular arrhythmias in young patients who have no overt signs or symptoms of ischemia [46]. The delay in diagnosis may be fatal in patients with clinically silent coronary anomaly. Therefore, early identification of patients with a coronary anomaly is crucial as they can be saved by medical, percutaneous intervention and/or surgical therapy.

Diagnostic approach

The diagnosis of these anomalies may not be exactly determined by defects observed by non-invasive tests such as electrocardiography, echocardiography, cardiovascular stress testing and nuclear medicine. So far, the main diagnostic tool for the determination of coronary vessel anomalies has been selective coronary angiography. Although coronary angiography is an effective and important diagnostic method, it has some disadvantages owing to its invasive nature. Due to developments in technology, new non-invasive methods such as coronary computed tomography angiography (CTA) and cardiac magnetic resonance imaging (MRI) play an important clinical role in determining coronary anomalies. Cardiac MRI may be superior to conventional angiography, especially in patients with congenital defects and isolated coronary anomalies. The most important feature of cardiac MRI is that it does not involve contrast agents and radiation. However, because of the low spatial resolution, this technique is currently less helpful in evaluating the distal coronary system [47, 48]. In contrast, although it has some limitations associated with the

administration of ionizing radiation and potentially allergenic or nephrotoxic agents, coronary CTA is a very good diagnostic tool in delineating coronary anomalies, because it has high spatial resolution and rapid acquisition. Additionally, with the use of electrocardiographic gating, coronary CTA provides excellent high-quality images of the coronary arteries, including their origin, course and termination. Thus, this technique that allows for evaluating the comprehensive anatomy of coronary arteries could also be helpful in detecting future therapeutic methods [20, 30, 49, 50]. In one reported case, a malignant right coronary anomaly coursing between the two great arteries, which could not be seen by conventional coronary angiography, was demonstrated by multi-slice coronary CTA [51].

Treatment options

Treatment for a coronary anomaly may be medical, percutaneous and/or surgical. Some difficulties may be encountered such as frequent catheter exchanges before finding the best-fitting catheter and guidewire, giving rise to increased fluoroscopic time and a greater amount of contrast agent used during coronary angiography and/or percutaneous coronary intervention (PCI) by reason of different anatomical structures in these patients. PCI for an anomalous RCA arising from the left coronary system has been reported by a variety of authors [21, 27, 36, 39–41]. Cardiovascular surgery is of vital importance in the therapy of a coronary anomaly of a patient who cannot be effectively treated by PCI.

Proposed options for those who need surgery include ostioplasty, bypass grafting of the RCA, and translocation of the RCA to the aorta (Table 6) [28, 42–46, 52, 53]. Recently, Gulati et al. [54] reported that a PA translocation procedure could be undertaken in patients with a single coronary artery arising from the opposite coronary ostium and passing between the great arteries in the absence of other factors associated with coronary insufficiency, such as fixed obstructive coronary lesions or slit-like ostium. However, the long-term benefits of such therapies have not yet been confirmed.

In conclusion, anomalous RCA usually originates from the proximal or mid-portion of LAD, and crosses anterior to PA before reaching the right AV groove. Current classifications may have led to a misunderstanding of the true scale of this specific anomaly. Approximately 15% of patients may in fact have myocardial ischemia caused by the abnormal anatomy of the coronary artery. In patients with a coronary vessel anomaly, an angiographic study

Table 6. Recommended surgical therapy in an anomalous right coronary artery (RCA) from the left coronary system.

Ostioplasty
Bypass grafting of the RCA
Reimplantation of the RCA to the aorta
Pulmonary artery translocation

such as conventional and coronary CT should be performed, and the management strategy of these patients may vary, based on clinical presentation, anatomical details and additional findings.

Conflict of interest: none declared

References

1. Yamanaka O, Hobbs RE. Coronary artery anomalies in 126,595 patients undergoing coronary arteriography. *Cathet Cardiovasc Diagn*, 1990; 21: 28–40.
2. Lipton MJ, Barry WH, Obrez I, Silverman JF, Wexler L. Isolated single coronary artery: Diagnosis, angiographic classification, and clinical significance. *Radiology*, 1979; 130: 39–47.
3. Engel HJ, Torres C, Page HL Jr. Major variations in anatomical origin of the coronary arteries: Angiographic observations in 4,250 patients without associated congenital heart disease. *Cathet Cardiovasc Diagn*, 1975; 1: 157–169.
4. Chaitman BR, Lesperance J, Saltiel J, Bourassa MG. Clinical, angiographic, and hemodynamic findings in patients with anomalous origin of the coronary arteries. *Circulation*, 1976; 53: 122–131.
5. Kimbris D, Iskandrian AS, Segal BL, Bemis CE. Anomalous aortic origin of coronary arteries. *Circulation*, 1978; 58: 606–615.
6. Donaldson RM, Raphael M, Rodley-Smith R et al. Angiographic identification of primary coronary anomalies causing impaired myocardial perfusion. *Cathet Cardiovasc Diagn*, 1983; 9: 237–249.
7. Hobbs RE, Millit HD, Raghavan PV, Moodie DS, Sheldon WC. Congenital coronary anomalies: Clinical and therapeutic implications. In: Vidt D ed. *Cardiovascular therapy*. Davis, Philadelphia, FA 1982: 43–58.
8. Wilkins CE, Betancourt B, Mathur VS et al. Coronary artery anomalies: A review of more than 10,000 patients from the Clayton Cardiovascular Laboratories. *Texas Heart Institute J*, 1988; 15: 166–173.
9. Aydinlar A, Cicek D, Senturk T et al. Primary congenital anomalies of the coronary arteries: A coronary arteriographic study in western Turkey. *Int Heart J*, 2005; 46: 97–103.
10. Shirani J, Roberts WC. Solitary coronary ostium in the aorta in the absence of other major congenital cardiovascular anomalies. *J Am Coll Cardiol*, 1993; 21: 137–143.
11. Topaz O, Demarchena R, Perin E, Sommer LS, Mallon SM, Chahine RA. Anomalous coronary arteries: Angiographic findings in 80 patients. *Int J Cardiol*, 1992; 34: 129–138.
12. Angelini P, Villason S, Chan AV, Diez JG. Normal and anomalous coronary arteries in humans. In: Angelini P ed. *Coronary artery anomalies: A comprehensive approach*. Lippincott Williams & Wilkins, Philadelphia 1999: 27–150.

13. Hughes MM. Anomalous origin of the right coronary artery from the left anterior descending coronary artery. *Cathet Cardiovasc Diagn*, 1997; 42: 308–309.
14. Rath S, Battler A. Anomalous origin of the right coronary artery from the left anterior descending coronary artery. *Cathet Cardiovasc Diagn*, 1998; 44: 328–329.
15. Akcay A, Tuncer C, Batyraliev T et al. Isolated single coronary artery: A series of ten cases. *Circ J*, 2008; 72: 1254–1258.
16. Teragawa H, Okada K, Sueda T. Anomalous origin of the right coronary artery from the left anterior descending coronary artery. *Heart*, 2004; 90: 1492.
17. Jammula P, Gupta R, Uretsky BF. Anomalous origin of the right coronary artery from the left anterior descending artery. *Heart*, 2005; 91: e30.
18. Goldstein PR, Pittman DE, Gay TC, Brandt CS. Anomalous origin of the right coronary artery from the ascending aorta: Case history. *Angiology*, 1990; 41: 164–166.
19. Husaini SN, Beaver WL, Wilson IJ, Lach RD. Anomalous right coronary artery originating from left mainstem. *Cathet Cardiovasc Diagn*, 1983; 9: 407–409.
20. Bayram E, Kocaturk H, Kantarci M, Fil F, Colak MC. Anomalous origin of the right coronary artery arising from the left anterior descending artery in a case with single coronary artery anomaly: Multi-detector computer tomography imaging. *Anad Kardiyol Derg*, 2008; 8: 385–386.
21. Caliskan M, Ciftci O, Gulu H, Alpaslan M. Anomalous right coronary artery from the left sinus of Valsalva presenting a challenge for percutaneous coronary intervention. *Arch Turk Soc Cardiol*, 2009; 37: 44–47.
22. Baskurt M, Yildiz A, Caglar IM et al. Right coronary artery arising from the pulmonary trunk. *Thorac Cardiovasc Surg*, 2009; 57: 424–426.
23. Isner JM, Shen EM, Martin ET, Fortin RV. Sudden unexpected death as a result of anomalous origin of the right coronary artery from the left sinus of Valsalva. *Am J Med*, 1984; 76: 155–158.
24. Roberts WC, Siegel RC, Zipes DP. Origin of the right coronary artery from the left sinus of Valsalva and its functional consequence: Analysis of 10 necropsy patients. *Am J Cardiol*, 1982; 49: 863–868.
25. Amasyali B, Kursaklioglu H, Kose S et al. Single coronary artery with anomalous origin of the right coronary artery from the left anterior descending artery with a unique proximal course. *Jpn Heart J*, 2004; 45: 521–525.
26. Meyers DG, McManus BM, McCall D, Walsh RA, Quaipe MA. Single coronary artery with the right coronary artery arising from the first septal perforator. *Cathet Cardiovasc Diagn*, 1984; 10: 479–484.
27. Hsueh SK, Youssef AA, Fang CY. Percutaneous coronary intervention of a stenotic left anterior descending artery with anomalous origin of right coronary artery. *Chang Gung Med J*, 2009; 32: 574–578.
28. Kaul P, Javangula K. Single left coronary artery with separate origins of proximal and distal right coronary arteries from left anterior descending and circumflex arteries: A previously undescribed coronary circulation. *J Cardiothorac Surg*, 2007; 2: 20.
29. Iyisoy A, Kursaklioglu H, Barcin C, Barindik N, Kose S, Demirtas E. Single coronary artery with anomalous origin of the right coronary artery as a branch from the left anterior descending artery: A very rare coronary anomaly. *Heart Vessels*, 2002; 16: 161–163.
30. Wann S, Schuchard G. Anomalous origin of the right coronary artery. *N Engl J Med*, 2006; 355: e8.
31. Kamran M, Bogal M. Anomalous right coronary artery originating from the left anterior descending artery. *J Invasive Cardiol*, 2006; 18: 221–222.
32. Smith JC. Review of single coronary artery with report of 2 cases. *Circulation*, 1950; 1: 1168–1175.
33. Ogden JA, Goodyer AVN. Patterns of distribution of the single coronary artery. *Yale J Biol Med*, 1970; 43: 11–21.
34. Saravanan P, Mennim P, Hancock JE. Anomalous origin of right coronary artery from the mid left anterior descending artery. *Heart*, 2006; 92: 1212.
35. Erdogan O, Buyuklu M, Aktoz M. Anomalous origin of the right coronary artery from the left anterior descending artery in a patient with single left coronary artery: A rare coronary artery anomaly and review of the literature. *Int J Cardiol*, 2008; 127: 280–283.
36. Calabro P, Bianchi R, Palmieri R, Sordelli C, Bigazzi MC, Calabro R. Evidence of right coronary from mid-left anterior descending coronary: A rare case coronary anomalous origin. *Eur Hear J*, 2009; 30: 565.
37. Taylor AJ, Rogan KM, Virmani R. Sudden cardiac death associated with isolated congenital coronary artery anomalies. *J Am Coll Cardiol*, 1992; 20: 640–647.
38. Samarendra P, Kumari S, Hafeez M, Vasavada BC, Sacchi TJ. Anomalous circumflex coronary artery: Benign or predisposed to selective atherosclerosis. *Angiology*, 2001; 52: 521–526.
39. Takano M, Seimiya K, Yokoyama S et al. Unique single coronary artery with acute myocardial infarction: Observation of the culprit lesion by intravascular ultrasound and coronary angiography. *Jpn Heart J*, 2003; 44: 271–276.
40. Kafkas N, Triantafyllou K, Babalis D. An isolated single L-I type coronary artery with severe LAD lesions treated by transradial PCI. *J Invasive Cardiol*, 2011; 23: E216–E218.
41. Rudan D, Todorovic N, Starcevic B, Raqaz M, Bergovec M. Percutaneous coronary intervention of an anomalous right coronary artery originating from the left coronary artery. *Wien Klin Wochenschr*, 2010; 122: 508–510.
42. Izumiya O, Yamashita A, Sugimoto S, Baba M, Hasegawa T. Coronary artery bypass grafting in two patients with single coronary artery. *Kyobu Geka*, 1999; 52: 143–147.
43. Simkoff WI, Murphy ES, DeMots H, Khonsari S, Abbruzzese P. Anomalous origin of the right coronary artery from the left anterior descending: Angiographic diagnosis in a patient with coronary artery disease. *Cathet Cardiovasc Diagn*, 1982; 8: 49–53.
44. Rinaldi RG, Carballido J, Giles R, Del Toro E, Porro R. Right coronary artery with anomalous origin and slit ostium. *Ann Thorac Surg*, 1994; 58: 829–832.
45. Shah AS, Milano CA, Lucke JP. Anomalous origin of the right coronary artery from the left coronary sinus: Case report and review of surgical treatments. *Cardiovasc Surg*, 2000; 8: 284–286.
46. Corrado D, Thiene G, Cocco P, Frescura C. Nonatherosclerotic coronary artery disease and sudden death in the young. *Br Heart J*, 1992; 68: 601–607.
47. McConnell MV, Stuber M, Maning WJ. Clinical role of coronary magnetic resonance angiography in the diagnosis of anomalous coronary arteries. *J Cardiovasc Magn Reson*, 2000; 2: 217–224.
48. ACCF/ACR/AHA/NASCI/SCMR 2010 expert consensus document on cardiovascular magnetic resonance: A report of the American College of Cardiology Foundation Task Force on Expert Consensus Documents. *Circulation*, 2010; 121: 2462–2508.
49. Zeina AR, Blinder J, Sharif D, Rosenschein U, Barneir E. Congenital coronary artery anomalies in adults: Non-invasive assessment with multidetector CT. *Br J Radiol*, 2009; 82: 254–261.
50. Srinivasan KG, Gaikwad A, Kannan BR, Ritesh K, Ushanandini KP. Congenital coronary artery anomalies: Diagnosis with 64 slice multidetector row computed tomography coronary angiography. A single-centre study. *J Med Imaging Radiat Oncol*, 2008; 52:148–154.
51. Dirksen MS, Bax JJ, Blom NA et al. Detection of malignant right coronary artery anomaly by multi-slice CT coronary angiography. *Eur Radiol*, 2002; 12: S177–S180.
52. Goena C, Ibarra A, Compana M et al. High risk anomalous origin of the right coronary artery. *Rev Esp Cardiol*, 2011 [Epub ahead of print].
53. Tsang GM, Pagano D, Beattie JM, Bonser RS. Anomalous aortic origin of the right coronary artery. An unusual cause of angina pectoris and its surgical correction. *Eur J Cardiothorac Surg*, 1995; 9: 715–716.
54. Gulati R, Reddy VM, Culbertson C et al. Surgical management of coronary artery arising from the wrong coronary sinus, using standard and novel approaches. *J Thorac Cardiovasc Surg*, 2007; 134: 1171–1178.