

Anterior Roux-en-Y Pancreatico-jejunostomy for Pancreatic Trauma

P. S. Aravinda, Sudipta Saha, Manoj Andley, O. P. Pathania, Ajay Kumar

Department of Surgery, Lady Hardinge Medical College,
New Delhi, India

INTRODUCTION

Pancreatic injuries can be caused by penetrating or blunt trauma to the abdomen. They occur in approximately 5% of all abdominal injuries.^[1] Pancreatic injuries are usually associated with injuries of other intra-abdominal organs, and isolated pancreatic rupture is quite rare.^[2] Management may vary from non operative management, including image-guided drainage, to complex procedures like distal pancreatectomy and pancreatico-jejunostomy.^[3] We are reporting two cases of isolated pancreatic injury with disruption of the pancreatic duct but preserved posterior surface at the site of laceration. These patients were managed by anastomosing Roux loop of jejunum with the lacerated site of the pancreas.

CASE REPORTS

Case 1

A 35-year-old male presented in the emergency department with the complaint of pain over epigastrium following direct compression injury of the upper abdomen with a concrete tile 5 days ago. Pain was continuous, severe, and radiating to back. On examination, the patient had tachycardia (pulse 102/min), along with tenderness and guarding over the epigastrium. Sonography of abdomen revealed free fluid in the peritoneal cavity. The body and tail of the pancreas had shaggy margins and there was peripancreatic collection.

ABSTRACT

Isolated pancreatic laceration is a rare injury. The typical mechanism by which it occurs is overstretching of the pancreas across the vertebral column during blunt abdominal trauma. The management depends on the location and extent of the injury. Disruption of the pancreatic duct usually requires operative treatment. Operative options for pancreatic laceration at the neck include distal pancreatectomy or suturing of the cephalic remnant and Roux-en-Y pancreatico-jejunostomy on the left remnant. We are reporting two cases of isolated pancreatic injury with disruption of the pancreatic duct but preserved posterior surface of the pancreas. These patients were managed by performing anterior Roux-en-Y pancreatico-jejunostomy at the lacerated area. Both the patients had successful outcome with removal of drains by 6th postoperative day. Anterior Roux-en-Y pancreatico-jejunostomy in this particular scenario is easy, less time consuming, and has the advantage of preserving the pancreas and the spleen.

Key words: Pancreatic trauma, Roux-en-Y pancreatico-jejunostomy, anterior pancreatico-jejunostomy

Contrast-enhanced computed tomography (CECT) scan of the abdomen showed laceration of pancreas at neck with injury of the pancreatic duct [Figure 1]. On exploratory laparotomy, the pancreas was found to be lacerated at the level of neck with disruption of the pancreatic duct. However, the posterior surface of the pancreas was preserved at the site of laceration [Figure 2]. An anterior Roux-en-Y pancreatico-jejunostomy was done at the lacerated site of the pancreas [Figure 3]. In this, the lacerated site of the pancreas was anastomosed to the lateral opening made in a Roux loop of the jejunum in two layers. Postoperatively, the drain output gradually reduced to minimum by day 4 and the patient was discharged on day 6. Patient is healthy at the last follow-up 10 months after the operation.

Case 2

A 35-year-old male presented with a history of fall from height of approximately 15 feet. At the time of presentation, the patient was having tachycardia (pulse rate 108/min) and his BP was 130/80 mm Hg. Abdomen was distended and there were signs of peritonitis. Ultrasound of the abdomen showed free fluid in the abdomen. CECT abdomen showed laceration at the neck of pancreas with

Access this article online

Quick Response Code:



Website:

www.jstcr.org

DOI:

10.4103/2006-8808.135147

Address for correspondence: Dr. P. S. Aravinda,
63, Defence Enclave, Vikas Marg, New Delhi - 110 092, India.
E-mail: psarvind07@gmail.com

surrounding hematoma and disruption of the pancreatic duct [Figure 4]. On exploratory laparotomy, laceration of 1.5 cm × 1 cm × 1.5 cm was found at the neck of the pancreas with disrupted pancreatic duct but intact posterior

surface of the pancreas at the lacerated site [Figure 5]. Anterior Roux-en-Y pancreatico-jejunostomy was done with suturing of edges of the laceration of pancreas to the side of Roux-en-Y loop of the jejunum [Figure 6].

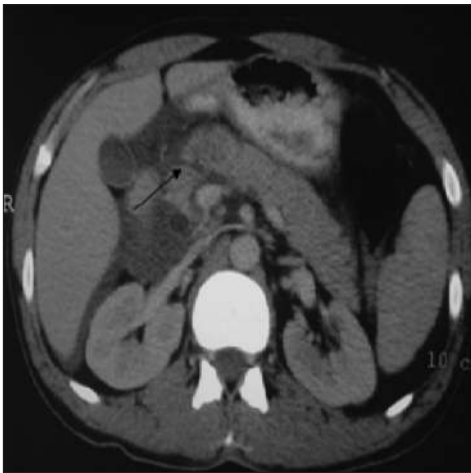

Figure 1: CECT abdomen showing laceration at the neck of the pancreas (arrow)

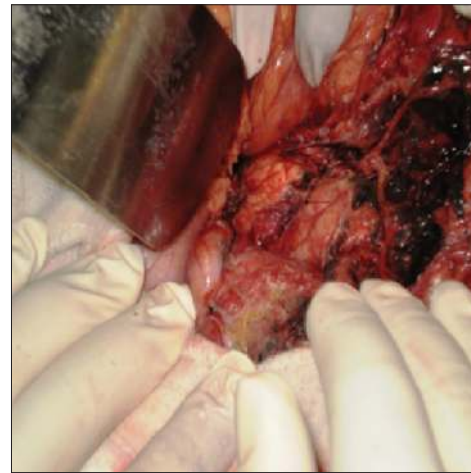


Figure 2: Intraoperative photograph showing laceration of the pancreas (arrow)

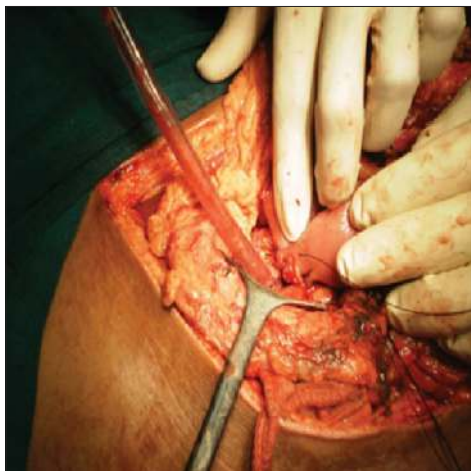


Figure 3: Anterior pancreatico-jejunostomy being done

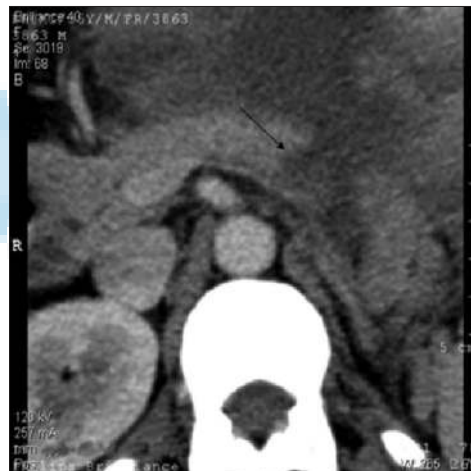

Figure 4: CECT abdomen showing laceration of the pancreas (arrow)

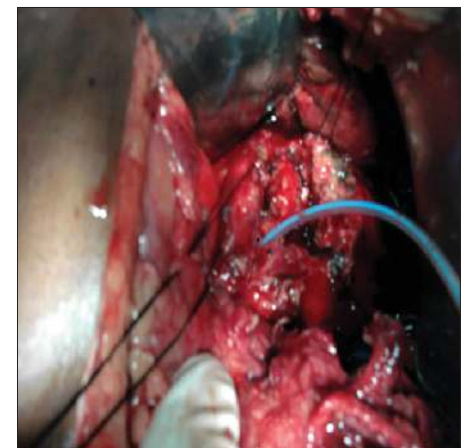

Figure 5: Intraoperative photograph showing lacerated pancreas. Pancreatic duct is shown cannulated with feeding tube

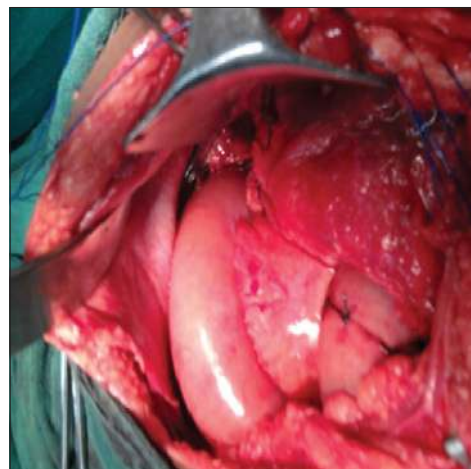


Figure 6: Anterior pancreatico-jejunostomy done at the lacerated site

The postoperative course was uneventful. Drain output decreased to minimum 6 days after the operation and the patient was discharged on the 7th day. The patient is normal at 1 year of follow-up.

DISCUSSION

Pancreatic injury most often results because of blunt trauma to the epigastrium causing the neck of the pancreas to be crushed against the vertebra. Pancreatic injury is usually associated with injuries to the other abdominal organs as well.^[2] Integrity of the pancreatic duct is one of the main factors which decide the management option in pancreatic injury. Missed pancreatic duct injury may result in complications such as pseudocysts, fistulas, pancreatitis, sepsis, and secondary hemorrhage. Some of these complications can cause significant morbidity and can even be life threatening.^[4] In the absence of injury to the pancreatic duct, simple debridement of devitalized pancreas and drainage is sufficient. However, injury of the pancreatic duct requires definite operative procedures depending upon the location of the injury. Distal pancreatectomy along with splenectomy is usually done for pancreatic duct injury at the body, neck, and tail of the pancreas. Spleen preserving distal pancreatectomy is also an option which has the advantage of preservation of spleen, but it increases the operation time.^[4,5]

Drawbacks of distal pancreatectomy at the neck include loss of splenic function if splenectomy is done along with distal pancreatectomy and the possibility of endocrine dysfunction. Endocrine dysfunction has been reported in 8-10% of patients after distal pancreatectomy done for a variety of indications.^[6,7] It has also been reported in a small series of patients in whom distal pancreatectomy was done for trauma.^[8] For these reasons, distal pancreatico-jejunostomy is an option in pancreatic injuries at the neck with disruption of the duct, as it has the advantages of preserving the spleen and pancreas.^[9]

We have reported here two cases of pancreatic laceration with pancreatic duct injury, where posterior surface of the pancreas was intact. We propose anterior pancreatico-jejunostomy as a management option in

this type of pancreatic injuries. In this, the edges of the laceration are anastomosed to the opening made at the side of a Roux loop of jejunum. This repair has the advantage of preservation of pancreas and spleen, and further, the operative time is less as no mobilization of the pancreas is required. This procedure has been described previously in nine patients, and was found to be an appropriate procedure in patients in whom posterior pancreatic capsule was intact.^[10]

CONCLUSION

Pancreatic laceration with disruption of the duct and preserved posterior surface is rare. Our experience of these two cases shows that anterior pancreatico-jejunostomy is a feasible option for the management of this type of injury. We propose that if the surgeons come across such a type of pancreatic injury, anterior pancreatico-jejunostomy should be considered.

REFERENCES

1. Subramanian A, Dente CJ, Feliciano DV. The management of pancreatic trauma in the modern era. *Surg Clin N Am* 2007;87:1515-32.
2. Levine RA, Bank MA. Traumatic transection of the pancreas. Case of delayed presentation. *JOP* 2011;12:47-9.
3. Degiannis E, Glapa M, Loukogeorgakis SP, Smith MD. Management of pancreatic trauma. *Injury* 2008;39:21-9.
4. Krige JE, Beningfield SJ, Nicol AJ, Navsaria P. The management of complex pancreatic injuries. *S Afr J Surg* 2005;43:92-102.
5. El-Boghdady S, Al-Yousef Z, Al Bedah K. Pancreatic injury: An audit and a practical approach. *Ann R Coll Surg Engl* 2000;82:258-62.
6. Lillemo KD, Kaushal S, Cameron JL, Sohn TA, Pitt HA, Yeo CJ. Distal pancreatectomy: Indications and outcomes in 235 patients. *Ann Surg* 1999;229:693-8.
7. King J, Kazanjian K, Matsumoto J, Reber HA, Yeh MW, Hines OJ, *et al.* Distal pancreatectomy: Incidence of postoperative diabetes. *J Gastrointest Surg* 2008;12:1548-53.
8. Al-Ahmadi K, Ahmed N. Outcomes after pancreatic trauma: Experience at a single institution. *Can J Surg* 2008;5:118-24.
9. Bhat S, Azad TP, Kaur M. Pancreaticojejunostomy in proximal pancreatic transection: A viable option. *N Am J Med Sci* 2011;3:46-7.
10. Jones RC. Management of pancreatic trauma. *Ann Surg* 1978;187:555-64.

How to cite this article: Aravinda PS, Saha S, Andley M, Pathania OP, Kumar A. Anterior roux-en-Y Pancreatico-jejunostomy for pancreatic trauma. *J Surg Tech Case Report* 2014;6:26-8.

Source of Support: Nil, **Conflict of Interest:** None declared.