

Review

Anti-ulcer activity of *Swietenia mahagoni* leaf extract in ethanol-induced gastric mucosal damage in rats

Salmah Al-Radahe¹, Khaled Abdul-Aziz Ahmed^{2,3*}, Suzy Salama², Mahmood Ameen Abdulla², Zahra A. Amin², Saad Al-Jassabi¹ and Harita Hashim⁴

¹Institute of Biological Sciences, Faculty of Science, University of Malaya, 50603 Kuala Lumpur, Malaysia.

²Department of Molecular Medicine, Faculty of Medicine, University of Malaya, 50603 Kuala Lumpur, Malaysia.

³Department of Medical Sciences, Faculty of Dentistry, IBB University, P. O. Box 70627, Ibb, Yemen.

⁴Department of Biology, Faculty of Applied Science, University Teknologi MARA 40450 Shah Alam, Malaysia.

Accepted 13 April, 2011

Swietenia mahagoni (West Indian mahogany) has been reported to have medicinal uses, such as treatment for hypertension, cancer, amoebiasis, chest pains and intestinal parasitism. The present study was performed to evaluate, the acute toxicity and anti-ulcer activity of *S. mahagoni* ethanol leaf extract against ethanol-induced gastric ulcer. 24 rats included in this study were divided into 4 groups with 6 rats each group. Group 1 rats (ulcer control group) were pre-treated with vehicle (Carboxyl methyl cellulose). Group 2 (reference group) was orally pretreated with 20 mg/kg omeprazole. Group 3 and 4 (experimental groups) were orally pre-treated with *S. mahagoni* ethanol leaf extract at 250 and 500 mg/kg doses, respectively. After one hour later, all groups received absolute ethanol to generate gastric mucosal injury. After an additional hour, all the rats were sacrificed and the ulcer areas of the gastric walls were determined. Grossly, the ulcer control group exhibited severe mucosal injury, whereas pre-treatment with either omeprazole or plant extract resulted in significantly protection of gastric mucosal injury and increase in mucus production. Flattening of gastric mucosal folds was also observed in rats pretreated with *S. mahagoni* leaf extract. Histological studies of the gastric wall of ulcer control group revealed severe damage of gastric mucosa, along with edema and leucocytes infiltration of the submucosal layer compared to rats received either omeprazole or *S. mahagoni* leaf extract where there was marked gastric protection along with reduction or absence of edema and leucocytes infiltration of the submucosal layer. Acute toxicity study with a higher dose of plant extract at 5 g/kg did not reveal any toxicological signs in rats. In conclusions, the present findings suggest that *S. mahagoni* ethanol leaf extract exhibit an anti-ulcer activity against ethanol-induced gastric ulcer in experimental animals.

Key words: *Swietenia mahagoni* leaf extract, gastric ulcer, histology.

INTRODUCTION

Various parts of *Swietenia mahagoni* have been used as folk medicine for the treatment of hypertension, malaria, cancer, amoebiasis, chest pains, fever, anemia diarrhea, dysentery, depurative and intestinal parasitism (Nagalakshmi et al., 2001; Maiti et al., 2007). Other

studies have showed other medicinal values of *S. mahagoni* plant like antibacterial (Majid et al., 2004) and antioxidant activities (Sahgal et al., 2009a) as well as diabetes therapy (Li et al., 2005). The biologically active ingredients, tetranortriterpenoids and fatty acids, are

*Corresponding author. E-mail: khaaah@gmail.com.

considered to be responsible for these therapeutic effects (Bacsal et al., 1997).

Previous phytochemical investigations on *S. mahogani* have led to the isolation of more than 45 limonoids belonging to the structural types of andirobin, gendunin, mexicanolide, phragmalin, triterpens, tetranortriterpenes, and chlorogenic acid (Abdelgaleil et al., 2006; Chen et al., 2007). From *S. Mahogani*, eighteen tetranortriterpenoids were isolated (Kadota et al., 1990) and the presence of known fatty acids and terpenoids were reported (Saad et al., 2003). There are no data available regarding anti-ulcerogenic property of *S. mahogani* in rats.

Therefore, the present study was undertaken to evaluate the antiulcerogenic activity of *S. mahogani* ethanol leaf extract against ethanol-induced gastric mucosal damage in experimental rats.

MATERIALS AND METHODS

Omeprazole

Omeprazole, a proton pump inhibitor, has been widely used as an acid inhibitor agent for the treatment of disorders related to gastric acid secretion for about 15 years (Li et al., 2004). In this study, Omeprazole was used as the reference anti-ulcer drug, and was obtained from the University of Malaya Medical Centre (UMMC) Pharmacy. The drug was dissolved in carboxymethyl cellulose (CMC) and administered orally to the rats in concentrations of 20 mg/kg body weight (5 ml/kg) (Pedernera et al., 2006).

Plant material

S. mahogani leaves were obtained from Ethno Resources Company (Selangor Malaysia) and identified by comparison with the Voucher specimen deposited at the Herbarium of Rimba Ilmu, Institute of Biological Sciences, University of Malaya, Malaysia.

Preparation of plant extract

S. mahogani leaves were shade-dried for 7 to 10 days and were then powdered using electrical blender. 100 g of fine powder were soaked in 500 ml of 95% ethanol in conical flask for 3 days. After 3 days the mixture was filtered using a fine muslin cloth followed by paper filtration (Whatman No. 1) and distilled under reduced pressure in an Eyela rotary evaporator (Sigma-Aldrich, USA). The dry extract was then dissolved in CMC (0.25% w/v) and administered orally to rats in concentrations of 250 and 500 mg/kg body weight (5 ml/kg body weight) (De Pasquale et al., 1995).

Acute toxicity test

Experimental animals

Adult healthy male and female *Sprague Dawley* rats (6 to 8 weeks old) were obtained from the Animal House, Faculty of Medicine, University of Malaya, Kuala Lumpur. The rats weighed between 150 to 180 g. The animals were given standard pellets and tap water. The acute toxicity study was used to determine the safe dose for the plant extract. Thirty six *Sprague Dawley* rats (18 males and 18 females) were assigned equally into 3 groups.

The first group was labeled as vehicle (CMC, 0.25% w/v, 5 ml/kg) while the second and third groups of animals were pretreated with 2

and 5 g/kg of *S. mahogani* leaf extract, respectively. The animals were fasted overnight (food but not water) prior dosing. Food was withheld for a further 3 to 4 h after dosing. The animals were observed for 30 min and 2, 4, 8, 24 and 48 h after extract administration for the onset of clinical and/or toxicological symptoms. The animals were sacrificed on the 14th day and histological, hematological and serum biochemical parameters were determined following standard methods (Bergmeyer and Horder, 1980; Tietz et al., 1983).

Behavioral observation and mortality

Throughout the study period, all animals were observed for behavioral signs of toxicity, morbidity and mortality. Mortality checks were made twice daily and determination of behavioral signs was observed daily for all animals. Detailed observations of the individual animals were made weekly in comparison with the vehicle treated animals.

Observations included gross evaluations of the skin, any signs of respiration (dyspnea), salivation, exophthalmia, convulsion and any changes in locomotion such as whether the animals tend to stay quietly or actively moving in their cage.

Hematological and biochemistry analysis

The animals were fasted overnight prior to necropsy and blood was collected. Blood samples were drawn from jugular vein under diethyl ether anesthesia. Blood samples were collected into EDTA tubes for total and differential white blood cell (WBC) count. For serum biochemistry analysis, blood was collected into anticoagulant-free tubes.

Biochemical parameters include aspartate aminotransferase (AST), alanine aminotransferase (ALT), total protein, albumin, globulin, total bilirubin, conjugated bilirubin, alkaline phosphatase, gamma glutamyl transferase (GGT), urea, creatinine, anion gap and serum electrolytes (CO₂, Potassium, Sodium and Chloride). All samples were sent immediately to the Clinical Diagnostic Laboratory at University of Malaya Medical Centre for liver and renal function tests. The results were compared to that of the rats' respective control groups.

Gross necropsy and histopathology

At scheduled termination, all surviving animals were anesthetized by diethyl ether inhalation and quickly sacrificed by exsanguinations of jugular vein for blood sample collection. Gross postmortem examinations were performed on all terminated animals. Liver and kidney from each animal were routinely processed and embedded in paraffin. After sectioning and staining with Haematoxylin and Eosin (H and E) stain method, all slides were observed under microscope to observe for any pathological changes.

Anti-ulcer activity studies

Experimental animals

Sprague Dawley healthy adult male rats were obtained from the Experimental Animal House, Faculty of Medicine, University of Malaya. The animals were kept at room temperature in humidity rooms on a standard light/dark cycle (12 h light; 12 h dark cycle). The rats were divided randomly into 4 groups of 6 rats each. Each rat that weighted between 200 to 225 g was placed individually in separate cage (one rat per cage) with wide-mesh wire bottoms to prevent coprophagia during the experiment. The animals were maintained on standard pellet diet and tap water.

Gastric ulcer induction by ethanol and tissue sample collection

The rats were fasted for 48 h before the experiment (Garg et al., 1993), but were allowed free access drinking water up to 2 h before the experiment. Gastric ulcer in *Sprague Dawley* was induced by orogastric intubation of absolute Ethanol (5 ml/kg) according to the method described by De Pasquale et al. (1995). Ulcer control group was orally administered with vehicle (CMC, 0.25% w/v, 5 ml/kg). The reference group was received oral doses of 20 mg/kg Omeprazole in CMC (5 ml/kg) as positive controls.

Experimental groups (groups 3 and 4) were orally administered 250 and 500 mg/kg of plant extract dissolved in CMC solution (5 ml/kg), respectively. One hour after this pre-treatment; all groups of rats were gavaged with absolute ethanol (5 ml/kg) in order to induce gastric ulcers (Hollander et al., 1985). After one hour, the rats were sacrificed by cervical dislocation under overdose of diethyl ether anesthesia (Paiva et al., 1998). The stomachs were immediately excised and rapidly immersed in 10% buffered formalin solution.

Measurement of acid of gastric juice and mucus production

Each stomach was opened along the greater curvature. Samples of gastric contents were analyzed for hydrogen ion concentration by pH-meter titration with 0.1 N NaOH solutions using digital pH meter. The acid content was expressed as mEq/l based on the method of Tan et al. (2002). Gastric mucus production was measured in the rats that were subjected to absolute ethanol-induced gastric mucosal injury. The gastric mucosa of each rat was gently scraped using a glass slide and the mucus obtained was weighed using a precision electronic balance (Tan et al., 2002).

Gross gastric lesions evaluation

Any ulcers would be found in the gastric mucosa, appearing as elongated bands of hemorrhagic lesions parallel to the long axis of the stomach. Each gastric mucosa was thus examined for damage. The length (mm) and width (mm) of the ulcer on the gastric mucosa were measured by a planimeter ($10 \times 10 \text{ mm}^2 = \text{ulcer area}$) under dissecting microscope (1.8 x).

The area of each ulcer lesion was measured by counting the number of small squares, $2 \times 2 \text{ mm}$, covering the length and width of each ulcer band. The sum of the areas of all lesions for each stomach was applied in the calculation of the ulcer area (UA) where the sum of small squares $\times 4 \times 1.8 = \text{UA mm}^2$ as described by Kauffman and Grossman (1978) with slight modification. The inhibition percentage (I %) was calculated by the following formula as described by Njar et al. (1995):

$$(I \%) = [(UA_{\text{control}} - UA_{\text{treated}}) \div UA_{\text{control}}] \times 100.$$

Histological evaluation of gastric lesions

Specimens of the gastric walls from each rat were fixed in 10% buffered formalin and processed in a paraffin tissue processing machine. After embedding, sections of the stomach were made at a thickness of $5 \mu\text{m}$ and stained with Hematoxylin and Eosin for histological evaluation.

Ethics

The study was approved by the ethics Committee for animal experimentation, Faculty of Medicine, University of Malaya, Malaysia (Ethics No. PM 07/10/2009 MAA (a)(R)). Throughout the

experiments, all animals received human care according to the criteria outlined in the "Guide for the Care and Use of Laboratory Animals" prepared by the National Academy of Sciences and published by the National Institute of Health.

Statistical analysis

All values were expressed as mean \pm S.E.M. The statistical significance of differences between groups was assessed using one-way analysis of variance (ANOVA). The Mann-Whitney U test was used to compare the difference between two groups. A value of $p < 0.05$ was considered significant. Statistical analysis was performed using SPSS 11.5 for Windows software (SPSS Inc, Chicago, IL, USA).

RESULTS

Acute toxicity study

The animals received leaf extract of *S. mahagoni* at doses of 2 and 5 g/kg b.wt were kept under observation for 14 days. All the animals remain alive and did not manifest any significant visible of toxicity at these doses. There was no mortality observed in the previous-mentioned doses over a period of 2 weeks. Additionally, there were no abnormal signs, behavioral, macroscopic, or histological changes until the end of the experiment.

In hematological analysis, total white blood cells for all rats were counted and showed that there are no significant differences among all groups. Meanwhile, results of renal function tests (Table 1) and liver profile tests (Table 2) have revealed no significant difference between rats pretreated with *S. mahagoni* leaf extract groups as compared to their respective vehicle group.

Anti-ulcer activity

Gross evaluation of gastric lesions

The anti-ulcer activity of *S. mahagoni* extract in ethanol-induced gastric lesion model is reported in Table 3. Results showed that rats pre-treated with leaf extract of *S. mahagoni* before being given absolute alcohol had significantly reduced areas of gastric ulcer formation compared to rats pre-treated with only CMC (ulcer control group) (Figures 1 and 2).

Moreover, the leaf extract significantly suppressed the formation of the ulcers and it was interesting to note the flattening of gastric mucosal folds in rats pre-treated with *S. mahagoni* extract. It was also observed that protection of gastric mucosa was more prominent in rats pre-treated with 500 mg/kg plant extract (Table 3). Beside, ethanol-induced mucosal damage was significantly and dose dependently reduced in the size and severity by pretreatment of the animals with *S. mahagoni* leaf extract.

The significant inhibition of gastric ulcer in rats pre-treated

Table 1. Renal function tests of rats in acute toxicity study of *S. mahagoni* leaf extract.

Dose	Sodium (mmol/L)	Pottasium (mmol/L)	Chloride (mmol/L)	CO ₂ (mmol/L)	Anion gap (mmol/L)	Urea (mmol/L)	Creatinine (μmol/L)
Vehicle (CMC, 0.25% w/v)	137.17 ± 0.47	5.17 ± 0.2	103.02 ± 0.17	23.11 ± 0.86	18.17 ± 0.75	5.61 ± 0.44	50.33 ± 1.74
<i>S. mahagoni</i> extract (2 g/kg b.wt)	137.67 ± 0.42	5.32 ± 0.16	101.69 ± 1.23	20.84 ± 0.77	19.17 ± 1.56	4.86 ± 0.46	49.67 ± 0.84
<i>S. mahagoni</i> extract (5 g/kg b.wt)	138.01 ± 0.50	4.88 ± 0.17	102.83 ± 0.79	21.9 ± 0.88	17.76 ± 0.61	5.72 ± 0.38	48.74 ± 1.88

Values are expressed as mean ± S.E.M. There are no significant differences among all groups.

Table 2. Liver function tests of rats in acute toxicity study of *S. mahagoni* leaf extract.

Dose	Total protein (g/L)	Albumin (g/L)	Globulin (g/L)	TB (μmol/L)	CB (μmol/L)	AP (IU/L)	ALT (IU/L)	AST (IU/L)	GGT (IU/L)
Vehicle (CMC, 0.25% w/v)	71.2 ± 1.7	11.33 ± 0.71	59.86 ± 1.70	1.81 ± 0.17	0.86 ± 0.17	134.5 ± 17.9	53.05 ± 3.17	152.9 ± 8.3	4.87 ± 0.92
Plant extract (2 g/kg b.wt)	71.2 ± 0.5	10.87 ± 0.33	59.62 ± 0.34	2.07 ± 0.17	1.00 ± 0.00	133.7 ± 8.9	50.83 ± 1.37	152.7 ± 3.6	5.01 ± 1.21
Plant extract (5 g/kg b.wt)t)	71.8 ± 1.0	11.63 ± 0.6	60.00 ± 0.93	1.77 ± 0.22	1.00 ± 0.00	135.1 ± 6.9	52.65 ± 3.27	154.0 ± 11.3	5.13 ± 1.09

Values are expressed as mean ± S.E.M. There are no significant differences among all groups. TB: Total bilirubin; CB: Conjugated bilirubin; AP: Alkaline phosphatase; ALT: Alanine aminotransferase; AST: Aspartate aminotransferase; GGT: G-Glutamyl Transferase.

Table 3. Effect of leaf extract of *S. mahagoni* on the ulcer area pre-treated with different preparations.

Animal group	Pre-treatment (5 ml/kg dose)	Mucus production	pH of gastric content	Ulcer area (mm) ²	Inhibition (%)
1	CMC (Ulcer control)	0.34 ± 0.009 ^a	4.0 ± 0.09 ^a	920.00 ± 10.72 ^a	-
2	Omeprazole (20 mg/kg b.wt) (positive control)	0.57 ± 0.006 ^b	6.85 ± 0.15 ^b	205.00 ± 7.64 ^b	77.72
3	<i>S. mahagoni</i> leaf extract (250 mg/kg b.wt)	0.89 ± 0.08 ^c	7.0 ± 0.13 ^{b,c}	185.33 ± 6.77 ^b	79.86
4	<i>S. mahagoni</i> leaf extract (500 mg/kg b.wt)	1.05 ± 0.02 ^d	7.25 ± 0.07 ^c	45.50 ± 5.16 ^c	95.05

All values are expressed as mean ± S.E.M of six rats per group. Mean values with different superscripts are significantly different. The mean difference is significant at *P* value of <0.05.

with leaf extract of *S. mahagoni* was compared with Omeprazole (Figure 3).

Histological evaluation of gastric lesions

Histological observations of ethanol induced

gastric lesions in ulcer control group pre-treated with only CMC, showed comparatively extensive damage to the gastric mucosa, edema and leucocytes infiltration of the submucosal layer (Figure 4). Rats that received pre-treatment with the plant extract had comparatively better protection of the gastric mucosa as proven by

reduction in ulcer area, reduced or absence of submucosal edema and leucocytes infiltration (Figure 5). *S. mahagoni* leaf extract has been shown to exert the cytoprotective effects in a dose-dependent manner. Enhanced gastric ulcer healing in rats pre-treated with *S. mahagoni* and Omeprazole are shown in Figures 5 and 6.

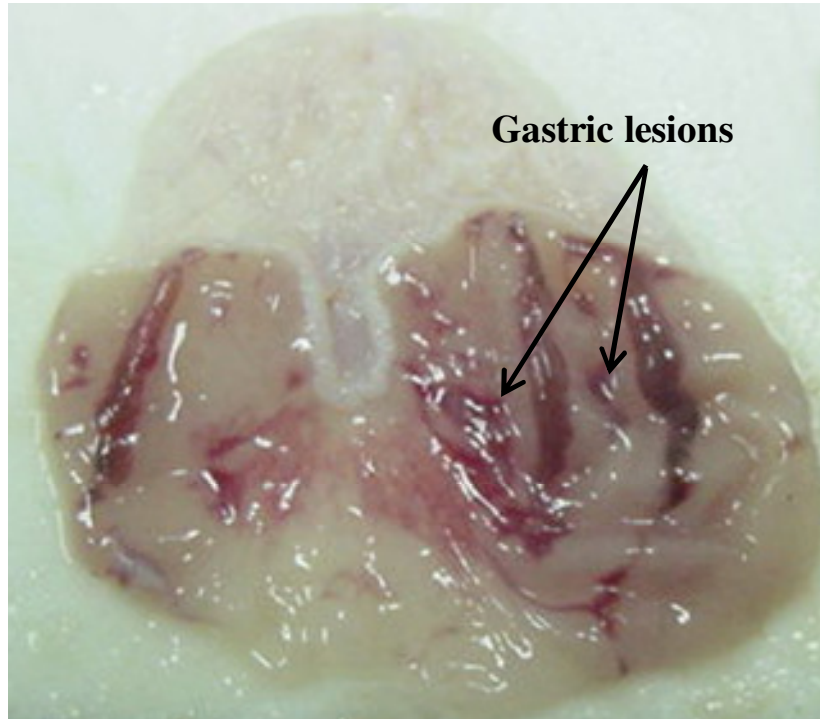


Figure 1. Macroscopic appearance of the gastric mucosa in a rat pre-treated with 5 ml/kg of CMC (ulcer control). Severe injuries were seen in the gastric mucosa.

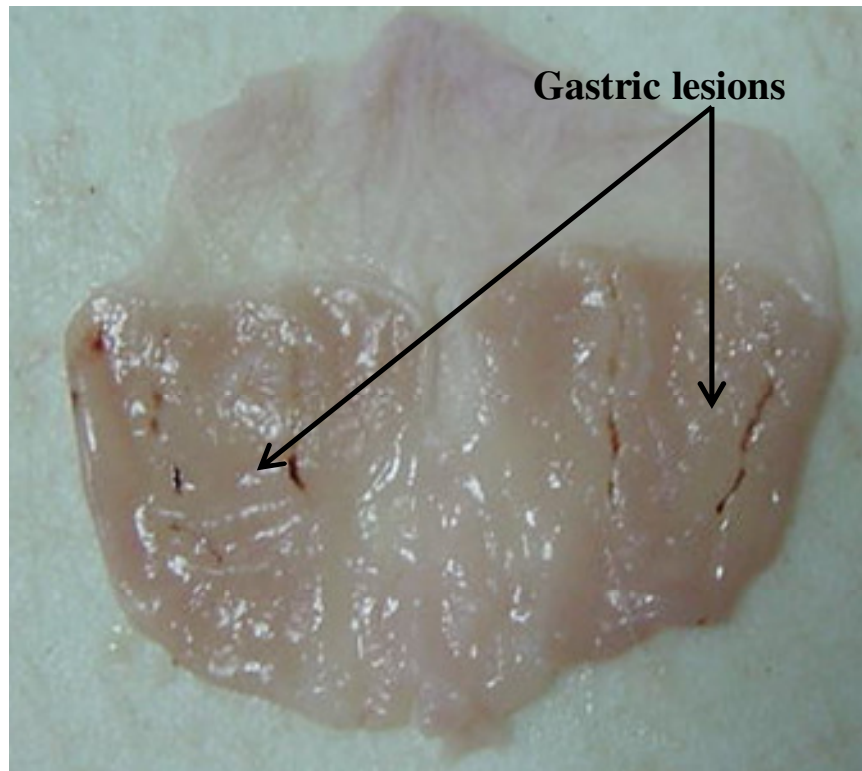


Figure 2. Macroscopic appearance of the gastric mucosa in a rat pre-treated with 5 ml/kg of Omeprazole (20 mg/kg). Injuries to the gastric mucosa were milder compared to the injuries seen in the ulcer control rat.

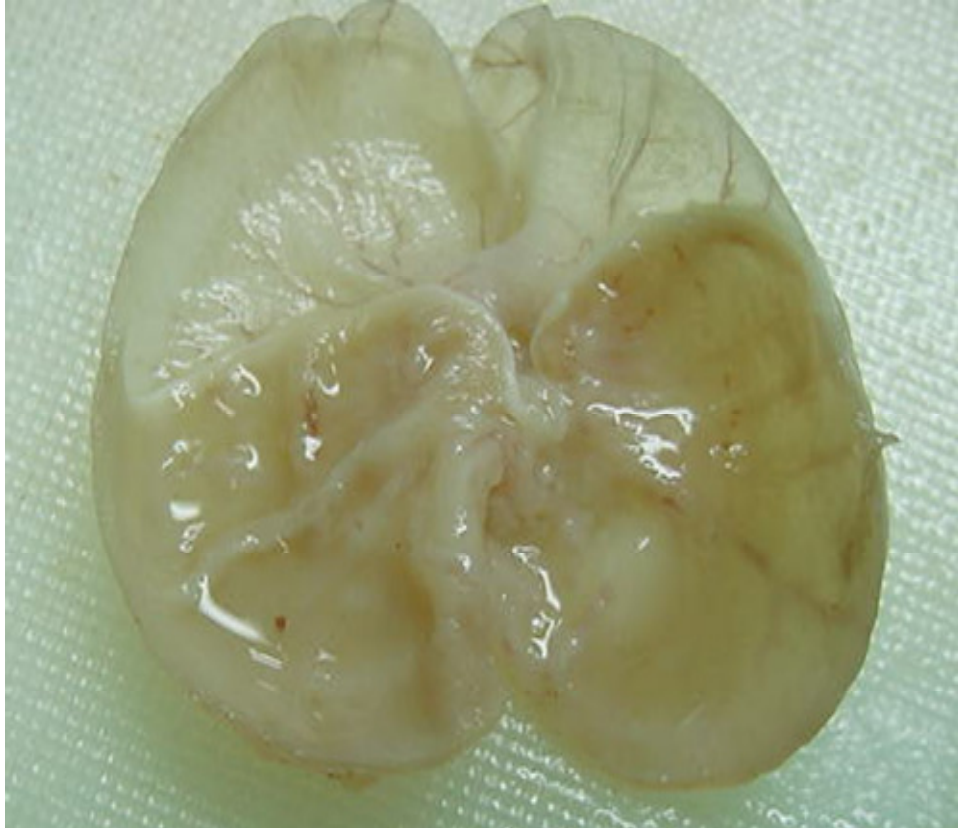

Figure 3. Macroscopic appearance of the gastric mucosa in a rat pre-treated with 5 ml/kg of *S. mahagoni* extract (500 mg/kg). Gastric mucosa showed flattening of mucosal fold, and no prominent injuries were observed.

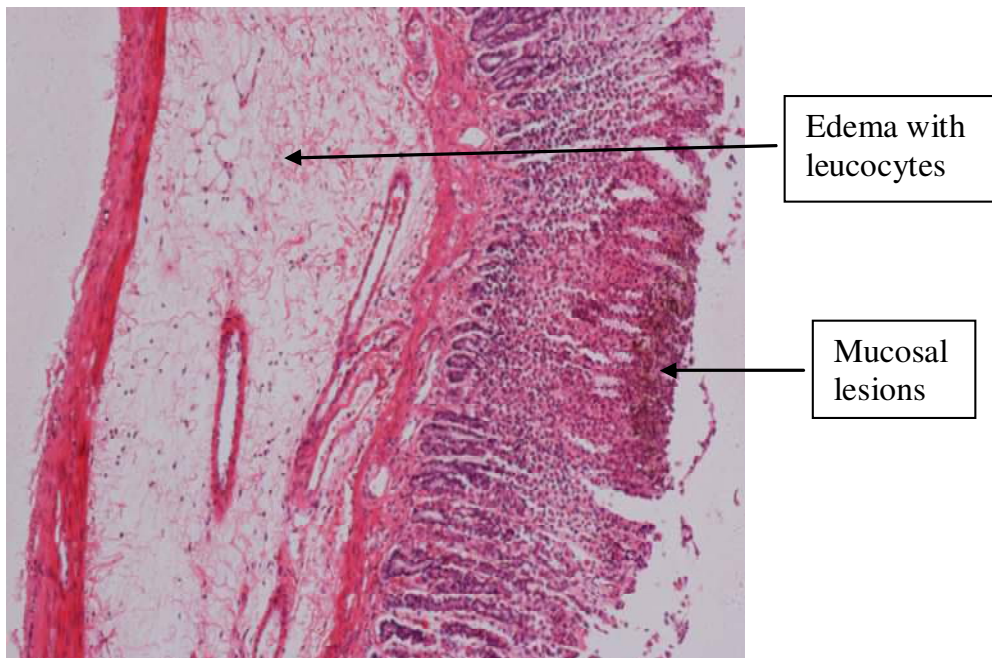


Figure 4. Histological section of gastric mucosa in a rat pre-treated with 5 ml/kg of CMC (ulcer control). There was severe disruption to the surface epithelium, and edema of the submucosa layer with leucocytes infiltration (H and E stain 10x magnification).

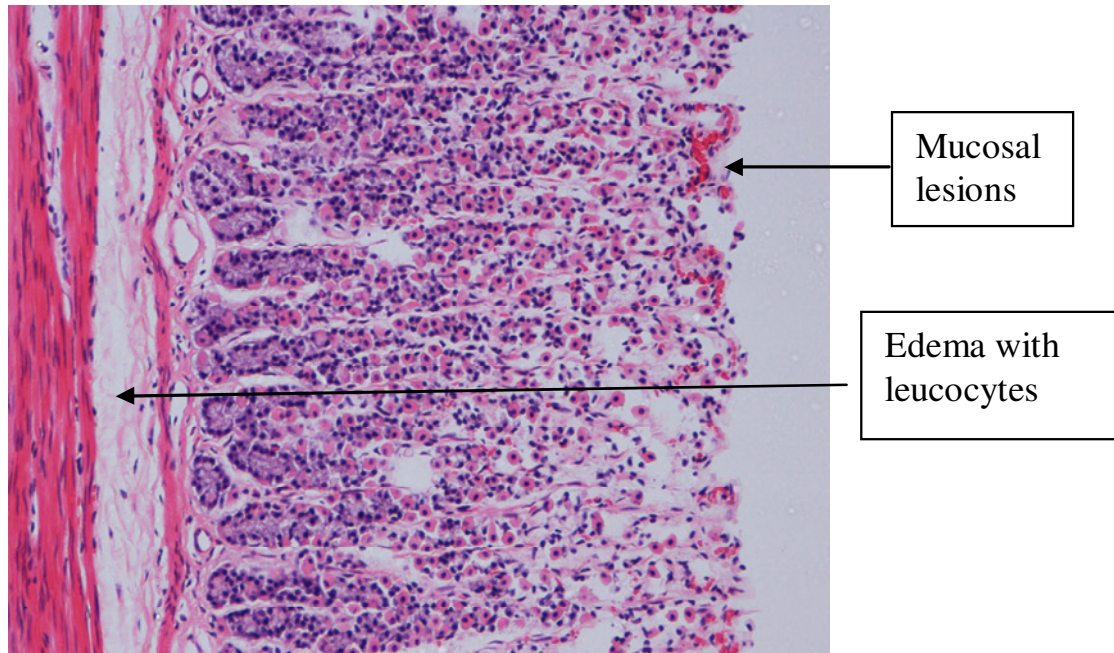


Figure 5. Histological section of gastric mucosa in a rat pre-treated with 5 ml/kg of Omeprazole (20 mg/kg). There was mild disruption to the surface epithelium with mild edema and leucocytes infiltration of the submucosal layer (H and E stain 10x).

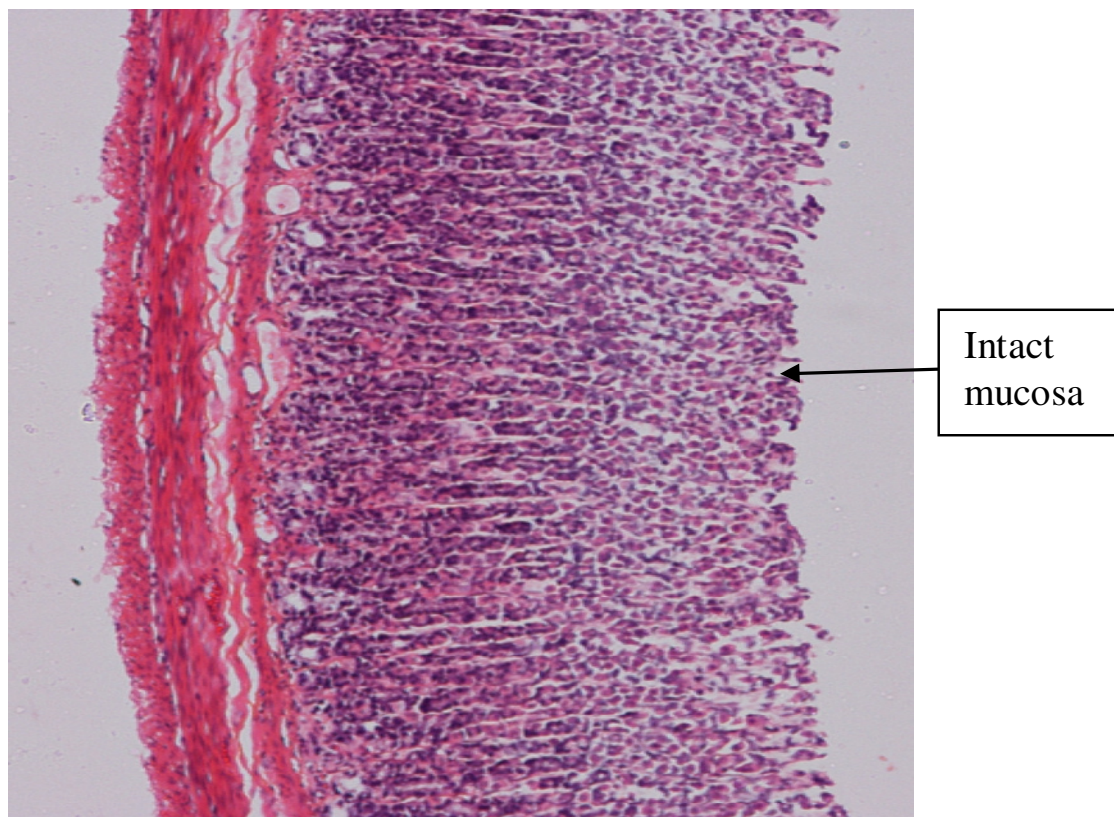


Figure 6. Histological section of gastric mucosa in a rat pre-treated with 5 ml/kg of *Swietenia mahagoni* (500 mg/kg). There was very mild disruption to the surface epithelium with no edema and no leucocytes infiltration of the submucosal layer (H and E stain 10x).

DISCUSSION

Although in most cases the etiology of ulcer is unknown, it is generally accepted that it is the result of an imbalance between aggressive factors and maintenance of the mucosal integrity through the endogenous defense mechanism (Piper and Stiel, 1986). It is known that gastric lesions produced by ethanol administration appeared as multiple-hemorrhagic red bands of different size along the glandular stomach.

Absolute ethanol is commonly used for inducing ulcer in experimental rats and lead to intense gastric mucosal damage. Studies suggest that the ethanol damage to the gastrointestinal mucosa starts with microvascular injury, namely disruption of the vascular endothelium resulting in increased vascular permeability, edema formation and epithelial lifting (Szabo et al., 1995). Furthermore, ethanol produces necrotic lesions in the gastric mucosa by its direct toxic effect, reducing the secretion of bicarbonates and production of mucus (Marhuenda et al., 1993).

The results of the present study show that the *S. mahagoni* leaf extract is capable of inhibiting gastric lesions formed by ethanol. The accompanying significant increase in mucus production suggests that the gastric mucosal strengthening mechanism contributes to the anti-irritant potential of the *S. mahagoni*. It is evident that increased mucus productions have largely contributed to preventive effect of the extract. The gastric wall mucus is thought to play an important role as a defensive factor against gastrointestinal damage (Davenport, 1968).

Pre-treatment of animals with leaf extract of *S. mahagoni* significantly increased gastric mucus content which suggests that gastroprotective effect of this plant is mediated partly by preservation of gastric mucus secretion.

In the present study, we observed flattening of the mucosal folds which in turn suggests that gastro-protective effect of *S. mahagoni* leaf extract might be due to a decrease in gastric motility. It is previously reported that the changes in the gastric motility may play a role in the development and prevention of experimental gastric lesions (Garrick et al., 1986; Takeuchi et al., 1987). Relaxation of circular muscles will increase the mucosal area to be exposed to necrotizing agents and reduce the volume of the gastric irritants on rugal crest leading to protection of the gastric mucosa against damage (Takeuch and Nobuhara, 1985).

Our findings have revealed protection of gastric mucosa and inhibition of leucocytes infiltration of gastric wall in rats pretreated with *S. mahagoni* leaf extract. Kobayashi et al. (2001) reported that teprenone exerts a protective effect against mucosal lesions through inhibition of neutrophil infiltration in the ulcerated gastric tissue while Shimizu et al. (2000) demonstrated that the reduction of neutrophil infiltration into ulcerated gastric tissue promotes the healing of gastric ulcers in rats.

Absolute alcohol would extensively damage the gastric

mucosa leading to increased neutrophil infiltration into the gastric mucosa. Oxygen free radicals derived from infiltrated neutrophils in ulcerated gastric tissues have inhibitory effect on gastric ulcers healing in rats (Suzuki et al., 1998). Neutrophils are a major source of inflammatory mediators and can release potent reactive oxygen species such as superoxide, hydrogen peroxide and myeloperoxidase derived oxidants. These reactive oxygen species are highly cytotoxic and can induce tissue damage (Cheng and Koo, 2000). Therefore, suppression of neutrophil infiltration during inflammation was found to enhance gastric ulcer healing (Tsukimi et al., 1996). *S. mahagoni* leaf extract have been shown to contain anti-inflammatory activity (Ghosh et al., 2009) and it is speculated that the gastro-protective exerted by this plant could be attributed to its anti-inflammatory property. Swarnakar et al. (2005) have reported that the anti-inflammatory activity of curcumin could be a key factor in the prevention of gastric ulcer.

Oxidative stress plays an important role in the pathogenesis of various diseases including gastric ulcer, with antioxidants being reported to play a significant role in the protection of gastric mucosa against various necrotic agents (Trivedi and Rawal, 2001).

Antioxidants could help to protect cells from damage caused by oxidative stress while enhancing the body's defense systems against degenerative diseases. Administration of antioxidants inhibits ethanol-induced gastric injury in rat (Ligumsky et al., 1995).

S. mahagoni have been reported to contain flavonoids (Sahgal et al., 2009a, b) and it could be conceivable that the anti-ulcer activity of *S. mahagoni* leaf extract could be linked to the flavonoids since flavonoids are reported to protect the mucosa by preventing the formation of lesions by various necrotic agents (Saurez et al., 1996). It is well known that many flavonoids display anti-secretory and cytoprotective properties in different experimental models of gastric ulcer (Zayachkivska et al., 2005).

Flavonoids possess anti-oxidant properties in addition to strengthening the mucosal defense system through stimulation of gastric mucus secretion (Martin et al., 1994). The acute toxicity profile of *S. mahagoni* leaf extract could be considered favorable judging from the absence of adverse clinical manifestations in experimental animals after 14 days of observation. Liver and kidney of the treated rats showed no significant changes as compared to the control group. Hematology and clinical biochemistry values were within the range of the control animals tested and similar to some of the control reference values published by other researchers (Ghosh et al., 2009; Radhamani et al., 2009).

The highest dose of ethanol extract of *S. mahagoni* which did not cause any toxicity was 5 g/kg body weight, suggesting that the *S. mahagoni* is relatively non-toxic since in acute toxicity studies, the product is considered non-toxic if no deaths are registered after 14 days of observation and no clinical signs of toxicity are observed

at doses at or below 5 g/kg. These results indicate that the extract is quite safe even at these higher doses and has no any acute toxicity.

In conclusion, *S. mahagoni* leaf extract could significantly protect the gastric mucosa against ethanol induced damage. Such protection was shown to be dose dependent as ascertained by the reduction of ulcer areas in the gastric wall, reduction or inhibition of edema, and leucocytes infiltration of submucosal layers.

ACKNOWLEDGEMENTS

The authors express gratitude to the staff of the Faculty of Medicine Animal House for the care and supply of rats, and to the University of Malaya for the financial support (P0102/2009C).

REFERENCES

- Abdelgaleil SA, Doe M, Morimoto Y, Nakatani M (2006). Rings B, D-seco limonoids from the leaves of *Swietenia mahogani*. *Phytochem.* 67:452-458.
- Bacsal K, Chavez L, Diaz I, Espina S, Javillo J, Manzanilla H, Motalban J, Panganiban C, Rodriguez A, Sampaico C (1997). The effect of *S. mahogany* (mahogany) seed extract on indomethacin-induced gastric ulcers in female Sprague-Dawley rats. *Acta Medica Philippina* 3:127-139.
- Bergmeyer HU, Horder M (1980). IFCC methods for the measurement of catalytic concentration of enzymes. Part 3. IFCC method for alanine aminotransferase. *J Clin. Chem. Clin. Biochem.*, 18: 521-534.
- Chen Y, Wang XN, Fan CQ, Yin S, Yue JM (2007). Swiemahogins A and B, two novel limonoids from *Swietenia mahogani*. *Tetrahedron Lett.* 48: 7480-7484.
- Cheng CL, Koo MWL (2007). Effects of *Centella asiatica* on ethanol induced gastric mucosal lesions in rats. *Life Sci.*, 67: 2647-2653.
- Davenport HW (1968). Destruction of the gastric mucosal barrier by detergents and urea. *Gastroenterol.* 54:175-180.
- De Pasquale R, German MP, Keita A, Sanogo R, Iauk L (1995). Antiulcer activity of *Pteleopsis suberosa*. *J. Ethnopharmacol.* 47:55-58.
- Garg GP, Nigam SK, Ogle CW (1993). The gastric antiulcer effects of the leaves of the neem tree. *Planta Medica* 59:215-217.
- Garrick T, Buack S, Bass P (1986). Gastric motility is major factor in cold, restraint induced lesion formation in rats. *Am. J. Physiol.* 250:6191-6199.
- Ghosh S, Besra SE, Roy K, Gupta JK, Vedasiromoni JR (2009). Pharmacological effects of methanolic extract of *Swietenia mahagoni* Jacq (meliaceae) seeds. *Int. J. Green Pharm.* 3:206-210.
- Hollander D, Tarnawski A, Krause WJ, Gergely H (1985). Protective effect of sucralofate against alcohol-induced gastric mucosal injury in the rat. Macroscopic, histologic, ultrastructural, and functional time sequence analysis. *Gastroenterology* 88:366-374.
- Kadota S, Yanagawa K, Kikuchi T, Tanaka K (1990). Mahagonin, a novel dimeric tetranortriterpenoid from Jacq. *Tetrahedron Lett.* 31:5943-5946.
- Kauffman GL, Grossman MI (1978). Prostaglandin and cimetidine inhibit the formation of ulcers produced by parenteral salicylates. *Gastroenterology* 75:1099-2102.
- Kobayashi T, Ohta Y, Yoshino J, Nakazawa S (2001). Teprenone promotes the healing of acetic acid-induced chronic gastric ulcers in rats by inhibiting neutrophil infiltration and lipid peroxidation in ulcerated gastric tissues. *Pharmacol. Res.* 43:23-30.
- Li DD, Chen JH, Chen Q, Chen Q, Li GW, Yue JM, Chen ML, Wang XP, Shen JH, Shen X (2005). *Swietenia mahogony* extract shows agonistic activity to PPAR and gives ameliorative effects on diabetic db/db mice. *Acta Pharmacologica Sin.* 26:220-222.
- Li X, Andersson TB, Ahlstrom M, Weidolf L (2004). Comparison of inhibitory effects of proton pump inhibiting drugs omeprazole, esomeprazole, lansoprazole, pantoprazole and rabeprazole on human cytochrome P450 activities. *Drug Metab. Dispos.* 32: 821-827.
- Ligumsky M, Sestieri M, Okon F, Ginsburg I (1995). Antioxidants inhibit ethanol-induced gastric injury in the rat. Role of manganese, glycin and carotene. *Scand. J. Gastroenterol.* 30:854-860.
- Maiti A, Dewanjee S, Mandal SC (2007). *In vivo* evaluation of antidiarrhoeal activity of the seed of *Swietenia macrophylla* King (Meliaceae). *Trop. J. Pharmace. Res.* 6:711-716.
- Majid MA, Rahman IMM, Shipar MAH, Uddin MH, Chowdhury YR (2004). Physico-chemical characterization, antimicrobial activity and toxicity analysis of *Swietenia mahagoni* seed oil. *Int. J. Agric. Biol.* 6:350-354.
- Marhuenda E, Martin MJ, De La Alarconlastra C (1993). Antiulcerogenic activity of aescine in different experimental models. *Phytother. Res.* 7:13-16.
- Martin MJ, Marhuenda E, Perez-Guerrero C, Franco JM (1994). Antiulcer effect of naringin on gastric lesion induced by ethanol in rats. *Pharmacol.* 49:144-150.
- Nagalakshmi MAH, Thangadurai D, Muralidara Rao D, Pullaiah T (2001). Phytochemical and antimicrobial study of *Chukrasia tabularis* leaves. *Fitoterapia* 72:62-64.
- Njar VCO, Adesanwo JK, Raji Y (1995). Methyl angolensate: the antiulcer agent of the stem bark of *Entandrophragma angolense*. *Planta Medica* 61:91-92.
- Paiva LAF, Rao VSN, Gramosa NV, Silveira FR (1998). Gastroprotective effect of *Copaifera langsdorffii* oleo-resin on experimental gastric ulcer models in rats. *J. Ethnopharmacol.* 62:73-78.
- Pedernera AM, Guardia T, Caleron CG, Rotelli AF, de la Rocha NF, di Genaro S, Pelze LF (2006). Antiulcerogenic and anti-inflammatory activity of the methanolic extract of *Larrea divaricata* Cav. in rat. *J. Ethnopharmacol.* 105:415-420.
- Piper DW, Stiel D (1986). Pathogenesis of chronic peptic ulcer, current thinking and clinical implications. *Med. Prog.* 2:7-10.
- Radhamani S, Sunilson J, Gopinath R, Das A, Nilugal K (2009). Hypoglycemic activity of endocarp of *Swietenia macrophylla* King. extracts in glucose loaded rats. *J. Pharmacy Res.* 2:1203-1205.
- Saad M, Iwagawa T, Doe M, Nakatani M (2003). Swietenialides, novel ring D opened phragmalin limonoid orthoesters from *Swietenia mahogani* JACQ. *Tetrahedron* 59:8027-8033.
- Sahgal G, Ramanathan S, Sasidharan S, Mordi MN, Ismail S, Mansor SM (2009a). *In vitro* antioxidant and xanthine oxidase inhibitory activities of methanolic *Swietenia mahagoni* seed extracts. *Molecules* 14:4476-85.
- Sahgal G, Ramanathan S, Sasidharan S, Mordi MN, Ismail S, Mansor SM (2009b). Phytochemical and antimicrobial activity of *Swietenia mahogani* crude methanolic seed extract. *Trop. Biomed.* 26:274-279.
- Saurez J, Herreta MD, Marhuenda E (1996). Hesperidin and neohesperidin dihydrochalcone on different experimental models of induced gastric ulcer. *Phytother. Res.* 10:616-618.
- Shimizu N, Watanabe T, Arakawa T, Fujiwara Y, Higuchi K, Kuroki T (2000). Pentoxifylline accelerates gastric ulcer healing in rats: roles of tumor necrosis factor alpha and neutrophils during the early phase of ulcer healing. *Digestion* 6:157-164.
- Suzuki Y, Ishihara M, Ito M (1998). Anti-ulcer effects of antioxidants, quercetin, a-tocopherol, nifedipine and tetracycline in rats. *Japanese J. Pharmacol.* 78:435-441.
- Swarnakar S, Ganguly K, Kundu P, Banerjee A, Maity P, Sharma AV (2005). Curcumin regulates expression and activity of matrix metalloproteinases 9 and 2 during prevention and healing of indomethacin-induced gastric ulcer. *J. Biol. Chem.* 280:9409-9415.
- Szabo S, Kusstatscher S, Sakoulas G, Sandor Z, Vincze AA, Judus M (1995). Growth factors: New "endogeneous drug" for ulcer healing. *Scand. J. Gastroenterol.* 210:15-18.
- Takeuch K, Nobuhara Y (1985). Inhibition of gastric motor activity by 16, 16-dimethyl-prostaglandin E2; a probable explanation of cycloprotection. *Dig. Dis. Sci.* 30:1181-1188.
- Takeuchi K, Nishiwakki K, Okabe S (1987). Effect of dopamine on gastric mucosal lesion induced by ethanol in rats—possible

- involvement of antigastric motor activity mediated with alpha 2 adrenoreceptors. *Dig. Dis. Sci.* 31:1100-1107.
- Tan PV, Nyasse B, Dimo T, Mezui C (2002). Gastric cytoprotective anti-ulcer effects of the leaf methanol extract of *Ocimum suave* (Lamiaceae) in rats. *J. Ethnopharmacol.* 82:69-74.
- Tietz NW, Rinker AD, Shaw LM (1983). IFCC methods for the measurement of catalytic concentration of enzymes. Part 5. IFCC method for alkaline phosphatase. *J. Clin. Chem. Clin. Biochem.* 21:731-748.
- Trivedi NP, Rawal UM (2001). Hepatoprotective and antioxidant property of *Andrographis paniculata* Nees in BHC induced liver damage in mice. *Indian J. Exp. Biol.* 39:41-46.
- Tsukimi Y, Nozue C, Okabe S (1996). Effects of teminoprazole, omeprazole and sucralfate on indomethacin-induced delayed healing of kissing gastric ulcers in rats. *J. Gastroenterol. Hepatol.* 11:335-340.
- Zayachkivska OS, Konturek SJ, Drozdowicz D, Konturek PC, Brzozowski T, Ghegotsky MR (2005). Gastroprotective effects of flavonoids in plant extracts. *J. Physiol. Pharmacol.* 56:219-231.