

PDF hosted at the Radboud Repository of the Radboud University Nijmegen

The following full text is a publisher's version.

For additional information about this publication click this link.

<http://hdl.handle.net/2066/48027>

Please be advised that this information was generated on 2022-08-23 and may be subject to change.

Apical Root Resorption Six and 12 Months After Initiation of Fixed Orthodontic Appliance Therapy

Jon Årtun^a; Isolde Smale^b; Faraj Behbehani^c; Diane Doppel^d;
Martin Van't Hof^e; Anne M. Kuijpers-Jagtman^f

Abstract: The low explained variance of identified risk factors for apical root resorption in orthodontic patients suggests effects of parameters related to individual predisposition. Our purpose was to explore this hypothesis. We evaluated standardized periapical radiographs of the maxillary incisors made before treatment (T1) as well as at about six and 12 months after bracket placement (T2 and T3) of 247 patients aged 10.1 to 57.1 years at T1. The radiographs were converted to digital images, and commercially available software was used to correct for differences in projection. The results showed that 20.2%, 7.7%, and 5.3% of the patients had ≥ 1 tooth with >2.0 , 3.0, and 4.0 mm resorption at T3, respectively. Pearson's correlation revealed an association between resorption from T1 to T2 and from T2 to T3 ($P < .01$). The risk of ≥ 1 tooth with >1.0 mm resorption from T2 to T3 was 3.8 times higher (95% CI 2.4–6.0) in patients with ≥ 1 tooth with >1.0 mm from T1 to T2 than in those without. Also, resorption was more pronounced ($P < .001$) from T2 to T3 in patients with ≥ 1 tooth with >1.0 mm and >2.0 mm resorption from T1 to T2 than in those without. The explained variance of identified risk factors was $<10\%$. Orthodontic patients with detectable root resorption during the first six months of active treatment are more likely to experience resorption in the following six-month period than those without. (*Angle Orthod* 2005;75:919–926.)

Key Words: Apical root resorption; Risk factors; Prediction

INTRODUCTION

Studies based on random measurements of tooth lengths (TL) on standardized periapical radiographs made before and after active orthodontic treatment

conclude that the sample mean of the averaged amount of resorption of all six maxillary anterior teeth,¹ of the four maxillary incisors,^{2,3} or of each pair of maxillary central and lateral incisors,¹⁻⁴ is less than 1.5 mm. Accordingly, apical root resorption is of limited clinical significance for the average patient.

However, about 4% of the patients experience generalized resorption of more than three mm,^{1,2} and about 5% of adults¹ and 2% of adolescents² are likely to have one or more teeth that undergo more than five mm of resorption during appliance therapy. Similarly, simultaneous subjective scoring of pre- and posttreatment panoramic radiographs of a large representative patient sample⁵ suggests that about 3% experience resorption of more than one fourth of the root length of both maxillary central incisors during fixed appliance therapy. Although the resorption process stops once the active appliances are removed,⁶ severely resorbed teeth may be lost prematurely in patients who are also susceptible to marginal periodontal breakdown. In addition, teeth with abnormally short roots may not be suitable as future bridge abutments. The ability to identify the small proportion of patients at risk of severe apical root resorption before or early in treatment may, therefore, be of clinical significance.

^a Professor and Chair, Department of Developmental and Preventive Sciences, Faculty of Dentistry, Kuwait University, Kuwait City, Kuwait.

^b Private Practice, Nijmegen, The Netherlands.

^c Assistant Professor, Department of Developmental and Preventive Sciences, Faculty of Dentistry, Kuwait University, Kuwait City, Kuwait.

^d Private Practice, Seattle, Wash.

^e Professor, Department of Clinical Dental Research, Radboud University Nijmegen Medical Centre, Nijmegen, The Netherlands.

^f Professor and Chair, Department of Orthodontics and Oral Biology, Radboud University Nijmegen Medical Centre, Nijmegen, The Netherlands.

Corresponding author: Jon Årtun, DDS, Dr Odont, Department of Developmental and Preventive Sciences, Faculty of Dentistry, Kuwait University, PO Box 24923 Safat, Kuwait city 13110, Kuwait
(e-mail: artun@hsc.edu.kw)

Accepted: December 2004. Submitted: November 2004.

© 2005 by The EH Angle Education and Research Foundation, Inc.

Regression analyses conclude that amount of tooth movement,^{7,8} abnormal root form,^{7,8} increased TL,^{7,8} and reduced root width (RW)⁷⁻⁹ are risk factors for apical root resorption. In addition, split mouth^{7,10} and intergroup⁷ comparisons of representative patient samples conclude that endodontic treatment is a preventive factor. Although a recent report on selected cases suggested that dental anomalies of any tooth in the dentition are a major general risk factor for orthodontic resorption of the maxillary incisors,¹¹ this hypothesis could not be confirmed in a recent controlled clinical study.¹²

Multivariate regression concludes that the variance in resorption at the end of treatment that can be explained by the identified risk factors is less than 20%.^{3,7,9} This finding suggests effects of parameters related to individual predisposition. If so, predisposed patients may experience root resorption early in orthodontic treatment. We recently explored this hypothesis by evaluating a large representative patient sample approximately six months after placement of maxillary incisor brackets.¹³ We found that 4.1% of the patients had an average resorption of 1.5 mm or more of the four maxillary incisors and that 15.5% had one or more teeth that resorbed at least 2.0 mm. The maximum resorption at the tooth level was 4.4 mm. The explained variance of the identified risk factors was as low as 14% for the central and 24% for the lateral incisors.

The aim of this study was to determine the prevalence of apical root resorption after about 12 months in this patient group and to test the hypothesis that an association exists between amount of resorption during the first and second observation periods.

MATERIALS AND METHODS

Study population and sample

A total of 302 orthodontic patients were consecutively enrolled between March 2001 and July 2002 at three different centers in Kuwait, Nijmegen, and Seattle. All patients were treated with either 0.018-inch (113 patients) or 0.022-inch (189 patients) bracket slot multibonded preadjusted appliances.

The protocol called for three radiographic projections, one with the central ray between the two central incisors and one with the ray centered at the lateral incisor on either side, according to a paralleling technique. The radiographs were obtained before (T1) and approximately six (T2) and 12 (T3) months after placement of maxillary incisor brackets.

For this communication, 247 patients, 164 females and 83 males (mean age at T1: 19.2 years, SD 10.8; range 10.1 to 57.1 years), were evaluated. The evaluations were over a time period ranging from 4.3 to

9.4 months from T1 to T2 (mean 6.4, SD 0.9), from 3.0 to 11.0 months from T2 to T3 (mean 6.0, SD 1.0), and from 8.7 to 15.7 months from T1 to T3 (mean 12.4, SD 1.0). Patients without radiographs at T3 (n = 49, of whom five elected to withdraw from the study) or with insufficient quality of the radiographs at T1 (n = 6) were excluded.

No systematic differences were detected in age, sex, extraction decision, incisor irregularity, or follow-up period between the included and discarded patients ($P > .05$). At T2, all radiographs were missing for two patients, and eight teeth were omitted among six of the remaining 245 patients, seven because of incomplete radiographic projection and one because of unsuccessful reconstruction (see subsequent paragraph). In addition, 75 teeth were omitted at all time periods among 53 patients, 26 because of a combination of congenital absence or incomplete radiographic projection and 49 because of unsuccessful reconstruction.

Anamnestic parameters

A history of previous orthodontic treatment was recorded as present or absent through patient interviews. A history of traumatic injury to any maxillary incisor was recorded through clinical and radiographic examination and patient interviews.

Occlusal parameters

Anatomic contact point displacement was measured from the mesial of one maxillary canine to the mesial of the other on the T1 study models. Labiolingual displacement was measured according to a modified irregularity index (IRI), defined as the sum of labiolingual discrepancies perpendicular to the dental arch. Mesiodistal displacement was measured according to a proposed spacing index (SPI), defined as the sum of horizontal discrepancies parallel to the dental arch, which recorded no displacement as zero, overlapping as negative, and spacing as positive. Contact point displacement was measured according to a proposed contact displacement index (CDI), similar to Little's IRI,¹⁴ and defined as the sum of the distances between adjacent anatomic contact points, regardless of space or overlapping. IRI and SPI were measured with a transparent millimeter-grid and CDI with a digital caliper (Fred V Fowler Co Inc, Newton, Mass), all to the nearest 0.5 mm.

Scanning and reconstruction of periapical radiographs

All periapical radiographs were converted to digital images using an HP Scanjet 5470c scanner (Hewlett-

Packard, Palo Alto, Calif) at a resolution of 300 dpi. The Windows-based Emago/Advanced version 2.20 software package (SODS, Amsterdam, The Netherlands) was used to correct for differences in enlargement and projection between corresponding images at different time intervals by superimposing on four identical anatomic landmarks on the images, two as far incisally and two as far apically as possible.^{13,15}

Each pair (T1, T3) or series (T1, T2, T3) of scanned images were evaluated simultaneously on the screen, and the projection judged most favorable was chosen as a reference (Figure 1A through C). The quality of the reconstruction was checked by subtracting the reconstructed image from the reference image. If only minimal root and crown structures could be discerned on the subtracted image, the reconstruction was considered successful (Figure 1E).

Computerized evaluations

All reconstructed and reference radiographic images were coded and measured in random order with the aid of the Emago software, recording the number of pixels between landmark pairs.^{13,15} TL was measured as the distance from tip of the apex to the midpoint of either the incisal edge, the line connecting the mesial and distal outlines of cemento-enamel junction (CEJ), or of the gingival contour of the bracket base, depending on location of the incisal reference points used for reconstruction. No reference brackets failed during the observation period. RW was measured four mm from the apex. Assuming that the enlargement factor was negligible, absolute distances were calculated according to the formula one pixel = 0.085 mm because all images were scanned at a resolution of 300 dpi.

Subjective evaluations

Root form was scored subjectively as normal, blunt, eroded, pointed, bent, or bottle shaped on the T1 radiographs (Figure 2).

Method error

The reproducibility of the measurements was assessed by analyzing the differences between double measurements taken at least one week apart on study models and radiographs at T1, T2, and T3 of 20 randomly selected patients. For the computerized measurements, the whole reconstruction and landmark identification procedures were repeated. The errors of the continuous variables were calculated from the equation

$$S_x = \sqrt{\frac{\sum D^2}{2N}}$$

where D is the difference between duplicated measurements and N is the number of double measurements,¹⁶ as well as according to Pearson's correlation coefficient (*r*).

The errors of the study model measurements were 1.33 mm for SPI (*r* = 0.71), 1.84 mm for IRI (*r* = 0.85), and 2.37 mm for CDI (*r* = 0.64). The errors for the measurements of TL and RW at T1 were 0.46 mm (*r* = 0.96) and 0.25 mm (*r* = 0.70), respectively, whereas the error for calculation of root resorption was 0.46 mm (*r* = 0.67). The Kappa for duplicate subjective scoring of root shape was 0.74.

Statistical analyses

Apical root resorption at T2 and T3 was calculated by subtracting each TL at T2 and T3 from the corresponding TL at T1 and T2. Descriptive statistics were performed, and Pearson's correlation coefficients were used to test the association between resorption from T1 to T2 and from T2 to T3. Chi-square or Fisher's exact tests were used to test the differences in proportions of patients with ≥ 1 incisor with >1.0 mm and >2.0 mm resorption from T2 to T3 between patients with and without ≥ 1 incisor with >1.0 mm resorption as well as between patients with and without ≥ 1 incisor with >2.0 mm resorption from T1 to T2. Independent *t*-tests were calculated to test for differences in resorption from T2 to T3 between patients with ≥ 1 tooth with >1.0 mm and >2.0 mm resorption from T1 to T2 and those without.

Linear regression analyses were used to test the association between resorption from T1 to T3 and the different anamnestic, occlusal, and treatment parameters as well as the measurements of the reconstructed T1 radiographic images (Table 4). After univariate regression, stepwise multiple regressions with forward selection were used to develop a prediction model. Variables with the lowest *P* value were successively entered into the model if their effects were significant at *P* < .05. Separate analyses were made for the central and lateral incisors, using the most severely resorbed tooth for each pair as the dependent variable.

RESULTS

Prevalence of resorption at T3

The average patient had 0.76 mm averaged resorption of all four maxillary incisors and one incisor with resorption of 1.39 mm (Table 1). A total of 5.3% (95% CI 2.4–8.2%) had averaged resorption >2.0 mm (Figure 3), and the maximum amount of averaged resorption was 5.48 mm (Figure 4; Table 1). Similarly, 7.7%

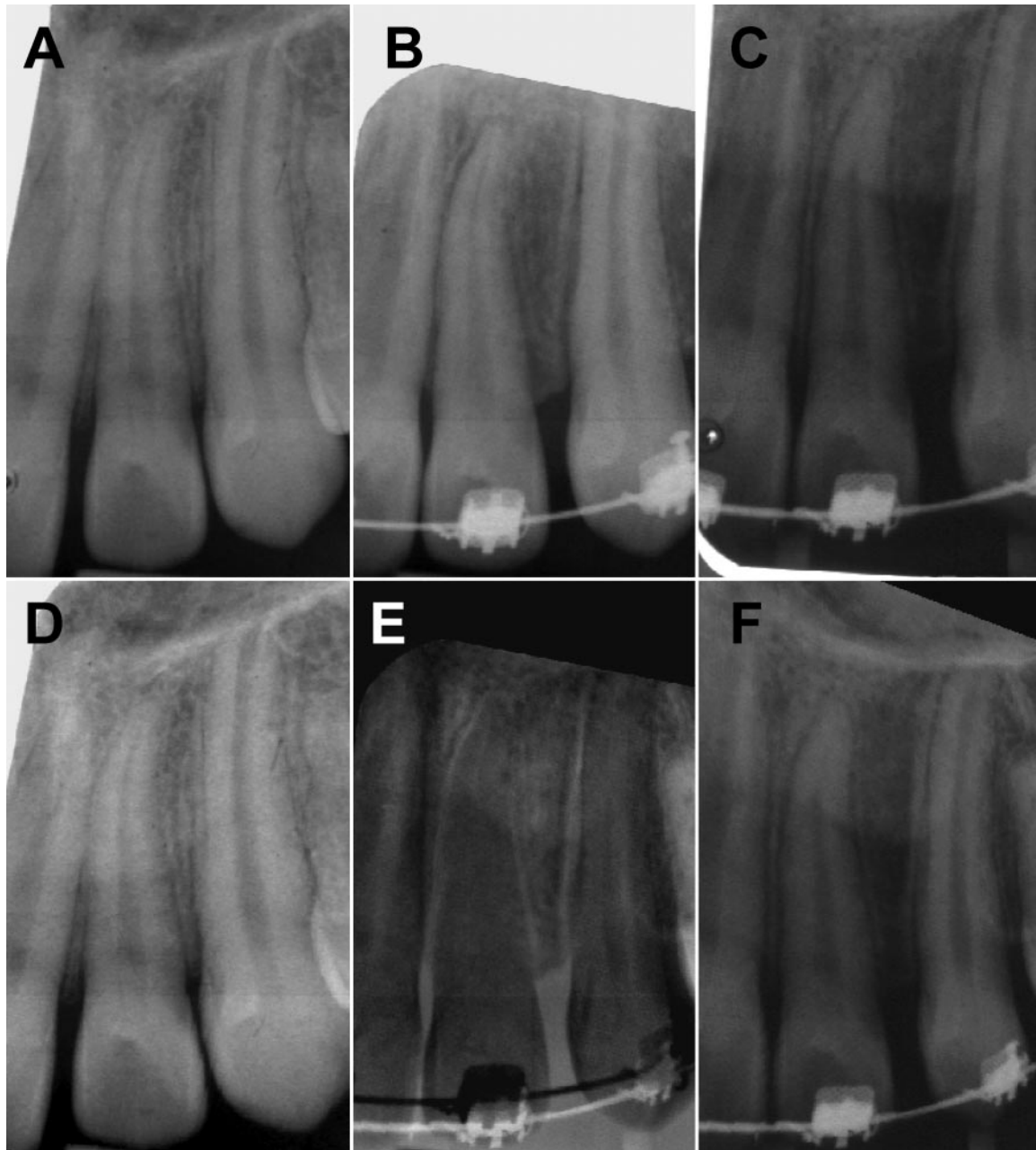


FIGURE 1. Reconstruction of pretreatment (T1) and 12-month follow-up periapical radiographs (T3) according to radiographic projection at six-month follow-up (T2): (A) original T1 image; (B) original T2 image; (C) original T3 image; (D) reconstructed T1 image; (E) subtraction of reconstructed T3 image from original T2 image; (F) reconstructed T3 image.

(95% CI 4.3–11.1%) had ≥ 1 teeth with >3.0 mm resorption, and 2.4% (95% CI 0.5–4.3%) had ≥ 1 teeth with >4.0 mm resorption (Figure 5). The maximum resorption at the tooth level was 6.26 mm (Figure 6; Table 1). A total of 9.4% of the teeth were calculated to have tooth elongation at a maximum value of 0.93 mm. As a result, 2.4% of the patients were calculated to have an averaged amount of tooth elongation of all four incisors and one patient was calculated to have a negative value for the most severely resorbed tooth.

Associations between resorption from T1 to T2 and from T2 to T3

Pearson's R for amount of resorption from T1 to T2 vs from T2 to T3 ranged from 0.24 to 0.49 ($P < .001$) for each incisor, was 0.55, 0.40, and 0.62 for averaged resorption of both lateral, both central, and all four incisors, respectively ($P < .001$), and was 0.56 for the most severely resorbed incisor per patient ($P < .001$). The frequency of patients with ≥ 1 tooth with >1.0 mm

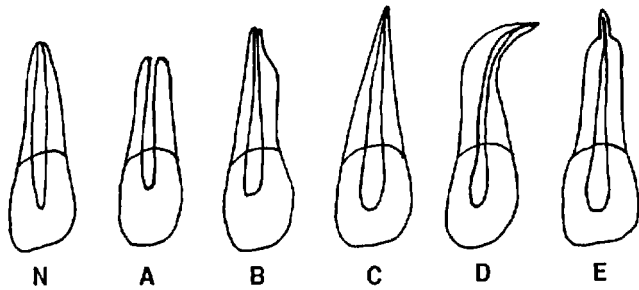


FIGURE 2. Criteria for subjective scoring of root form: N, normal; A, blunt; B, eroded; C, pointed; D, deviated; E, bottle shaped.

TABLE 1. Descriptive Statistics for Resorption of Each Incisor (12, 11, 21, 22) and the Most Severely Resorbed Incisor (Inc Max) as well as Averaged Resorption of Both Lateral (12, 22), Both Central (11, 21), and All Four Incisors Per Patient (in mm) at a Mean Period of 12.4 Months (SD 1.0) After Bracket Placement

| | Mean | SD | Min | Max |
|----------------|------|------|-------|------|
| 12 | 0.94 | 1.00 | -0.34 | 5.08 |
| 11 | 0.72 | 0.79 | -0.68 | 5.59 |
| 21 | 0.66 | 0.81 | -0.93 | 5.08 |
| 22 | 0.78 | 0.92 | -0.68 | 6.26 |
| Inc Max | 1.39 | 0.98 | -0.08 | 6.26 |
| 12, 22 | 0.67 | 0.70 | -0.34 | 5.63 |
| 11, 21 | 0.84 | 0.82 | -0.27 | 5.33 |
| 12, 11, 21, 22 | 0.76 | 0.67 | -0.14 | 5.48 |

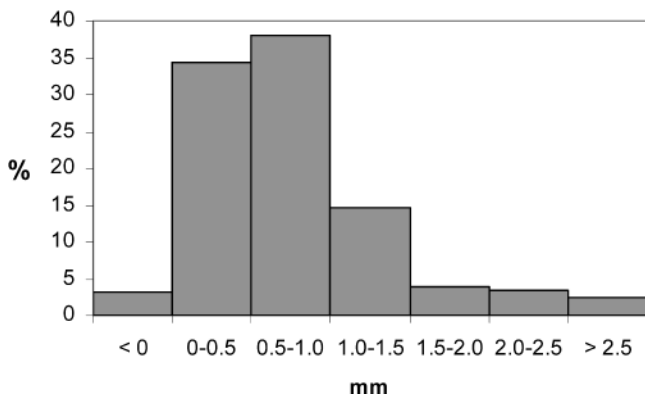


FIGURE 3. Percentage of patients with averaged amount of apical root resorption of all four maxillary incisors within each 0.5 mm interval.

and with >2.0 resorption from T2 to T3 was higher ($P < .001$) in patients with ≥ 1 tooth with >1.0 mm and with >2.0 mm resorption from T1 to T2 than in those without (Table 2). The risk of ≥ 1 tooth with >1.0 mm resorption from T2 to T3 was 3.8 times higher (95% CI 2.4–6.0) in patients with ≥ 1 tooth with >1.0 mm from T1 to T2 than in those without. Similarly, mean values for averaged resorption of all four incisors as well as of the most severely resorbed tooth per patient from T2 to T3 was higher ($P < .001$) in patients with ≥ 1 tooth with >1.0 mm and with >2.0 mm resorption from T1 to T2 (Table 3) than in those without.

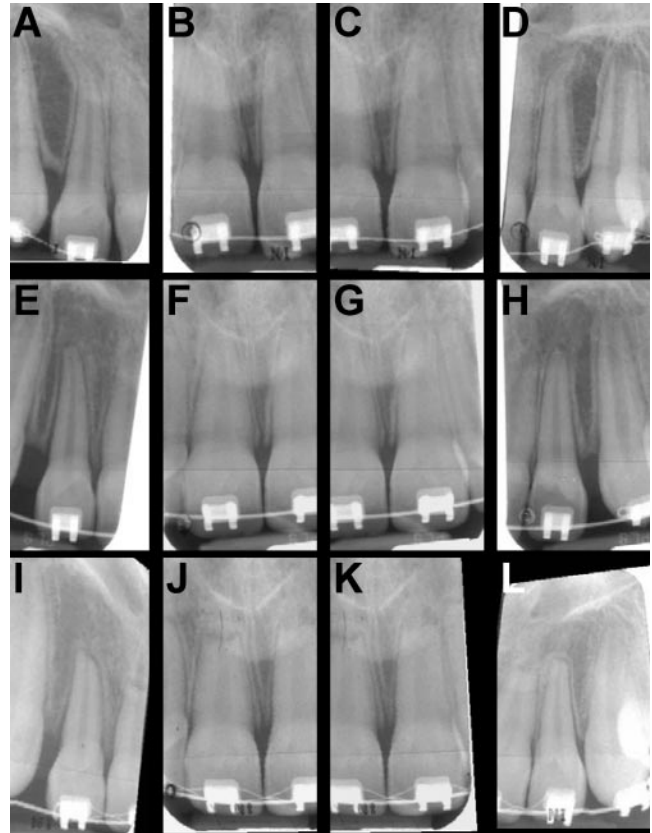


FIGURE 4. Reconstruction of pretreatment (T1) and 12-month follow-up periapical radiographs (T3) according to radiographic projection at six-month follow-up (T2) of patient with averaged resorption of 2.22 mm from T1 to T2 and 3.26 mm from T2 to T3 of all four incisors.

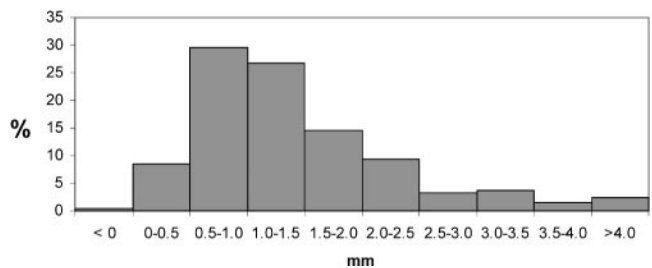


FIGURE 5. Percentage of patients with maximum amount of resorption of one maxillary incisor within each 0.5 mm interval.

Predictors for resorption

Univariate linear regression revealed that an increase in TL as well as increased observation period from T1 to T3 were associated with increased risk of resorption of the central incisors ($P < .05$, Table 4). Both variables were included in the final model as risk factors (Table 4), with r^2 (explained variance) of 0.032.

The univariate analyses detected an association between male sex ($P < .05$), time with square wire ($P < .01$), increased TL ($P < .01$), and reduced RW ($P < .01$).

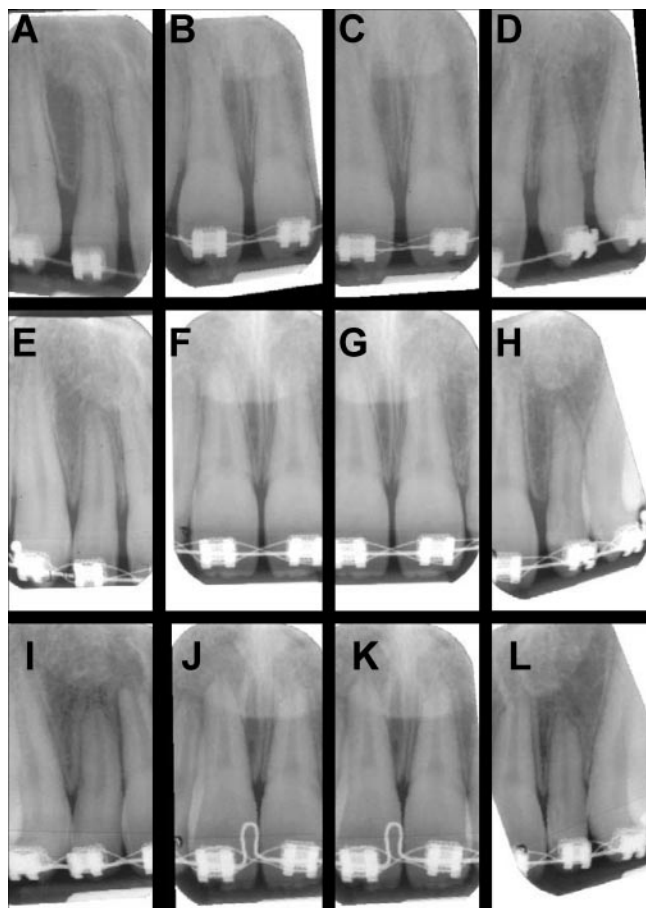


FIGURE 6. Reconstruction of pretreatment (T1) and 12-month follow-up periapical radiographs (T3) according to radiographic projection at six-month follow-up (T2) of patient with 2.88 mm resorption from T1 to T2 and 3.38 mm from T2 to T3 of maxillary left lateral incisor.

.001) and resorption of the lateral incisors (Table 4). Time with square wire, increased TL, and reduced RW were included in the final prediction model, with $r^2 = 0.075$. Sex was not offered as a variable in the multivariate analyses because of a colinearity between TL and sex, with males having longer lateral incisors. Anterior elastics were only used from 0.3 to 10.1 months in nine patients and bottle-shaped roots only scored in one lateral and four central incisors. These parameters were therefore not included as parameters in the regression analyses.

DISCUSSION

Interpretation of the whole range of root resorption estimates derived from radiographs made according to a standardized paralleling technique revealed that some teeth were judged to have tooth elongation despite the fact that continued root growth can be ruled out,^{1,3} suggesting that projection and magnification errors may be common. Attempting to minimize this problem, we used a recently introduced digital reconstruction technique¹⁵ in our study. The fact that the maximum enlargement was 0.9 mm in this as well as in a previous study¹³ as opposed to two mm or more without reconstruction^{1,3} confirms the usefulness of the technique.

We could confirm previous findings of an association between increased TL and amount of root resorption.^{7,8,13} We could also confirm an association between narrow roots and resorption.^{7-9,13} Because such root forms are more common in the maxillary lateral than in the maxillary central incisors, the common find-

TABLE 2. Number (N) and Percentage of Patients With and Without ≥1 Incisor With >1.0 mm and >2.0 mm Resorption From T2 to T3 Among Patients With and Without ≥1 Incisor With >1.0 mm Resorption as well as With and Without ≥1 Incisor With >2.0 mm Resorption From T1 to T2

| | <1.0 mm T2 to T3 | | >1.0 mm T2 to T3 | | <2.0 mm T2 to T3 | | >2.0 mm T2 to T3 | |
|----------------------------|------------------|------|------------------|------|------------------|-------|------------------|------|
| | N | % | N | % | N | % | N | % |
| <1.0 mm T1 to T2 (N = 159) | 140 | 88.1 | 19 | 11.9 | 159 | 100.0 | 0 | 0.0 |
| >1.0 mm T1 to T2 (N = 86) | 48 | 55.5 | 38 | 44.2 | 82 | 95.3 | 4 | 4.7 |
| <2.0 mm T1 to T2 (N = 226) | 184 | 81.4 | 42 | 18.6 | 226 | 100.0 | 0 | 0.0 |
| >2.0 mm T1 to T2 (N = 19) | 4 | 21.1 | 15 | 78.9 | 15 | 78.9 | 4 | 21.1 |

TABLE 3. Differences in Averaged Amount of Resorption of All Four Incisors (12, 11, 21, 22) as well as of the Most Severely Resorbed Incisor (Inc Max) Per Patient During the Second Approximate Six-Month Period (T2 to T3) Between Patients With and Without ≥1 Incisors With >1.0 mm and >2.0 mm Resorption During the First Approximate Six-Month Period (T1 to T2) After Bracket Placement

| | 12, 11, 21, 22 (T2 to T3) | | | Inc Max (T2 to T3) | | |
|-----------------------------|---------------------------|------|-------|--------------------|------|-------|
| | Mean | SD | P | Mean | SD | P |
| <1.0 mm (T1 to T2, N = 159) | 0.22 | 0.21 | | 0.54 | 0.37 | |
| >1.0 mm (T1 to T2, N = 86) | 0.49 | 0.48 | <.001 | 0.97 | 0.66 | <.001 |
| <2.0 mm (T1 to T2, N = 226) | 0.26 | 0.25 | | 0.62 | 0.40 | |
| >2.0 mm (T1 to T2, N = 19) | 0.90 | 0.73 | <.001 | 1.57 | 0.93 | <.001 |

TABLE 4. Results of Univariate Regression and Multivariate Regression Analyses With Forward Selection Using the Most Severely Resorbed Maxillary Central and Lateral Incisors (in mm) at a Mean Period of 12.4 Months (T3) After Bracket Placement (T1) as the Dependent Variables^a

| Variable (unit) | Maxillary Central Incisor | | | | Maxillary Lateral Incisor | | | |
|-----------------------------|---------------------------|------|--------------|------|---------------------------|-------|--------------|------|
| | Univariate | | Multivariate | | Univariate | | Multivariate | |
| | Effect | P | Effect (SE) | P | Effect | P | Effect (SE) | P |
| Age at T1 (y) | -0.09 | .18 | | .60 | -0.11 | .06 | | .17 |
| Time T1 to T3 (mo) | 0.15 | <.05 | 0.15 (0.05) | <.05 | 0.04 | .53 | | .94 |
| Sex (male/female) | -0.06 | .36 | | .25 | -0.18 | <.01 | | |
| Previous treatment (yes/no) | -0.09 | .19 | | .23 | -0.13 | .06 | | .12 |
| Square wire (mo) | 0.05 | .42 | | .49 | 0.15 | <.05 | 0.15 (0.02) | <.05 |
| IRI (mm) | 0.06 | .34 | | .50 | -0.04 | .51 | | .79 |
| SPI (mm) | 0.07 | .31 | | .44 | 0.03 | .60 | | .53 |
| CDI (mm) | 0.08 | .25 | | .44 | -0.05 | .42 | | .97 |
| Tooth length (mm) | 0.13 | <.05 | 0.13 (0.01) | <.05 | 0.17 | <.05 | 0.15 (0.01) | <.05 |
| Trauma (yes/no) | 0.10 | .14 | | .07 | 0.05 | .42 | | .79 |
| Root width (mm) | -0.08 | .25 | | .52 | -0.21 | <.001 | -0.19 (0.01) | <.01 |
| Root form: | | | | | | | | |
| Normal (0) (yes/no) | -0.06 | .38 | | .31 | -0.10 | .13 | | .62 |
| Blunt (1) (yes/no) | -0.01 | .86 | | .83 | -0.01 | .89 | | .47 |
| Eroded (2) (yes/no) | 0.08 | .20 | | .96 | 0.07 | .24 | | .45 |
| Pointed (3) (yes/no) | 0.04 | .51 | | .55 | 0.11 | .09 | | .45 |
| Deviated (4) (yes/no) | 0.09 | .25 | | .43 | 0.08 | .21 | | .60 |
| Post elastics (mo) | 0.07 | .48 | | .44 | 0.08 | .53 | | .56 |

^a IRI indicates irregularity index; SPI, spacing index; and CDI, contact displacement index.

ing that maxillary lateral incisors experience resorption more than other teeth during orthodontic treatment^{1,3,4,13} may not be unexpected.

In keeping with previous studies,^{7,8,13} we found no indications that teeth with short, blunt roots are at increased risk of resorption. Although we could confirm atypical root form^{7,8} as a risk factor after six months of treatment,¹³ no such association was detected after 12 months. However, we could confirm our six-month observation of increased resorption with increased treatment time.¹³ Inconclusive findings in previous studies regarding total treatment time and amount of resorption at time of appliance removal^{3,5,7-9} may reflect lack of association between treatment time and time with appliance activity in later stages of treatment. In keeping with previous studies,^{3,7,9,13} the explained variance of the identified risk factors related to tooth morphology and treatment parameters was low, in this sample less than 10%.

The fact that about 5% of the patients in our sample had an averaged resorption of more than two mm and that almost 8% had at least one incisor with more than three mm resorption during the first 12 months of treatment may be of concern if the process proves to continue at a similar rate, particularly because the maximum resorption at the tooth level was more than six mm.

Our findings of a clinically significant association between the amount of resorption during the first and second six-month periods of active treatment suggest that patients at risk of severe resorption may be iden-

tified early in treatment. Our aim is to explore the predictive value of early signs of resorption in detail once all treatment is completed. Of particular significance may be the final amount of resorption among the 13.4% of the patients in our study with more than two mm resorption after six months¹³ and the 7.7% with more than three mm resorption after 12 months of treatment (Figure 5) of one or more incisors relative to the patients with minimal amount of resorption during the initial treatment stages.

The patients in our study were recruited from three different centers in different countries. Regardless of possible racial differences and any differences in treatment mechanics, no differences in resorption were detected among the subsamples, justifying our combining the patients to one group for the statistical analyses.

CONCLUSIONS

- Root resorption can be detected in the early stages of orthodontic treatment.
- About 5% of the patients have an averaged amount of resorption of two mm or more of the four maxillary incisors, and almost 8% have one or more maxillary incisor with resorption of three mm or more at an average of about 12 months after initiation of fixed appliance therapy.
- The low explained variance of identified risk factors related to tooth morphology and treatment parameters combined with the strong association between

amount of resorption during the first and second six-month treatment period strongly suggest individual predisposition as the major etiological factor.

ACKNOWLEDGMENT

This research was supported by Kuwait University Grant DD02/00.

REFERENCES

1. Mirabella AD, Årtun J. Prevalence and severity of apical root resorption of maxillary anterior teeth in adult orthodontic patients. *Eur J Orthod.* 1995;17:93-99.
2. Linge BO, Linge L. Apical root resorption in upper and anterior teeth. *Eur J Orthod.* 1983;5:173-183.
3. Linge L, Linge BO. Patient characteristics and treatment variables associated with apical root resorption during orthodontic treatment. *Am J Orthod Dentofacial Orthop.* 1991;99:35-43.
4. Sameshima GT, Sinclair PM. Predicting and preventing root resorption: Part I. Diagnostic factors. *Am J Orthod Dentofacial Orthop.* 2001;119:505-510.
5. Kaley J, Phillips C. Factors related to root resorption in edgewise practice. *Angle Orthod.* 1991;61:125-132.
6. Remington DN, Joondeph DR, Årtun J, Riedel RA, Chapko MK. Long term evaluation of root resorption occurring during orthodontic treatment. *Am J Orthod Dentofacial Orthop.* 1989;96:43-46.
7. Mirabella AD, Årtun J. Risk factors for apical root resorption of maxillary anterior teeth in adult orthodontic patients. *Am J Orthod Dentofacial Orthop.* 1995;108:48-55.
8. Sameshima GT, Sinclair PM. Predicting and preventing root resorption: Part II. Treatment factors. *Am J Orthod Dentofacial Orthop.* 2001;119:511-515.
9. Taithongchai R, Sookkorn K, Killiany DM. Facial and dentoalveolar structure and the prediction of apical root shortening. *Am J Orthod Dentofacial Orthop.* 1996;110:296-302.
10. Spurrier SW, Hall SH, Joondeph DR, Shapiro PA, Riedel RA. A comparison of apical root resorption during orthodontic treatment in endodontically treated and vital teeth. *Am J Orthod Dentofacial Orthop.* 1990;97:130-134.
11. Kjær I. Morphological characteristics of dentitions developing excessive root resorption during orthodontic treatment. *Eur J Orthod.* 1995;16:25-34.
12. Lee RY, Årtun J, Alonzo TA. Are dental anomalies risk factors for apical root resorption in orthodontic patients? *Am J Orthod Dentofacial Orthop.* 1999;116:187-195.
13. Smale I, Årtun J, Behbehani F, Doppel D, Van't Hof M, Kuijpers-Jagtman AM. Apical root resorption six months after initiation of fixed appliance therapy. *Am J Orthod Dentofacial Orthop.* In press.
14. Little RM. The irregularity index: a quantitative score of mandibular anterior alignment. *Am J Orthod.* 1975;68:554-563.
15. Reukers E, Sanderink G, Kuijpers-Jagtman AM, Van't Hof M. Assessment of apical root resorption using digital reconstruction. *Dentomaxillofac Radiol.* 1998;27:25-29.
16. Dahlberg G. *Statistical methods for medical and biological students.* London: George Allen and Unwin Ltd; 1940:122-132.