

Research Article

Application of *Antrodia camphorata* Promotes Rat's Wound Healing *In Vivo* and Facilitates Fibroblast Cell Proliferation *In Vitro*

Zahra A. Amin,¹ Hapipah M. Ali,² Mohammed A. Alshawsh,³
Pouya H. Darvish,⁴ and Mahmood A. Abdulla⁵

¹Department of Pharmacognosy, College of Pharmacy, Hawler Medical University, Erbil 44001, Iraq

²Department of Chemistry, Faculty of Science, University of Malaya, 50603 Kuala Lumpur, Malaysia

³Department of Pharmacology, Faculty of Medicine, University of Malaya, 50603 Kuala Lumpur, Malaysia

⁴Department of Microbiology, Faculty of Medicine, University of Malaya, 50603 Kuala Lumpur, Malaysia

⁵Department of Biomedical Science, Faculty of Medicine, University of Malaya, 50603 Kuala Lumpur, Malaysia

Correspondence should be addressed to Mahmood A. Abdulla; ammeen@um.edu.my

Received 21 April 2015; Revised 15 August 2015; Accepted 23 August 2015

Academic Editor: Shuang-En Chuang

Copyright © 2015 Zahra A. Amin et al. This is an open access article distributed under the Creative Commons Attribution License, which permits unrestricted use, distribution, and reproduction in any medium, provided the original work is properly cited.

Antrodia camphorata is a parasitic fungus from Taiwan, it has been documented to possess a variety of pharmacological and biological activities. The present study was undertaken to evaluate the potential of *Antrodia camphorata* ethanol extract to accelerate the rate of wound healing closure and histology of wound area in experimental rats. The safety of *Antrodia camphorata* was determined *in vivo* by the acute toxicity test and *in vitro* by fibroblast cell proliferation assay. The scratch assay was used to evaluate the *in vitro* wound healing in fibroblast cells and the excision model of wound healing was tested *in vivo* using four groups of adult *Sprague Dawley* rats. Our results showed that wound treated with *Antrodia camphorata* extract and intrasite gel significantly accelerates the rate of wound healing closure than those treated with the vehicle. Wounds dressed with *Antrodia camphorata* extract showed remarkably less scar width at wound closure and granulation tissue contained less inflammatory cell and more fibroblast compared to wounds treated with the vehicle. Masson's trichrom stain showed granulation tissue containing more collagen and less inflammatory cell in *Antrodia camphorata* treated wounds. In conclusion, *Antrodia camphorata* extract significantly enhanced the rate of the wound enclosure in rats and promotes the *in vitro* healing through fibroblast cell proliferation.

1. Introduction

A wound can be described as the disruption of the typical anatomical shape and physiological function of a tissue. Wounds may arise due to physical, chemical, or microbial agents. Wound healing process is a dynamic procedure which consists of three main stages including inflammation, proliferation, and tissue remodeling. In the inflammation stage platelets aggregates, blood clots, and subsequently phagocytosis and vasodilatation occur. The proliferation stage (active growth stage) includes tissue granulation and epithelialization, while the remodeling stage (reconstruction stage) involves maturation and remodeling of the scar tissue [1].

Natural products have been proven to enclose wound healing property and their primary or secondary metabolites have been shown to contribute potential repair mechanisms including activation of immune epithelial cells, cytokines, extracellular matrix (ECM), reactive oxygen species (ROS), growth factors, and different inflammatory mediators [2]. In the literature, a huge number of medicinal mushrooms and plant extracts with wound healing potential have been reported by several authors [3–6].

Antrodia camphorata, a Basidiomycete fungus from Taiwan [7], from family Polyporaceae, has been used widely in the Taiwanese traditional medicine for the treatment of several diseases such as hypertension, abdominal pain, diarrhea, and skin itches and as remedy for drug and food

intoxication [8]. It is rare in nature and very costly because it has host specificity as it grows only on the inner wood wall of *Cinnamomum kanehirai* tree and it has failed to be cultivated artificially [9]. Prior research has documented that *Antrodia camphorata* possesses a variety of pharmacological functions like anti-inflammatory, antioxidant [10, 11], antiproliferative [12], antimetastatic (of bladder cancer) [13], anti-hepatitis B virus, vasorelaxative [14], anti-hepatocellular carcinoma [15], and anti-breast cancer [16] effects. The bioactive constituents of *Antrodia camphorata* have been analyzed including steroid, sesquiterpene lactone, triterpenoids, and polysaccharide and their biological activities were documented [17, 18].

No literature was found concerning the activity of *Antrodia camphorata* as a wound healing agent. Therefore, this study aimed to evaluate the ability of topical application *Antrodia camphorata* extract in accelerating wound healing *in vivo* in Sprague Dawley rats and to study whether *Antrodia camphorata* facilitates the *in vitro* wound healing process by fibroblast cell line proliferation.

2. Experimental Methods

2.1. Chemicals. Intracite gel (Smith and Nephew Healthcare Ltd., UK), an amorphous gel, containing 2.3% of a modified carboxymethyl cellulose (CMC) polymer with propylene glycol (20%), was used as the reference control. Acacia Arabic gum (Sigma Aldrich, USA), a complex mixture of polysaccharides and glycoproteins, was used as the vehicle control after dissolving in normal saline as described by Zahra et al. [19]. MTT reagent (3-(4,5-dimethylthiazol-2-yl)-2,5-diphenyltetrazolium bromide) was purchased from Merck, Germany. Green bean extracted powder of *Antrodia camphorata* was purchased from Bio-Herb Biotech. Co., Ltd., Taiwan.

2.2. Preparation of *Antrodia camphorata* Extract for Topical Application of Wounds. *Antrodia camphorata* extract was dissolved by using the vehicle, gum acacia, in normal saline as described by Zahra et al. [19]. Two grams of gum acacia was dissolved in 100 mL of normal saline. From this, 10 mL of solution, which contains 200 mg of gum acacia, was used for dissolving 1 gm and 2 gm of *Antrodia camphorata* extract each. So one mL of each solution contains 100 and 200 mg of *Antrodia camphorata* extract, respectively.

2.3. In Vivo Wound Healing (Excision Model). Sprague Dawley adult male rats were randomly divided into 4 groups of 6 rats each. Each rat that weighed between 180 and 200 gm was housed separately (one rat per cage). The animals were maintained on standard pellet diet and tap water. The animals were anesthetized by light dosage of ketamin and xylazine anesthesia. The skin shaved by electrical shaver, disinfected with 70% alcohol. An area of uniform wound 2.00 cm in diameter was excised from the nape of the dorsal neck of all rats with the aid of round seal as described by [1]. 0.2 mL of vehicle (gum acacia) was applied topically to the wounds of

Group 1 rats twice a day. Group 2 rats were topically dressed twice daily with 0.2 mL of 100 mg/mL of *Antrodia camphorata* extract, and Group 3 rats were dressed twice daily with 0.2 mL of 200 mg/mL *Antrodia camphorata* extract. Group 4 rats were dressed twice daily with 0.2 mL of 200 mg/kg reference drug (Intrasite gel) *Antrodia camphorata* extract. The contraction of the wound area was measured. Wound areas were traced manually and calculated in square millimeters. The wound closure area of each animal was assessed by tracing the wound at days 0, 7, and 14 after wounding surgery and the wound closure rate was expressed as the percentage of wound area compared with that on postoperative day by using transparency paper and a permanent marker under general anesthesia (a mixture of Ketamine and Xylazil) as described by Abdulla et al. [3].

The wound areas recorded were measured using a graph paper. The percent wounds healing on these days are determined. Number of days required for falling of scar without any residual raw wound gave the period of epithelization. The wound area was measured immediately by placing a transparent tracing paper over the wound and tracing it out. The tracing paper was placed on 1 mm² graph sheet and traced out. The squares were counted and the area recorded.

Then the percentage of wound closure was calculated following the formula:

$$\text{Wound closure (\%)} = 1 - \left(\frac{A_d}{A_0} \right) * 100, \quad (1)$$

where A_0 is wound area at day zero and A_d is wound area on corresponding day [20].

For assessing the histological observations of the healed wounds, the skin specimens from wounds healed areas were fixed in 10% buffered formalin and processed by paraffin tissue processing machine. The healed skin was assessed by taking a 5 μ m section followed by staining with hematoxylin and eosin and Masson's trichrome stains and examined using an Olympus light microscope. The evaluated parameters were epithelialization, inflammatory cell infiltration, fibroblast proliferation, neovascularization, and collagen deposition, which were assessed generally whether absent, present, or abundant.

The wound tissue homogenate from each rat was prepared at 4°C by using a Teflon homogenizer (Polytron, Germany). After centrifugation at 4,500 rpm for 15 min at 4°C, the supernatant was used for nitric oxide (NO) and hydroxyproline (HXP) determinations. The NO levels of the wound tissues were measured using the NO assay kit (Cayman Chemical Co., USA). The HXP assay kit from (Sigma Aldrich, USA) was used to test the wound tissues HXP levels.

2.4. In Vitro Wound Healing. Before evaluating the wound healing activity of *Antrodia camphorata* on human fibroblast cell lines, the MTT assay was performed to study its cytotoxicity. Cells were grown in DMEM medium (Dulbecco's Modified Eagle's Medium with 4500 mg glucose/L, 110 mg sodium pyruvate/L, and L-glutamine (from Sigma Aldrich,

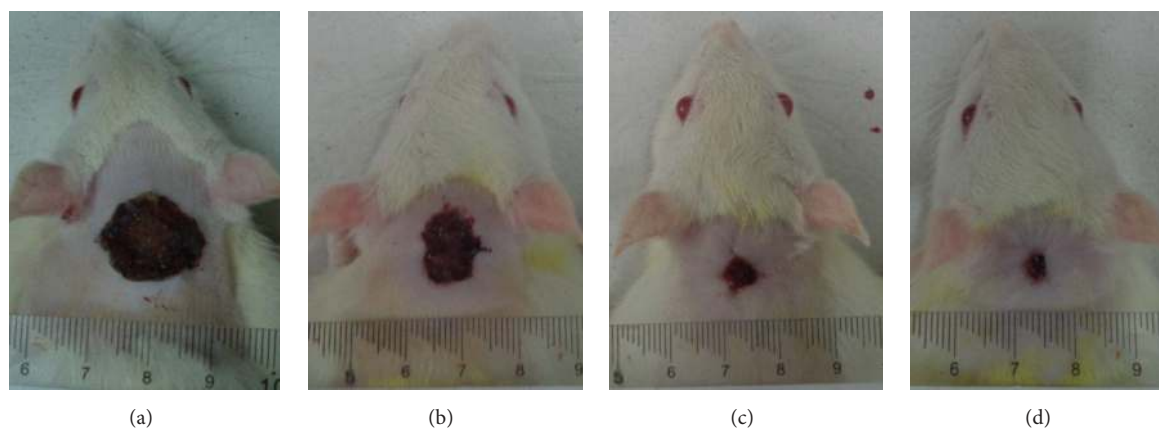


FIGURE 1: Macroscopic appearance of wound healing at day 14 after surgery: (a) rats treated with 0.2 mL gum acacia show wide wound closure area; (b) rats treated with 100 mg/mL of *Antrodia camphorata* show remarkably moderate wound closure area compared to vehicle; (c) rats treated with 200 mg/mL of *Antrodia camphorata* show remarkably smaller wound closure area compared to vehicle; (d) rats treated with Intracel gel show smaller wound closure area compared to vehicle.

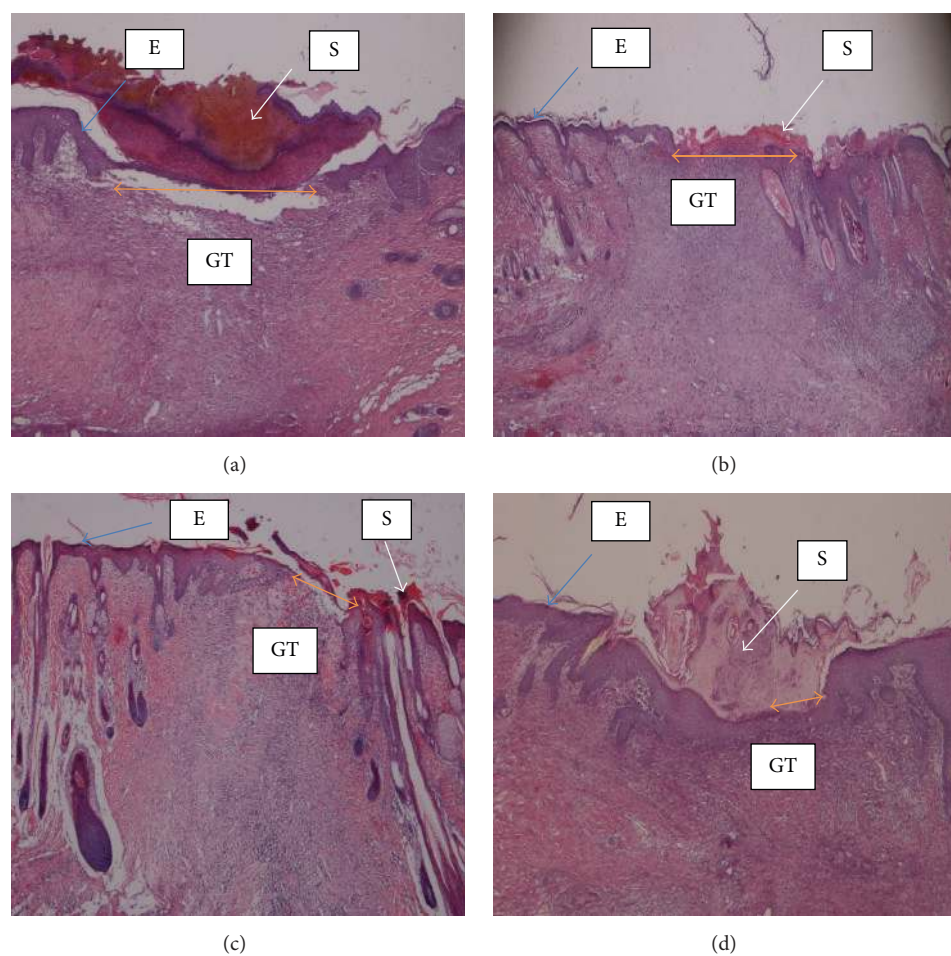


FIGURE 2: Histology of wound tissue at day 14 after wounding in rats, stained with hematoxylin and eosin and dressed with (a) 0.2 mL of vehicle, gum acacia, wide wound area (orange arrow); (b) 0.2 mL of *Antrodia camphorata* (100 mg/mL) moderate wound area compared to vehicle; (c) 0.2 mL of *Antrodia camphorata* (200 mg/mL), smaller wound area compared to vehicle (orange arrow); (d) 0.2 mL of Intracel gel, very small wound area compared to vehicle (orange arrow). S = scab, E = epidermis, and GT = granulation tissue (magnification 20x).

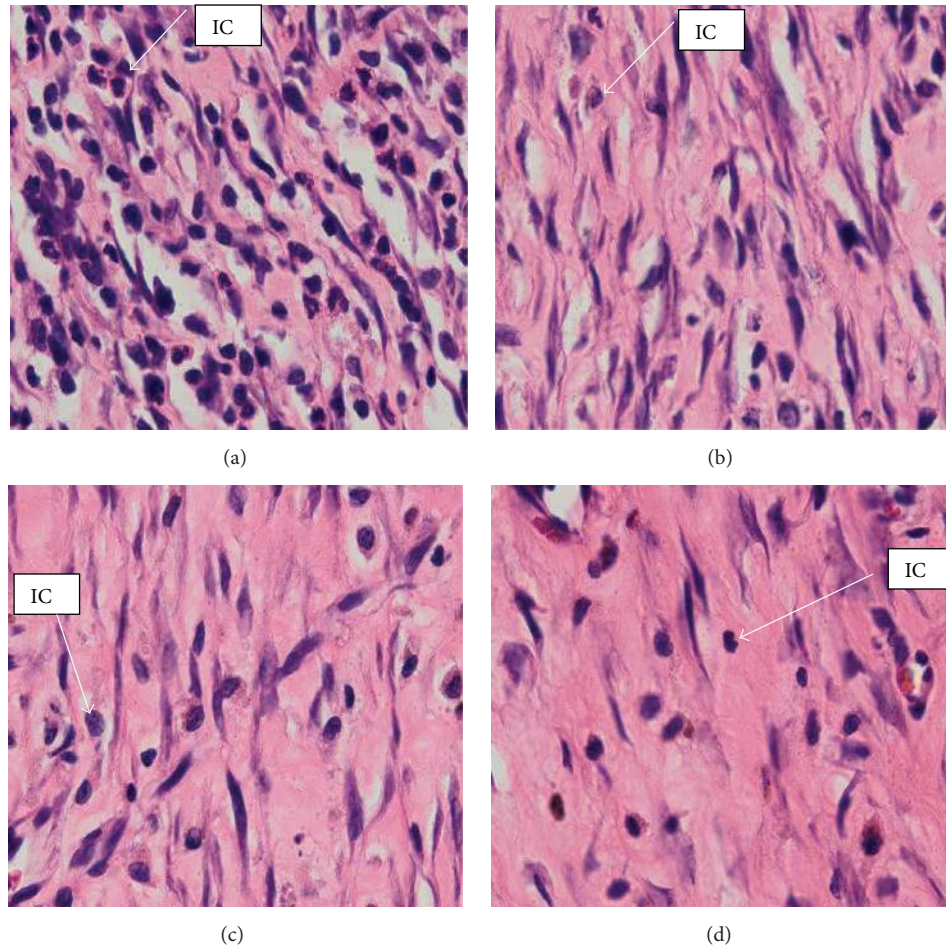


FIGURE 3: High magnification of histology of wound granulation tissue stained with hematoxylin and eosin, at day 14 after wounding in rats dressed with (a) 0.2 mL of vehicle, gum acacia, more inflammatory cells and less fibroblast and collagen; (b) 0.2 mL of *Antrodia camphorata* (100 mg/mL), remarkably less inflammatory cells and more fibroblast and collagen compared to vehicle; (c) 0.2 mL of *Antrodia camphorata* (200 mg/mL), remarkably less inflammatory cells and more fibroblast and collagen compared to vehicle; (d) 0.2 mL of Intrasisite gel, remarkably more collagen fibers and fibroblasts, with less inflammatory cells compared to vehicle. IC = inflammatory cells (H&E stains, 100x magnification).

TABLE 1: Effect of *Antrodia camphorata* extract on percentage (%) wound healing in experimental rats.

Groups	Doses	Day 0		Day 7		Day 14	
		Twice daily	Wound area mm ²	Wound area mm ²	Closure %	Wound area mm ²	Closure %
Gum acacia	0.2 mL/kg		340.00 ± 4.36	180.33 ± 8.69	47.06	76.00 ± 8.33	77.65
<i>Antrodia camphorata</i>	100 mg/kg		338.33 ± 3.71	149.67 ± 6.17*	55.92*	37.00 ± 5.57*	89.05*
	200 mg/kg		337.67 ± 4.84	146.33 ± 4.91*	56.68*	33.67 ± 4.81*	90.21*
Intrasite gel	0.2 mL/kg		336.67 ± 4.84	129.33 ± 6.98*	61.61*	36.67 ± 7.45*	89.29*

Statistical analysis of the data was carried out using one-way analysis of variance (ANOVA) and Tukey's post hoc test for average comparison on SPSS 18.0. Mean values ± SEM were used. Significance was defined as $P < 0.05$ compared to gum acacia group.

USA)), supplemented with 10% fetal bovine serum (Sigma Aldrich, USA) at 37°C under 5% CO₂ in a humidified IR Jacketed incubator (from NUAIRE laboratory equipment supply, USA). Cells were counted (0.5×10^5 cells/mL) and transmitted into a 96-well plate and incubated for 48 hours before adding the *Antrodia camphorata* extracts. Serial dilutions of extracts were prepared by using distilled water and

0.25% DMSO as solvents to give final concentrations of 100, 50, 25, 12.5, 6.25, and 3.125 µg/mL and then 10 µL was injected to each well and incubated for 48 hours. 10 µL of MTT (Merck, Germany) solution was added and incubated at 37°C for four hours. Thus the solution was took out by suction and 100 µL of DMSO was added to each well and then the absorbance was recorded by the ELISA plate reader

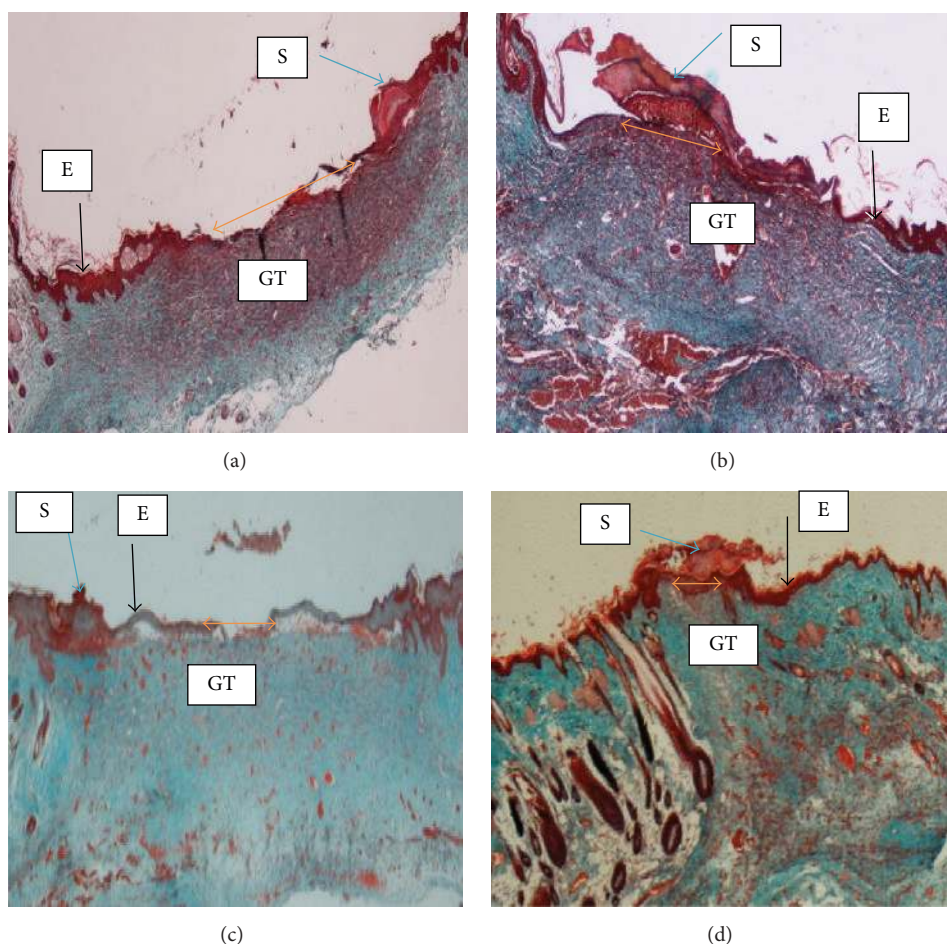


FIGURE 4: Histological sections of wound tissue stained with Masson's trichrome at day 14 after wounding in rats topically dressed with (a) 0.2 mL of vehicle, gum acacia, showed remarkably wide wound closure area (orange arrow) and granulation tissue (GT) contained less collagen deposition. (b) 0.2 mL of *Antrodia camphorata* (100 mg/mL) showed remarkably moderate wound closure and granulation tissue contained less collagen deposition. (c) 0.2 mL of *Antrodia camphorata* (200 mg/mL) showed narrow wound closure area and thin epidermis and granulation tissue contained remarkably more collagen deposition compared to vehicle group. (d) 0.2 mL of Intracel gel showed very narrow wound closure area and granulation tissue contained remarkably more collagen deposition compared to vehicle group. S = scab, E = epidermis, and GT = granulation tissue (magnification 20x).

(PowerWave X340, BIO-TEK Instruments Ltd.) at 595 nm. The percentage of cell growth inhibition was calculated as

$$\% \text{ Cell viability} = \left(\frac{\text{abs of extract sample} - \text{abs of control}}{\text{abs of control}} \right) \times 100. \quad (2)$$

Moreover, the *in vitro* wound healing assay was performed using the CytoSelect wound healing assay kit (Cell Biolabs, Inc., USA) [21] in which proprietary inserts were used to generate a defined wound gap (0.9 mm), and then cells were cultured (0.5×10^6 cells/mL) in media containing 10% fetal bovine serum (FBS) and incubated for 48 hrs until a monolayer was formed around the inserts. The inserts were removed and cells were treated with the experimental samples (200 $\mu\text{g/mL}$) and incubated for 48 hrs. The migration and

proliferation of the cells into the wound field were monitored and then the wound percent closure was measured as

$$\begin{aligned} \text{Total surface area} &= 0.9 \text{ mm} \times \text{length} \\ \text{Migrated cell surface area} &= \text{length of cell migration (mm)} \times 2 \times \text{length} \\ \text{Percent closure (\%)} &= \frac{\text{migrated cell surface area}}{\text{total surface area}} \times 100. \end{aligned} \quad (3)$$

2.5. Chemical Analysis. 500 gm of the fine powder of *Antrodia camphorata* was sent to the Consolidated Laboratory (M) Sdn. Bhd., for the analysis of the minerals, fats, and elemental compositions.




FIGURE 5: High magnification of wound granulation tissue stained with Masson's trichrome at day 14 after wounding in rats dressed with (a) 0.2 mL of vehicle, gum acacia, showed more inflammatory cells and less fibroblast and collagen deposition. (b) 0.2 mL of *Antrodia camphorata* (100 mg/mL) showed remarkably less inflammatory cells and moderately more fibroblast and collagen deposition compared to vehicle group. (c) 0.2 mL of *Antrodia camphorata* (200 mg/mL) showed remarkably less inflammatory cells and more fibroblast and collagen deposition compared to vehicle group. (d) 0.2 mL of Intracel gel showed remarkably more collagen fibers and fibroblasts and less inflammatory cells compared to vehicle group. C = collagen, IC = inflammatory cells, and BV = blood vessels (100x magnification).

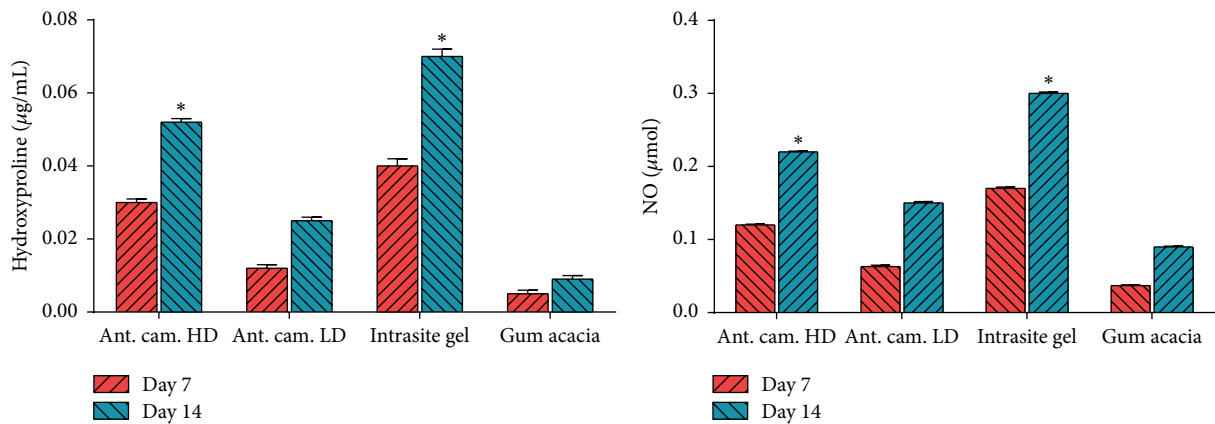


FIGURE 6: Hydroxyproline (HXP) and nitric oxide (NO) levels in healed skin homogenates treated with 2% gum acacia, Intracel gel, *Antrodia camphorata* LD (low dose 100 mg/kg), and *Antrodia camphorata* HD (high dose 200 mg/kg). * indicates significance when $P < 0.05$.

TABLE 2: Chemical analysis of *Antrodia camphorata*'s extract.

Test parameter	Result	Unit
Energy	373	kcal/100 gm
Total fat	1.4	gm/100 gm
Carbohydrate	83.5	gm/100 gm
Protein	6.6	gm/100 gm
Cholesterol	<0.001	mg/100 gm
Dietary fibre	67.5	gm/100 gm
Monosaturated fat	0.1	gm/100 gm
Polysaturated fat	0.75	gm/100 gm
Saturated fat	0.54	gm/100 gm
Transfat	<0.01	gm/100 gm
Phosphorus (P)	285.82	mg/100 gm
Potassium (K)	724.4	mg/100 gm
Sodium (Na)	142.81	mg/100 gm
Zinc (Zn)	0.62	mg/100 gm
Calcium (Ca)	84.72	mg/100 gm
Copper (Cu)	0.13	mg/100 gm
Iron (Fe)	0.98	mg/100 gm
Magnesium (Mg)	51.05	mg/100 gm
Manganese (Mn)	0.33	mg/100 gm
Selenium (Se)	0.03	mg/100 gm

2.6. Acute Toxicity Test. The acute toxicity test was used to determine the safety of *Antrodia camphorata* extract when administered by oral gavage to rats at single doses of 2 gm/kg following OECD-423 guidelines [22]. In brief, thirty-six healthy Sprague Dawley rats (18 males and 18 females) were randomly assigned equally into 3 groups each labeled as vehicle (dH₂O), low dose 2 gm/kg, and high dose 5 gm/kg of *Antrodia camphorata* extract, respectively. Each rat was made to fast (no food but water) overnight prior to dosing. Food was withheld for another 3 to 4 hours after the dosing. The rats were closely observed for 30 minutes and at 2, 4, 24, and 48 hours after the dosing to detect if there were any acute signs of clinical toxicity, morbidity, and mortality twice daily. Comparisons were verified between the individual animals and their respective vehicle treated animals. Detailed behavioral observations include respiration (dyspnea), salivation, skin piloerection, exophthalmos, convulsion, and locomotion changes. After keeping them alive for 14 days, at day 15, the rats were sacrificed to measure serum biochemical and (liver and kidney) histological parameters following the standard methods [23].

2.7. Statistical Analysis. All values are reported as mean \pm SEM. and the statistical significance of differences among groups was assessed using one-way ANOVA. A value of $P < 0.05$ was considered significant.

3. Results and Discussion

3.1. In Vivo Wound Healing (Excision Model). Wounds dressed with *Antrodia camphorata* or Intrasisite gel showed considerable signs of dermal healing and healed faster than

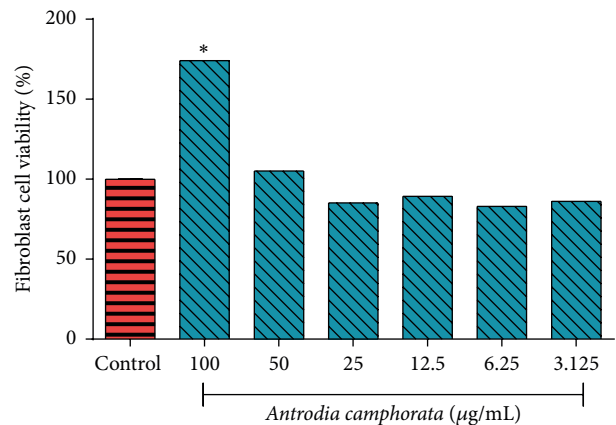


FIGURE 7: Effect of *Antrodia camphorata* on fibroblast cell viability. * indicates significance when $P < 0.05$.

the vehicle group (gum acacia). Table 1 shows the effects of *Antrodia camphorata* extract on the percentage of wound healed at days after surgery. Throughout the experiment, the percentage of healing in the vehicle control group wounds was significantly lower than those of *Antrodia camphorata* extract-treated groups and Intrasisite gel wounds (Figure 1 and Table 1). In both stains (H&E and Masson's trichrome) histology of wound area at day 14 after surgery showed that wound dressed with *Antrodia camphorata* extract showed comparatively less scar width at wound closure compared to the vehicle treated group (Figures 2, 3, 4, and 5), and the granulation tissue of wound area contained remarkably few inflammatory cells and more collagen and proliferating blood capillaries (angiogenesis) compared with vehicle treated group.

The results of the current study showed that *Antrodia camphorata* topically dressed significantly accelerated the rate of wound healing, and histology of wound contained remarkably less inflammatory cells, more collagen, and angiogenesis. With the agreement to our results enhanced wound healing activity may be attributed to collagen synthesis and angiogenesis [3, 24]. In granulation region of wound tissues angiogenesis improves blood circulation to the wound area therefore providing oxygen and nutrients vital for the wound curing process [4, 25] which consist of reepithelization. Wound healing mechanisms may be attributed to motivating the manufacture of antioxidants in wound location and provide encouraging background for tissue healing [3, 24]. Antioxidants play an important part in the course of wound curing by improving the curative time and the manifestation of the healed tissue, while defensive tissues from oxidative injury [3, 5, 6]. The wound healing achievement of *Antrodia camphorata* may be due to the antioxidant present in the *Antrodia camphorata* and also elevated free radical scavenging action. The reactive oxygen species and free radicals formed throughout tissue injury are potentially concerned in late wound curing [3, 5, 6]. Moreover, the effects of *Antrodia camphorata* on hydroxyproline and nitric oxide contents were shown in Figure 6 in which it is obvious that treatment with the reference control (Intrasisite gel) significantly increased the

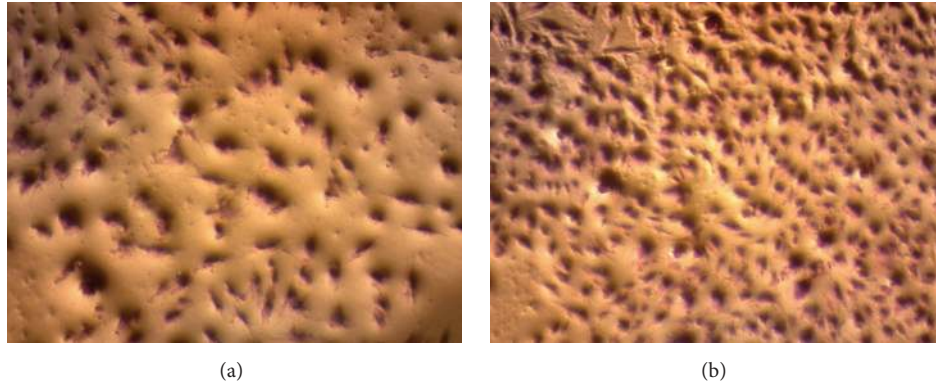


FIGURE 8: Light microscope images of the effect of *Antrodia camphorata* on fibroblast cell viability and proliferation. (a) Fibroblast cell with no treatments and (b) fibroblast cell after treatment with *Antrodia camphorata*.

TABLE 3: Renal function test of male rats in acute toxicity study of *Antrodia camphorata* extract.

Dose	Sodium (mmol/L)	Potassium (mmol/L)	Chloride (mmol/L)	CO ₂ (mmol/L)	Anion gap (mmol/L)	Urea (mmol/L)	Creatinine (μmol/L)
Vehicle	141.08 ± 0.88	4.87 ± 0.087	105.21 ± 1.85	24.87 ± 0.85	18.18 ± 0.57	5.55 ± 0.48	34.85 ± 2.35
AC/LD (2 gm/kg)	142.05 ± 1.67	5.03 ± 0.07	106.33 ± 1.06	24.66 ± 1.19	18.17 ± 0.65	6.24 ± 0.52	33.60 ± 2.68
AC/HD (5 gm/kg)	142.52 ± 0.89	4.98 ± 0.08	105.25 ± 1.68	23.97 ± 1.07	18.56 ± 0.58	5.673 ± 0.59	34.53 ± 4.92

Values expressed as mean ± SEM. There are no significant differences between groups. AC/LD = *Antrodia camphorata* low dose group and AC/HD = *Antrodia camphorata* high dose group.

collagen content represented as high level of hydroxyproline in comparison to the decreased levels of the vehicle control group (gum acacia). Treatment with this mushroom extract significantly increased the hydroxyproline levels and also the treatment with *Antrodia camphorata* increased the level of nitric oxide as compared to the vehicle group as shown in Figure 6.

Moreover, this study showed that *Antrodia camphorata* was able to accelerate the wound healing process *in vivo* in doses of 100 mg/kg and 200 mg/kg based on the macroscopic and microscopic findings; also the high content of hydroxyproline (HXP) and nitric oxide (NO) proves that the effect of *Antrodia camphorata* extract on an excision wound model was significantly greater than that of the vehicle itself. These results were with the consistence of the previous studies published elsewhere [4, 5]. A previous study has shown that healing can be accelerated and enhanced by the use of specific wound dressing or care product and techniques and that it is not a passive process [26]. It has been observed that plant constituents can significantly accelerate the healing process and improve the quality of wound healing [4]. Numerous studies have shown that plant compounds could potentially be therapeutic agents to treat wounds [4, 6, 27, 28]. The findings of this study are also in line with previous studies of Abdulla et al. and Hajiaghaalipour et al. who reported that various plant extracts showed high potential in wound healing activity [3, 6].

3.2. In Vitro Wound Healing. Figure 7 shows that *Antrodia camphorata* extract has remarkable activity on fibroblast cell proliferation. The cell viability increased after treatment; it is

clear that the extract is not potentially toxic to the skin cells and it is proliferating their growth as shown in Figure 8.

Moreover, the effectiveness of *Antrodia camphorata* on *in vitro* wound closure was assessed by scratch assay in which the level of cellular fill within the wound area in response to *Antrodia camphorata* was recoded (Figure 9). Percentage of cells in the wound area was 60 ± 1.9 and 85 ± 3.4 after 24 and 48 hours of treatment, respectively.

Our results have proved that the application of *Antrodia camphorata* promotes the wound healing process *in vitro* by proliferating the growth of fibroblast cells. These results are supported by the study of Walter et al. [29] who revealed that in the *in vitro* wound healing process the fibroblast and keratinocyte cells migrate to the wound closure area and extracellular matrix was formed. Another *in vitro* study demonstrated that fibroblast cells cause tissue repair and fibrosis through different signaling pathways as a response to a tissue damage [30].

3.3. Chemical Analysis. The chemical analysis of *Antrodia camphorata* extract is shown in Table 2. The crude extract contains high phosphorus (285.82 mg/100 gm) and sodium (142.81 mg/100 gm) and is rich in energy (373 kcal/100 gm) and potassium (724 mg/100 gm). The high potassium content of *Antrodia camphorata* may represent the key mechanism of its wound healing activity since potassium channels modulate the mitogen-activated protein kinase (MAPK) signaling pathway and direct collagen synthesis and angiogenesis in wound healing [31]. Also potassium channels are important in the cell cycle control and they can influence cell proliferation and modulate cell cycle progression [32]. Moreover, most

TABLE 4: Renal function test of female rats in acute toxicity study of *Antrodia camphorata* extract.

Dose	Sodium (mmol/L)	Potassium (mmol/L)	Chloride (mmol/L)	CO ₂ (mmol/L)	Anion gap (mmol/L)	Urea (mmol/L)	Creatinine (μmol/L)
Vehicle	141.56 ± 1.48	4.68 ± 0.13	105.32 ± 0.68	23.34 ± 0.58	18.05 ± 0.38	7.95 ± 0.35	41.02 ± 2.75
AC/LD (2 gm/kg)	141.07 ± 1.65	4.73 ± 0.16	104.50 ± 0.78	22.97 ± 0.55	17.38 ± 0.49	7.98 ± 0.24	42.00 ± 4.76
AC/HD (5 gm/kg)	142.26 ± 1.57	4.59 ± 0.12	106.03 ± 0.83	21.88 ± 0.76	17.56 ± 0.50	8.31 ± 0.69	41.35 ± 3.15

Values expressed as mean ± SEM. There are no significant differences between groups. AC/LD = *Antrodia camphorata* low dose group and AC/HD = *Antrodia camphorata* high dose group.

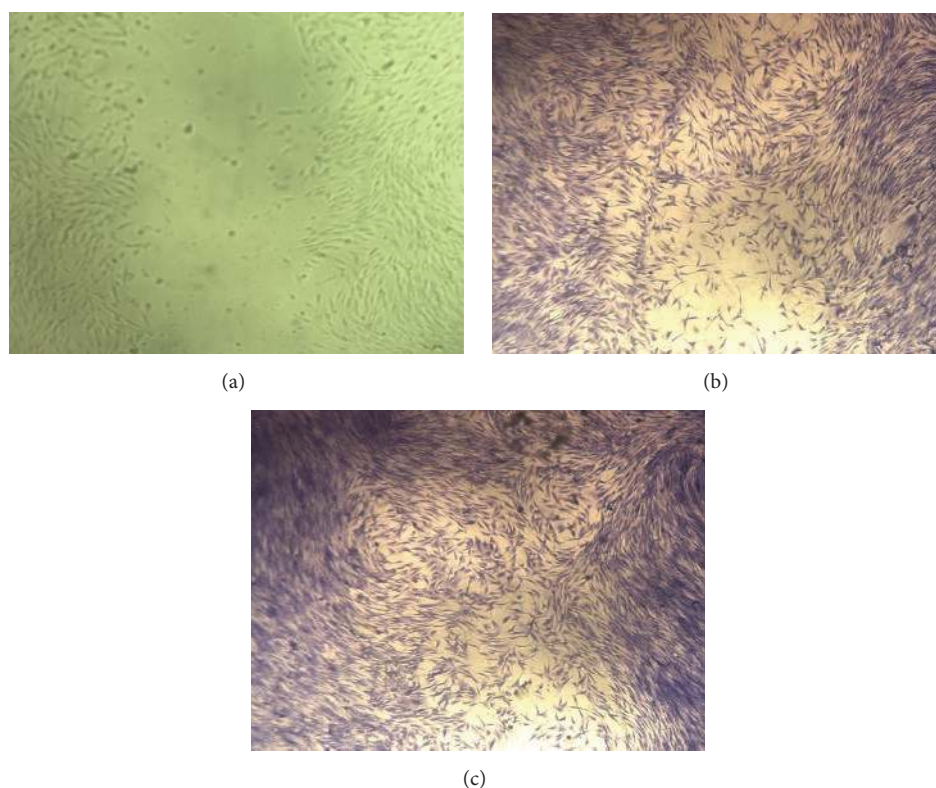


FIGURE 9: The percent closure of fibroblast cells after treatment with *Antrodia camphorata*: (a) wound area immediately after wounding (no stain), (b) wound area after 24 hours of treatment, and (c) wound area after 48 hours of treatment.

electrolytes presented in Table 2 such as sodium, potassium, calcium, and magnesium have been reported as the most important electrolytes of the wound healing process [33].

3.4. Acute Toxicity. The experimental rats were pretreated with a dose of 2 gm/kg and 5 gm/kg of *Antrodia camphorata*. The animals were carefully observed for 14 days. During the observation period, animals remain living with active healthy condition and there were no obvious toxicity signs. There were no macroscopic abnormalities at any times of observation and no cases of death were recorded. The animals were sacrificed, and the blood biochemical tests and histopathology tests were made. The results obtained from blood biochemical tests and histopathology tests did not demonstrate any difference between the treated groups and the control group as shown in Figure 10 and Tables 3, 4, 5, and 6 suggesting that *Antrodia camphorata* was safe in oral acute toxicity test even at these high doses.

The results of the present study revealed that *Antrodia camphorata* is safe when administered orally in doses 2 gm/kg and 5 gm/kg because none of the animals produced toxic signs and symptoms and none died during the study period. During topical application of *Antrodia camphorata*, the rats did not show any signs of irritation, pain, restlessness, and biting of wound area. Moreover there were no significant differences in biochemical parameters of liver and kidney and the values are within normal range. Histology revealed no nephrotoxic or hepatotoxic effect. Similarly, large numbers of medicinal mushrooms and plant extracts with potential wound healing activity which have no hepatotoxic or nephrotoxic effects on laboratory animals have been reported by several authors [3, 5, 6].

4. Conclusion

Antrodia camphorata showed high potential in wound healing activity, especially at higher concentrations. The

TABLE 5: Liver function test of male rats in acute toxicity study of *Anetrodia camphorata* extract.

Dose	Total protein (gm/L)	Albumin (gm/L)	Globulin (gm/L)	TB (μ mol/L)	CB (μ mol/L)	AP (IU/L)	ALT (IU/L)	AST (IU/L)	GGT (IU/L)
Vehicle	61.17 \pm 1.08	9.35 \pm 0.57	51.19 \pm 1.35	2.33 \pm 0.19	1.00 \pm 0.00	153.81 \pm 15.05	50.51 \pm 1.72	173.55 \pm 7.37	3.17 \pm 0.27
AC/LD (2 gm/kg)	58.92 \pm 0.84	8.64 \pm 0.39	49.78 \pm 0.89	2.15 \pm 0.17	1.00 \pm 0.00	156.06 \pm 15.27	48.52 \pm 0.89	174.58 \pm 5.86	3.65 \pm 0.54
AC/HD (5 gm/kg)	60.08 \pm 1.05	9.73 \pm 0.48	50.11 \pm 1.07	2.09 \pm 0.14	1.00 \pm 0.00	155.15 \pm 10.13	47.58 \pm 1.78	175.84 \pm 8.52	3.27 \pm 0.42

Values expressed as mean \pm SEM. There are no significant differences between groups. TB: total bilirubin; CB: conjugated bilirubin; AP: alkaline phosphatase; ALT: alanine aminotransferase; AST: aspartate aminotransferase; GGT: G-Glutamyl Transferase. AC/LD = *Anetrodia camphorata* low dose group and AC/HD = *Anetrodia camphorata* high dose group.

TABLE 6: Liver function test of female rats in acute toxicity study of *Antrodia camphorata* extract.

Dose	Total protein (gm/L)	Albumin (gm/L)	Globulin (gm/L)	TB (μmol/L)	CB (μmol/L)	AP (IU/L)	ALT (IU/L)	AST (IU/L)	GGT (IU/L)
Vehicle	64.31 ± 1.26	11.25 ± 0.27	53.13 ± 1.28	2.00 ± 0.00	1.00 ± 0.00	10785 ± 6.36	43.28 ± 1.98	171.56 ± 6.82	3.75 ± 0.35
AC/LD (2 gm/kg)	63.53 ± 1.15	11.08 ± 0.56	52.33 ± 1.27	2.00 ± 0.00	1.00 ± 0.00	102.35 ± 4.98	40.85 ± 2.75	172.25 ± 8.66	3.54 ± 0.54
AC/HD (5 gm/kg)	65.11 ± 0.88	11.51 ± 0.46	53.18 ± 1.08	2.00 ± 0.00	1.00 ± 0.00	104.82 ± 5.36	44.12 ± 1.89	174.84 ± 5.84	3.01 ± 0.38

Values expressed as mean ± SEM. There are no significant differences between groups. TB: total bilirubin; CB: conjugated bilirubin; AP: alkaline phosphatase; ALT: alanine aminotransferase; AST: aspartate aminotransferase; GGT: G-Glutamyl Transferase. AC/LD = *Antrodia camphorata* low dose group and AC/HD = *Antrodia camphorata* high dose group.

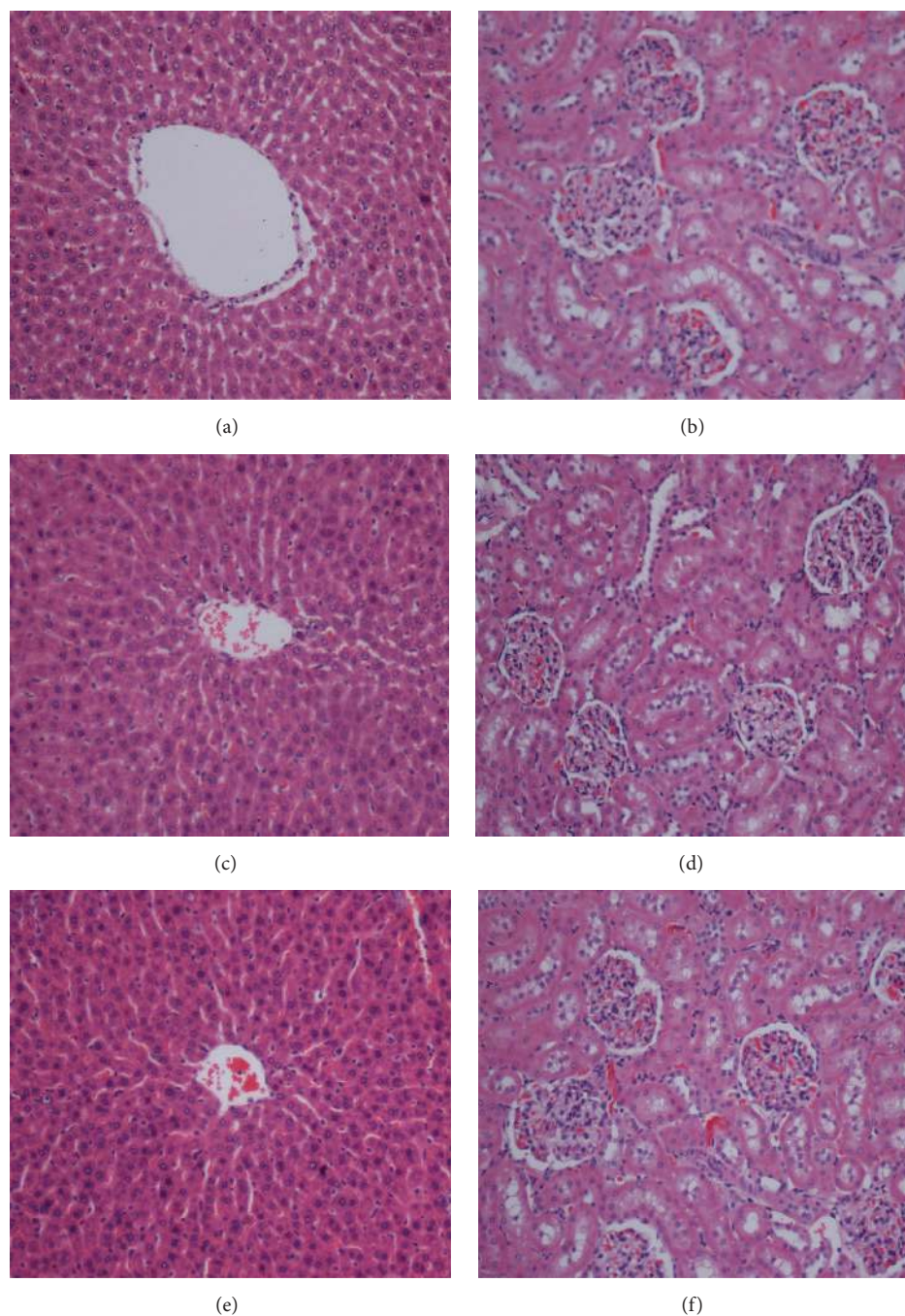


FIGURE 10: Histology of liver ((a), (c), and (e)) and kidney ((b), (d), and (f)) in acute toxicity test. Rats treated with 5 mL/kg vehicle (dH₂O) ((a) and (b)). Rats treated with 2 gm/kg (5 mL/kg) *Antrodia camphorata* extract ((c) and (d)). Rats treated with 5 gm/kg (5 mL/kg) *Antrodia camphorata* extract ((e) and (f)). There is no significant differences in structures of liver and kidney (no hepatotoxic and nephrotoxic) between treated and control groups (H&E stain 20x).

results showed that the wound area of wounds dressed with *Antrodia camphorata* extract had relatively less scar width at wound closure. They also showed a proliferating effect on fibroblast cells and promoted the *in vitro* wound healing. Such natural sources may lead to better forms of therapy for patients with acute, chronic, and surgical skin wounds.

Conflict of Interests

The authors declare no conflict of interests.

Acknowledgment

This research was supported by the University of Malaya High Impact Research Grant UNRG:RPO43A-15HTM.

References

- [1] S. Rawat, R. Singh, P. Thakur, S. Kaur, and A. Semwal, "Wound healing agents from medicinal plants: a review," *Asian Pacific Journal of Tropical Biomedicine*, vol. 2, no. 3, pp. S1910–S1917, 2012.
- [2] D. E. Tsala, D. Amadou, and S. Habtemariam, "Natural wound healing and bioactive natural products," *Phytopharmacology*, vol. 4, no. 3, pp. 532–560, 2013.
- [3] M. A. Abdulla, A. A. Fard, V. Sabaratnam et al., "Potential activity of aqueous extract of culinary-medicinal Lion's Mane mushroom, *Hericium erinaceus* (Bull.: Fr.) Pers. (Aphyllophoromycetidae) in accelerating wound healing in rats," *International Journal of Medicinal Mushrooms*, vol. 13, no. 1, pp. 33–39, 2011.
- [4] F. H. Al-Bayaty, M. A. Abdulla, M. I. A. Hassan, and H. M. Ali, "Effect of andrographis paniculata leaf extract on wound healing in rats," *Natural Product Research*, vol. 26, no. 5, pp. 423–429, 2012.
- [5] P.-G. Cheng, C.-W. Phan, V. Sabaratnam, N. Abdullah, M. A. Abdulla, and U. R. Kuppusamy, "Polysaccharides-rich extract of *Ganoderma lucidum* (M.A. Curtis:Fr.) P. Karst accelerates wound healing in streptozotocin-induced diabetic rats," *Evidence-Based Complementary and Alternative Medicine*, vol. 2013, Article ID 671252, 9 pages, 2013.
- [6] F. Hajiaghaalipour, M. S. Kanthimathi, M. A. Abdulla, and J. Sanusi, "The effect of camellia sinensis on wound healing potential in an animal model," *Evidence-Based Complementary and Alternative Medicine*, vol. 2013, Article ID 386734, 7 pages, 2013.
- [7] Y.-C. Hseu, S.-C. Chen, P.-C. Tsai et al., "Inhibition of cyclooxygenase-2 and induction of apoptosis in estrogen-nonresponsive breast cancer cells by *Antrodia camphorata*," *Food and Chemical Toxicology*, vol. 45, no. 7, pp. 1107–1115, 2007.
- [8] Y.-C. Hseu, F.-Y. Wu, J.-J. Wu et al., "Anti-inflammatory potential of *Antrodia Camphorata* through inhibition of iNOS, COX-2 and cytokines via the NF- κ B pathway," *International Immunopharmacology*, vol. 5, no. 13, pp. 1914–1925, 2005.
- [9] S.-H. Wu and L. Ryvarden, "*Antrodia camphorata* ('niu-chang-chih'), new combination of a medicinal fungus in Taiwan," *Botanical Bulletin-Academia Sinica Taipei*, vol. 38, pp. 273–276, 1997.
- [10] Y.-C. Hseu, W.-C. Chang, Y.-T. Hseu et al., "Protection of oxidative damage by aqueous extract from *Antrodia camphorata* mycelia in normal human erythrocytes," *Life Sciences*, vol. 71, no. 4, pp. 469–482, 2002.
- [11] G. Hsiao, M.-Y. Shen, K.-H. Lin et al., "Antioxidative and hepatoprotective effects of *Antrodia camphorata* extract," *Journal of Agricultural and Food Chemistry*, vol. 51, no. 11, pp. 3302–3308, 2003.
- [12] Y.-C. Hseu, S.-C. Chen, H.-C. Chen, J.-W. Liao, and H.-L. Yang, "*Antrodia camphorata* inhibits proliferation of human breast cancer cells *in vitro* and *in vivo*," *Food and Chemical Toxicology*, vol. 46, no. 8, pp. 2680–2688, 2008.
- [13] C.-C. Peng, K.-C. Chen, R. Y. Peng, C.-H. Su, and H. M. Hsieh-Li, "Human urinary bladder cancer T24 cells are susceptible to the *Antrodia camphorata* extracts," *Cancer Letters*, vol. 243, no. 1, pp. 109–119, 2006.
- [14] G.-J. Wang, H.-W. Tseng, C.-J. Chou, T.-H. Tsai, C.-T. Chen, and M.-K. Lu, "The vasorelaxation of *Antrodia camphorata* mycelia: involvement of endothelial Ca^{2+} -NO-cGMP pathway," *Life Sciences*, vol. 73, no. 21, pp. 2769–2783, 2003.
- [15] Y.-L. Hsu, Y.-C. Kuo, P.-L. Kuo, L.-T. Ng, Y.-H. Kuo, and C.-C. Lin, "Apoptotic effects of extract from *Antrodia camphorata* fruiting bodies in human hepatocellular carcinoma cell lines," *Cancer letters*, vol. 221, no. 1, pp. 77–89, 2005.
- [16] H.-L. Yang, C.-S. Chen, W.-H. Chang et al., "Growth inhibition and induction of apoptosis in MCF-7 breast cancer cells by *Antrodia camphorata*," *Cancer Letters*, vol. 231, no. 2, pp. 215–227, 2006.
- [17] Y.-Y. Chan, C.-S. Chang, L.-H. Chien, and T.-F. Wu, "Apoptotic effects of a high performance liquid chromatography (HPLC) fraction of *Antrodia camphorata* mycelia are mediated by down-regulation of the expressions of four tumor-related genes in human non-small cell lung carcinoma A549 cell," *Journal of Ethnopharmacology*, vol. 127, no. 3, pp. 652–661, 2010.
- [18] C.-T. Yeh, Y. K. Rao, C.-J. Yao et al., "Cytotoxic triterpenes from *Antrodia camphorata* and their mode of action in HT-29 human colon cancer cells," *Cancer Letters*, vol. 285, no. 1, pp. 73–79, 2009.
- [19] A. A. Zahra, F. A. Kadir, A. A. Mahmood et al., "Acute toxicity study and wound healing potential of *Gynura procumbens* leaf extract in rats," *Journal of Medicinal Plants Research*, vol. 5, no. 12, pp. 2551–2558, 2011.
- [20] M. Niyas Ahamed and T. Sastry, "An *in vivo* study on the wound healing activity of cellulose-chitosan composite incorporated with silver nanoparticles in albino rats," *International Journal of Research in Ayurveda & Pharmacy*, vol. 2, no. 4, p. 1203, 2011.
- [21] K. Hostanska, M. Rostock, J. Melzer, S. Baumgartner, and R. Saller, "A homeopathic remedy from arnica, marigold, St. John's wort and comfrey accelerates *in vitro* wound scratch closure of NIH 3T3 fibroblasts," *BMC Complementary and Alternative Medicine*, vol. 12, no. 1, article 100, 2012.
- [22] OECD, *OECD Guidelines for the Testing of Chemicals*, OECD Publishing, 1998.
- [23] Z. A. Amin, M. Bilgen, M. A. Alshawsh, H. M. Ali, A. H. A. Hadi, and M. A. Abdulla, "Protective role of *Phyllanthus niruri* extract against thioacetamide-induced liver cirrhosis in rat model," *Evidence-Based Complementary and Alternative Medicine*, vol. 2012, Article ID 241583, 9 pages, 2012.
- [24] A. Shukla, A. M. Rasik, and B. N. Dhawan, "Asiaticoside-induced elevation of antioxidant levels in healing wounds," *Phytotherapy Research*, vol. 13, no. 1, pp. 50–54, 1999.
- [25] S. Szabo, S. Kusstatscher, G. Sakoulas, Z. Sandor, A. Vincze, and M. Jadus, "Growth factors: new 'endogenous drugs' for ulcer healing," *Scandinavian Journal of Gastroenterology. Supplement*, vol. 210, pp. 15–18, 1995.
- [26] D. M. Cooper, "Optimizing wound healing. A practice within nursing's domain," *The Nursing Clinics of North America*, vol. 25, no. 1, pp. 165–180, 1990.
- [27] E. K. Akkol, U. Koca, I. Peşin, D. Yilmazer, G. Toker, and E. Yeşilada, "Exploring the wound healing activity of *Arnebia densiflora* (Nordm.) Ledeb. *by in vivo* models," *Journal of Ethnopharmacology*, vol. 124, no. 1, pp. 137–141, 2009.
- [28] D. Csupor, G. Blazsó, Á. Balogh, and J. Hohmann, "The traditional Hungarian medicinal plant *Centaurea sadleriana* Janka accelerates wound healing in rats," *Journal of Ethnopharmacology*, vol. 127, no. 1, pp. 193–195, 2010.
- [29] M. N. M. Walter, K. T. Wright, H. R. Fuller, S. MacNeil, and W. E. B. Johnson, "Mesenchymal stem cell-conditioned medium accelerates skin wound healing: an *in vitro* study of fibroblast and keratinocyte scratch assays," *Experimental Cell Research*, vol. 316, no. 7, pp. 1271–1281, 2010.

- [30] S. Sonnylal, X. Shi-Wen, P. Leoni et al., "Selective expression of connective tissue growth factor in fibroblasts in vivo promotes systemic tissue fibrosis," *Arthritis & Rheumatism*, vol. 62, no. 5, pp. 1523–1532, 2010.
- [31] J. H. Shim, J. W. Lim, B. K. Kim, S. J. Park, S. W. Kim, and T. H. Choi, "KCL mediates K^+ channel-activated mitogen-activated protein kinases signaling in wound healing," *Archives of Plastic Surgery*, vol. 42, no. 1, pp. 11–19, 2015.
- [32] D. Urrego, A. P. Tomczak, F. Zahed, W. Stühmer, and L. A. Pardo, "Potassium channels in cell cycle and cell proliferation," *Philosophical Transactions of the Royal Society B: Biological Sciences*, vol. 369, no. 1638, Article ID 20130094, 2014.
- [33] J. A. Molnar, *Nutrition and Wound Healing*, CRC Press, 2006.

