



Appropriate therapy for fistulizing and fibrostenotic Crohn's disease: Results of a multidisciplinary expert panel — EPACT II

Christian Felley^{a,*}, John-Paul Vader^b, Pascal Juillerat^{a,b}, Valérie Pittet^b, Colm O'Morain^d, Yves Panis^e, Boris Vucelic^f, Jean-Jacques Gonvers^a, Christian Mottet^a, Florian Froehlich^{a,c}, Pierre Michetti^a and the EPACT II Study Group¹

^a Department of Gastroenterology & Hepatology, Centre Hospitalier Universitaire Vaudois and University of Lausanne, Lausanne, Switzerland

^b Healthcare Evaluation Unit, Institute of Social & Preventive Medicine (IUMSP), Centre Hospitalier Universitaire Vaudois and University of Lausanne, Lausanne, Switzerland

^c Department of Gastroenterology, University of Basle, Basle, Switzerland

^d Gastroenterology Office, Adelaide & Meath Hospital and Trinity College Dublin, Dublin, Ireland

^e Service de chirurgie colorectale, Hôpital Beaujon, Clichy, France

^f Division of Gastroenterology, University Hospital Rebro, Zagreb, Croatia

Received 13 March 2009; received in revised form 5 June 2009; accepted 5 June 2009

KEYWORDS

Crohn's disease;
Fistulas;
Stenosis;
Appropriateness;
RAND Appropriateness
Method

Abstract

Introduction: Many therapeutic decisions in the management of fistulizing and fibrostenotic Crohn's disease (CD) have to be taken without the benefit of strong scientific evidence. For this reason, explicit appropriateness criteria for CD fistula and stenosis treatment were developed by a multidisciplinary European expert panel in 2004 with the aim of making them easily available on the Internet and thus allowing individual case scenario evaluation; these criteria were updated in 2007.

Methods: Twelve international experts convened in Geneva, Switzerland in December 2007. Explicit clinical scenarios, corresponding to real daily practice, were rated on a 9-point scale

Abbreviations: CD, Crohn's Disease; EPACT, European Panel on the Appropriateness of Crohn's Disease Therapy; 5-ASA, 5-aminosalicylates; AZA/6MP, azathioprine/6-mercaptopurine; MTX, methotrexate; TNF α , tumour necrosis factor α ; ECCO, European Crohn's & Colitis Organisation; (Cys A), cyclosporin A; (Fk), tacrolimus.

* Corresponding author. Christian Felley, MD, Department of Gastroenterology & Hepatology, Centre Hospitalier Universitaire Vaudois, Rue du Bugnon 46, CH-1001 Lausanne, Switzerland. Tel.: +41 21 314 0690; fax: +41 21 314 0707.

E-mail address: christian.felley@chuv.ch (C. Felley).

¹ The EPACT II Study Group (in alphabetical order): Erika Angelucci (Italy), Willem Bemelman (The Netherlands), Miquel Gassull (Spain), Franz Josef Heil (Germany), Marc Lémann (France), Tom Öresland (Norway), Colm O'Morain (Ireland), Yves Panis (France), Frank Seibold (Switzerland), Eduard Stange (Germany), Reinhold Stockbrügger (The Netherlands) and Boris Vucelic (Croatia).

based on evidence from the published literature and panelists' own expertise. Median ratings were stratified into three categories: appropriate (7–9), uncertain (4–6) and inappropriate (1–3).

Results: Overall, panelists rated 60 indications pertaining to fistulas. Antibiotics, azathioprine/6-mercaptopurine and conservative surgery are the mainstay of therapy for simple and complex fistulas. In the event of previous failure of azathioprine/6-mercaptopurine therapy, methotrexate and infliximab were considered appropriate for complex fistulas. The panel also rated 72 indications related to the management of fibrostenotic CD. The experts considered balloon dilation, if the stricture was endoscopically accessible, stricturoplasty and bowel resection to be appropriate for small bowel fibrostenotic Crohn's disease, and balloon dilation and bowel resection appropriate for fibrostenotic colonic disease. In the presence of an ileocolonic or ileorectal anastomotic stricture of <7 cm, endoscopic balloon dilation, and bowel resection were considered appropriate.

Conclusion: Antibiotics, azathioprine/6-mercaptopurine, and conservative surgery are the mainstay of therapy for fistulizing Crohn's disease. Infliximab is a therapeutic option in patients without prior response to immunosuppressant therapy. In fibrostenotic Crohn's disease, endoscopic balloon dilation, if feasible, or surgical therapy should be considered. These expert recommendations are available online (www.epact.ch). Prospective evaluation is now needed to test the validity of these appropriateness criteria in clinical practice.

© 2009 European Crohn's and Colitis Organisation. Published by Elsevier B.V. All rights reserved.

1. Introduction

Fistulizing or fibrostenotic presentations are the predominant patterns in the long-term evolution of Crohn's disease (CD)¹.

An American population-based study observed a cumulative risk for fistulas of 33% after 10 years and 50% after 20 years². In a prior review of the literature concerning fistulizing CD³, on which the EPACT II panel was based, we concluded that medical therapy is the main option for perianal fistulas once abscesses, if present, have been drained. Treatment should include antibiotics (both ciprofloxacin and metronidazole) and immunosuppressants. Infliximab should be reserved for refractory patients. Surgery is often necessary for internal fistulas.

Strictures are also a common complication of CD and mainly occur in the ileocaecal region. Fibrostenotic CD does not respond to medical therapy and requires endoscopic or surgical treatment⁴.

There are, however, numerous unresolved issues concerning the use of methotrexate (MTX), anti-tumour necrosis factor α (TNF α) agents and aggressive surgery in fistulizing CD, and the role of minimal surgery such as stricturoplasty in fibrostenotic CD. High-grade evidence based on randomised controlled trials is lacking.

The European Panel on the Appropriateness of Crohn's Disease Therapy (EPACT II) convened in Geneva, Switzerland on November 30th and December 1st, 2007. Twelve experts (8 gastroenterologists, 1 internist/GP and 3 surgeons), from 9 European countries participated (Croatia, France, Germany, Ireland, Italy, Norway, Spain, Switzerland, The Netherlands). This meeting aimed to update criteria developed by a first panel (EPACT I) in 2004 in Lausanne⁵ and to define appropriateness criteria for the treatment of CD, taking into account recent advances in medicine and new evidence from the published literature. This article focuses on appropriate therapy for perianal fistulizing and fibrostenotic CD.

2. Methods

2.1. RAND Appropriateness Method

The RAND Appropriateness Method is a well recognized way to standardise expert opinion based on an evidence-based literature review, discussion at a panel meeting and a voting process. Methodological details of the various steps that took place during the RAND panel process (recruitment of experts, literature review, first rating round, second rating round, expert panel meeting) are well described in an earlier article on EPACT I and in the literature review for this earlier panel⁵.

A few specific changes in the methodology that occurred during this current update and the method of analysis of the panel's results are described here.

2.2. List of indications and selection of treatment options

Factors that contributed to the appropriateness of various types of treatment for differing presentations of CD were identified, based on the literature review. Mini-scenarios describing patients corresponding to clinical indications encountered in daily practice were created. They differed from one another due to factors such as the presence of simple or complex fistulas, and the previous response to azathioprine/6-mercaptopurine, for fistulizing Crohn's disease, and the anatomical location of the stricture and its length, for fibrostenotic Crohn's disease. These scenarios were submitted to the experts for approval during the first round of the panel and their accuracy was discussed during individual scheduled conference calls with one of the organizers.

2.3. Specific changes in the voting process

If there was more than one appropriate therapy for a given scenario, we asked the experts to classify their choices

from the best (A) to the least fitting drug (B; C, D or E, depending on the number of appropriate drugs) for the clinical indication.

A ranking was thus obtained by addition of points: A=2 points, B=1 point, C, D, E=0 points.

For fistulizing CD, the panel rated the appropriateness of antibiotics, cyclosporine A, tacrolimus, azathioprine/6-mercaptopurine (AZA/6MP), MTX, infliximab, adalimumab, certolizumab, natalizumab, conservative surgery and "aggressive" surgery. For fibrostenotic CD, 5-aminosalicylates (5-ASA), AZA/6MP, MTX, antibiotics, steroids, endoscopic balloon dilation, infliximab, certolizumab, natalizumab, stricturoplasty and bowel resection were assessed.

2.4. Definition of appropriateness and disagreement

A treatment is defined as being appropriate when the benefit to the patient exceeds the potential risks by a sufficiently wide margin that the treatment is worth giving⁶. The rate of appropriateness of each clinical indications was calculated using the median of the twelve experts' votes between 1 and 9 (1=extremely inappropriate, 9=extremely appropriate). According to the value obtained, each scenario was classified as "appropriate", "uncertain" or "inappropriate" (1–3 = inappropriate; 4–6 = uncertain; 7–9 = appropriate). In a classical interpretation of the results, an intra-panel disagreement was considered to be present when at least three of the twelve ratings fell in the 1-3 category *and* at least three others in the 7–9 point category. This situation was then defined "uncertain", irrespective of the median panel score. The IPRAS (Interpercentile Range Adjusted for Symmetry) method of analysis allowed a reduction in the number of disagreements in the experts' votes⁷.

2.5. Definition of simple and complex fistulas

Perianal fistulas can be classified as low (below the dentate line) or high (above the dentate line). A perianal fistula will furthermore be classified as simple if it is low, has a single external opening, is not associated with pain and if there is no evidence of rectovaginal fistula or anorectal stricture⁸. A complex fistula is high, may have multiple external openings, may be associated with pain, with the presence of a rectovaginal fistula, anorectal stricture or active rectal disease at endoscopy.

2.6. Definition of conservative and aggressive surgical treatment

Conservative surgery was defined as incision and drainage of abscesses and placement of setons, fistula plugs and mucosal advancement flaps. Aggressive surgery includes proctocolectomy and diversion through stomas.

2.7. Definition of fibrostenotic Crohn's disease

Fibrostenotic Crohn's disease was defined as compatible symptoms, confirmed by radiological examination, and with no sign of inflammation. In case of doubt, an inflammatory

stenosis should be excluded by a corticosteroid test (prednisone 1 mg/kg/day intravenously for 5–7 days).

3. Results

3.1. Treatment of fistulas

Sixty scenarios corresponding to fistulizing Crohn's disease were rated by the experts. Proposed therapeutic options were antibiotics, AZA/6-MP, Cys A/Fk, methotrexate, anti-TNF α agents alone (infliximab, adalimumab, certolizumab), natalizumab or surgery (conservative or aggressive approach).

For both simple and complex fistulas, the scenarios proposed the following situations: patient had never received AZA/6-MP, patient had a prior successful treatment by AZA/6-MP, patient had previously received treatment by AZA/6-MP which had failed.

Eighteen scenarios were judged appropriate by the panel of experts, 29 were rated inappropriate (Fig. 1). Thirteen situations were rated uncertain, including two situations where there was disagreement between the experts.

3.2. Treatment of simple fistulas

Out of 30 scenarios referring to simple fistulas, 8 therapeutic options were considered as appropriate, 17 were inappropriate and 5 uncertain. There was no disagreement.

The panel rated therapy with antibiotics or conservative surgery appropriate, whether the patient had previously received AZA/6-MP or not. Treatment with AZA/6-MP was deemed appropriate if there had been no prior treatment with the same substances, or if a prior treatment was successful.

Calcineurin inhibitors (Cys A, Fk), aggressive surgery, certolizumab and natalizumab were inappropriate in all situations as were a first-line treatment by infliximab or adalimumab. If a previous treatment with AZA/6-MP had failed, the experts considered re-treatment with AZA/6-MP to be inappropriate.

The use of methotrexate was uncertain in all situations, as was treatment by infliximab or adalimumab when a previous treatment by AZA/6-MP had failed.

The panel concluded that for simple fistulas appropriate therapeutic options for patients who had never received AZA/6-MP were antibiotics or conservative surgery as first-line therapies and AZA/6-MP as second-line therapy. For patients who had been treated successfully with AZA/6-MP in the past, the appropriate first-line therapy was conservative surgery, antibiotics were a second-line option, and a retreatment with AZA/6-MP was a third-line treatment. Appropriate therapies for patients in whom AZA/6-MP therapy had previously been unsuccessful were conservative surgery as first-line and antibiotics as second-line.

3.3. Treatment of complex fistulas

Out of 30 scenarios concerning complex fistulas, 10 therapeutic options were considered appropriate, 12 were inappropriate and 8 uncertain, including two with disagreement.

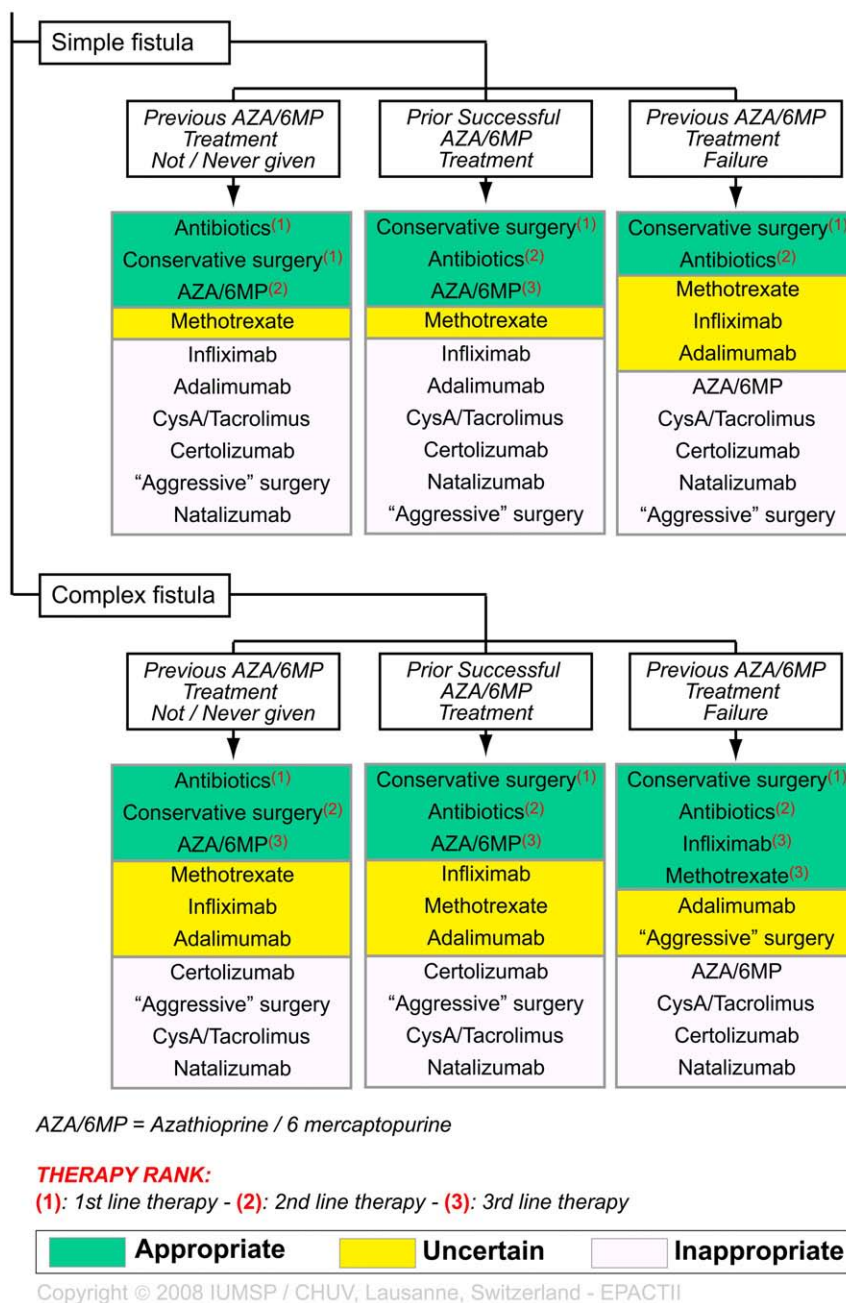


Figure 1 Appropriateness ratings for therapy of simple and complex fistulas in fistulising Crohn's disease.

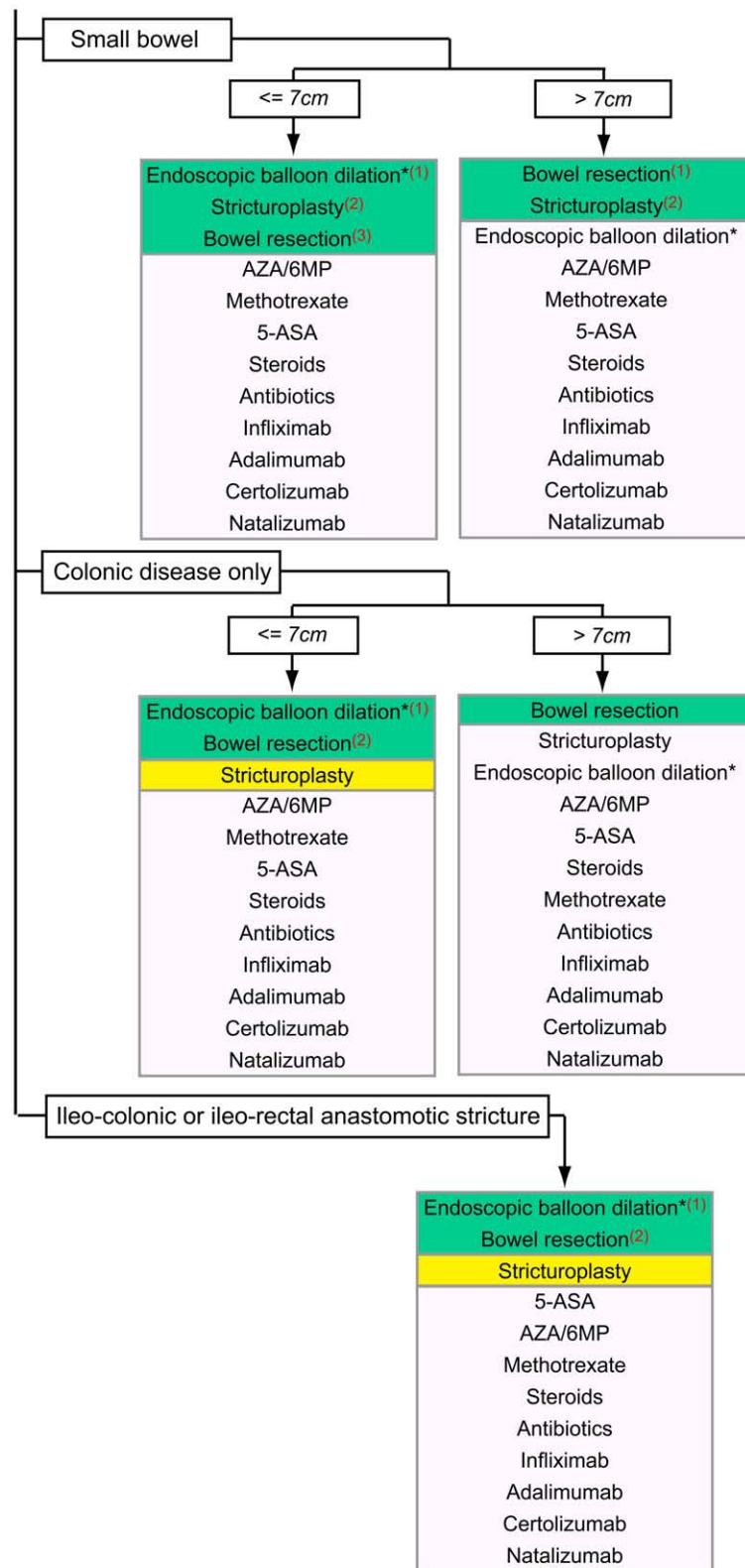
Therapy with antibiotics, or conservative surgery, were rated appropriate whether the patient had previously received AZA/6-MP or not. A trial of AZA/6-MP was also appropriate in patients who had never received this treatment or who had a prior response to immunosuppressants. Methotrexate or infliximab were appropriate for patients in whom a prior therapy with AZA/6-MP failed.

Immunosuppressants (Cys A, Fk), certolizumab and natalizumab were inappropriate in all situations. A second course of AZA/6-MP therapy in patients in whom this therapy had previously failed was inappropriate, as was aggressive surgery in patients who had never received or responded to AZA/6-MP.

The use of methotrexate, infliximab or adalimumab was uncertain in all complex fistulas.

In two situations, the experts deemed the therapeutic option uncertain, but with disagreement: both situations concerned patients with failure of a prior therapy with AZA/6-MP and for whom a treatment with adalimumab or aggressive surgery was evaluated.

For some clinical presentations of complex fistulas, several therapeutic options were appropriate. According to the experts' rating, the ranking showed that for complex fistulas, patients who had not received a previous treatment with AZA/6-MP should receive conservative surgery as first-line, antibiotics as second-line and a new course of AZA/6-MP as third-



Downloaded from https://academic.oup.com/ecco-jcc/article/3/4/250/471702 by guest on 20 August 2022

AZA/6MP = Azathioprine / 6 Mercaptopurine; 5-ASA = 5-aminosalicylic Acid; *= if accessible

THERAPY RANK:

(1): 1st line therapy - (2): 2nd line therapy - (3): 3rd line therapy

Appropriate	Uncertain	Inappropriate
-------------	-----------	---------------

Copyright © 2008 IUMSP / CHUV, Lausanne, Switzerland - E-PACTII

Figure 2 Appropriateness ratings for therapy of fibrostenotic Crohn's disease.

line therapy. When a previous treatment with AZA/6-MP was successful, the experts deemed appropriate as first-line therapy antibiotics, conservative surgery as the second-line option and a re-treatment with AZA/6-MP as a third-line treatment. When a prior treatment with AZA/6-MP had failed, conservative surgery was deemed to be the first-line therapy of choice, with antibiotics as second-line therapy, with both infliximab or methotrexate as third-line options.

When asked to evaluate combined treatment, experts found the following combinations to be appropriate for patients without prior or with prior successful exposure to AZA/6-MP treatment: antibiotics+conservative surgery, AZA/6-MP+conservative surgery, antibiotics+AZA/6-MP with or without conservative surgery. For patients in whom AZA/6-MP had previously failed, appropriate combinations were antibiotics+conservative surgery with either of the following: infliximab, methotrexate.

3.4. Treatment of fibrostenotic Crohn's disease

Seventy two scenarios concerning management of fibrostenotic Crohn's disease were rated by the experts. Proposed therapeutic options were 5-ASA, AZA/6-MP, antibiotics, methotrexate, anti-TNF α agents alone (infliximab, adalimumab or certolizumab), natalizumab, steroids, endoscopic balloon dilation, stricturoplasty or bowel resection.

Scenarios reflected the following clinical situations in fibrostenosis: in small bowel ≤ 7 cm, in small bowel > 7 cm, in colon ≤ 7 cm, in colon > 7 cm, ileocolonic anastomotic stricture ≤ 7 cm, ileorectal anastomotic stricture ≤ 7 cm.

Twelve scenarios were judged appropriate by the panel and three inappropriate (Fig. 2). Fifty seven situations were rated uncertain.

3.5. Treatment of small bowel stenosis

Appropriate therapeutic options for a fibrostenotic stricture of ≤ 7 cm were endoscopic balloon dilation, stricturoplasty, or bowel resection. All medical treatments were rated inappropriate. If the stricture was > 7 cm in length, stricturoplasty or bowel resection were appropriate, whereas endoscopic balloon dilation or medical treatment were inappropriate.

3.6. Treatment of colonic stenosis

Endoscopic balloon dilation or bowel resection were judged to be appropriate treatments for colonic strictures ≤ 7 cm in length. Stricturoplasty was rated uncertain. All medical treatments were inappropriate according to the panel.

For colonic stricture > 7 cm, bowel resection was the only appropriate treatment. Stricturoplasty was uncertain and endoscopic balloon dilation as well as all medical approaches were judged inappropriate.

3.7. Treatment of ileocolonic or ileorectal anastomotic strictures

For both ileocolonic and ileorectal anastomotic strictures < 7 cm, endoscopic balloon dilation, and bowel resection

were rated appropriate. Stricturoplasty was uncertain and all medical treatments were inappropriate.

According to the experts, endoscopic balloon dilation is the first-line treatment of small bowel, colonic and anastomotic strictures ≤ 7 cm, if these are endoscopically accessible. Bowel resection is the first-line option for small bowel and colonic stenosis > 7 cm. Stricturoplasty is the second-line therapy for all small bowel strictures as is bowel resection for ≤ 7 cm colonic and anastomotic strictures. Bowel resection is a third-line option for ≤ 7 cm small bowel strictures.

4. Discussion

High-quality evidence, such as randomized controlled trials, is lacking for many therapeutic decisions in the management of Crohn's disease and thus the development of explicit appropriateness criteria has an important role to play in the improvement and maintenance of quality of care. Panel-based criteria such as those produced by the RAND process, which combines a review of published data and systematically developed scenarios rated according to the expert judgement of clinicians, offer the best chance of providing an optimal therapeutic option in clinical practice. The validated approach used by the EPACT panel allowed us to define management strategies for fistulizing and fibrostenotic Crohn's disease, using both the well-studied options and also more controversial situations. For example, even if only uncontrolled or retrospective studies had evaluated the role of antibiotics in fistulizing Crohn's disease⁹⁻¹², this panel clearly defined the crucial role of antibiotics for this condition. The panel also favoured giving methotrexate to patients with complex fistulas which did not respond to azathioprine or 6-mercaptopurine, even if only limited evidence is in fact available concerning this drug for this indication¹³. On the other hand, available evidence does and must impact on panelist judgement. Thus, among the anti-TNF α agents, only infliximab was considered appropriate for the treatment of fistulas since this is the only anti-TNF α agent as yet evaluated by a randomized controlled study¹⁴. Furthermore, considering that there is at present only limited knowledge on the long-term safety of TNF α blockers, the panel considered infliximab appropriate only in complex fistulas after failure of a previous therapy by azathioprine or 6-mercaptopurine.

The management of fistulizing and fibrostenotic Crohn's disease has recently been evaluated by the European Crohn's and Colitis Organisation (ECCO) consensus^{15,16}. Overall, the ECCO treatment decisions are in agreement with the EPACT results; they agree on the treatment of symptomatic simple and complex fistulas by conservative surgery and antibiotics. A perianal abscess should be ruled out and drained if present. Azathioprine/6-mercaptopurine are the mainstay for maintenance therapy and infliximab should be a second-line therapy. The major difference between EPACT II and ECCO concerns methotrexate. The EPACT panel judged this therapy appropriate in the case of complex fistulas which did not respond to azathioprine/6-mercaptopurine. Contrary to the EPACT recommendations, the ECCO consensus concluded that methotrexate should not be recommended as standard practice in this indication.

In fibrostenotic disease, EPACT II and ECCO also converge. Endoscopic dilation of a Crohn-related stenosis is the preferred technique for accessible short strictures. ECCO advised conventional stricturoplasty for small bowel strictures of <10 cm. Long-term results after conservative surgery for small bowel Crohn's disease have recently been published¹⁷. They show that conservative surgery is safe and effective for treating patients with jejunoileal Crohn's disease. Stricturoplasty in the colon is controversial for both EPACT II and ECCO. Surgical resection is appropriate in both small bowel and colonic Crohn's disease and should be as restrictive as possible.

Treatment recommendations for Crohn's disease published by the British Society of Gastroenterology in 2004¹⁸ are also in general agreement with our results.

In conclusion, using the RAND method we were able to establish expert recommendations for the treatment of fistulizing and fibrostenotic Crohn's disease, which are freely available online (www.epact.ch). Prospective evaluation should now test these appropriateness criteria in clinical practice.

Acknowledgements

We gratefully acknowledge the participation of Renzo Caprilli (Italy) and Yehuda Chowers (Israel) in the first round of the EPACT II panel. We thank Susan Giddons for editorial assistance.

Financial support for this work was received from a scientific grant from the Swiss National Science Foundation (3347CO-108792/1), supplemented with research funds of the Department of Gastroenterology & Hepatology, Centre Hospitalier Universitaire Vaudois and University of Lausanne, Lausanne, Switzerland, and with unrestricted research grants from Abbott, Essex Chemie AG, UCB Pharma, Nicomed, Vifor pharma.

Competing interests: none.

References

1. Cosnes J, Cattan S, Blain A, et al. Long-term evolution of disease behavior of Crohn's disease. *Inflamm Bowel Dis* 2002;**8**: 244–50.
2. Schwartz DA, Loftus Jr EV, Tremaine WJ, et al. The natural history of fistulizing Crohn's disease in Olmsted County, Minnesota. *Gastroenterology* 2002;**122**:875–80.
3. Felley C, Mottet C, Juillerat P, et al. Fistulizing Crohn's disease. *Digestion* 2007;**76**:109–12.
4. Froehlich F, Juillerat P, Mottet C, et al. Fibrostenotic Crohn's disease. *Digestion* 2007;**76**:113–5.
5. Vader J, Froehlich F, Juillerat P, et al. Appropriate treatment for Crohn's disease: methodology and summary results of a multidisciplinary international expert panel approach – EPACT. *Digestion* 2006;**73**:237–48.
6. Brook R, Chassin M, Fink A, Solomon D, Kosecoff J, Park R. A method for the detailed assessment of the appropriateness of medical technologies. *Int J Technol Assess Health Care* 1986;**2**: 53–63.
7. Fitch K, Bernstein S, Aguilar M, et al. The RAND/UCLA Appropriateness Method User's manual. *Rand Corp* 2001.
8. Sandborn Wa, Fazio Vb, Feagan Bc, Hanauer Sd. AGA technical review on perianal Crohn's disease. *Gastroenterology* 2003;**125**: 1508–30.
9. Bernstein LH, Frank MS, Brandt LJ, Boley SJ. Healing of perineal Crohn's disease with metronidazole. *Gastroenterology* 1980;**79**: 357–65.
10. Brandt L, Bernstein L, Boley S, Frank M. Metronidazole therapy for perineal Crohn's disease: a follow-up study. *Gastroenterology* 1982;**83**:383–7.
11. Turunen U, Farkkila M, Valtonen V, Seppala K. Long-term outcome of ciprofloxacin treatment in severe perianal or fistulous Crohn's disease. *Gastroenterology* 1993;**104**:A793-A793.
12. Solomon M. Combination of ciprofloxacin and metronidazole in severe perianal Crohn's disease. *Clin Invest Med S* 1992;**15**:A41.
13. Mahadevan U, JFMDHP. Fistula response to methotrexate in Crohn's disease: a case series. *Aliment Pharmacol Ther* 2003;**18**: 1003–8.
14. Sands B, Van Deventer S, Bernstein C. Long-term treatment of fistulas in patients with Crohn's disease: response to infliximab in ACCENT II trial through 54 weeks. *Gastroenterology* 2002;**122**: A81.
15. Caprilli R, Gassull MA, Escher JC, et al, for the European Crohn's and Colitis O. European evidence based consensus on the diagnosis and management of Crohn's disease: special situations. *Gut* 2006;**55**: i36–58.
16. Clark M, Colombel J-F, Feagan BC, et al. American gastroenterological association consensus development conference on the use of biologics in the treatment of inflammatory bowel disease, June 21–23, 2006. *Gastroenterology* 2007;**133**:312–39.
17. Sampietro GM, Corsi F, Maconi G, et al. Prospective study of long-term results and prognostic factors after conservative surgery for small bowel Crohn's disease. *Clin Gastroenterol Hepatol* 2009;**7**:183–91 quiz 125.
18. Carter MJ, Lobo AJ, Travis SPL. Guidelines for the management of inflammatory bowel disease in adults. *Gut* 2004;**53**:v1–16.