Original Article With Video Illustration

Arthroscopic Biceps Tenodesis: A New Technique Using Bioabsorbable Interference Screw Fixation

Pascal Boileau, M.D., Sumant G. Krishnan, M.D., Jean-Sebastien Coste, M.D., and Gilles Walch, M.D.

Purpose: To report a new technique of arthroscopic biceps tenodesis using bioabsorbable interference screw fixation and the early results. **Type of Study:** Prospective, nonrandomized study. **Methods:** Technique: The principle of arthroscopic biceps tenodesis is simple: after biceps tenotomy, the tendon is exteriorized and doubled on a suture; the biceps tendon is then pulled into a humeral socket (7 or 8 mm × 25 mm) drilled at the top of the bicipital groove, and fixed using a bioabsorbable interference screw (8 or 9 mm × 25 mm) under arthroscopic control. Patients: 43 patients treated with this technique between 1997 and 1999 were followed-up for at least 1 year. The technique was indicated in 3 clinical situations: (1) with arthroscopic cuff repair (3 cases), (2) in case of isolated pathology of the biceps tendon with an intact cuff (6 cases), and (3) as an alternative to biceps tenotomy in patients with massive, degenerative and irreparable cuff tears (34 cases). The biceps pathology was tenosynovitis (4 cases), prerupture (15 cases), subluxation (11 cases), and luxation (13 cases). **Results:** The absolute Constant score improved from 43 points preoperatively to 79 points at review ($P < .005$). There was no loss of elbow movement and biceps strength was 90% of the strength of the other side. Two patients, operated on early in the series, presented with a rupture of the tenodesis. In both cases the bicipital tendon was very friable and the diameter of the screw proved to be insufficient (7 mm). No neurologic or vascular complications occurred. **Conclusions:** Arthroscopic biceps tenodesis using bioabsorbable screw fixation is technically possible and gives good clinical results. This technique can be used in cases of isolated pathologic biceps tendon or a cuff tear. A very thin, fragile, almost ruptured biceps tendon is the technical limit of this arthroscopic technique. **Key Words:** Shoulder arthroscopy—Biceps tenodesis—Bioabsorbable screw.

The long head of the biceps is a well-known cause of shoulder pain because of the multiple possibilities of pathology of the tendon itself and its pulley system,[1-12] leading to tenosynovitis, prerupture, subluxation, or dislocation of the tendon. Surgical treatment for disorders of the long head of the biceps is limited to removal of the intra-articular portion of the tendon, with either tenotomy or tenodesis.[13-20] Biceps tenodesis, associated with or without rotator cuff repair, is a common and well-accepted open surgical procedure.[9,14-16,18,20,21] Arthroscopic biceps tenotomy has been proposed for patients with chronic and significant shoulder pain in the presence of a massive irreparable rotator cuff tear, leading to complete resolution of pain.[19]

Because we were familiar with the technique of interference screw fixation for hamstring anterior cruciate ligament reconstruction,[25-27] we developed a personal technique for biceps tenodesis using bioabsorb

From the Orthopaedic Department, Hôpital de L'Archet, University of Nice, Nice, France.

Address correspondence and reprint requests to Pascal Boileau, M.D., Department of Orthopaedic Surgery, Hôpital de L'Archet-University of Nice, 151 Route de St. Antoine de Ginestière, 06202 Nice, France. E-mail: boileau.p@chu-nice.fr

© 2002 by the Arthroscopy Association of North America

0749-8063/02/1809-2743$35.00/0

doi:10.1053/jars.2002.36488

NOTE: To access the video illustration accompanying this report, visit the November-December on-line issue of *Arthroscopy* at www.arthroscopyjournal.org

able interference screws. This technique has been used routinely in open surgery since 1996, and since 1997 has been used under arthroscopic control.[28,29] This technique is different from previous techniques described, using either isolated sutures (Habermeyer and Mall[23]) or sutures with anchors (Snyder,[22] Gartsman and Hammerman[24]). The goal of this study is to describe this new technique of arthroscopic biceps tenodesis using bioabsorbable interference screw fixation and to report the early results.

METHODS

Surgical Technique

The principle of arthroscopic biceps tenodesis is simple: after biceps tenotomy, the tendon is exteriorized and doubled on a suture; the biceps tendon is then pulled into a humeral socket and fixed using an bioabsorbable interference screw (Fig 1).

Although the lateral decubitus position can be used, we prefer to perform this technique with the patient in the beach-chair position under general anesthesia or interscalene block. The shoulder should be placed in approximately 30° of flexion, 30° of internal rotation, and 30° of abduction (arthrodesis position), allowing the anterior part of the subacromial bursa to be adequately filled with water in order to have a clear view of the superior part of the bicipital groove. When using the beach-chair position, a classical knee U-shaped support is used with a Mayo stand to place the shoulder in the desired position. The elbow can be extended and flexed to 90°. Bony landmarks are drawn on the shoulder to identify the spine of the scapula, the acromion, the coracoid process, and the coracoacromial ligament. This procedure requires 3 arthroscopic portals: the classical posterior portal is created 2 cm inferior and 2 cm medial to the posterolateral corner of the acromion, and 2 anterior portals (anteromedial and anterolateral) are created 1.5 cm on each side of the bicipital groove (Fig 2). The posterior and anterolateral portals are used for the arthroscope (viewing portals) and the anteromedial portal is used for the instruments (working portal). A pump is helpful to obtain distension of the joint and the bursa but it is important to maintain low pump pressure (30 mm Hg or less) during the procedure, to prevent excessive soft tissue distension.

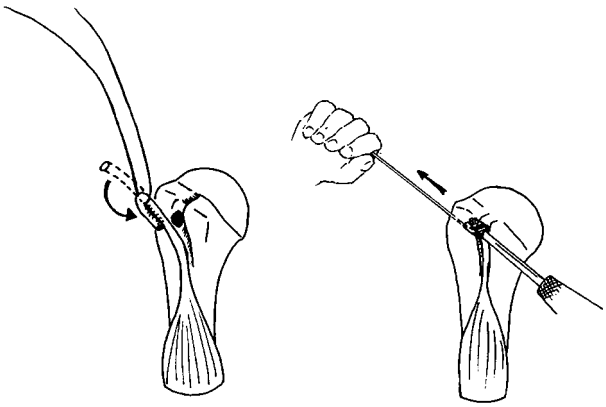

FIGURE 1. Principle of arthroscopic biceps tenodesis. (A) After biceps tenotomy, the tendon is exteriorized and doubled on a suture. (B) It is then pulled into a humeral socket and fixed using an absorbable interference screw.

FIGURE 2. Three portals are used: the posterior portal and 2 anterior portals, anteromedial and anterolateral, on each side of the bicipital groove.

Step 1. Glenohumeral Exploration and Tenotomy of the Long Head of the Biceps: The glenohumeral joint is first explored with the 30° arthroscope through the posterior portal. An anteromedial portal is established from inside to outside passing the trocar of the arthroscope through the rotator interval, lateral to the coracoid process, one cm distal to it, and just above the subscapularis tendon (Fig 2). This portal corresponds to the anteroinferior portal described by

Wolf.[31] After insertion of a cannula, the deep surface of the rotator cuff is assessed and pathology of the biceps tendon is confirmed: tenosynovitis, subluxation, dislocation, or prerupture. Biceps tendon pathology is very often in the intertubercular groove portion[10-12] and it is important to draw this part of the biceps tendon into the joint with a probe introduced through the anteromedial portal. The long head of the biceps is intra-articularly transfixed with a spinal needle at its entrance into the groove: this will avoid its retraction into the groove and help identify its location during subacromial bursoscopy. The tendon is then detached from its glenoid insertion using either a knife, a punch or electrocautery (Fig 3).

Step 2. Location and Opening of the Bicipital Groove After Anterosuperior Bursectomy: The arthroscope, still in the posterior portal, is removed from the joint and reoriented under the acromion, into the subacromial bursa. The same is done for the anteromedial cannula, which is placed into the anterosuperior bursa (lateral to the coracoacromial ligament). The bursectomy is begun with either a motorized shaver or the Mitek VAPR device (Mitek Products, Ethicon, Sommerville, NJ). The third anterolateral portal is now created: it is located 3 cm from the anterior border of the acromion and 3 cm from the anteromedial portal to allow triangulation (Fig 2). The arthroscope is removed from the posterior portal and placed in the anterolateral portal. At this point, the anteromedial portal is the working portal, the anterolateral portal is the viewing portal, and the posterior portal is for outflow only. Instruments are placed in the anteromedial portal to continue the bursectomy and identify the bicipital groove. Shaving of the anterior part of the bursa is essential for visualization, and is continued until the spinal needle is located (Fig 4A). The rotator cuff is evaluated and, if no tear is found, its insertion into the greater tuberosity is identified. A probe is used to palpate the "soft spot" corresponding to the bicipital groove, which is usually just medial to the lateral part of the greater tuberosity. Visualization of the white fibers of the transverse ligament and of the ascendant vessels on the lateral

Figure 3. Tenotomy of the long head of the biceps is performed after transfixion with a spinal needle to prevent distal retraction.

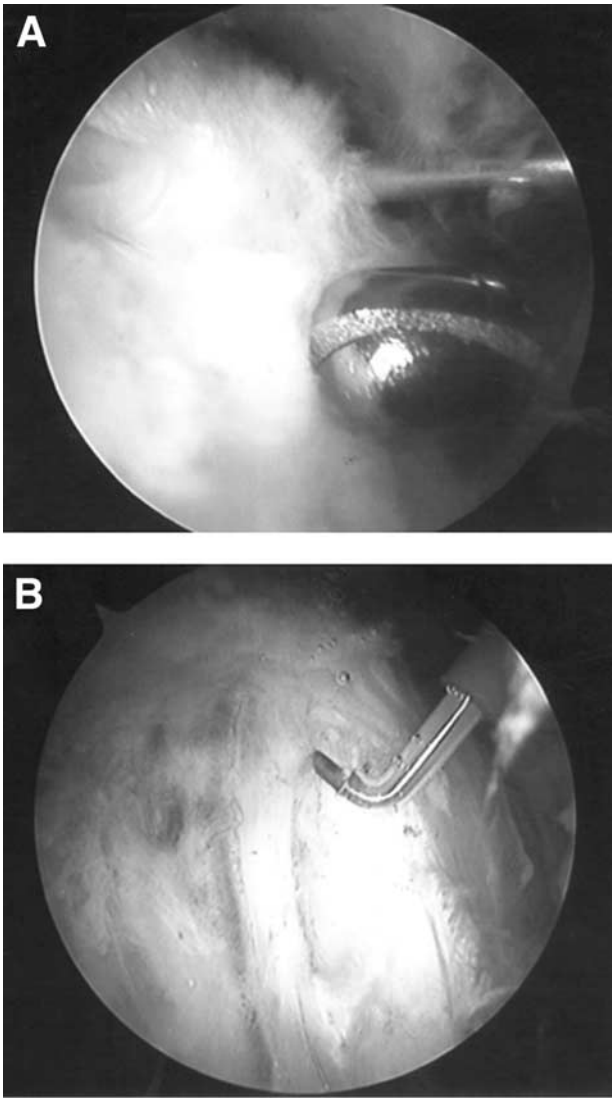

Figure 4. (A) Anterior bursectomy allows location of the spinal needle at the top of the groove. (B) The transverse humeral ligament can then be opened with electrocautery, staying medial to the ascending vessels on the lateral border of the bicipital groove.

part of the groove help also to locate the bicipital groove. The probe can be used to feel the "roll" of the biceps tendon in its groove. The transverse humeral ligament is now opened in a longitudinal fashion, using an electrocautery because of the leash of vessels on either border of the groove (Fig 4B). Once the groove is open, the long head of the biceps is probed and a careful arthroscopic synovectomy is performed using the shaver. Now the biceps tendon lifted out of the groove to free possible adhesions. Of course, location of the groove is much easier when there is a large cuff tear, with the biceps being uncovered when it enters the superior part of the groove.

Step 3. Biceps Exteriorization and Preparation: The long head of the biceps is grasped in its groove with a forceps while the spinal needle is removed. The biceps should then be grasped by its most proximal end to facilitate exteriorization (Fig 5A). The tendon is now exteriorized through the anteromedial portal while the cannula is temporarily removed (Fig 5B). A vascular clamp is used to grasp the tendon more distally and to keep it outside the wound; this will help to avoid tendon damage and to allow tendon preparation. Exteriorization of the tendon is facilitated by flexion of the elbow. About 4 to 5 cm of tendon should be exteriorized and the tendon is prepared. A brief tenosynovectomy and trimming of the tendon is performed, and then the tendon is doubled over a No. 5 suture (Ethibond, Ethicon; or Flexidene, Braun, Germany). The tendon is evened and the end of the tendon is whip stitched using a running baseball stitch with No. 4 absorbable suture (Vicryl, Ethicon; or Dexon, Braun, Germany). The tendon should be doubled and sewn to its anterior face for a length of about 2 cm (Fig 6). The diameter of the double tendon is measured using the same type of graft sizer used in the knee. The diameter of the double tendon should be 7 or 8 mm. If the tendon is too large, part of it must be cut in the direction of the fibbers and removed so that the diameter of the doubled tendon will be 8 mm. The size of the double tendon determines the drill diameter needed to drill the humeral socket. The arthroscopic working cannula is reintroduced into the anteromedial portal while the biceps tendon is kept outside the wound and outside the cannula; this is facilitated by placing the No. 5 suture under tension by attaching it to the sterile drapes with a nonpenetrating clamp. The rest of the procedure is performed with the arthroscope in the anterolateral (viewing) portal and the instruments inserted through the anteromedial (working) portal.

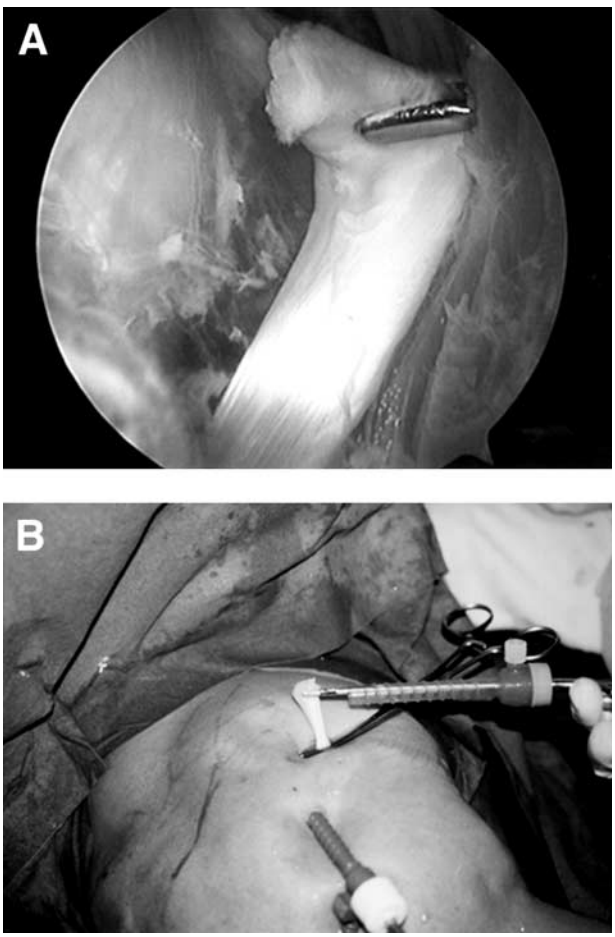

Figure 5. (A) The biceps tendon is grasped by its most proximal end to facilitate exteriorization through the deltoid and (B) outside the anteromedial portal.

Figure 6. (A) The biceps tendon is doubled on a traction suture and whip-stitched. (B) The biceps tendon is calibrated to 7 or 8 mm.

Step 4. Drilling the Humeral Socket: The bicipital groove is cleaned of all fibrous tissue with the shaver or the VAPR. Care must be taken not to shave on the most lateral or medial parts of the groove, because the leash of several small vessels there will bleed. The socket placement is assessed with probe measurement; this is optimally placed approximately 10 mm below the top of the groove entrance to prevent any anterosuperior impingement with the acromial arch. The location of the humeral socket is identified and penetrated with a sharp-tipped pick or awl, because the bone within the groove is quite hard; this prevents skiving or sliding of the guide pin along the cortical bone of the groove when drilling. A guidewire is then placed in the pilot hole and is oriented strictly perpendicular to the humerus and parallel to the lateral border of the acromion. A guide (Shoulder-Guide, Future Medical System, Glen Burnie, MD) can be used to perform this procedure safely, without any risk to the axillary nerve; this makes the procedure reproducible for any surgeon (Fig 7). The guidewire is drilled until it just penetrates the posterior cortex of the humerus. The humeral guide pin is over drilled with a 7- or 8-mm cannulated reamer, depending on the size of the double tendon, to a depth of 25 mm (Fig 8). The reamer and guide pin are then removed. The motorized shaver and an arthroscopic burr are placed through the same portal and into the humeral socket, to chamfer smooth its entrance by removing bone debris and tissues that may contribute to tendon blocking and abrasion (Fig 9). Most attention should be paid to the inferior part of the humeral socket, where the tendon will enter. The synovial tissue around the biceps tendon is also removed.

Figure 7. Outside view showing the position for drilling humeral guide pin: strictly perpendicular to humeral shaft and parallel to lateral border of acromion. The use of a Shoulder-Guide facilitates this step.

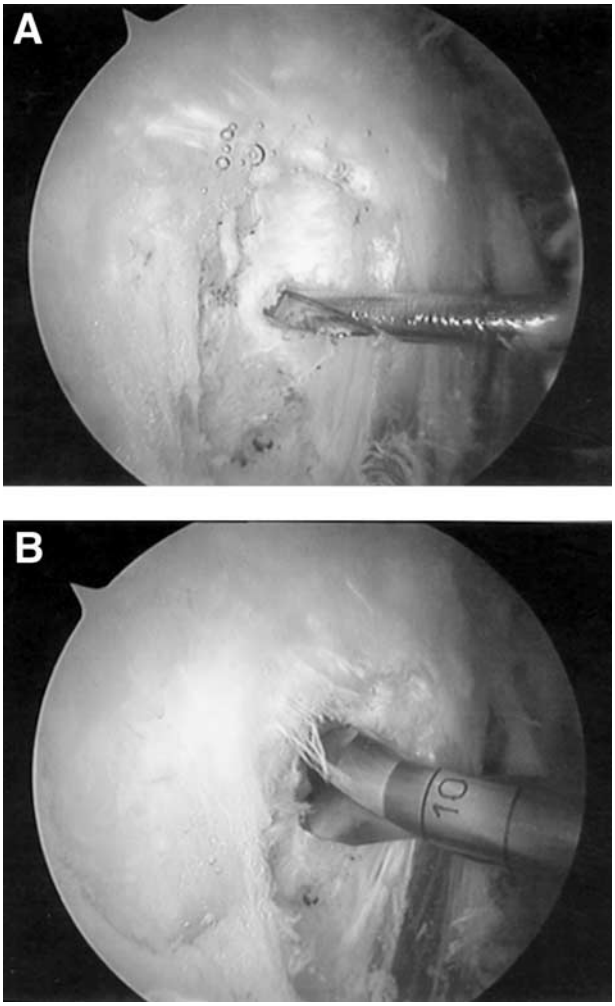

Figure 8. (A) The guide pin is introduced in a pilot hole 1 cm below the top of the bicipital groove and is drilled until it reaches the posterior cortex of the humerus. (B) The humeral guide pin is overdrilled with a 7- or 8-mm cannulated reamer (depending on the size of the double tendon) to a depth of 25 mm.

Step 5. Passing the Transhumeral Pin: A Beath needle pull-through technique is used for tendon placement. This needle has an eyelet on its trailing end and serves as a suture passer. The Beath pin is placed through the anteromedial cannula into the humeral socket. The direction of the transhumeral Beath pin is very important: it should be strictly perpendicular to the humerus and parallel to the lateral border of the acromion. The Beath pin is drilled until it exits the skin, which will be approximately 2 cm inferior and 2

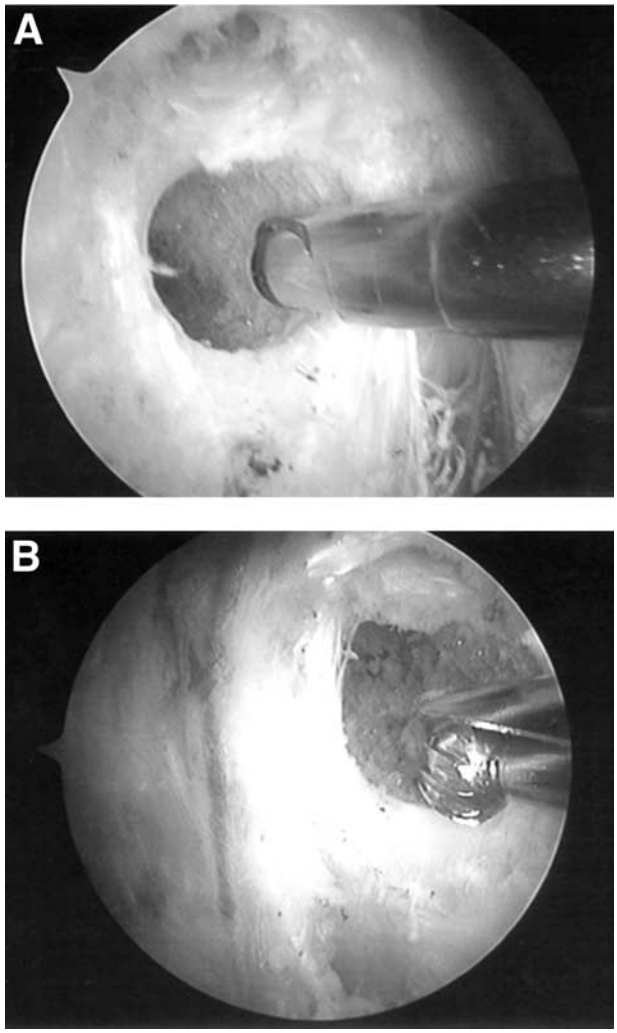

FIGURE 9. (A) Cleaning the humeral socket of bone debris and (B) chamfering the entry of the humeral socket with a burr.

cm medial the posterolateral border of the acromion, avoiding the axillary nerve[31,32] (Fig 10). Both ends of the No. 5 suture are threaded through the eyelet of the Beath pin, and the pin and sutures are pulled through the humerus. The suture will be used to pull the biceps tendon into the humeral socket (Fig 11). Before pulling the biceps tendon into the socket, a flexible guidewire for the interference screw is inserted to prevent screw divergence. To facilitate placement of this guide pin in the socket, the anteromedial cannula is brought into direct contact with the humeral socket entrance. Once the pin is inside the socket, the biceps tendon is pulled into the humerus. The ink mark at the base of the doubled portion of the tendon is visualized to insert completely into the humeral socket.

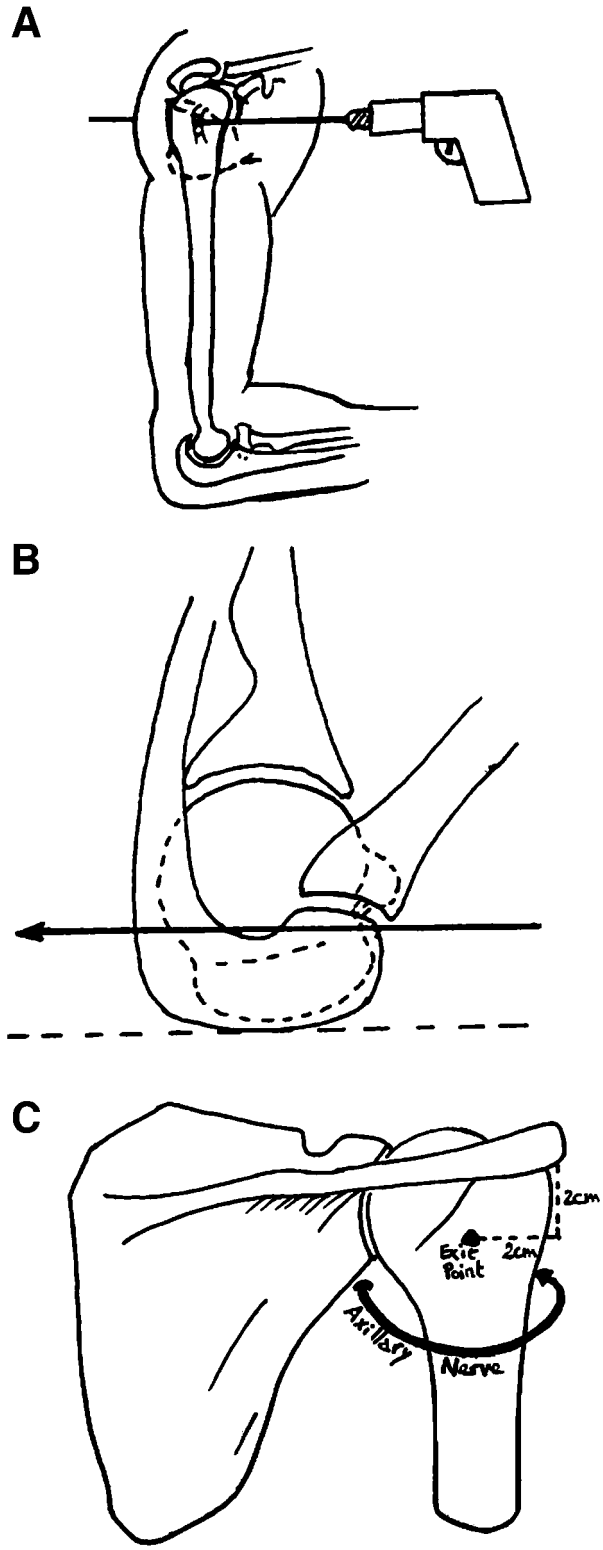

FIGURE 10. (A) The humeral guide pin is strictly perpendicular to humeral shaft and (B) parallel to lateral border of acromion. (C) The position of Beath needle in relation to axillary nerve: the target should be the posterior portal (or a point slightly lateral to it).

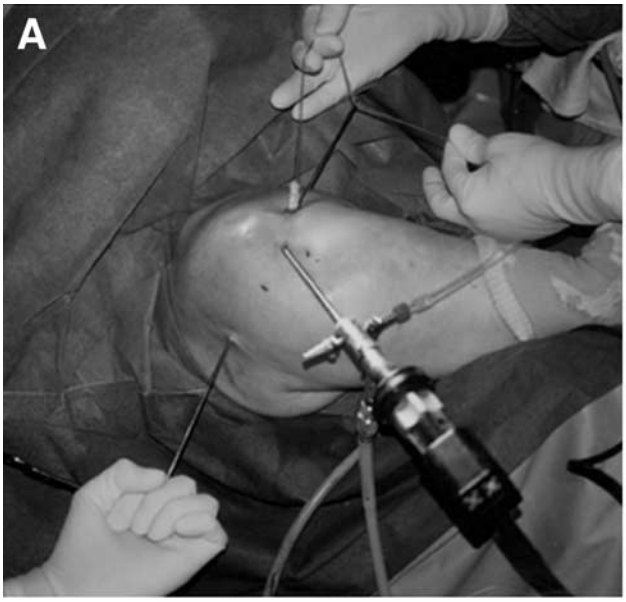

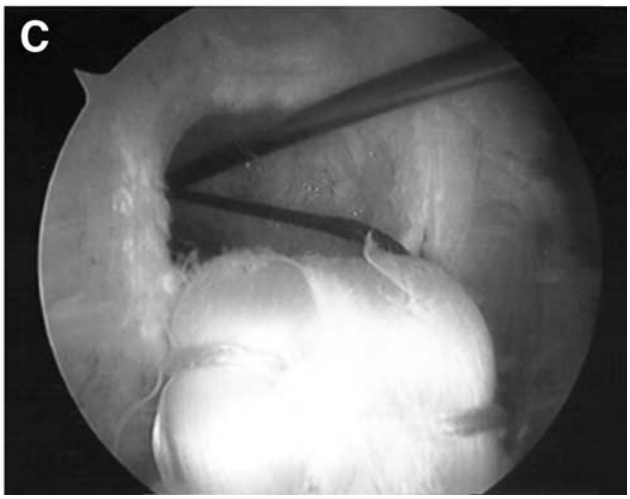

Figure 11. (A) Outside view showing the Beath needle with the traction suture passing through the humerus. (B, C) Arthroscopic views showing humeral socket, with guidewire for interference screw and pull-through suture for tendon placement.

Step 6. Interference Screw Fixation: The tendon is fixed in the hole using a 9 × 25 mm bioabsorbable interference screw (Fig 12). As a general rule, we used a 9-mm interference screw for a 7- or 8-mm socket diameter. The screws are bioabsorbable polylactic acid (PLA98) and are smooth so as not to damage the tendon (Tenoscrew, Phusis; Tornier, Stafford, TX). The screw is placed on the superior aspect of the tendon while the elbow is still flexed at 90°. Once the tip of the screw is engaged between the tendon and the socket wall, the tendon is stabilized by extending the elbow: this prevents twisting and rotation of the tendon during screw placement. After complete insertion of the tendon, fixation is checked by probing the biceps tendon. After flexing and extending the elbow, fixation of the tendon is rechecked. The transverse humeral ligament may be sutured if desired using a suture hook, and the rotator cuff is repaired if a tear is present. Tensioning of the biceps is optimal because the intra-articular part of the tendon is placed in the humeral socket instead of being in the joint.

Postoperative Care

Passive and active elbow flexion and extension are allowed the day of surgery with no restriction and no immobilization. In cases of isolated biceps tenodesis, complete passive and active motion is allowed for the shoulder. In cases with associated cuff repair, only early passive motion is allowed for the shoulder.

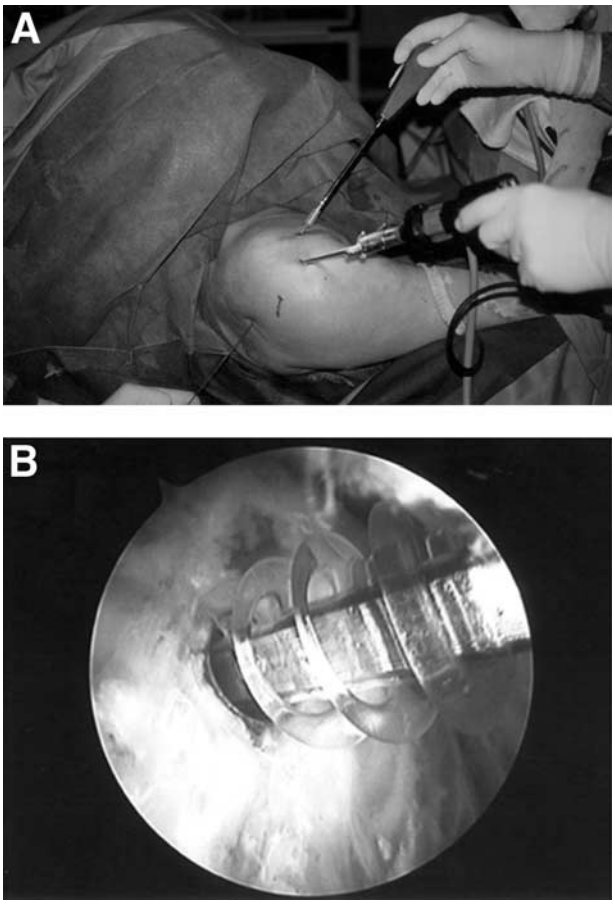

FIGURE 12. (A) Outside view showing insertion of interference screw while pulling on the traction suture. (B) Arthroscopic view of the screw insertion. The 9-mm screw is oversized compared with the humeral socket (7 or 8 mm) and is nonaggressive for the tendon (Tenoscrew, Phusis).

Patients

Between 1997 and 1999, arthroscopic biceps tenodesis has been performed in 43 cases. Indication for a tenodesis of the long head of the biceps was a pathologic biceps tendon, diagnosed preoperatively with computed tomography scan or magnetic resonance imaging (MRI) and/or intraoperatively under arthroscopy: tenosynovitis (4 cases), prerupture (15 cases), subluxation (11 cases), and dislocation (13 cases). A pathologic biceps tendon was encountered in 3 clinical situations: (1) in 3 cases of arthroscopic or mini-open rotator cuff repairs, (2) in 6 cases of isolated pathology of the biceps tendon with an intact cuff (1 type-3 SLAP lesion) or with a partial deep cuff tear, and (3) in 34 cases of massive, degenerative and irreparable cuff tears, where a tenodesis was preferred to a simple tenotomy.

Preoperatively, patients typically complained of pain in the anterior region of the shoulder, with occasional distal radiation along the anterior aspect of the upper arm and the cervical spine. Pain was more severe in overhead activities and at night. Speed's test was positive and helpful in the preoperative examination. There was tenderness on palpation of the bicipital groove (approximately 2 cm distal to the anterolateral acromion with the arm in neutral rotation). There was also tenderness with passive external rotation of the arm while the examiner was palpating the bicipital groove, as the pathologic biceps was "rolled" under the examiner's fingers.

The mean age of the patients was 63 years (25 to 78 years). All patients have been reviewed with a mean follow-up of 17 months (12 to 34 months). The shoulder function was evaluated using the Constant scoring system.[29] Mobility of the elbow was measured. Strength of the biceps was measured using a spring balance with the elbow in flexion and the forearm in supination. Radiographs of the shoulder and, in 12 cases, MRI scans, were obtained.

RESULTS

The Constant score averaged 43 points (range, 13 to 60) preoperatively and it averaged 79 points (range, 59 to 87) at review ($P < .005$). No deficit of flexion or extension of the elbow was observed compared with the contralateral side. Strength of the tenodesed biceps averaged 90% of the other side (range, 80% to 100%). The shape and contour of the biceps was conserved in all but two patients, where a failure of the tenodesis was observed clinically by distal retraction of the muscle belly. Both failures occurred early in our experience with this technique. MRI evaluation showed tight fixation of the biceps tendon in the humeral socket with no adverse reaction related to the bioabsorbable screw. No neurologic or vascular complications occurred. Four patients were diagnosed with temporary reflex sympathetic dystrophy because of persistent pain and stiffness after the operation: rehabilitation allowed to regain complete motion and all the patients were pain free at review.

DISCUSSION

We have described a new technique for arthroscopic biceps tenodesis using bioabsorbable interference screw and reported the early results. The fixation principle to tenodese the long head of the biceps is similar to the interference screw fixation used with

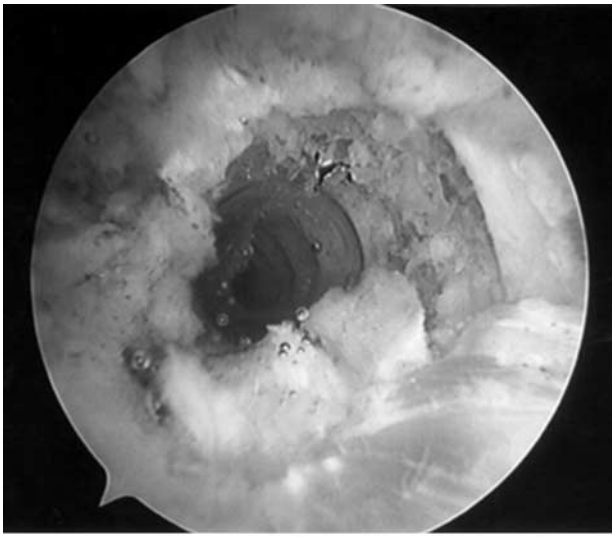

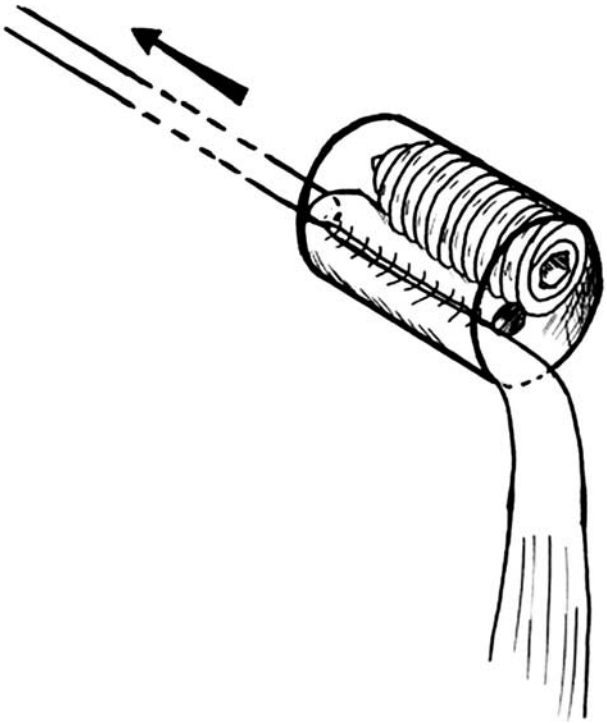

FIGURE 13. Doubling the biceps tendon has at least 3 advantages: (1) it reinforces the strength of the tendon, which cannot be damaged by the interference screw; (2) it prevents any sliding of the tendon after screw insertion ("stop-block" effect); and (3) it allows correct tensioning of the biceps muscle because the intra-articular part of the tendon is placed in the humeral socket instead of being in the joint.

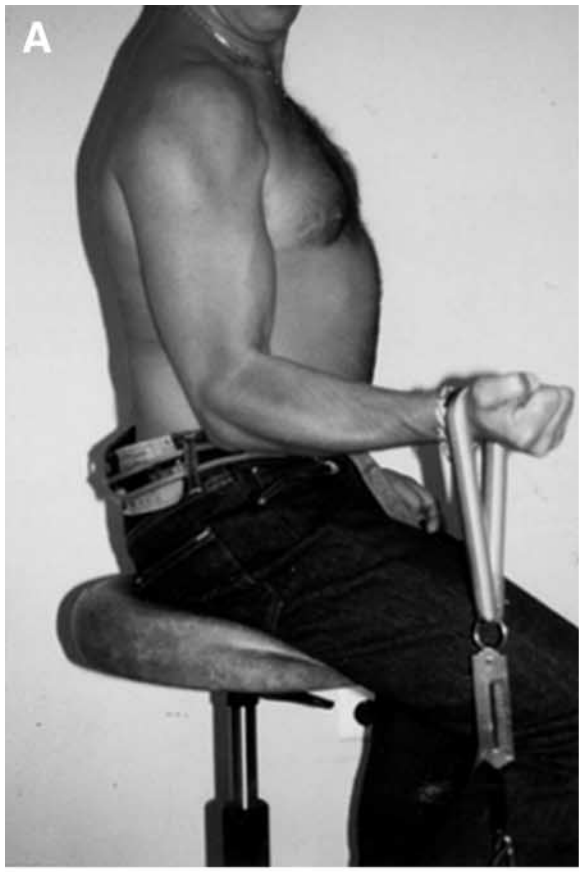

FIGURE 14. (A) Clinical appearance with restoration of the shape, tension, and strength of the biceps, and (B) MRI appearance of interference screw and final tenodesis.

success for hamstring anterior cruciate ligament reconstruction of the knee.[25-27] We have used interference screw fixation for biceps tenodesis in open surgery since 1996 and developed the arthroscopic technique in 1997.[28,29] The technique of arthroscopic biceps tenodesis is simple: after biceps tenotomy, the bicipital groove is open under arthroscopic control; the tendon is exteriorized and doubled on a suture; the biceps tendon is then pulled into a humeral socket (7 or 8 mm × 25 mm) drilled at the top of the bicipital groove; the fixation is done using a bioabsorbable interference screw, 1 mm larger than the humeral socket (8 or 9 mm × 25 mm). The results of this technique compare favorably both with standard open surgery and with previously described arthroscopic techniques using sutures.[13-18,22-24]

Tenodesis of the biceps is frequently indicated.[2,3,9-18] Performing this procedure under arthroscopic control may be beneficial for the patient in cases of pathologic biceps tendon (tenosynovitis, prerupture, subluxation or dislocation, and nonreparable SLAP lesion), whether or not the rotator cuff is torn. Basically, we have performed this procedure in 3 different clinical situations: (1) in association with arthroscopic rotator cuff repairs (3 cases), (2) in cases of isolated pathology of the biceps tendon with an intact cuff, especially in young athletes (6 cases), and (3) in cases of massive, degenerative and irreparable cuff tears with a pathologic biceps tendon, responsible for a painful shoulder (34 cases). In this last situation, tenodesis of the biceps was performed as an alternative to a simple tenotomy. In this case, a tenodesis was preferred to a simple tenotomy, especially in elderly but active and muscular patients. This avoids the distal retraction and bulging of the muscle at the elbow (which may be a source of painful contracture while working) and the possible slight decrease in supination strength.[11]

Interference fixation with absorbable screws provides strong initial fixation, at least equal if not superior to those techniques that use sutures tied over soft tissue or metallic anchors placed in the bicipital groove.[22,23] The screw that we use (Phusis) has been extensively tested in animal trials and has been used in the knee for 10 years. It is a polylactic acid composite (PLA 98) with a very slow period of resorption (up to 5 years) and avoids any inflammatory reaction.[26,34,35] We feel that our arthroscopic technique is also superior to those suturing techniques where the biceps tenodesis is performed with sutures tied over the capsule of the rotator interval.[23] Besides the fact that fixation of the tendon is less solid, such techniques preserve the intra-articular portion of the biceps, which may lead to continued pain from persistent tenosynovitis and/or persistent instability at the tendon's entry into the bicipital groove. The 2 failures that we encountered were related to technical mistakes early in our experience. In both cases when the biceps tendon was friable the diameter of the screw proved to be insufficient (7 mm), and initially we had not thought to double the tendon. As a rule, the screw diameter should be 1 mm larger than the socket diameter. Because of the usual size of the biceps tendon, we generally drill a 7 or 8 mm humeral socket and systematically use a 8 or 9 mm interference screw.

The advantages of this new arthroscopic biceps tenodesis using a bioabsorbable interference screw are multiple. First, it is a quick, safe, and reproducible technique. The humeral socket is drilled strictly perpendicular to the humeral shaft and parallel to the acromion. A guide (Shoulder-Guide) can be used to perform this procedure safely, without any risk for the axillary nerve; this makes the procedure reproducible for any surgeons (Fig 7). The axillary nerve is not at risk because the transhumeral pin exits the skin through the posterior portal or just lateral to it[32,33] (Figs 10 and 11). No neurologic or vascular complication was encountered in this series. Second, this technique is less traumatic than classical open surgery and, if no rotator cuff tear is present, this technique avoids any violation of the intact rotator cuff. Third, this technique needs only 3 small portals and is performed entirely arthroscopically, contrary to other techniques, which are done partially open.[22] Exteriorization of the biceps tendon through the anteromedial portal makes its preparation easy. Fourth, interference screw fixation provides secure fixation of the biceps tendon into bone,[25,26] allowing immediate mobilization of both the shoulder and the elbow. Fifth, doubling the biceps tendon has at least 3 advantages (Fig 13): (1) it reinforces the strength of the tendon which is not damaged by the interference screw, (2) it prevents a possible sliding of the tendon after screw insertion ("stop-block" effect), and (3) it allows an optimal tensioning of the biceps muscle. Sixth, bioabsorbable screw fixation does not interfere with MRI evaluation of the shoulder and allows late evaluation of the cuff[34] (Fig 14).

In conclusion, arthroscopic biceps tenodesis using bioabsorbable screw fixation is technically possible and gives good clinical results. This technique can be used in cases of pathologic biceps tendon, either isolated or associated with a cuff tear. A very thin, fragile, almost ruptured biceps tendon may be the technical limit of this arthroscopic technique. In such a situation, the arthroscopic procedure can be easily

converted to simple tenotomy alone or open tenodesis without difficulty. We do not pretend that arthroscopic biceps tenodesis is superior to a simple tenotomy; it is just another technical option available for the arthroscopic shoulder surgeon.

REFERENCES

1. Meyer AW. Spontaneous dislocation and destruction of long head of biceps brachii. *Arch Surg* 1928;17:493-506.
2. Hichcock HH, Bechtol CO. Painful shoulder: Observations on role of tendon of long head of biceps brachii in its causation. *J Bone Joint Surg Am* 1948;30:263-273.
3. Neviaser RJ. Lesions of the biceps and tendinitis of the shoulder. *Orthop Clin North Am* 1980;11:343-348.
4. O'Donogue DH. Subluxating biceps tendon in the athlete. *Clin Orthop* 1982;164:26-29.
5. Paavolainen P, Slatis A, Aalto K. Surgical pathology in chronic shoulder pain. In: Bateman JE, Welsh RP, eds. *Surgery of the shoulder*. Philadelphia: Mosby, 1984;313-318.
6. Warren RF. Lesions of the long head of the biceps tendon. *Instr Course Lect* 1985;30:204-209.
7. Peterson CJ. Spontaneous medial dislocation of the long biceps brachii. *Clin Orthop* 1986;21:224-227.
8. Post M, Benca P. Primary tendinitis of the long head of the biceps. *Clin Orthop* 1989;246:117-125.
9. Burkhead WZ Jr. The biceps tendon. In: Rockwood CA Jr, Matsen FA III, eds. *The shoulder*. Vol 2. Philadelphia: WB Saunders, 1990;791-836.
10. Boileau P, Walch G. So-called "isolated" supraspinatus tears: A plea for systematic opening of the rotator interval. In: Gazielly D, Gleyze P, Thomas T, eds. *The cuff*. Paris: Elsevier, 1997;320-323.
11. Walch G, Nové-Josserand L, Boileau P, Lévigne C. Subluxations and dislocations of the tendon of the long head of the biceps, *J Shoulder Elbow Surg* 1998;7:100-108.
12. Pfahler M, Branner S, Refior HJ. The role of the bicipital groove in tendinopathy of the long biceps tendon. *J Shoulder Elbow Surg* 1999;8:419-424.
13. Creenshaw AH, Kilgore WE. Surgical treatment of bicipital tenosynovitis. *J Bone Joint Surg Am*1966;48:1496-1502.
14. Froimson AL. Keyhole tenodesis of biceps origin at the shoulder. *Clin Orthop* 1974;112:245-249.
15. Dines D, Warren RF, Inglis AE. Surgical treament of lesions of the long head of the biceps. *Clin Orthop* 1982;164:165-174.
16. De Palma AF. *Surgery of the shoulder*. Philadelphia: JB Lippincott, 1983;266-276.
17. Becker DA, Cofield RH. Tenodesis of the long head of the biceps brachii for chronic bicipital tendinitis—Long term results. *J Bone Joint Surg Am* 1989;71:376-381.
18. Berleman U, Bayley I. Tenodesis of the long head of the biceps brachii in the painful shoulder: Improving the results in the long term. *J Shoulder Elbow Surg* 1995;4:429-435.
19. Walch G, Patte D, Boileau P. Luxation de la longue portion du biceps et rupture de la coiffe des rotateurs. *Rev Chir Orthop* 1990;76:95 (suppl I).
20. Curtis AS, Snyder SJ. Evaluation and treatment of biceps tendon pathology. *Arthroscopy* 1993;24:33-34.
21. Goldfarb C, Yamaguchi K. The biceps tendon: Dogma and controversies. *Sports Med Arthrosc Rev* 1999;7:93-103.
22. Snyder SJ. Arthroscope-assisted biceps tendon surgery. In: Snyder SJ, ed. *Shoulder arthroscopy*. New York: McGraw-Hill, 1994;61-76.
23. Habermeyer P, Mall U. Arthroscopic tenodesis of the long head of the biceps: Technique and results. *J Shoulder Elbow Surg* 1999;8:557 (abstr 199).
24. Gartsman G, Hammerman S. Arthroscopic biceps tenodesis. *Arthroscopy* 2000;16:550-552.
25. Blickenstaff KR, Grana WA, Egle D. Analysis of a semitendinosus autograft in a rabbit model. *Am J Sports Med* 1997; 25:4:554-559.
26. Aune AK, Ekeland A, Cawley PW. Interference screw fixation of hamstring vs patellar tendon grafts for anterior cruciate ligament reconstruction. *Knee Surg Sports Traumatol Arthrosc* 1998;6:99-102.
27. Weiler A, Windhagen HJ, Raschke MJ, Laumyer A, Hoffmann RFG. Biodegradable interference screw fixation exhibits pullout force and stiffness similar to titanium screws. *Am J Sports Med* 1998;26:119-128.
28. Boileau P, Walch G. A new technique for tenodesis of the long head of the biceps using bioabsorbable screw fixation. *J Shoulder Elbow Surg* 1999;8:557 (abstr 198).
29. Boileau P, Krishnan SG, Coste JS, Walch G. A new technique for tenodesis of the long head of the biceps using bioabsorbable screw fixation. *Tech Shoulder Elbow Surg* 2001;2:153-165.
30. Constant CR, Murley AHG. A clinical method of functional assessment of the shoulder. *Clin Orthop* 1987;214:160-164.
31. Wolf EM. Anterior portals in shoulder arthroscopy. *Arthroscopy* 1989;5:201-208.
32. Burkhead WZ, Sheinberg RR, Box G. Surgical anatomy of the axillary nerve *J Shoulder Elbow Surg* 1992;1:31-36.
33. Bryan JB, Schouder K, Tullos HS, et al. The axillary nerve and its relationship to common sports medicine shoulder procedure. *Am J Sports Med* 1986;14:113-116.
34. Athanasiou KA, Agrawal CM, Barber FA, Burkhart SS. Orthopaedic application for PLA-PGA biodegradable polymers. Current Concepts. *Arthroscopy* 1998;14:726-737.
35. Chambat P, Christel P, Eloy R, Therin M. Biocompatibility of a bioabsorbable interference screw until total resorption in a functional sheep model. Presented at the 4th EFORT Meeting, Brussels, June 3-8, 1999 (abstract book p 65).