

Arthroscopic Subscapularis Bankart Technique as a Salvage Procedure for Failed Anterior Shoulder Stabilization

Salma Chaudhury, MD · Demetris Delos, MD · Joshua S. Dines, MD ·
David W. Altchek, MD · Christopher C. Dodson, MD · Ashley M. Newman, BA ·
Stephen J. O'Brien, MD, MBA

Received: 11 March 2012/Accepted: 18 October 2013 /Published online: 10 December 2013
© Hospital for Special Surgery 2013

Abstract *Background:* Shoulder instability is a relatively common problem. Even with contemporary surgical techniques, instability can recur following both open and arthroscopic fixation. Surgical management of capsular insufficiency in anterior shoulder stabilization represents a significant challenge, particularly in young, active patients. There are a limited number of surgical treatment options. The Latarjet technique can present with a number of intraoperative challenges and postoperative complication. *Description of Technique:* We report an arthroscopic subscapularis tenodesis technique as a salvage procedure for challenging glenohumeral instability cases. Sutures are passed through the subscapularis tendon and capsule before they are tied as one in the subdeltoid space. The rotator interval is closed with superior and medial advancement of anterior and inferior tissue. This technical note carefully describes this procedure with useful technical tips, illustrations, and diagrams. *Patients and Methods:* Two clinical cases are described involving patients with recurrent instability following failed surgery who were successfully managed with this procedure. *Results:* Both cases described resulted in improved shoulder stability, range of motion, and function following management with this surgical technique. This

arthroscopic subscapularis tenodesis procedure is proposed as a useful alternative repair technique for cases of recurrent instability after failed surgery with isolated capsular insufficiency. *Conclusion:* It is believed that this arthroscopic subscapularis tenodesis technique can potentially provide similar outcomes to open bone block stabilization procedures, while reducing the risks associated with those procedures.

Keywords anterior shoulder stabilization · subscapularis · Bankart repair · shoulder instability · arthroscopic · tenodesis

Introduction

Shoulder instability is a common problem with a reported annual incidence of 2.8% in young, athletic individuals [16]. For many patients, especially those who are young and active, surgical management is often indicated to prevent recurrence. However, even with contemporary surgical techniques, instability can recur with rates of both open and arthroscopic failure at 7–19% [9, 20]. The causes for failed surgical management and recurrence are likely multifactorial, including poor preoperative planning, technical error, repeat trauma, periarticular soft tissue insufficiency, bone loss, or failed rehabilitation [4, 19].

Surgical options are limited when capsular insufficiency is present. Treatment in these cases often involves a bone block operation or the use of a soft tissue allograft. One popular alternative, the modified Latarjet procedure, is being increasingly used to address recurrent instability, particularly in the setting of capsular insufficiency and/or bone loss. Recent studies have shown that up to 90% of patients with recurrent instability have anterior glenoid rim alterations [17]. It has been hypothesized that the Latarjet procedure is successful because of the “triple effect”: (1) the glenoid bone deficiency is addressed via the coracoid bone graft, effectively lengthening the glenoid in the anteroposterior

Electronic supplementary material The online version of this article (doi:10.1007/s11420-013-9370-8) contains supplementary material, which is available to authorized users.

S. Chaudhury, MD (✉) · D. Delos, MD · J. S. Dines, MD ·
D. W. Altchek, MD · A. M. Newman, BA ·
S. J. O'Brien, MD, MBA
Sports Medicine Department, Hospital for Special Surgery,
535 East 70th Street,
New York, NY 10021, USA
e-mail: salmachaudhury@doctors.org.uk

C. C. Dodson, MD
Sports Medicine Department, Rothman Institute,
Pennsylvania, USA

dimension; (2) the inferior glenohumeral ligament is reinforced via the lower subscapularis muscle fibers which are maintained in position by the conjoint tendon, thereby acting as a sling (hammock effect); and (3) imbrication of the coracoacromial ligament (attached to the transferred coracoid process) is allowed to the lateral aspect of the anterior capsule, thereby acting as an additional restraint [8]. Perhaps the most important element of this operation is using the conjoint tendon as a soft tissue “sling” to reinforce the anteroinferior capsule by lowering the inferior 1/3 of the subscapularis so that it acts as a “dynamic” sling as the arm comes out into abduction and external rotation. This effectively pushes the humeral head posteriorly during abduction and external rotation (the so-called “at risk” position for anterior shoulder instability) [6].

Despite low rates of recurrent instability reported after the Latarjet procedure (between 1% and 4.9%), other potential problems include hardware failure/migration, non-union of the bone block, and degenerative joint disease [5, 14]. The procedure is typically performed through an open approach, though recently authors have described a completely arthroscopic technique [2, 12]. In a series of 47 patients treated with arthroscopic Latarjet plus Bankart repair, 12% of patients required conversion to open repairs. Of the patients, 13.6% had either pain or apprehension in the throwing position after 16 months [2].

The senior authors believe that a technique of arthroscopic subscapularis tenodesis for cases of recurrent instability after failed surgery secondary with isolated capsular insufficiency can potentially provide similar outcomes to open bone block stabilization procedures, while mitigating the risks associated with those procedures. The modified Latarjet procedure and subscapularis tenodesis techniques for treating anterior shoulder instability were compared in cadaveric models [7]. Controlled forced were applied to the rotator cuff and long head of biceps after surgical stabilization with the two techniques, followed by assessment of rotational range of motion, glenohumeral translation, and the path of glenohumeral articulation. Both techniques were found to effectively reduce anterior and inferior translation in six matched pairs of cadaveric shoulders. External and internal rotation was significantly decreased following both subscapularis tenodesis and the modified Latarjet procedure. Specifically, the subscapularis tenodesis technique reduced external rotation by 16° compared to the modified Latarjet procedure ($p=0.03$). The repair technique did not cause any significant differences in glenohumeral translation. Thus, the subscapularis tenodesis procedure may have an important role in the treatment of select cases of recurrent instability.

This case report describes an arthroscopic subscapularis tenodesis technique as a salvage procedure for challenging glenohumeral instability cases and describes two clinical cases managed with this procedure with adequate follow-up. The authors have obtained the patient’s informed written consent for print and electronic publication of the case report. No institutional review board approval was required for this study. None of the authors have any conflicts of interest with this manuscript.

Technique

The patient is placed in the beach chair position ensuring that all bony prominences are well-padded. An examination under anesthesia is performed to assess passive range of motion and instability. A standard posterior arthroscopic portal is established and diagnostic arthroscopy is performed to confirm that there is no significant bone loss on the humeral head or glenoid that would require an open stabilization procedure involving bone grafts.

An arthroscopic subscapularis tenodesis (“Bankart repair”) begins by creating two standard anterior portals in the rotator interval, including twin anterior portals as described by Laurencin et al. [13]. A 70° scope is frequently used to help with visualization. A third portal is placed high and medial in the rotator interval to allow for pulling up of the tissue with multiple sutures placed in the subscapularis and capsule together. The subscapularis and capsule are pulled together away from the glenoid, as is done with a standard arthroscopic stabilization (Fig. 1). The anterior glenoid neck and rim are debrided down to bleeding cancellous bone to enhance healing potential. Two or three suture anchors are placed in a standard fashion and impacted onto the articular margin of the glenoid at about the 4 and 5 o’clock positions, through the inferior interval portal. The steps of this procedure are demonstrated by the illustration in Fig. 2. Using a tissue-piercing device, a suture from each anchor is shuttled through the middle to lower 1/3 of the muscle belly of the subscapularis tendon where there is usually good tendon, before piercing the capsule with the same instrument. The subdeltoid space is exposed through a subdeltoid approach as described by O’Brien et al. [15]. The sutures are retrieved and passed in a mattress fashion. The sutures are tied in the subdeltoid space as would be done in an open procedure, with the shoulder in approximately 30° of external rotation to prevent overtightening and constraining of the joint.

The inferior capsule and anterior band are pulled up to remove any redundancy anteriorly, inferiorly, or even posteriorly (see Fig. 3). The rotator interval is then closed through the same technique as would be utilized with a pants over vest interval closure. This is performed using suture retrievers and an EXPRESSEW™ II (Depuy, Warsaw, IN, USA) suture passer to pass the suture through the anterior edge of the supraspinatus. The figures show the medial and superior advancement of the inferior and anterior tissue, with subsequent closure of the rotator interval (Fig. 4). This mimics entirely in technique an open Bankart procedure; the only difference is that the capsule and the subscapularis muscle are manipulated and tied as one unit.

Case Studies

Case 1 A 27-year-old female competitive swimmer presented with right shoulder pain and antero-inferior capsular laxity. Initial management at another institution involved arthroscopic capsular plication, but the patient suffered from excessive tightening and only

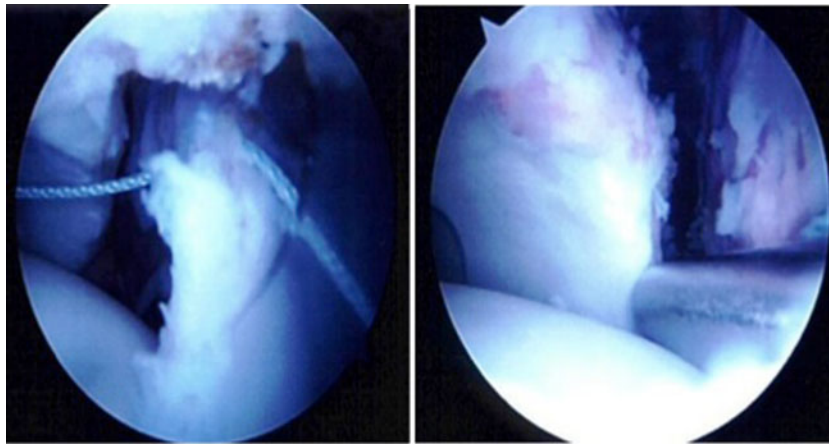


Fig. 1. The subscapularis and capsule are retracted together after tagging with a suture. The anterior glenoid edge is exposed for placement of suture anchors.

had 10° of external rotation on the affected shoulder. The patient had 90° of external rotation on the contralateral shoulder. Both were measured with the arm at the side as well as with the arm abducted to

90°. Her pain and antero-inferior laxity recurred despite arthroscopic removal of sutures and manipulation. Due to absent capsule anteriorly and minimal tissue attached to the glenoid, the

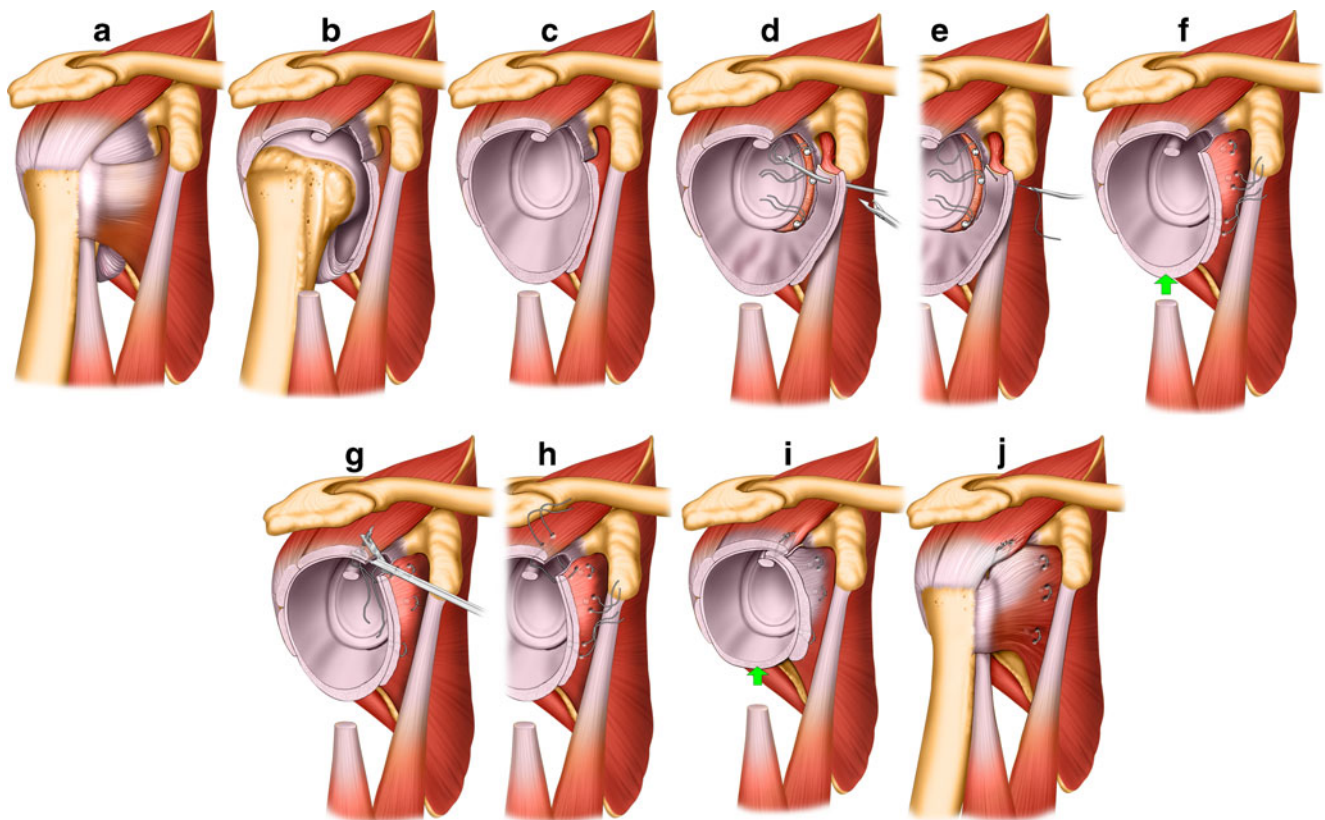


Fig. 2. **a–c** These illustrations depict the glenohumeral joint in different degrees of dissection showing the patulous capsule in both **b** and **c**. Patients who undergo a subscapularis Bankart repair have poor tissue quality of the anterior inferior capsule. **d–f** The anterior capsule, along with the subscapularis, is dissected as one unit, after debridement of the anterior edge of the interface of the articular cartilage with the bone, away from the anterior glenoid. The area is thoroughly debrided and then three anchors are placed at 1, 3, and 5 o'clock in order to advance the capsule. The tissue is then advanced using a bird beak device to pull the sutures medially through the capsule and the muscle as one unit. **g, h** A rotator interval closure is performed after the medial capsule and muscle are attached to the anterior edge of the glenoid getting rid of any redundancy. A suture passing device is used to place a horizontal mattress suture to close the rotator interval, bringing up the subscapularis tendon, and capsule to the anterior edge of the supraspinatus taking care not to incorporate the biceps tendon in the stitch. **i, j** These illustrations demonstrate a completed subscapularis Bankart where the anterior inferior capsule, as well as the subscapularis, is advanced superiorly and attached medially through three anchors. The rotator interval is then closed with a horizontal mattress suture, taking care not to incorporate the biceps tendon. The horizontal mattress suture is performed in a “pants over vest” fashion.

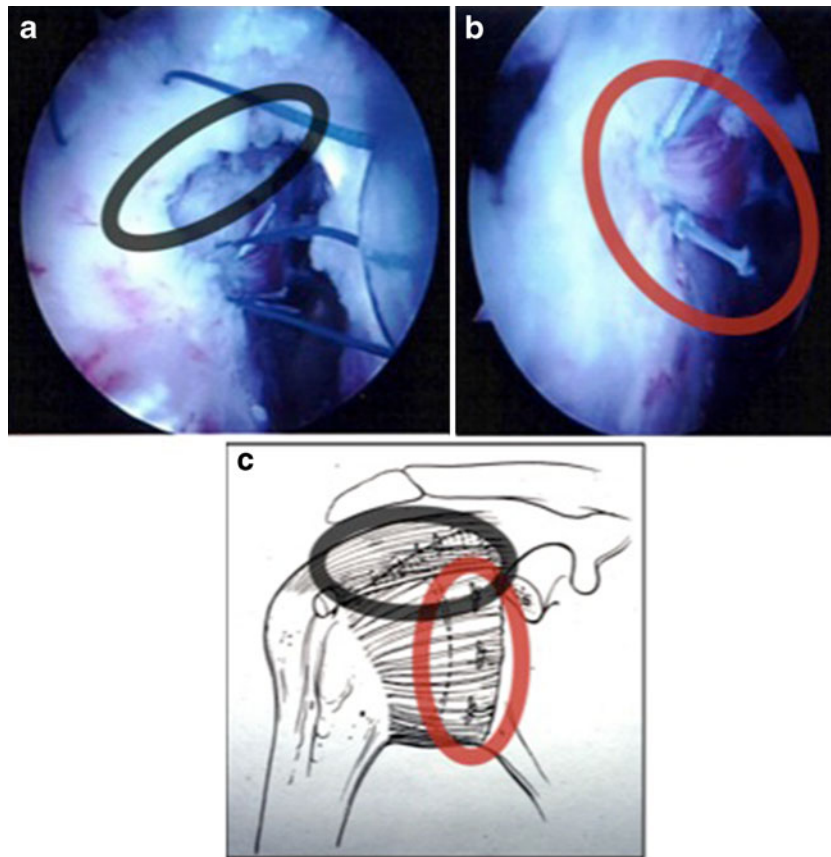


Fig. 3. **a** An arthroscopic Bankart repair in progress, with closure of the rotator interval. **b** View of subscapularis Bankart repair from subdeltoid space. **c** Diagrammatic representation of images **a** and **b** during subscapularis Bankart repair.

patient underwent an arthroscopic subscapularis Bankart procedure. The patient was immobilized in a sling for 4 weeks, with protected external rotation. She reported excellent stability, and after 6 months returned to her pre-injury level of competitive swimming.

Case 2 A 21-year-old female former college diver presented with recurrent left shoulder instability despite two failed arthroscopic stabilizations. Failure was hypothesized to be due to poor capsular tissue with

pull through of the sutures. An MRI revealed capsular insufficiency without any bony loss. The patient was managed with an arthroscopic subscapularis Bankart procedure. Six months after her procedure, the patient had an excellent range of motion with no translation detected with the load and shift test, and a negative apprehension test. Forward elevation was 170° and external rotation was 90° on the affected left side compared to 175° and 110° , respectively on the intact, right side.

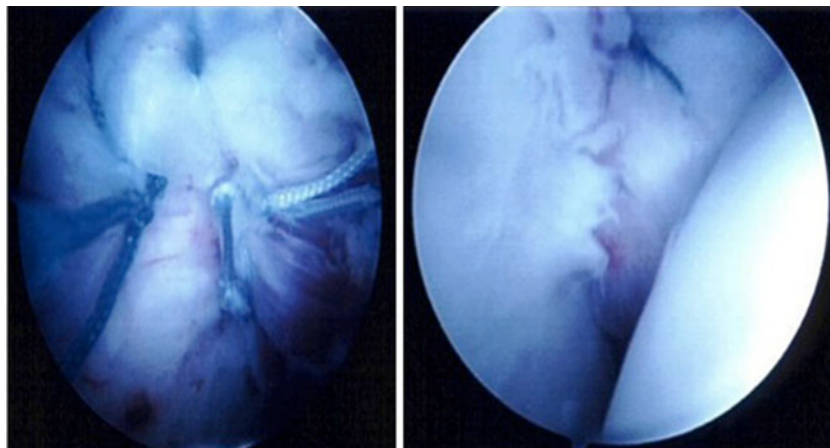


Fig. 4. Outside and inside arthroscopic view of a completed subscapularis Bankart repair.

Discussion

Failed anterior stabilization surgery presents a significant clinical challenge as contemporary instrumentation and arthroscopic techniques are limited in the revision setting [3]. For recurrent instability secondary to soft tissue insufficiency, the Latarjet procedure has been advocated as a means of limiting the risk of redislocation. While it has demonstrated positive results in several studies [1, 10, 11, 18, 21], the Latarjet procedure can be technically demanding. Furthermore, it is associated with significant risks including hardware complications.

Other options for treating instability secondary to soft tissue insufficiency include more historical options such as the Putti-Platt procedure and the use of allografts. However, allografts are associated with a number of additional risks including infection and disease transmission, graft failure, increased or late graft laxity, requirement for open surgery, poor outcomes, etc.

In an attempt to use a simpler, less invasive method, we have developed an arthroscopic “subscapularis Bankart-type” tenodesis procedure. We refer to it as the subscapularis Bankart as the same principles of a Bankart repair are applied the subscapularis tendon to complete the procedure. As described above, it can be done entirely via an arthroscopic approach, which may limit morbidity in comparison to an open procedure. Furthermore, in most surgeons’ hands, it can be performed in less time, and the learning curve is less steep than with the Latarjet or other bone block procedures. Prior to using this technique, we would typically perform open procedures using bone graft or allograft tissues. We now believe that similar outcomes can be achieved with this less invasive technique in select patients with less morbidity. We recommend that postoperatively patients spend 4 weeks in a sling and then start physical therapy during that time with passive motion to 90° in the plane of the scapula. Patients can expect to return to full sports at 5–6 months.

A simple clinical algorithm to aid appropriate patient selection should involve consideration of the tissue quality, whether there is bony involvement and the functional demands of the patient. This technique is ideally indicated for cases with recurrent instability with poor capsular tissue with no bone loss. A revision arthroscopic Bankart procedure is ideally suited to cases with good tissue quality and no bone loss, in noncontact athletes. Open stabilization should be considered if there is no bone loss, for athletes involved in contact sports. Latarjet or other bony procedures should be considered if there is bone loss on the glenoid side or a Hill–Sachs lesion.

We speculate that the benefits of this procedure stem from the fact that deficient capsule can be supplemented with subscapularis tendon and act as an inferior glenohumeral ligament. The tenodesis portion fixes the inferior subscapularis tendon in a biomechanically favorable position for restraining the glenohumeral joint. While we cannot be certain of the exact mechanism of stabilization, we hypothesize that it is most likely due to the subscapularis acting like an anterior restraint. We performed a cadaveric

biomechanical study which demonstrated that following this technique, there was no significant effect on the subscapularis tendon or the range of motion in a cadaver model (unpublished data) [7].

In conclusion, the subscapularis tenodesis (Bankart) procedure described in this small case series is an alternative salvage option for patients who have recurrent instability secondary to significant capsule/soft tissue insufficiency. It is not advocated for patients with significant glenoid bone defects (>20%) or large Hill–Sachs defects. As it can be performed arthroscopically, it may potentially decrease patients’ perioperative pain and lower the potential infection rate compared to open procedures. Furthermore, this procedure is less technically demanding than traditional open stabilization procedures, which may benefit many orthopedic surgeons who treat this difficult clinical problem.

Disclosures

Conflict of Interest: Salma Chaudhury, MD, Christopher C. Dodson, MD, Demetris Delos, MD, David W. Altchek, MD, Ashley M. Newman, BA, and Stephen J. O’Brien, MD, MBA have declared that they have no conflict of interest. Joshua S. Dines, MD is a paid consultant for Biomimetics, Conmed, and Phussis, outside the work.

Human/Animal Rights: All procedures followed were in accordance with the ethical standards of the responsible committee on human experimentation (institutional and national) and with the Helsinki Declaration of 1975, as revised in 2008 (5).

Informed Consent: Informed consent was waived from all patients for being included in the study.

Required Author Forms Disclosure forms provided by the authors are available with the online version of this article.

References

- Allain J, Goutallier D, et al. Long-term results of the Latarjet procedure for the treatment of anterior instability of the shoulder. *J Bone Joint Surg Am.* 1998; 80A(6): 841-852.
- Boileau P, Mercier N, et al. Arthroscopic Bankart–Bristow–Latarjet procedure: the development and early results of a safe and reproducible technique. *Arthroscopy J Arthroscopic Related Surg.* 2010; 26(11): 1434-1450.
- Boileau P, Richou J, et al. The role of arthroscopy in revision of failed open anterior stabilization of the shoulder. *Arthroscopy J Arthroscopic Related Surg.* 2009; 25(10): 1075-1084.
- Boileau P, Villalba M, et al. Risk factors for recurrence of shoulder instability after arthroscopic bankart repair. *J Bone Joint Surg A.* 2006; 88(8): 1755-1763.
- Burkhart SS, De Beer JF, et al. Results of modified Latarjet reconstruction in patients with anteroinferior instability and significant bone loss. *Arthroscopy J Arthroscopic Related Surg.* 2007; 23(10): 1033-1041.
- Dines J. *The “at risk” position for anterior shoulder instability.* San Diego: American Shoulder and Elbow Society Speciality Day; 2011.
- Dodson C, Dines JS, et al. *Biomechanical analysis comparing the modified Latarjet procedure with a novel subscapularis tenodesis technique in a cadaveric anterior shoulder instability model.* Providence, Rhode Island: American Orthopaedic Society for Sports Medicine; 2010.

8. Edwards TB, Walch G. The Latarjet procedure for recurrent anterior shoulder instability: rationale and technique. *Oper Techn Sport Med.* 2002; 10(1): 25-32.
9. Gartsman GM, Roddey TS, et al. Arthroscopic treatment of anterior–inferior glenohumeral instability. Two to five-year follow-up. *J Bone Joint Surg Am- Series A.* 2000; 82(7): 991-1003.
10. Hovelius L, Sandstrom B, et al. One hundred eighteen Bristow–Latarjet repairs for recurrent anterior dislocation of the shoulder prospectively followed for fifteen years: study I—clinical results. *J Shoulder Elb Surg.* 2004; 13(5): 509-516.
11. Hovelius LK, Sandstrom BC, et al. Long-term results with the Bankart and Bristow–Latarjet procedures: recurrent shoulder instability and arthropathy. *J Shoulder Elb Surg.* 2001; 10(5): 445-452.
12. Lafosse L, Boyle S. Arthroscopic Latarjet procedure. *J Shoulder Elb Surg.* 2010; 19(2 SUPPL): 2-12.
13. Laurencin CT, Deutch A, et al. The superolateral portal for arthroscopy of the shoulder. *Arthroscopy.* 1994; 10(3): 255-258.
14. Maynou C, Cassagnaud X, et al. Function of subscapularis after surgical treatment for recurrent instability of the shoulder using a bone-block procedure. *J Bone Joint Surg British Volume.* 2005; 87B(8): 1096-1101.
15. O'Brien SJ, Miller AN, et al. Arthroscopic subdeltoid approach to the biceps transfer. *Oper Techn Sport Med.* 2007; 15(1): 20-26.
16. Owens BD, Duffey ML, et al. The incidence and characteristics of shoulder instability at the United States Military Academy. *Am J Sports Med.* 2007; 35(7): 1168-1173.
17. Piasecki DP, Verma NN, et al. Glenoid bone deficiency in recurrent anterior shoulder instability: diagnosis and management. *J Am Acad Orthop Surg.* 2009; 17(8): 482-493.
18. Spoor AB, Malefijt JD. Long-term results and arthropathy following the modified Bristow–Latarjet procedure. *Int Orthop.* 2005; 29(5): 265-267.
19. Tauber M, Resch H, et al. Reasons for failure after surgical repair of anterior shoulder instability. *J Shoulder Elb Surg.* 2004; 13(3): 279-285.
20. Voos JE, Livermore RW, et al. Prospective evaluation of arthroscopic bankart repairs for anterior instability. *Am J Sports Med.* 2010; 38(2): 302-307.
21. Young AA, Maia R, et al. Open Latarjet procedure for management of bone loss in anterior instability of the glenohumeral joint. *J Shoulder Elb Surg.* 2011; 20(2): S61-S69.