


Arthroscopic Ultrasound Assessment of Articular Cartilage in the Human Knee Joint: A Potential Diagnostic Method

Cartilage
2(3) 246–253
© The Author(s) 2011
Reprints and permission:
sagepub.com/journalsPermissions.nav
DOI: 10.1177/1947603510391781
http://cart.sagepub.com


Erna Kaleva¹, Tuomas Virén¹, Simo Saarakkala^{1,2}, Janne Sahlman³, Joonas Sirola³, Jani Puhakka⁴, Teemu Paatela⁵, Heikki Kröger^{3,6}, Ilkka Kiviranta^{4,5}, Jukka S. Jurvelin¹, and Juha Töyräs^{1,7}

Abstract

Objective: We tested whether an intra-articular ultrasound (IAUS) method could be used to evaluate cartilage status arthroscopically in human knee joints *in vivo*. **Design:** Seven patients undergoing arthroscopic surgery of the knee were enrolled in this study. An ultrasonic examination was conducted using the same portals as in the arthroscopic surgery. A high-frequency (40-MHz) ultrasound transducer (diameter = 1 mm) was directed to the desired location on the articular surface under arthroscopic control. In addition to ultrasound data, an IAUS video and optical video through the arthroscope were recorded. Classification of cartilage injuries according to International Cartilage Repair Society, as conducted by the orthopedic surgeon, provided reference data for comparison with the IAUS. **Results:** The IAUS method was successful in imaging different characteristics of the articular surfaces (e.g., intact surface, surface fibrillation, and lesions of varying depth). In some cases, also the subchondral bone and abnormal internal cartilage structure were visible in the IAUS images. Specifically, using the IAUS, a local cartilage lesion of 1 patient was found to be deeper than estimated arthroscopically. **Conclusions:** The IAUS method provided a novel arthroscopic method for quantitative imaging of articular cartilage lesions. The IAUS provided quantitative information about the cartilage integrity and thickness, which are not available in conventional arthroscopy. The present equipment is already approved by the Food and Drug Administration for intravascular use and might be transferred to intra-articular use. The invasiveness of the IAUS method might restrict its wider clinical use but combined with arthroscopy, ultrasonic assessment may enlarge the diagnostic potential of arthroscopic surgery.

Keywords

arthroscopy, ultrasound, cartilage, subchondral bone, knee

Cartilage and subchondral bone lesions, including structural and compositional changes, are poorly detected in their early stages with the current noninvasive clinical diagnostic methods such as clinical examination, radiography, or magnetic resonance imaging (MRI). With x-ray imaging, only an indirect indication of cartilage erosion, the narrowing of the joint space, is revealed. The MRI enables visualization of the cartilage tissue, but currently the resolution of the clinical MRI is not sufficient to allow detection of incipient fibrillation of the tissue related to early osteoarthritis (OA). Arthroscopy enables direct inspection of the surface of the articular cartilage, but the diagnosis is based only on qualitative and subjective visual evaluation and manual mechanical palpation. Another example of a challenging joint damage is osteochondritis dissecans (OCD), which might not be visible in the arthroscopy if the cartilage surface is intact. In addition to diagnosing diseases and disorders of articular cartilage and subchondral bone, more accurate delineation of articular areas in need of local

treatment would be valuable.¹ Further development of many promising cartilage repair techniques, such as autologous chondrocyte implantation or microfracturing and the novel

¹Department of Physics and Mathematics, University of Eastern Finland, Kuopio Campus, Kuopio, Finland

²Department of Diagnostic Radiology, University of Oulu, Oulu, Finland

³Department of Orthopaedics and Traumatology, Kuopio University Hospital, Kuopio, Finland

⁴Orthopaedic Research Laboratory, University of Helsinki, Helsinki, Finland

⁵Department of Orthopaedics and Traumatology, Helsinki University Hospital, Helsinki, Finland

⁶Bone and Cartilage Research Unit, University of Eastern Finland, Kuopio, Finland

⁷Department of Clinical Neurophysiology, Kuopio University Hospital, Kuopio, Finland

Corresponding Author:

Erna Kaleva, PhD, Department of Physics and Mathematics, University of Eastern Finland, Kuopio Campus, PO Box 1627, FI-70211 Kuopio, Finland
Email: erna.kaleva@gmail.com

Table 1. Descriptions of the Patients Involved in the Study

Patient Number	Age	Sex	Case History	Current Arthroscopy Findings
1	69	Male	Earlier diagnosis of osteoarthritis in the right knee, now pain also in the left knee	Osteophytes, exposed bone, ICRS grade 4 cartilage lesions
2	22	Female	Suspected patellofemoral osteoarthritis	Fibrillation and softening of patellar cartilage
3	58	Female	Pain in the knee not related to trauma. Meniscal tear detected with MRI.	Meniscal tear
4	30	Male	Drilling of medial femur 4 years earlier. Original cartilage damage likely due to trauma.	Tibial cartilage soft, cracks extending to bone
5	30	Male	Former tear of meniscus. Suspicion of osteoarthritis on patellofemoral joint surfaces.	Chondromalacia of the patella
6	34	Female	Earlier dislocation of right patella. Now anterior knee pain and recurrent subluxation of the right patella.	Slightly subluxated patella. Chondral ICRS grade 3 lesion of patella and ICRS grade I lesion of lateral tibial condyle.
7	29	Male	Earlier treatment of left patellar malalignment with Helfet operation. Now mechanical symptoms of left knee. Loose body in the x-ray.	Congruent patellofemoral joint. Loose body. ICRS grade 3 lesion of the patella and grade 4 lesion of medial femoral condyle.

ICRS = International Cartilage Repair Society; MRI = magnetic resonance imaging.

disease-modifying drugs for OA, require more sensitive methods capable of imaging and quantifying the effectiveness of the treatments *in vivo*.¹⁻³

High-frequency quantitative ultrasound imaging (QUI) has been successfully used *in vitro* to evaluate and correlate the variation in ultrasound reflection from the surface of the cartilage with the variation in superficial roughness and composition of the tissue related to OA, maturation, enzymatic degradation, or spontaneous repair.⁴⁻¹¹ Conventional ultrasound with lower frequencies, conducted from outside of the knee¹²⁻¹⁶ or during an open surgery,¹⁷ has also been used to relate ultrasonographic findings to the condition of the articular cartilage. We have recently introduced a new intra-articular ultrasonic (IAUS) application¹⁸ based on Food and Drug Administration (FDA)-approved intravascular ultrasound (IVUS) catheters conventionally used in cardiographic imaging.^{19,20} The catheter can be applied into the joint space through a tubular instrument or even a thin injection needle. The advantages of this new method compared with widely used ultrasonic imaging conducted from outside of the joint¹²⁻¹⁶ include higher spatial resolution due to higher ultrasound frequency (40 MHz) and absence of disturbing soft tissue layers since the imaging is done inside the joint capsule. Furthermore, the IAUS method enables imaging of cartilage surfaces under the patella, which is not possible with the conventional external ultrasound imaging. The resolution of the IAUS (~40 μm) system is also superior to that of clinical X-ray imaging (~200 μm) or MRI (~500 μm). We have validated the IAUS method *in vitro* with bovine, rabbit,²¹ and equine²² cartilage and *ex vivo* in simulated arthroscopic conditions with a bovine knee joint.¹⁸ The IAUS method was able to detect and quantify collagen disruption and increased roughness of the

articular surface in enzymatically^{18,23} or mechanically¹⁸ damaged bovine cartilage and to quantify the integrity and qualitatively evaluate the integration and internal structure of spontaneously and surgically repaired rabbit²¹ and equine²² cartilage tissue. Furthermore, Huang and Zheng²³ showed that the thickness of cartilage determined *in vitro* with an IVUS system correlates highly with the thickness determined with a reference ultrasound device. Quantitative ultrasonic point measurements of human articular cartilage have already been done *in vivo* during arthroscopic surgery.²⁴⁻²⁷ However, quantitative intra-articular ultrasound imaging of human cartilage has not been conducted *in vivo*.

The purpose of this study was to test whether the IAUS method would be feasible for human patients and whether it would enable diagnosing various types of articular cartilage defects *in vivo*. We calculated ultrasound parameters that quantify the reflection and scattering properties and superficial roughness of the cartilage and further examined the qualitative imaging potential of the IAUS method. We hypothesized that at least the superficial cartilage defects are visible and quantifiable in human joints *in vivo*. We also hypothesized that we might be able to see changes in the subchondral bone as well, although the greater thickness of human cartilage compared to bovine cartilage, for example, might prevent imaging of the subchondral bone due to strong attenuation of the high-frequency ultrasound.

Methods

Seven patients (**Table 1**) undergoing an arthroscopic surgery of the knee as treatment or examination of their joint disease or condition were enrolled in the present study. Informed consent was obtained from the patients. The

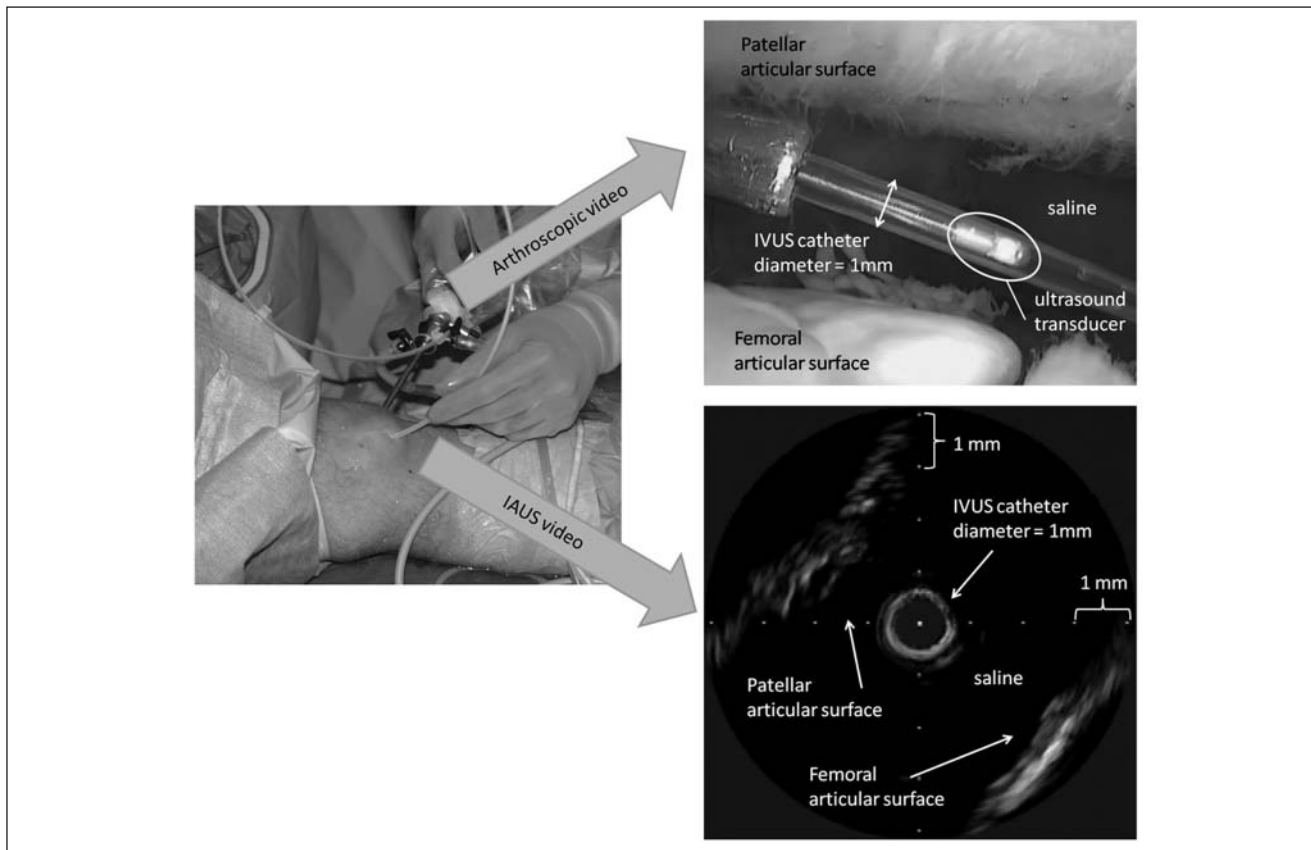


Figure 1. During arthroscopy, an arthroscopic video and an intra-articular ultrasound (IAUS) video were recorded. The patellofemoral cartilage surfaces of the knee joint are visible on both videos. The patellar articular surface is clearly more fibrillated than the femoral articular surface. The intravascular ultrasound (IVUS) catheter was inserted into the saline-filled joint space through a shielding tube. The cross section of the IVUS catheter can be seen at the center of the IAUS image.

arthroscopies took place at Kuopio University Hospital (conducted by J. Sahlman and J. Sirola) and Helsinki University Hospital (conducted by T. Paatela), and the study was in compliance with the ethical guidelines of the authors' institutions. The patients were evaluated clinically and in some cases also by MRI. The indication for conducting an arthroscopy was a suspicion of articular or meniscal pathology, such as meniscal tear, chondral lesion, osteoarthritis, or loose body. During the normal arthroscopic procedures, an ultrasound examination was carried out using the same anteromedial and anterolateral portals that were used for the surgery. No special positioning of the knee was required due to the ultrasonic measurements. The articular surfaces of the knee joints were classified by the operating surgeon according to the International Cartilage Repair Society (ICRS) grading system¹ (**Table 2**).

The ultrasound measurement system consisted of a clinical IVUS main unit (ClearView Ultra, Boston Scientific Corporation, San Jose, CA) and a miniature unfocused high-frequency ultrasound transducer (40 MHz, -6 dB bandwidth 30.1-45.3 MHz) attached to a tip of a rotating

(30 rounds per second) wire inside a catheter (diameter = 1 mm). The ultrasound catheter was inserted into the knee joint through a shielding tube and directed to the desired location on the articular surface with arthroscopic visualization. The measurement sites were the central part of the patella, the femoral groove, and the central plateau of the tibia. A video of the ultrasound measurements was recorded from the IVUS main unit. **Figure 1** displays a still image taken from the IAUS video from the patellofemoral knee joint of patient 1. During a full rotation of the IVUS probe, 255 individual radiofrequency signals were collected, each of them corresponding to a polar angle of about $360^\circ/255 \approx 1.4^\circ$. To calculate quantitative ultrasound parameters, radiofrequency signals from one full rotation of the probe were recorded by the IVUS main unit and digitized at a sampling frequency of 250 MHz using a digital oscilloscope (Wave Runner 6051A, LeCroy Corporation, Chestnut Ridge, NY). The signals were stored for offline analysis on a laptop computer using custom-made Labview software (version 8.2, National Instruments Corporation, Austin, TX). The perpendicular angle of incidence between the articular sur-

Table 2. Articular Cartilage Injury Classification according to the International Cartilage Repair Society (ICRS)

Grade	Description of the Condition of the Cartilage Tissue
0	Normal
1	Nearly normal. Superficial lesions. Soft indentation and/or superficial fissures and cracks.
2	Abnormal. Lesions extending down to <50% of cartilage depth.
3	Severely abnormal. Cartilage defects extending down >50% of cartilage depth as well as down to calcified layer and down to but not through the subchondral bone. Blisters are included in this grade.
4	Severely abnormal. Cartilage defects extending through the subchondral bone.

face and the direction of the ultrasound beam was adjusted manually by maximizing the amplitude of the ultrasound reflection. This was done by monitoring the brightness of the articular surface on the IVUS monitor. At every measurement site, 3 successive measurements were conducted, and the best measurement (one with the highest reflection amplitude) was chosen for calculation of the quantitative ultrasound parameters.

The quantitative ultrasound parameters were calculated using custom-made Matlab functions (Matlab 7.0.4, Mathworks, Inc., Natick, MA).¹⁸ The reflection coefficient (R)¹⁰ describes the reflection amplitude of the ultrasound signal from the articular surface relative to that from a perfect reflector (in this study, a saline-polished steel interface; R = 93.7%). The integrated reflection coefficient (IRC)⁶ is essentially the same as the R, but the IRC is defined in the frequency domain over a -6 dB frequency bandwidth, thus incorporating a larger portion of the signal in the analysis. The apparent integrated backscatter (AIB)⁶ measures the average backscatter of the ultrasonic signal from within the cartilage tissue. For the calculation of the reflection and scattering parameters R, IRC, and AIB, 1 signal acquisition out of 255 was selected that had the smallest time of flight and thus corresponded to the closest distance and best perpendicularity between the articular surface and the ultrasound probe. The ultrasound roughness index (URI)¹⁰ describes the roughness of the articular surface. To evaluate the URI, 11 signal acquisitions out of 255 were selected, the one with the smallest time of flight and 5 acquisitions on both sides of it. The acquisitions used for the calculation of the URI thus corresponded to a polar angle of $11 \times 1.4^\circ \approx 15.5^\circ$. Typically, the distance between the IVUS transducer and the articular surface was 1 to 2 mm, and thus the length of the path on the surface of the cartilage used for the calculation of the URI was from 0.27 to 0.55 mm.

In addition to the ultrasonic data, a video (see **Figure 1**) from the arthroscopy was recorded through the arthroscope (30° direction of view, diameter = 4 mm; Telecam SL PAL,

Table 3. The Intra-Articular Ultrasound (IAUS) Score

Grade	Description of the Condition of the Cartilage Tissue
0	Normal
1	Nearly normal. Superficial lesions. Superficial fissures and cracks.
2	Abnormal. Lesions extending down to <50% of cartilage depth.
3	Severely abnormal. Cartilage defects extending down >50% of cartilage depth as well as down to calcified layer and down to but not through the subchondral bone. Blisters are included in this grade.
4	Severely abnormal. Cartilage defects extending through the subchondral bone.

Karl Storz GmbH, Tuttlingen, Germany). The video was used as a reference for confirming the ICRS grade addressed to the articular surface at each measurement site by the operating surgeon. Furthermore, during the arthroscopy, the surgeon used a blunt arthroscopic hook to subjectively test the stiffness of the cartilage.

Afterward, one operating surgeon examined 13 blind coded still images from the IAUS video (all data were successfully obtained from 13 measurement sites [7 patients * 1-3 sites per patient = 13 sites]) and was asked to give them an IAUS score (**Table 3**), which had similar descriptions of the cartilage status as the ICRS grade (**Table 2**) excluding the information about manual palpation. Spearman's correlation test was used to compare the values of the ICRS grade with the IAUS score and with the URI.

Results

The arthroscopic ultrasound imaging revealed different characteristics of the articular surfaces in the knee joints of the human patients *in vivo* (**Figure 2**). Comparison of **Figure 2a,b** demonstrates the ability of the IAUS method to differentiate an intact cartilage surface from a fibrillated one both qualitatively and quantitatively. In fibrillated cartilage, the values of the R and IRC decreased, and the value of the URI increased. According to the arthroscopic finding at the measurement site of **Figure 2b**, the cartilage was slightly fibrillated and softened (ICRS grade 1).

At some measurement sites, the cartilage was thin enough to enable detection of the ultrasonic reflection from the cartilage-subchondral bone interface, enabling measurement of cartilage thickness. The thicknesses of the cartilage layers, evaluated from the representative IAUS images (**Figure 2a-e**), varied from 0.65 to 1.65 mm. The cartilage in **Figure 2a** is intact and in **Figure 2b** slightly fibrillated, and the cartilage thicknesses (1.65 mm and 0.95 mm, respectively) are in the range of normal thickness values in a human knee joint.²⁸⁻³⁰ In the IAUS image in

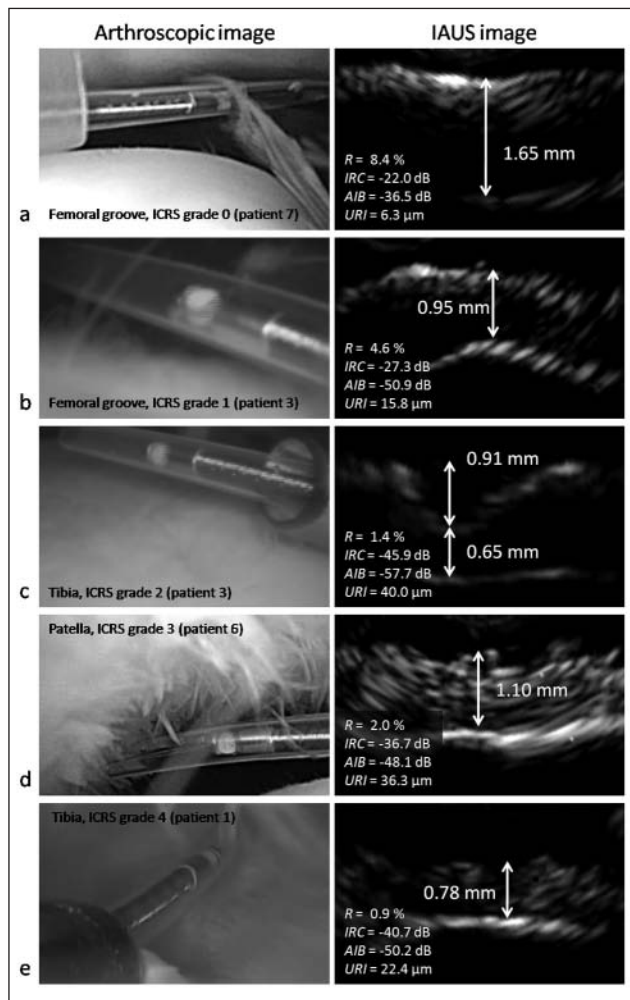


Figure 2. Arthroscopic and ultrasonic images of articular surfaces in the human knee joints. The diameter of the ultrasound catheter (visible in the arthroscopic images) is 1 mm. The International Cartilage Repair Society (ICRS) grade addressed to each measurement site is shown on the arthroscopic images. The dimensions of the intra-articular ultrasound (IAUS) images are 2.5×4 mm. In the IAUS images, the direction of the incident ultrasonic signal is from the physiological saline (above) to the articular cartilage (below). The quantitative ultrasound parameters calculated using the ultrasonic signal are shown on the IAUS images. R = reflection coefficient; IRC = integrated reflection coefficient; AIB = apparent integrated backscatter; URI = ultrasound roughness index.

Figure 2c, a local lesion in the cartilage is clearly visible. The depth of the lesion could be estimated to be 0.91 mm, which is about 58% of the whole cartilage thickness (1.56 mm). Thus, the IAUS method enabled evaluation of the thickness of cartilage and depth of local cartilage lesions relative to the whole cartilage thickness, which is not possible with conventional arthroscopy.

IAUS images in **Figure 2d,e** illustrate severely abnormal cartilage structures, where the cartilage is damaged through its whole depth, and the maximum ultrasonic reflection amplitude is received from the subchondral bone. Thereby, the IAUS method also enabled evaluation of the internal cartilage structure, which is not possible with conventional arthroscopy.

The ICRS grades and the IAUS scores of the 13 evaluated sites were consistent (Spearman's correlation test, $r = 0.939$, $P < 0.01$). The value of the IAUS score differed from the ICRS grade in 4 of 13 sites. In all of these 4 cases, the IAUS score was one rank higher than the ICRS grade, thus implicating that the status of the cartilage in those cases was found to be worse when assessed with the IAUS method than what was estimated during conventional arthroscopy. The correlation between the ICRS grade and the URI was not significant (Spearman's correlation test, $r = 0.436$, $P = 0.157$), suggesting that these methods provide information about different aspects of cartilage quality.

Discussion

In this study, we tested the potential of a novel intra-articular ultrasound method, validated previously *in vitro*,^{18,21} in human arthroscopy measurements *in vivo*. Imaging of human articular cartilage was conducted with ultrasound in arthroscopic conditions for the first time.

Superficial fibrillation of cartilage, visible as an uneven surface structure in the IAUS image (e.g., **Figure 2b**), was not always visually detectable through the arthroscope. This suggests that the IAUS imaging might provide supplementary diagnostic information to the conventional arthroscopic evaluation. This finding is supported by our earlier study reporting that in laboratory conditions, micrometer scale fibrillation can be quantitatively measured with the IAUS technique.¹⁸ The cartilage surfaces that were assigned ICRS grades 0 (normal; **Figure 2a**) and 1 (nearly normal; **Figure 2b**) were distinguishable in the IAUS images. This important finding supports the potential of the IAUS method to detect early osteoarthritic changes of the superficial cartilage. Another important finding of the present study was the ability of the IAUS method to visualize the thickness of cartilage in the cases where the cartilage was thin enough so that the subchondral bone underneath it was visible as well. In the case of the IAUS image in **Figure 2c**, the surgeon assigned the lesion ICRS grade 2 (abnormal [lesions extending down to <50% of cartilage depth]) during the arthroscopy. However, the depth of local lesions can never be accurately evaluated in routine arthroscopy. From the IAUS image in **Figure 2c**, the depth of the lesion could be evaluated to be 0.91 mm,

which is about 58% of the whole thickness of the cartilage (1.56 mm). Thus, ICRS grade 3 (severely abnormal [cartilage defects extending down >50% of cartilage depth]) would have been justified. Because the arthroscopic ultrasound imaging can be used to define the depth of a lesion relative to the cartilage thickness, the method may be of value for the intraoperative decision to treat or not to treat a cartilage lesion. In addition, when comparing the ICRS grade with the IAUS score, it was found that in 4 of 13 cases, the IAUS score was higher than the ICRS grade, and in 9 of 13 cases, it was the same. Thus, the IAUS method seemed to be able to give valuable additional information over the visual or palpation assessment of conventional arthroscopy.

In this preliminary study, the number of the patients was limited. Therefore, statistical methods could not be applied, and the quantitative parameter results are not comparable as such. However, the reflection coefficient R was largest and the roughness index URI was smallest for the intact cartilage surface (**Figure 2a**) compared with the other cartilage surfaces (**Figure 2b-e**). This was expected based on our earlier *in vitro* studies.^{11,31} Furthermore, significant correlation has been found between the stiffness of cartilage and the IRC in earlier studies.^{11,32} In **Figure 2**, a similar trend can be seen; the value of the IRC for degenerated cartilage (**Figure 2b-e**) decreases compared with the IRC of intact cartilage (**Figure 2a**). Thus, the IAUS might even provide information on the mechanical competence of cartilage. However, it should be noted that ultrasound reflection at the surface of the cartilage is controlled by collagen content and fibrillation of the surface rather than by mechanical stiffness of the cartilage directly. Because the collagen content and fibrillation affect the cartilage stiffness, the correlation between the reflection parameters and the tissue stiffness should be considered secondary.

The safety and convenience of the patient were always given priority during the measurements. Therefore, all intended measurement sites of every patient could not always be satisfyingly measured because of lack of time to adjust the inclination of the ultrasound catheter carefully to obtain the maximum reflection amplitude. Consequently, correct positioning of the catheter is probably the most challenging issue when using the IAUS method *in vivo*, and a surgical applicator needs to be developed to minimize the user dependence of the method. In this study, for the first time, we tested the method with human patients, and the method is still under development. Before the operations, the surgeons practiced the ultrasound measurements on a bovine knee joint *ex vivo*. The ultrasound measurements took between 10 and 30 minutes per patient. We believe that in the future, the method can be optimized to be faster and easier to use. An optimal device would also enable assessment of larger articular areas.

In the present study, the ICRS articular cartilage injury classification grade (see **Table 2**) was used as a reference. The ICRS grade is insensitive to the earliest structural changes in cartilage, such as fibrillation of the surface. Some of the patients also had x-ray images of their knee joints taken as part of their diagnosis before the arthroscopy, but because the x-ray images are not sensitive enough to reveal changes in the cartilage integrity in detail, they were not used as a reference. In our earlier *in vitro* IAUS studies,^{18,21} we used histology as a reference method to relate the quantitative ultrasound parameter values to the integrity of the cartilage tissue. In an *in vivo* study, histological methods are not applicable because they involve extraction of tissue. However, we believe that after solving the technical challenges related to the positioning of the ultrasound catheter in the *in vivo* measurements, the ultrasound parameters can be used complementarily with the IAUS images in assessing the integrity of the cartilage and the subchondral bone.

It is notable that the IVUS transducer we used had a higher frequency (40 MHz) compared with that used by Huang and Zheng²³ (20 MHz). Therefore, the spatial resolution of our system was better, which is an advantage when evaluating minor surface fibrillation of cartilage. On the other hand, in the case of relatively thick human cartilage, the lower frequency enables more consistent imaging of the subchondral bone. Visualization of the subchondral bone enables calculation of the cartilage thickness and lesion depth. Structural and biomechanical changes of the subchondral bone, such as formation of osteophytes and cysts or subchondral sclerosis, are also known to occur even in the early stages of OA.³³⁻³⁵ Furthermore, it has been reported that the density, structure, and collagen content of bone can be quantified from ultrasonic information.³⁶⁻³⁸ Therefore, we believe that evaluation of the properties of subchondral bone could be feasible with the IAUS method also and that the IAUS would provide additional information compared with the conventional arthroscopy.

The IAUS method may provide a diagnostic *in vivo* method for evaluation of the severity of articular cartilage lesions and early osteoarthritic changes. Because the present ultrasound equipment is FDA approved for intravascular use, the threshold for applying the method for clinical intra-articular use might be low. The invasiveness of the IAUS method naturally poses some restrictions on its wider clinical use, but it could well be used together with other invasive procedures, such as an arthroscopy of a knee. A definite advantage of the IAUS method compared with conventional arthroscopy is its ability to image the subchondral bone and internal structure of the cartilage as well as the cartilage surface in the cases where the cartilage is thin enough. Furthermore, as opposed to conventional arthroscopy, quantification of cartilage thickness, lesion depth, superficial fibrillation, and the abnormal-

ity of the collagen network within the cartilage is possible with the IAUS imaging. In principle, the IAUS method could also be applied to smaller joints, such as the wrist, shoulder, or ankle. In those joints, the cartilage may be thinner than in the knee joint,³⁹ and thus the subchondral bone could be visualized with high-frequency (40 MHz) ultrasound more consistently than in the knee joint. To further optimize intra-articular IAUS imaging of the thick knee joint cartilage, a lower ultrasound frequency could be used.

Funding

The authors received no financial support for the research and/or authorship of this article.

Declaration of Conflicting Interests

The authors disclosed receipt of the following financial support for the research and/or authorship of this article: supported by outside funding or grant(s) from Academy of Finland (projects 127198 and 132367), Päivikki and Sakari Sohlberg Foundation, and Kuopio University Hospital (EVO grant).

References

1. Brittberg M, Winalski CS. Evaluation of cartilage injuries and repair. *J Bone Joint Surg.* 2003;85A:58-69.
2. Qvist P, Bay-Jensen A-C, Christiansen C, Dam EB, Pastoureau P, Karsdal MA. The disease modifying osteoarthritis drug (DMOAD): is it in the horizon? *Pharmacol Res.* 2008;58:1-7.
3. Hunziker EB. Articular cartilage repair: basic science and clinical progress. A review of the current status and prospects. *Osteoarthritis Cartilage.* 2002;10:432-63.
4. Adler RS, Dedrick DK, Laing TJ, Chiang EH, Meyer CR, Bland PH, *et al.* Quantitative assessment of cartilage surface roughness in osteoarthritis using high frequency ultrasound. *Ultrasound Med Biol.* 1992;18:51-8.
5. Chiang EH, Adler RS, Meyer CR, Rubin JM, Dedrick DK, Laing TJ. Quantitative assessment of surface roughness using backscattered ultrasound: the effects of finite surface curvature. *Ultrasound Med Biol.* 1994;20:123-35.
6. Chérin E, Saïed A, Laugier P, Netter P, Berger G. Evaluation of acoustical parameter sensitivity to age-related and osteoarthritic changes in articular cartilage using 50-MHz ultrasound. *Ultrasound Med Biol.* 1998;24:341-54.
7. Hattori K, Mori K, Habata T, Takakura Y, Ikeuchi K. Measurement of the mechanical condition of articular cartilage with an ultrasonic probe: quantitative evaluation using wavelet transformation. *Clin Biomech.* 2003;18:553-7.
8. Laasanen MS, Saarakkala S, Töyräs J, Rieppo J, Jurvelin JS. Site-specific ultrasound reflection properties and superficial collagen content of bovine knee articular cartilage. *Phys Med Biol.* 2005;50:3221-33.
9. Laasanen MS, Töyräs J, Vasara A, Saarakkala S, Hyttinen MM, Kiviranta I, *et al.* Quantitative ultrasound imaging of spontaneous repair of porcine cartilage. *Osteoarthritis Cartilage.* 2006;14:258-63.
10. Saarakkala S, Korhonen RK, Laasanen M, Töyräs J, Rieppo J, Jurvelin JS. Mechano-acoustic determination of Young's modulus of articular cartilage. *Biorheology.* 2004;41:167-79.
11. Saarakkala S, Laasanen MS, Jurvelin JS, Töyräs J. Quantitative ultrasound imaging detects degenerative changes in articular cartilage surface and subchondral bone. *Phys Med Biol.* 2006;51:5333-46.
12. Conaghan PG, D'Agostino MA, Le Bars M, Baron G, Schmidely N, Wakefield R, *et al.* Clinical and ultrasonographic predictors of joint replacement for knee osteoarthritis: results from a large, 3-year, prospective EULAR study. *Ann Rheum Dis.* 2010;69:644-7.
13. Kumm J, Tamm A, Lintrop M, Tamm A. Association between ultrasonographic findings and bone/cartilage biomarkers in patients with early-stage knee osteoarthritis. *Calcif Tissue Int.* 2009;85:514-22.
14. Monteforte P, Sessarego P, Rovetta G. Sonographic assessment of soft tissue alterations in osteoarthritis of the knee. *G Ital Med Lav Ergon.* 2008;30:75-7.
15. Möller I, Bong D, Naredo E, Filippucci E, Carrasco I, Moragues C, *et al.* Ultrasound in the study and monitoring of osteoarthritis. *Osteoarthritis Cartilage.* 2008;16:S4-7.
16. Lee C-L, Huang M-H, Chai C-Y, Chen C-H, Su J-Y, Tien Y-C. The validity of in vivo ultrasonographic grading of osteoarthritic femoral condylar cartilage: a comparison with in vitro ultrasonographic and histologic gradings. *Osteoarthritis Cartilage.* 2008;16:352-8.
17. Kuroki H, Nakagawa Y, Mori K, Kobayashi M, Yasura K, Okamoto Y, *et al.* Ultrasound properties of articular cartilage in the tibio-femoral joint in knee osteoarthritis: relation to clinical assessment (International Cartilage Repair Society grade). *Arthritis Res Ther.* 2008;10:R78.
18. Virén T, Saarakkala S, Kaleva E, Nieminen HJ, Jurvelin JS, Töyräs J. Minimally invasive ultrasound method for intra-articular diagnostics of cartilage degeneration. *Ultrasound Med Biol.* 2009;35:1546-54.
19. Kastelein JJP, de Groot E. Ultrasound imaging techniques for the evaluation of cardiovascular therapies. *Eur Heart J.* 2008;29:849-58.
20. König A, Margolis MP, Virmani R, Holmes D, Klauss V. Technology insight: in vivo coronary plaque classification by intravascular ultrasonography radiofrequency analysis. *Nature.* 2008;5:219-29.
21. Virén T, Saarakkala S, Jurvelin JS, Pulkkinen HJ, Tiitu V, Valonen P, *et al.* Quantitative evaluation of spontaneously and surgically repaired rabbit articular cartilage using intra-articular ultrasound method in situ. *Ultrasound Med Biol.* 2010;36:833-9.
22. Virén T, Saarakkala S, Pulkkinen H, Tiitu V, Kiviranta I, Lammi MJ, *et al.* Quantitative evaluation of spontaneously

- repaired equine cartilage with minimally invasive ultrasound technique. *Trans Orthop Res Soc.* 2010;35:1015.
23. Huang Y-P, Zheng YP. Intravascular ultrasound (IVUS): a potential arthroscopic tool for quantitative assessment of articular cartilage. *Open Biomed Eng J.* 2009;3:13-20.
 24. Hattori K, Takakura Y, Ishimura M, Habata T, Uematsu K, Ikeuchi K. Quantitative arthroscopic ultrasound evaluation of living human cartilage. *Clin Biomech.* 2004;19:213-6.
 25. Hattori K, Takakura Y, Ishimura M, Tanaka Y, Habata T, Ikeuchi K. Differential acoustic properties of early cartilage lesions in living human knee and ankle joints. *Arthritis Rheum.* 2005;52:3125-31.
 26. Nishitani K, Nakagawa Y, Gotoh T, Kobayashi M, Nakamura T. Intraoperative acoustic evaluation of living human cartilage of the elbow and knee during mosaicplasty for osteochondritis dissecans of the elbow. *Am J Sports Med.* 2008;36:2345-53.
 27. Shigematsu K, Hattori K, Kobata Y, Kawamura K, Yajima H, Takakura Y. A pilot feasibility study for ultrasound evaluation of living human wrist cartilage: site-specific differences in acoustic properties. *J Hand Surg.* 2009;34A:34-9.
 28. Ateshian GA, Soslowky LJ, Mow VC. Quantitation of articular surface topography and cartilage thickness in knee joints using stereophotogrammetry. *J Biomech.* 1991;24:761-76.
 29. Faber SC, Eckstein F, Lukasz S, Mühlbauer R, Hohe J, Englmeier K-H, *et al.* Gender differences in knee joint cartilage thickness, volume and articular surface areas: assessment with quantitative three-dimensional MR imaging. *Skeletal Radiol.* 2001;30:144-50.
 30. Hall FM, Wyshak G. Thickness of articular cartilage in the normal knee. *J Bone Joint Surg Am.* 1980;62:408-13.
 31. Kaleva E, Saarakkala S, Töyräs J, Nieminen HJ, Jurvelin JS. In-vitro comparison of time-domain, frequency domain and wavelet ultrasound parameters in diagnostics of cartilage degeneration. *Ultrasound Med Biol.* 2008;34:155-9.
 32. Gelse K, Olk A, Eichhorn S, Swoboda B, Schoene M, Raum K. Quantitative ultrasound biomicroscopy for the analysis of healthy and repair cartilage tissues. *Eur Cell Mater.* 2010;19: 58-71.
 33. Anderson-MacKenzie JM, Quasnicka HL, Starr RL, Lewis EJ, Billingham EJ, Bailey AJ. Fundamental subchondral bone changes in spontaneous knee osteoarthritis. *Int J Biochem Cell Biol.* 2005;37:224-36.
 34. Buckwalter JA, Martin J. Degenerative joint disease. *Clin Symp.* 1995;47:1-32.
 35. Radin EL, Paul IL, Tolkoff MJ. Subchondral bone changes in patients with early degenerative joint disease. *Arthritis Rheum.* 1970;13:400-5.
 36. Chaffai S, Peyrin F, Nuzzo S, Porcher R, Berger G, Laugier P. Ultrasonic characterization of human cancellous bone using transmission and backscatter measurements: relationships to density and microstructure. *Bone.* 2002;30:229-37.
 37. Hakulinen MA, Day JS, Töyräs J, Timonen M, Kröger H, Weinans H, *et al.* Prediction of density and mechanical properties of human trabecular bone in vitro by using ultrasound transmission and backscattering measurements at 0.2-6.7 MHz frequency range. *Phys Med Biol.* 2005;50:1629-42.
 38. Hoffmeister BK, Johnston DP, Janeski JA, Keedy DA, Steinert BW, Viano AM, *et al.* Ultrasonic characterization of human cancellous bone in vitro using three different apparent backscatter parameters in the frequency range 0.6-15.0 MHz. *IEEE Trans Ultrason Ferroelectr Freq Control.* 2008;55:1442-52.
 39. Stockwell RA. The interrelationship of cell density and cartilage thickness in mammalian articular cartilage. *J Anat.* 1971;109:411-21.