

Association of Cardiac Infection With SARS-CoV-2 in Confirmed COVID-19 Autopsy Cases

Diana Lindner, PhD; Antonia Fitzek, MD; Hanna Bräuninger, MS; Ganna Aleshcheva, PhD; Caroline Edler, MD; Kira Meissner; Katharina Scherschel, PhD; Paulus Kirchhof, MD; Felicitas Escher, MD; Heinz-Peter Schultheiss, MD; Stefan Blankenberg, MD; Klaus Püschel, MD; Dirk Westermann, MD

IMPORTANCE Severe acute respiratory syndrome coronavirus 2 (SARS-CoV-2) can be documented in various tissues, but the frequency of cardiac involvement as well as possible consequences are unknown.

OBJECTIVE To evaluate the presence of SARS-CoV-2 in the myocardial tissue from autopsy cases and to document a possible cardiac response to that infection.

DESIGN, SETTING, AND PARTICIPANTS This cohort study used data from consecutive autopsy cases from Germany between April 8 and April 18, 2020. All patients had tested positive for SARS-CoV-2 in pharyngeal swab tests.

EXPOSURES Patients who died of coronavirus disease 2019.

MAIN OUTCOMES AND MEASURES Incidence of SARS-CoV-2 positivity in cardiac tissue as well as CD3⁺, CD45⁺, and CD68⁺ cells in the myocardium and gene expression of tumor necrosis growth factor α , interferon γ , chemokine ligand 5, as well as interleukin-6, -8, and -18.

RESULTS Cardiac tissue from 39 consecutive autopsy cases were included. The median (interquartile range) age of patients was 85 (78-89) years, and 23 (59.0%) were women. SARS-CoV-2 could be documented in 24 of 39 patients (61.5%). Viral load above 1000 copies per μg RNA could be documented in 16 of 39 patients (41.0%). A cytokine response panel consisting of 6 proinflammatory genes was increased in those 16 patients compared with 15 patients without any SARS-CoV-2 in the heart. Comparison of 15 patients without cardiac infection with 16 patients with more than 1000 copies revealed no inflammatory cell infiltrates or differences in leukocyte numbers per high power field.

CONCLUSIONS AND RELEVANCE In this analysis of autopsy cases, viral presence within the myocardium could be documented. While a response to this infection could be reported in cases with higher virus load vs no virus infection, this was not associated with an influx of inflammatory cells. Future investigations should focus on evaluating the long-term consequences of this cardiac involvement.

JAMA Cardiol. 2020;5(11):1281-1285. doi:10.1001/jamacardio.2020.3551
Published online July 27, 2020.

← Editorial page 1216

+ Supplemental content

Author Affiliations: Department of Cardiology, University Heart and Vascular Centre, Hamburg, Germany (Lindner, Bräuninger, Scherschel, Kirchhof, Blankenberg, Westermann); DZHK (German Center for Cardiovascular Research), Partner site, Hamburg/Kiel/Lübeck, Germany (Lindner, Bräuninger, Scherschel, Kirchhof, Blankenberg, Westermann); Department of Legal Medicine, University Medical Center Hamburg-Eppendorf, Hamburg, Germany (Fitzek, Edler, Meissner, Püschel); Institute for Cardiac Diagnostics and Therapy, Berlin, Germany (Aleshcheva, Escher, Schultheiss); Department of Cardiology, Charité Campus Virchow-Klinikum, University Medicine Berlin, Berlin, Germany (Escher); DZHK (German Center for Cardiovascular Research), Berlin, Germany (Escher).

Corresponding Author: Dirk Westermann, MD, University Heart and Vascular Centre Hamburg, Department of Cardiology, Martinistr. 52, 20246 Hamburg, Germany (d.westermann@uke.de).

In patients with coronavirus disease 2019 (COVID-19), cardiovascular involvement occurs frequently. Myocardial injury with elevated troponin levels is described in patients hospitalized with COVID-19¹ and seems to be associated with outcome.² The origin of myocardial injury can result from ischemia due to thrombotic coronary obstruction but can also include other causes such as heart failure, pulmonary embolism, tachycardia, and sepsis.³ Obviously, an infection of the myocardium with severe acute respiratory syndrome coronavirus 2 (SARS-CoV-2) is another alternative for elevated troponin. Next to elevated biomarkers for cardiac injury, myocardial dysfunction determined by echocardiography is also reported in up to 70% of hospitalized patients.⁴ This makes cardiac involvement during

COVID-19, which manifests primarily as a pulmonary disease, likely.

Myocarditislike clinical presentations have been described in only a few patients with COVID-19 to date,⁵ suggesting that fulminant myocarditis is rare.⁶ In the very few cases with clinically suspected myocarditis, SARS-CoV-2 infection was associated with cardiac inflammation.⁷

Whether SARS-CoV-2 can be documented and replicates within the heart and whether this is associated with mononuclear cell infiltration or induces cytokine expression remains elusive in deceased patients without clinically overt myocarditis. Therefore, we investigated whether myocardial infection occurred in autopsy cases of patients with COVID-19.

Methods

Study Cohort and Tissue Sampling

Consecutively, deceased individuals with diagnosed SARS-CoV-2 infection were autopsied at the Institute of Legal Medicine at the University Medical Center Hamburg-Eppendorf in Germany between April 8 and April 18, 2020. The diagnosis was confirmed post mortem by quantitative reverse transcriptase-polymerase chain reaction to detect SARS-CoV-2 RNA and performed from pharyngeal swabs.⁸ This study was approved by the local ethics committee of the Hamburg Chamber of Physicians. The cases were included in the autopsy study of the first consecutive 80 individuals who had died of SARS-CoV-2 infection in Hamburg, Germany, which reported cause of death and comorbidities.⁹ A detailed description of myocardial tissue is the subject of this article. Cardiac tissue was collected during autopsy with median postmortem intervals of 3.0 (interquartile range, 2.0-4.3) days. Two tissue specimens were taken from the left ventricle and either snap frozen in liquid nitrogen or fixed in formalin for subsequent analysis.

Gene Expression Analysis and Histological Analysis

Isolation of total RNA has been described earlier.¹⁰ Reverse transcription of 1 µg of RNA was carried out using the high-capacity complementary DNA kit in the presence of random reverse transcription primers to determine virus load and gene expression. Gene expression of cytokines was determined as described in the eMethods and eTable 1 in the Supplement and plotted as a heat map. Quantitative real-time polymerase chain reaction for SARS-

Key Points

Question Can severe acute respiratory syndrome coronavirus 2 (SARS-CoV-2) be documented in cardiac tissue of coronavirus disease 2019 (COVID-19) autopsy cases?

Findings In this cohort study of 39 autopsy cases of patients with COVID-19, cardiac infection with SARS-CoV-2 was found to be frequent but not associated with myocarditislike influx of inflammatory cells into the myocardium.

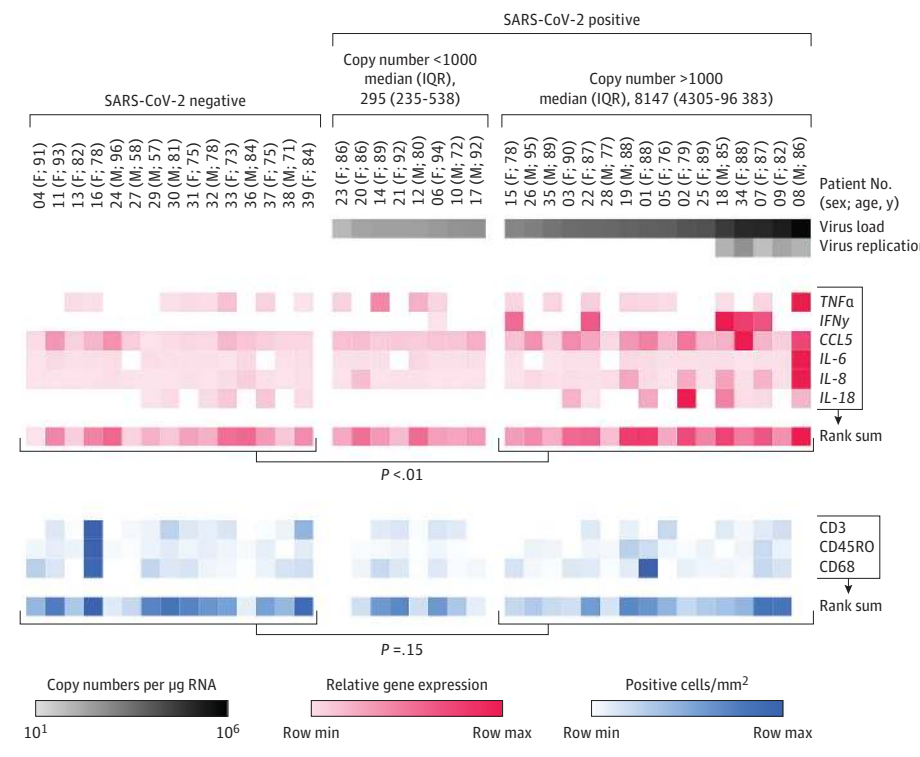
Meaning Among individuals with cardiac infection, overt myocarditis was not observed in the acute phase, but the long-term consequences of this cardiac infection needs to be studied.

CoV-2 was performed with primers and probe for the viral gene E (Tib Molbiol).¹¹ To investigate virus replication, complementary DNA synthesis was performed in the presence of 1 µM gene-specific forward primer (E_Sarbeco_F)¹¹ or in the absence of primer to exclude nonspecific complementary DNA synthesis. Paraffin sections were stained with antibodies against CD3, CD45RO, and CD68 and quantified as positive cells/mm² as described in the eMethods and eTable 2 in the Supplement.

In Situ Hybridization

In situ hybridization was carried out to detect viral RNA of SARS-CoV-2 on paraffin sections using RNAscope 2.5 high-definition detection kit (Advanced Cell Diagnostics). In brief, tissue sections were deparaffinized in xylene and followed by target retrieval

Figure 1. Virus Infection and Inflammatory Response in Cardiac Tissue From Coronavirus Disease 2019 Deaths



Severe acute respiratory syndrome coronavirus 2 (SARS-CoV-2) RNA was detected by reverse transcriptase-polymerase chain reaction in 24 of 39 patients (61.5%). Patients were grouped according to SARS-CoV-2 copy numbers. Virus replication was determined in the 5 patients with the highest virus load. Gene expression data of a cytokine response panel revealed increased proinflammatory response in cardiac tissue with copy numbers more than 1000 compared with noninfected cardiac tissue, whereas immunohistochemistry staining revealed no difference in leukocyte infiltrates. F indicates female; IL, interleukin; IQR, interquartile range; interferon γ, IFNγ; M, male; max, maximum; min, minimum; tumor necrosis growth factor α, TNFα.

at 95 °C for 10 minutes. Subsequently, internal peroxidase activity was quenched by hydrogen peroxide incubation for 10 minutes followed by permeabilization using protease plus treatment at 40 °C for 30 minutes. The SARS-CoV-2-specific probe V-nCoV2019-S was hybridized at 40 °C for 2 hours. RNAScope signal was developed with 3,3'-diaminobenzidine and nuclei were counterstained using hematoxylin. Negative controls are shown in the eFigure in the Supplement.

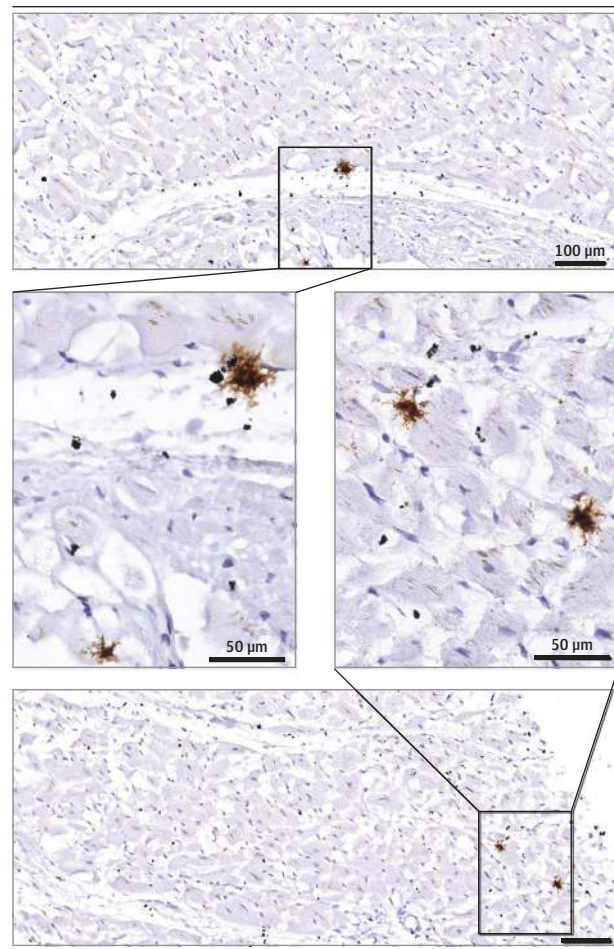
Results

The median (interquartile range) age of the 39 individuals was 85 (78- 89) years and 23 (59.0%) were women. Pneumonia was evaluated as cause of death in 35 individuals (89.7%); in 4 individuals (10.2%), another cause of death was identified (patient 6, necrotizing fasciitis; patient 11, cardiac decompensation with prior heart failure; patient 21, bacterial bronchitis; patient 27, unknown).⁹ None of the patients in the study were diagnosed as having clinically fulminant myocarditis. Comorbidities such as hypertension, coronary artery disease, and diabetes were frequent and diagnosed in 17 (43.6%), 32 (82.0%), and 7 patients (17.9%), respectively. In **Figure 1**, patients were sorted according to their virus load within the myocardium. Fifteen of 39 autopsies (38.5%) had no SARS-CoV-2 RNA in the myocardium. In 8 of 24 patients (33.3%) with viral presence, the virus load was lower than 1000 copies per μg RNA. In the remaining 16 patients, virus load was above 1000 copies. Virus replication of SARS-CoV-2 defined by detection of the (-) strand replicate of the RNA genome was documented in the myocardium of the 5 patients with the highest virus load. The median (interquartile range) copy number of those 5 patients was 135 584 (84 949-474 675) per μg RNA. In situ hybridization of SARS-CoV-2 RNA confirmed the virus presence in interstitial cells within the cardiac tissue (**Figure 2**). Gene expression of a response panel of 6 genes was measured in the myocardium. Comparing the rank sums of this panel, lower expression was present in those patients without compared with the group with virus load higher than 1000 copies (**Figure 1**, shown in red). The number of CD3⁺, CD45⁺, and CD68⁺ cells/mm² were quantified (**Figure 1**, shown in blue). Importantly, virus presence was not associated with increased infiltration of mononuclear cells into the myocardium (**Figure 3**) compared with the virus negative group. According to the Dallas criteria, no myocarditis was present because no massive cell infiltrates or necrosis could be documented.

Discussion

Viral genome was present in the myocardial tissue in this autopsy study. This is in line with findings that the SARS-CoV-2 receptors are expressed within myocardial cells¹² as well as findings from SARS-CoV, where myocardial infection was documented as well.¹³ Our findings from in situ hybridization revealed the most likely localization of SARS-CoV-2 not to be in the cardiomyocytes but in interstitial cells or macrophages

Figure 2. In-situ Hybridization to Detect Virus RNA in SARS-CoV-2-Infected Cardiac Tissue



Paraffin-embedded cardiac tissue section of a patient with severe acute respiratory syndrome coronavirus 2 (SARS-CoV-2) infection revealed interstitial cells carrying virus RNA detected.

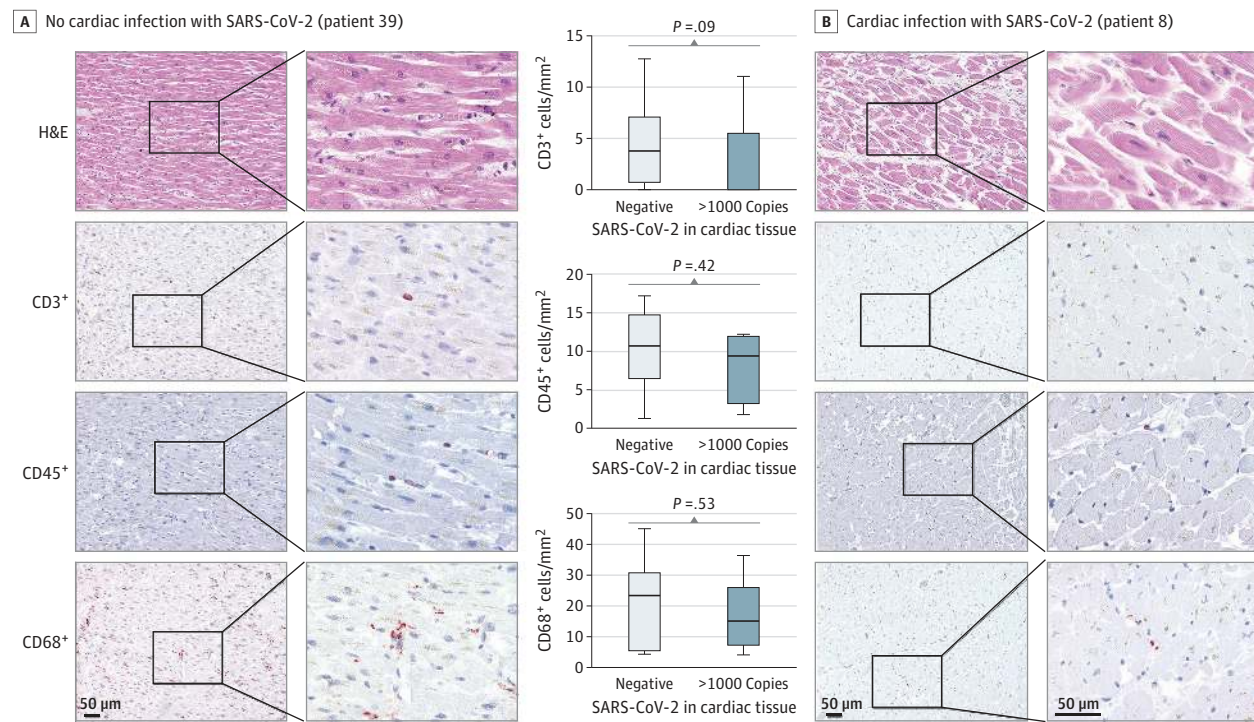
invading the myocardial tissue. Nevertheless, this has to be studied in more detail in upcoming studies.

In this study, 5 of 16 patients with virus load above 1000 copies, which we deem to be clinically significant, showed signs of viral replication within the myocardial tissue. This indicates not only virus presence but viral progeny. Whether it is associated with viral shedding is unknown.

A response with increased expression of cytokines modulating the inflammatory process was documented in patients with a virus load above 1000 copies. This is in line with findings that the cytokine-induced organ dysfunction contributes to the disease process.⁶

Importantly, fulminant myocarditis was not associated with SARS-CoV-2 infection in this study with no significant change in transendothelial migration of inflammatory cells in the myocardium in patients with high virus load vs no virus. In the published cases in which myocardial inflammation was present, there was also evidence of clinical myocarditis, and therefore the current cases underlie a different pathophysiology. Our findings emphasize no increased inflammatory cells

Figure 3. Histological Analyses of Cardiac Tissue



Paraffin-embedded cardiac tissue sections either virus-negative (light blue) or with more than 1000 copies of severe acute respiratory syndrome coronavirus 2 (SARS-CoV-2) (dark blue) were analyzed and depicted as Tukey-style box plots with median and interquartile range. The comparison of the 15 patients without cardiac infection to the 16 patients with more than 1000 copies revealed no

infiltrates or differences in leukocyte numbers per high power field. Representative images for patient 39 with no cardiac infection and patient 8 revealing the highest copy number in the cardiac tissue are displayed. H&E indicates hematoxylin-eosin.

in consecutive COVID-19 cases without clinical myocarditis. Whether myocardial viral activity in the absence of clinical evidence of myocarditis might result in long-term consequences is unknown. Leukocytopenia is another feature of COVID-19, which might hamper myocardial invasion of mononuclear cells.¹⁴

Limitations

This study has limitations, including the design as an autopsy study. Elderly age of the patients might have influenced the results. Presumably, in nonautopsy studies, the incidence of virus infection will be different. Unfortunately, endomyocardial biopsies of patients with COVID-19 are not available in significant numbers at the moment and will likely not be available in higher numbers to address this in the near future owing to the emerging health care crisis due to COVID-

19. As an autopsy study, we have only limited clinical information. Therefore, future studies are needed to reveal whether cytokine expression correlates with cardiac dysfunction during the disease and its aftermath. Moreover, no information is present about myocardial biomarkers, which might be up-regulated due to the SARS-CoV-2 infection.

Conclusions

Overt fulminant myocarditis has been reported in isolated patients with SARS-CoV-2 infection. However, the current data indicate that the presence of SARS-CoV-2 in cardiac tissue does not necessarily cause an inflammatory reaction consistent with clinical myocarditis. The long-term consequences of this cardiac infection requires further investigation.

ARTICLE INFORMATION

Accepted for Publication: June 29, 2020.

Published Online: July 27, 2020.

doi:10.1001/jamacardio.2020.3551

Author Contributions: Drs Westermann and Lindner had full access to all of the data in the study and take responsibility for the integrity of the data and the accuracy of the data analysis. *Concept and design:* Lindner, Scherschel, Westermann.

Acquisition, analysis, or interpretation of data:

Lindner, Fitzek, Bräuninger, Aleshcheva, Edler, Meißner, Kirchhof, Escher, Schultheiss, Blankenberg, Püschel, Westermann.

Drafting of the manuscript: Lindner, Westermann.

Critical revision of the manuscript for important intellectual content: Fitzek, Bräuninger, Aleshcheva, Edler, Meißner, Scherschel, Kirchhof, Escher, Schultheiss, Blankenberg, Püschel, Westermann.

Statistical analysis: Lindner, Westermann.

Obtained funding: Lindner, Aleshcheva, Westermann.

Administrative, technical, or material support: Lindner, Bräuninger, Aleshcheva, Edler, Meißner, Scherschel, Escher, Püschel, Westermann.

Supervision: Escher, Schultheiss, Blankenberg, Westermann.

Conflict of Interest Disclosures: Dr Kirchhof reports grants and nonfinancial support for basic, translational, and clinical research projects from European Union, British Heart Foundation, Leducq

Foundation, Medical Research Council (UK), and German Centre for Cardiovascular Research; and is an inventor on 2 patents held by University of Birmingham (Atrial Fibrillation Therapy WO 2015140571, Markers for Atrial Fibrillation WO 2016012783) outside the submitted work. Dr Escher reported personal fees from IKDT Berlin outside the submitted work. Dr Blankenberg reports grants and personal fees from Abbott Diagnostics, Bayer, Siemens, and Thermo Fisher; grants from Singulex; and personal fees from AstraZeneca, Amgen, Medtronic, Pfizer, Roche, Novartis, Abbott, and Siemens DX outside the submitted work. Dr Westermann reported personal fees from AstraZeneca, Bayer, Novartis, and Medtronic outside the submitted work. No other disclosures were reported.

Funding/Support: This study was supported by the grant to Drs Westermann and Lindner from the Deutsche Herzstiftung and by the German Center of Cardiovascular Research (DZHK).

Role of the Funder/Sponsor: The funders had no role in the design and conduct of the study; collection, management, analysis, and interpretation of the data; preparation, review, or approval of the manuscript; and decision to submit the manuscript for publication.

REFERENCES

- Guo T, Fan Y, Chen M, et al. Cardiovascular implications of fatal outcomes of patients with coronavirus disease 2019 (COVID-19). *JAMA Cardiol*. Published online March 27, 2020. doi:10.1001/jamacardio.2020.1017
- Lala A, Johnson KW, Januzzi JL, et al; Mount Sinai Covid Informatics Center. Prevalence and impact of myocardial injury in patients hospitalized with COVID-19 infection. *J Am Coll Cardiol*. Published online June 8, 2020.
- Hartikainen TS, Sörensen NA, Haller PM, et al. Clinical application of the 4th Universal Definition of Myocardial Infarction. *Eur Heart J*. 2020;41(23):2209-2216. doi:10.1093/eurheartj/ehaa035
- Szekely Y, Lichter Y, Taieb P, et al. The spectrum of cardiac manifestations in coronavirus disease 2019 (covid-19): a systematic echocardiographic study. *Circulation*. Published online May 29, 2020. doi:10.1161/CIRCULATIONAHA.120.047971
- Inciardi RM, Lupi L, Zacccone G, et al. Cardiac involvement in a patient with coronavirus disease 2019 (COVID-19). *JAMA Cardiol*. Published online March 27, 2020. doi:10.1001/jamacardio.2020.1096
- Guzik TJ, Mohiddin SA, Dimarco A, et al. COVID-19 and the cardiovascular system: implications for risk assessment, diagnosis, and treatment options. *Cardiovasc Res*. Published online April 30, 2020. doi:10.1093/cvr/cvaa106
- Escher F, Pietsch H, Aleshcheva G, et al. Detection of viral SARS-CoV-2 genomes and histopathological changes in endomyocardial biopsies. *ESC Heart Fail*. Published online June 12, 2020. doi:10.1002/ehf2.12805
- Pfefferle S, Reucher S, Nörz D, Lütgehetmann M. Evaluation of a quantitative RT-PCR assay for the detection of the emerging coronavirus SARS-CoV-2 using a high throughput system. *Euro Surveill*. 2020;25(9). doi:10.2807/1560-7917.ES.2020.25.9.2000152
- Edler C, Schröder AS, Aepfelbacher M, et al. Dying with SARS-CoV-2 infection—an autopsy study of the first consecutive 80 cases in Hamburg, Germany. *Int J Legal Med*. 2020;134(4):1275-1284. doi:10.1007/s00414-020-02317-w
- Hinrichs S, Scherschel K, Krüger S, et al. Precursor proadrenomedullin influences cardiomyocyte survival and local inflammation related to myocardial infarction. *Proc Natl Acad Sci U S A*. 2018;115(37):E8727-E8736. doi:10.1073/pnas.1721635115
- Corman VM, Landt O, Kaiser M, et al. Detection of 2019 novel coronavirus (2019-nCoV) by real-time RT-PCR. *Euro Surveill*. 2020;25(3). doi:10.2807/1560-7917.ES.2020.25.3.2000045
- Nicin L, Abplanalp WT, Mellentin H, et al. Cell type-specific expression of the putative SARS-CoV-2 receptor ACE2 in human hearts. *Eur Heart J*. 2020;41(19):1804-1806. doi:10.1093/eurheartj/ehaa311
- Oudit GY, Kassiri Z, Jiang C, et al. SARS-coronavirus modulation of myocardial ACE2 expression and inflammation in patients with SARS. *Eur J Clin Invest*. 2009;39(7):618-625. doi:10.1111/j.1365-2362.2009.02153.x
- Zhang X, Tan Y, Ling Y, et al. Viral and host factors related to the clinical outcome of COVID-19. *Nature*. 2020. doi:10.1038/s41586-020-2355-0