

Associations of radiological features in *Mycoplasma pneumoniae* pneumonia

Qi Guo¹, Hai-Yan Li², Yi-Ping Zhou¹, Ming Li¹, Xiao-Ke Chen¹, Hong-Lin Peng¹, Hai-Qiong Yu¹, Li-Hua Liang³, Qing-Zhou Zhao³, Mei Jiang⁴

¹Department of Respiratory Medicine, Affiliated Futian Hospital, Guangdong Medical College, Shenzhen, Guangdong, China

²Department of Primary Care, Affiliated Futian Hospital, Guangdong Medical College, Shenzhen, Guangdong, China

³Department of Radiology, Affiliated Futian Hospital, Guangdong Medical College, Shenzhen, Guangdong, China

⁴Guangzhou Institute of Respiratory Diseases (State Key Laboratory of Respiratory Diseases), First Affiliated Hospital, Guangzhou Medical University, Guangzhou, Guangdong, China

Submitted: 23 June 2012

Accepted: 3 December 2012

Arch Med Sci 2014; 10, 4: 725–732

DOI: 10.5114/aoms.2014.44863

Copyright © 2014 Termedia & Banach

Corresponding author:

Qi Guo MD, PhD
Department
of Respiratory Medicine
Affiliated Futian Hospital,
Guangdong Medical College
Shennan middle Road
No. 3025
Shenzhen, Guangdong,
China, 518033
Phone: +86 13923714808
Fax: +86 755 83986387
E-mail: qiguoo007@sina.com

Abstract

Introduction: The associations of radiological features with clinical and laboratory findings in *Mycoplasma pneumoniae* infection are poorly understood. The purpose of this study was to assess the associations.

Material and methods: A retrospective cohort study of 1230 patients with community-acquired pneumonia was carried out between January 2005 and December 2009. The diagnosis of *M. pneumoniae* infection was made using the indirect microparticle agglutinin assay and enzyme-linked immunosorbent assay.

Results: Females were more susceptible to *M. pneumoniae* infection. Ground-glass opacification on radiographs was positively associated with *M. pneumoniae*-IgM titres (rank correlation coefficient (r_s) = 0.141, p = 0.006). The left upper lobe was more susceptible to infection with *M. pneumoniae* compared with other pathogens. More increases in the risk of multilobar opacities were found among older or male patients with *M. pneumoniae* pneumonia (odds ratio, 1.065, 3.279; 95% confidence interval, 1.041–1.089, 1.812–5.934; p < 0.001, p < 0.001; respectively). Patients with *M. pneumoniae* pneumonia showing multilobar opacities or consolidation had a significantly longer hospital length of stay (r_s = 0.111, r_s = 0.275; p = 0.033, p < 0.001; respectively), incurring significantly higher costs (r_s = 0.119, r_s = 0.200; p = 0.022, p < 0.001; respectively).

Conclusions: Our study highlighted female susceptibility to *M. pneumoniae* pneumonia and the association of ground-glass opacification with higher *M. pneumoniae*-IgM titres. The left upper lobe might be more susceptible to *M. pneumoniae* infection. Older or male patients with *M. pneumoniae* pneumonia were more likely to show multilobar opacities. Multilobar opacities and consolidation were positively associated with hospital length of stay and costs.

Key words: community-acquired pneumonia, *Mycoplasma pneumoniae*, radiological features, association.

Introduction

Community-acquired pneumonia (CAP) is a common infection. Despite substantial progress in therapeutic options, the mortality remains

unacceptably high [1], as high as 58% in patients with severe CAP admitted to the intensive care unit [2]. *Mycoplasma pneumoniae* is an important causative organism of CAP, accounting for 10–30% of all cases [3–5]. The frequency of CAP due to *M. pneumoniae* was 20.7% in China from December 2003 to November 2004 [6]. Patients infected with *M. pneumoniae* constitute about 29% of ambulatory adult patients with CAP and about 20% of hospitalized low-risk CAP patients in China [7, 8]. Three–four percent of patients infected with *M. pneumoniae* are known to develop a severe life-threatening pneumonia with respiratory failure and acute respiratory distress syndrome [9].

Although characteristic computed tomographic (CT) features of *M. pneumoniae* pneumonia have been described [10], radiological findings are not particularly specific. The disease is most frequently characterized by bronchopneumonic or interstitial infiltrates usually in the lower lobe, unilateral and centrally dense [11].

Manifestations of infectious diseases may be influenced by both the pathogen and the host. In the case of *M. pneumoniae* pneumonia, mechanistic correlates of disease severity are poorly characterised. Generally, evidence from research on humans and animal models suggests that the immune system may on the one hand limit disease through the enhancement of host defence mechanisms but on the other hand exacerbate organ damage and systemic disease manifestations. Thus, the more vigorous the cell-mediated immune response and cytokine stimulation, the more severe the clinical illness and pulmonary injury [4]. Consequently, it might be expected that radiological signs of pulmonary lesions in *M. pneumoniae* pneumonia might vary according to the demographics of the patients and clinical and laboratory findings. To our knowledge, however, these associations have so far been only partly addressed by a few studies [10, 12–15].

In the present study, adult patients with CAP were selected to investigate the associations of radiological features with clinical and laboratory findings in a Chinese affiliated hospital.

Material and methods

Design and setting

A retrospective cohort study was performed of 1230 adult patients who met the criteria for CAP presenting to the Department of Respiratory Medicine in a Chinese affiliated hospital of a medical college from 1st January 2005 to 31st December 2009, thus including five autumn-winter seasons.

Criteria for enrolment

The CAP was defined as an acute infection of the pulmonary parenchyma associated with an

acute infiltrate on the chest radiograph with two or more symptoms including fever (> 38°C), hypothermia (< 36°C), rigors, sweats, new cough or change in colour of respiratory secretions, chest discomfort or dyspnoea [16].

Acute *M. pneumoniae* infection was defined as a fourfold or greater increase in specific IgM and/or IgG titres between acute and convalescent phase serum samples. The CAP due only to acute *M. pneumoniae* infection was defined as *M. pneumoniae* pneumonia. However, CAP caused by other pathogens and not having a fourfold or greater increase in specific IgM and/or IgG titres was defined as other pneumonias. Mixed pneumonia (atypical + bacteria) was discarded. Patients < 18 years of age, any who had been hospitalized during the 28 days preceding the study, and any who had severe immunosuppression (e.g., patients with neutropenia after chemotherapy or bone marrow transplantation, patients with drug-induced immunosuppression as a result of solid-organ transplantation or corticosteroid or cytotoxic therapy, and patients with HIV-related disorders) [17], active tuberculosis, or end-stage diseases, or who had a written “do not resuscitate” order were excluded. We also excluded patients with pulmonary emphysema, idiopathic interstitial pneumonia and malignant diseases. In such patients it is difficult to distinguish bronchopneumonia from lobar pneumonia and unifocal from multifocal disease. There were no patients with concurrent infectious disease.

We used recent definitions of radiological abnormalities as follows [18]:

Ground-glass opacity: On chest radiographs, it appears as an area of hazy increased lung opacity, usually extensive, within which margins of pulmonary vessels may be indistinct. On CT scans, it appears as hazy increased opacity of lung, with preservation of bronchial and vascular margins.

Consolidation: It appears as a homogeneous increase in pulmonary parenchymal attenuation that obscures the margins of vessels and airway walls. An air bronchogram may be present.

Grouping

One thousand two hundred and forty-five patients were selected and then 15 cases were excluded from this investigation due to exclusion criteria. A total of 1230 patients were accepted for the study. Three hundred and seventy-two patients with *M. pneumoniae*-associated pneumonia were included in one group and compared with 858 patients caused by infection due to other pathogens. Patients with ground-glass opacity were further designated as the bronchopneumonia subgroup and those with consolidation as the lobar pneumonia subgroup. Patients were also further subgrouped according to lobar involvement as follows:

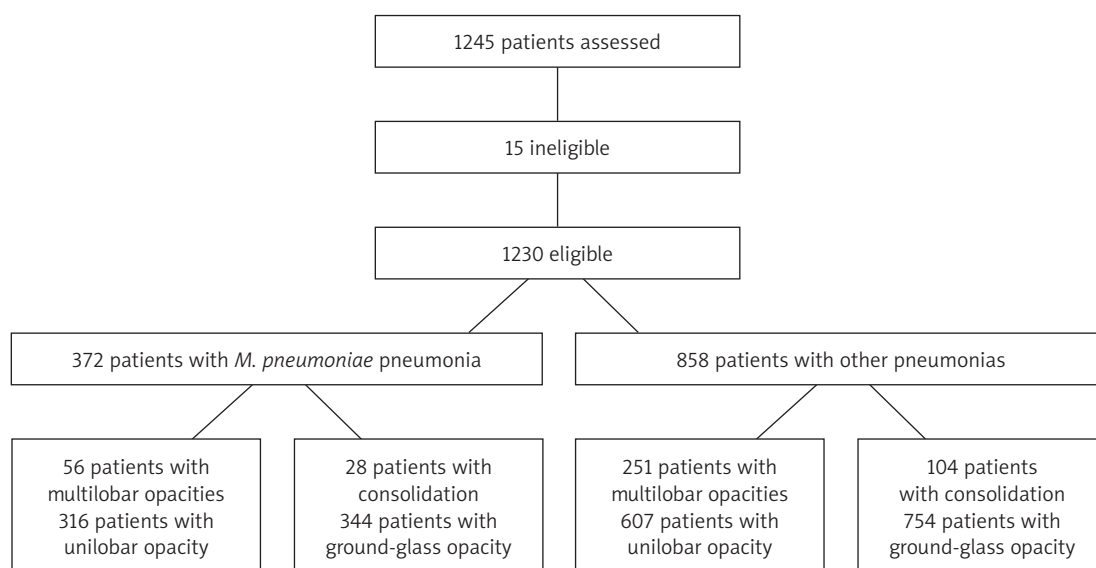


Figure 1. Study Flow Chart

the unilobar opacity subgroup and the multilobar opacities subgroup (Figure 1).

Data collection

Clinical and diagnostic data and radiological features were collected from medical records following discharge. For the detection of *M. pneumoniae* specific IgM antibodies, the indirect microparticle agglutinin assay (Serodia-Myco II, Fujirebio, Japan, positive threshold value $\geq 1 : 40$) was used according to the manufacturer's instructions. *Mycoplasma pneumoniae* specific IgG antibodies were measured by SERION ELISA (enzyme-linked immunosorbent assay: Friedrich-Bergius-Ring 19, D-97076 Würzburg, Germany, positive threshold > 30 U/ml). We analyzed *M. pneumoniae*-IgM titres as continuous variables after natural logarithmic transformation to normalize their distribution. CURB-65 (confusion, urea, respiratory rate, blood pressure, and age) scores at admission and sequential organ failure assessment (SOFA) scores at 72 h after commencing therapy were calculated. We also recorded total hospital costs, including pharmacy, radiology, and laboratory costs (including tests of blood, urine and stool, arterial blood gas, and bacterial cultures), examination costs (including lung function tests, electrocardiogram, and ultrasound), medical staff fees (including costs for physicians and nurses), bed or room fees, and other costs such as nebulization and oxygen therapy. Costs of dealing with multiple co-morbidities were excluded. All the patients had chest radiographs and CT scans. The frontal and lateral chest radiographic findings and CT scan images were reviewed and classified independently by two senior radiologists (LH Liang and QZ Zhao) and two senior physicians (YP Zhou

and M Li) to ensure accuracy. Missing laboratory findings (most common in patients with less severe illness) were assumed to be normal [19]. The principal investigator reviewed every form and medical record to ensure accuracy. The study was approved by our Institutional Review Board (Review Board of Guangdong Medical College). No informed consent was required because the data were already in existence.

Statistical analysis

All statistical analyses were performed with Statistical Package for the Social Science for Windows version 13.0 (SPSS, Chicago, IL, USA). Categorical variables and continuous variables were reported as percentages and as the mean \pm standard deviation (SD), respectively. The χ^2 test, unpaired Student's *t*-test, univariate logistic regression and Spearman rank correlation were employed. A *p* value of < 0.05 was considered statistically significant.

Results

Baseline characteristics of patients

Characteristics of the patients are presented in Table I. Patients infected with *M. pneumoniae* were younger, more likely to be female, and more likely to have a less severe condition compared with such patients infected with other pathogens. *Mycoplasma pneumoniae* was an important causative organism of CAP in the current study, accounting for 30.2% of all cases. All patients underwent diagnostic tests for the detection of the etiologic agent of pneumonia, but the aetiologies were detected in only 21.7% of the patients infected with other pathogens. Hence, the data were not shown.

Table I. Baseline characteristics of the patients (mean ± SD, n = 1230)

Variable	<i>M. pneumoniae</i> pneumonia group	Other pneumonias group	t or χ^2 value	Value of p
Age [years]	31.3 ±11.6	50.4 ±22.4	15.702	< 0.001
Age ≥ 65 years [%]	2.2	31.8	132.151	< 0.001
Male sex [%]	39.8	51.0	13.717	< 0.001
Confusion [%]	0	2.1	7.963	0.005
Body temperature [°C]	37.5 ±1.1	37.5 ±1.1	0.281	0.779
Respiratory rate [breaths/min]	19.7 ±2.3	20.6 ±2.9	5.053	< 0.001
Low blood pressure* [%]	15.1	14.2	0.171	0.679
WBC count [10 ⁹ /l]	7.46 ±3.65	8.83 ±4.42	5.353	< 0.001
PaO ₂ /FiO ₂ ≤ 250 mm Hg [%]	0	3.6	13.914	< 0.001
Serum BUN ≥ 7 mmol/l [%]	0	7.5	29.413	< 0.001
Platelet count [10 ⁹ /l]	245.69 ±96.52	226.57 ±89.34	3.469	0.001
CURB-65 score: 0-1-2-3-4 [%]	82.8-17.2-0-0-0	53.8-35.4-9.4-1.1-0.2	107.118	< 0.001
Multilobar opacities, n (%)	15.1 (56)	29.3 (251)	29.295	< 0.001
Consolidation, n (%)	7.5 (28)	12.1 (104)	5.838	0.016

*Systolic < 90 mm Hg; or diastolic ≤ 60 mm Hg, WBC – white blood cell, PaO₂/FiO₂ – arterial oxygen pressure/fraction inspired oxygen, BUN – blood urea nitrogen, CURB-65 – confusion, urea, respiratory rate, blood pressure, and age

Mycoplasma pneumoniae-IgM titres

The percentages of patients with *M. pneumoniae*-IgM titres of 1 : 80, 1 : 160, 1 : 320, 1 : 640, 1 : 1280, 1 : 2560 and 1 : 5120 in acute phase sera in the *M. pneumoniae* pneumonia group were 26.9, 21.5, 11.8, 11.8, 20.4, 6.5 and 1.1, respectively. Patients with ground-glass opacification had higher *M. pneumoniae*-IgM titres compared with such patients with consolidation (1 : 2.524 ±1 : 0.521 vs. 1 : 2.243 ±1 : 0.414, t = 2.789, p = 0.006), but there was no significant difference in the titres between patients with a unilobar opacity and those with multilobar opacities (1 : 2.515

±1 : 0.515 vs. 1 : 2.436 ±1 : 0.539, t = 1.024, p = 0.309). Ground-glass opacity showed a significant positive relationship with *M. pneumoniae*-IgM titres (rank correlation coefficient (r_s) = 0.141, p = 0.006). *Mycoplasma pneumoniae* specific IgM titres in convalescent sera and *M. pneumoniae* specific IgG titres were not shown.

Distribution of opacities

Distribution of opacities amongst the lobes is shown in Figure 2. A significant difference was observed between the two groups (χ^2 = 110.824, p < 0.001). Compared with other lobes, the left up-

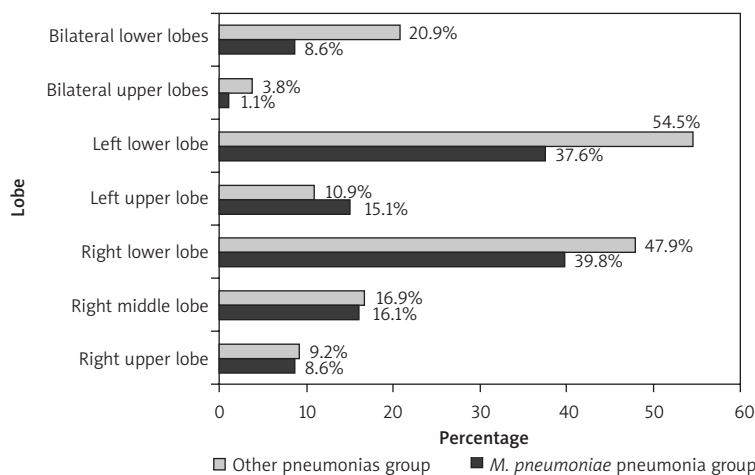


Figure 2. Distribution of opacities amongst the lobes

per lobe appeared more susceptible to infection with *M. pneumoniae* than with other pathogens ($\chi^2 = 4.437$, $p = 0.035$).

Radiological features according to demographic characteristics

Associations of lobar involvement and parenchymal opacification with patients' demographic characteristics are depicted in Tables II and III, respectively. Comparisons between the *M. pneumoniae* pneumonia group and the other pneumonias group are listed in columns, whereas comparisons between the subgroups are shown in rows. More increases in the risk of multilobar opacities were found among older patients than younger patients in both the *M. pneumoniae* pneumonia group and the oth-

er pneumonias group (odds ratio (OR), 1.065, 1.029; 95% confidence interval (CI), 1.041–1.089, 1.022–1.035; $p < 0.001$, $p < 0.001$; respectively). Older patients with *M. pneumoniae* pneumonia also showed a trend towards lower susceptibility to lobar pneumonia than younger patients (OR = 0.971; 95% CI: 0.932–1.011; $p = 0.155$), whereas older patients with other pneumonias had a decreased OR for lobar pneumonia compared with the younger patients (OR = 0.989; 95% CI: 0.980–0.997; $p = 0.009$). An increased OR for multilobar opacities was observed in male patients with *M. pneumoniae* pneumonia compared with the female patients (OR = 3.279; 95% CI: 1.812–5.934; $p < 0.001$), whereas with other pathogens this was decreased (OR = 0.744; 95% CI: 0.570–0.973; $p = 0.030$).

Table II. Associations of lobar involvement with clinical and laboratory characteristics (mean \pm SD, $n = 1230$)

Variable	Group	Multilobar opacities subgroup	Unilobar opacity subgroup	t or χ^2 value	Value of p
Age [years]	<i>M. pneumoniae</i> pneumonia	39.9 \pm 15.2	29.8 \pm 10.1	6.349	< 0.001
	Other pneumonias	60.2 \pm 23.2	46.3 \pm 20.8	9.485	< 0.001
	t	6.298	13.495		
	p	< 0.001	< 0.001		
Male sex [%]	<i>M. pneumoniae</i> pneumonia	64.3	35.4	16.519	< 0.001
	Other pneumonias	45.8	53.1	4.695	0.030
	χ^2	6.509	27.697		
	p	0.011	< 0.001		
CURB-65 score	<i>M. pneumoniae</i> pneumonia	0.29 \pm 0.46	0.15 \pm 0.36	2.459	0.014
	Other pneumonias	0.90 \pm 0.85	0.45 \pm 0.62	9.523	< 0.001
	t	5.312	8.076		
	p	< 0.001	< 0.001		
SOFA score	<i>M. pneumoniae</i> pneumonia	0.43 \pm 0.74	0.23 \pm 0.53	2.459	0.014
	Other pneumonias	1.20 \pm 1.59	0.54 \pm 1.08	7.762	< 0.001
	t	3.574	4.915		
	p	< 0.001	< 0.001		
Hospital LOS [days]	<i>M. pneumoniae</i> pneumonia	10.4 \pm 4.5	9.1 \pm 3.0	2.601	0.010
	Other pneumonias	11.9 \pm 10.3	9.4 \pm 4.4	5.594	< 0.001
	t	1.126	1.514		
	p	0.261	0.131		
Costs [\$]	<i>M. pneumoniae</i> pneumonia	768.22 \pm 411.26	623.47 \pm 270.69	3.375	0.001
	Other pneumonias	1204.35 \pm 1323.26	703.60 \pm 443.74	9.122	< 0.001
	t	2.366	2.564		
	p	0.019	0.010		

CURB-65 – confusion, urea, respiratory rate, blood pressure, and age, SOFA – sequential organ failure assessment, LOS – length of stay, \$ – US dollars

Table III. Associations of parenchymal opacification with clinical and laboratory characteristics (mean ± SD, n = 1230)

Variable	Group	Lobar pneumonia subgroup	Bronchopneumonia subgroup	t or χ^2 value	Value of p
Age [years]	<i>M. pneumoniae</i> pneumonia	28.3 ±8.1	31.6 ±11.8	1.966	0.057
	Other pneumonias	43.8 ±19.7	51.1 ±22.6	3.360	0.001
	t	4.340	15.275		
	p	< 0.001	< 0.001		
Male sex [%]	<i>M. pneumoniae</i> pneumonia	28.6	40.7	1.589	0.207
	Other pneumonias	49.2	51.2	0.178	0.915
	χ^2	3.934	11.049		
	p	0.047	0.001		
CURB-65 score	<i>M. pneumoniae</i> pneumonia	0.29 ±0.46	0.16 ±0.37	1.659	0.098
	Other pneumonias	0.56 ±0.77	0.58 ±0.72	0.329	0.742
	t	2.057	10.397		
	p	0.041	< 0.001		
SOFA score	<i>M. pneumoniae</i> pneumonia	0.14 ±0.36	0.27 ±0.58	1.119	0.264
	Other pneumonias	0.64 ±1.34	0.75 ±1.28	0.823	0.412
	t	3.539	6.741		
	p	0.001	< 0.001		
Hospital LOS [days]	<i>M. pneumoniae</i> pneumonia	14.1 ±4.4	9.5 ±3.6	5.409	< 0.001
	Other pneumonias	14.4 ±13.3	9.6 ±5.2	7.334	< 0.001
	t	0.100	0.250		
	p	0.920	0.803		
Costs [\$]	<i>M. pneumoniae</i> pneumonia	823.44 ±243.93	630.76 ±299.72	3.944	< 0.001
	Other pneumonias	1181.28 ±1311.15	808.57 ±749.44	4.579	< 0.001
	t	2.569	4.001		
	p	0.011	< 0.001		

CURB-65 – confusion, urea, respiratory rate, blood pressure, and age, SOFA – sequential organ failure assessment, LOS – length of stay, \$ – US dollars

Associations of lobar involvements with clinical and laboratory characteristics

Associations of lobar involvements with clinical and laboratory characteristics are shown in Table II. Multilobar opacities had significant positive relationships with CURB-65 scores in both the *M. pneumoniae* pneumonia group and the other pneumonias group ($r_s = 0.127$, $r_s = 0.262$; $p = 0.014$, $p < 0.001$; respectively). Multilobar opacities were associated with longer hospital LOS in both the *M. pneumoniae* pneumonia group and the other pneumonias group ($r_s = 0.111$, $r_s = 0.083$; $p = 0.033$, $p = 0.008$; respectively), incurring significantly higher costs ($r_s = 0.119$, $r_s = 0.201$; $p = 0.022$, $p < 0.001$; respectively).

Associations of parenchymal opacification with clinical and laboratory characteristics

Associations of parenchymal opacification with clinical and laboratory characteristics are shown in Table III. Consolidation had significant positive relationships with hospital LOS in both the *M. pneumo-*

niae pneumonia group and the other pneumonias group ($r_s = 0.275$, $r_s = 0.192$; $p < 0.001$, $p < 0.001$; respectively), as it did with costs despite no association with the severity of the disease ($r_s = 0.200$, $r_s = 0.151$; $p < 0.001$, $p < 0.001$; respectively).

Discussion

Our findings show that females were more susceptible to *M. pneumoniae* infection, that ground-glass opacification had a positive association with *M. pneumoniae*-IgM titres, that the left upper lobe was more susceptible to infection with *M. pneumoniae*, that older or male patients with *M. pneumoniae* pneumonia were more likely to show multilobar opacities, and that patients with *M. pneumoniae* pneumonia showing multilobar opacities or consolidation had a significantly longer hospital LOS and higher costs.

Radiographic manifestations of *M. pneumoniae* pneumonia can be extremely variable and mimic a wide variety of lung diseases. The inflammatory response elicited by *M. pneumoniae* causes interstitial mononuclear cell inflammation that may be

manifested radiographically as diffuse, reticular infiltrates of bronchopneumonia in the perihilar regions or lower lobes, usually with a unilateral distribution, and hilar adenopathy [4]. In the current study, the common radiographic features of *M. pneumoniae* pneumonia on chest radiographs and CT scans were ground-glass opacification, unilobar opacification, or lower lobe involvement as previously described by Mansel *et al.* [11] and Reittner *et al.* [20]. *Mycoplasma pneumoniae* is an extracellular pathogen, the survival of which depends on adherence to the respiratory epithelium, and this fixation to ciliary membranes is conducted primarily by interactive adhesion and accessory proteins. The major adhesion protein is P1 adhesin. Cytoadhesion protects *M. pneumoniae* from mucociliary clearance [21]. Hydrogen peroxide and superoxide radicals synthesized by *M. pneumoniae* act in concert with endogenous toxic oxygen molecules generated by host cells to induce oxidative stress in the respiratory epithelium [4]. Attachment of the microorganism to epithelial cilia is responsible for bronchial wall thickening [21]. Therefore, this attachment might be envisaged to interpret higher frequency of the presentation of ground-glass opacification in *M. pneumoniae* pneumonia compared with other pneumonias and the association of ground-glass opacification with higher *M. pneumoniae*-IgM titres. Our finding that lobar involvement did not associate with IgM titres is not congruent with what Waites *et al.* [4] observed (the cold agglutinin response often correlates directly with the severity of pulmonary involvement). On the basis of the current knowledge, we can envisage no definite mechanisms to account for the apparent increase in susceptibility of females to *M. pneumoniae* infection. As mycoplasma occurs in epidemic cycles, there may be local epidemiologic factors that may have played a role in the female preponderance to mycoplasma infection. Similarly, there is little information to determine the possible reasons why the left upper lobe was more susceptible to infection with *M. pneumoniae* than with other pathogens and it requires further epidemiological observations. Hence, further studies are warranted.

The frequency of consolidation in association with *M. pneumoniae* infection appears to vary greatly between studies. One study reported that consolidation was infrequent in adult patients in Japan [10], Hsieh *et al.* [12] reported a higher frequency of this pattern (38%) in paediatric patients in Taiwan, whereas Hosker *et al.* [13] reported that 95% of paediatric patients presented with this pattern in Hong Kong and Defilippi *et al.* [14] showed that consolidation was the commonest finding in children with infection due to *M. pneumoniae* in Genoa. Bilateral involvement may occur

in about 20% of cases [22], but it was observed in only 9.7% of the patients in the current study.

The factors determining disease manifestations and severity in *M. pneumoniae* infection are only partly understood. Few studies have attempted a clinical comparison of the effects of *M. pneumoniae* infection according to age. Youn *et al.* [15] reported that paediatric patients with segmental/lobar pneumonia were older than those with bronchopneumonia in Korea. Defilippi *et al.* [14] also found that the rate of chest radiographic consolidation was higher in older children with *M. pneumoniae* infection. There was a significantly increased OR for multilobar opacities in older adult patients and younger adult patients showed a trend toward susceptibility to lobar pneumonia in the current study. These may reflect the fact that the immune response and/or the mucociliary clearance of *M. pneumoniae* are less active in older adults and younger children, conferring a risk of more severe disease. On the basis of the above-mentioned rationale, it is difficult to interpret the positive association of multilobar opacities with male patients suffering from *M. pneumoniae* pneumonia in the current study. It warrants further study.

In the current study, the positive association of multilobar opacities, but not consolidation, with severity of the disease is consistent with the common understanding that the presentation of multilobar opacities is one of nine minor criteria for severe CAP [1]. There have been few previous studies about the associations of radiological features with hospital LOS and costs in patients with pneumonia due to *M. pneumoniae*. The length of stay depends on the time needed to reach clinical stability, which is significantly influenced by the severity of disease [23]. Bilateral or multilobar opacities on chest radiographs of low-risk CAP patients were not significantly associated with higher total costs [8], but we found that multilobar opacities were positively associated with hospital LOS and costs in both groups, as was consolidation despite no association with the severity of the disease, which might have implications for the management of *M. pneumoniae* pneumonia and other pathogens pneumonia and health economics.

A few laboratory findings were inevitably missed due to retrospective data collection. This phenomenon is most common in patients with less severe illness. Missing values were assumed to be normal in the current study. This strategy is widely used in the clinical application of prediction rules and reflects the methods used in the original derivation and validation of the Pneumonia Severity Index [19]. Even so, some of them might be abnormal. Therefore, the assumption might result in the alterations of statistical power and even statistical results and might give rise to misleading

conclusions. Hence, further prospective validation of our findings is warranted.

Several limitations of this study deserve comment. First, the numbers of patients with consolidation or multilobar opacities were relatively small despite this being a cohort study. Had the number been larger, perhaps the results might have been more robust. The best method to detect acute *M. pneumoniae* infection is a polymerase chain reaction assay. Therefore, a few patients infected with *M. pneumoniae* might be excluded because of the absence of IgM antibodies in the early stage. It was not multicentre. A further weakness of this study was its retrospective design.

In conclusion, females were more susceptible to *M. pneumoniae* pneumonia. Ground-glass opacification was associated with higher *M. pneumoniae*-IgM titres. The left upper lobe might be more likely to be infected with *M. pneumoniae* compared with other pathogens. Older or male patients with *M. pneumoniae* pneumonia were more likely to show multilobar opacities. Multilobar opacities and consolidation were positively associated with hospital LOS and costs.

Acknowledgments

Qi Guo and Hai-Yan Li are joint first authors.

We are indebted to the nurses, further education physicians and postgraduates of the Department of Respiratory Medicine, and the staff of the Department of Medical Record for making contributions to this study.

We thank Chris J. Corrigan (King's College London) for assistance in English editing.

The abstract (No. 501) has been accepted for a Thematic Poster at the ERS (European Respiratory Society) Amsterdam 2011 Annual Congress (24-28 September).

The study was funded by the medical science and technology foundation of Guangdong province in 2010 (No. A2010553), the planned science and technology project of Shenzhen municipality in 2011 (No. 201102078), and the non-profit scientific research project of Futian district in 2011 (No. FTWS201120).

References

- Mandell LA, Wunderink RG, Anzueto A, et al. Infectious Diseases Society of America/American Thoracic Society consensus guidelines on the management of community-acquired pneumonia in adults. *Clin Infect Dis* 2007; 44 (Suppl 2): S27-72.
- Restrepo MI, Anzueto A. Severe community-acquired pneumonia. *Infect Dis Clin North Am* 2009; 23: 503-20.
- Blasi F. Atypical pathogens and respiratory tract infections. *Eur Respir J* 2004; 24: 171-81.
- Waites KB, Talkington DF. *Mycoplasma pneumoniae* and its role as a human pathogen. *Clin Microbiol Rev* 2004; 17: 697-728.
- Atkinson TP, Balish MF, Waites KB. Epidemiology, clinical manifestations, pathogenesis and laboratory detection of *Mycoplasma pneumoniae* infections. *FEMS Microbiol Rev* 2008; 32: 956-73.
- Liu YN, Chen MJ, Zhao TM, et al. A multicentre study on the pathogenic agents in 665 adult patients with community-acquired pneumonia in cities of China. *Zhonghua Jie He He Hu Xi Za Zhi* 2006; 29: 3-8.
- Cao B, Ren LL, Zhao F, et al. Viral and *Mycoplasma pneumoniae* community-acquired pneumonia and novel clinical outcome evaluation in ambulatory adult patients in China. *Eur J Clin Microbiol Infect Dis* 2010; 29: 1443-8.
- Zhou QT, He B, Zhu H. Potential for cost-savings in the care of hospitalized low-risk community-acquired pneumonia patients in China. *Value Health* 2009; 12: 40-6.
- Koletsky RJ, Weinstein AJ. Fulminant *Mycoplasma pneumoniae* infection. Report of a fatal case, and review of the literature. *Am Rev Respir Dis* 1980; 122: 491-6.
- Miyashita N, Sugiu T, Kawai Y, et al. Radiographic features of *Mycoplasma pneumoniae* pneumonia: differential diagnosis and performance timing. *BMC Med Imaging* 2009; 9: 7.
- Mansel JK, Rosenow EC 3rd, Smith TF, Martin JW Jr. *Mycoplasma pneumoniae* pneumonia. *Chest* 1989; 95: 639-46.
- Hsieh SC, Kuo YT, Chern MS, Chen CY, Chan WP, Yu C. *Mycoplasma pneumoniae*: clinical and radiographic features in 39 children. *Pediatr Int* 2007; 49: 363-7.
- Hosker HS, Tam JS, Chain CH, Lai CK. *Mycoplasma pneumoniae* infection in Hong Kong: clinical and epidemiological features during an epidemic. *Respiration* 1993; 60: 237-40.
- Defilippi A, Silvestri M, Tacchella A, et al. Epidemiology and clinical features of *Mycoplasma pneumoniae* infection in children. *Respir Med* 2008; 102: 1762-8.
- Youn YS, Lee KY, Hwang JY, et al. Difference of clinical features in childhood *Mycoplasma pneumoniae* pneumonia. *BMC Pediatr* 2010; 10: 48.
- Phua J, See KC, Chan YH, et al. Validation and clinical implications of the IDSA/ATS minor criteria for severe community-acquired pneumonia. *Thorax* 2009; 64: 598-603.
- Hilbert G, Gruson D, Vargas F, et al. Noninvasive ventilation in immunosuppressed patients with pulmonary infiltrates, fever, and acute respiratory failure. *N Engl J Med* 2001; 344: 481-7.
- Hansell DM, Bankier AA, MacMahon H, McCloud TC, Müller NL, Remy J. Fleischner Society: glossary of terms for thoracic imaging. *Radiology* 2008; 246: 697-722.
- Aujesky D, Auble TE, Yealy DM, et al. Prospective comparison of three validated prediction rules for prognosis in community-acquired pneumonia. *Am J Med* 2005; 118: 384-92.
- Reittner P, Müller NL, Heyneman L, et al. *Mycoplasma pneumoniae* pneumonia: radiographic and high-resolution CT features in 28 patients. *AJR Am J Roentgenol* 2000; 174: 37-41.
- Kashyap S, Sarkar M. *Mycoplasma pneumoniae*: clinical features and management. *Lung India* 2010; 27: 75-85.
- Ferwerda A, Moll HA, de Groot R. Respiratory tract infections by *Mycoplasma pneumoniae* in children: a review of diagnostic and therapeutic measures. *Eur J Pediatr* 2001; 160: 483-91.
- Halm EA, Fine MJ, Marrie TJ, et al. Time to clinical stability in patients hospitalized with community-acquired pneumonia: implications for practice guidelines. *JAMA* 1998; 279: 1452-7.