

Asymmetric Resting Scapular Posture in Healthy Overhead Athletes

Sakiko Oyama, MS, ATC*†; Joseph B. Myers, PhD, ATC*†; Craig A. Wassinger, PhD, PT*; R. Daniel Ricci, MS, ATC‡; Scott M. Lephart, PhD, ATC*

*University of Pittsburgh, Pittsburgh, PA; †The University of North Carolina at Chapel Hill, Chapel Hill, NC; ‡Marshall University, Huntington, WV

Context: Observation of the scapular posture is one of the most important components of the physical examination in overhead athletes. Postural asymmetry is typically considered to be associated with injuries. However, asymmetry in the overhead athlete's scapula may be normal due to the dominant use of the limb.

Objective: To quantify the differences in resting scapular posture between the dominant and nondominant sides in 3 groups of healthy overhead athletes (baseball pitchers, volleyball players, and tennis players) using an electromagnetic tracking device.

Design: Cross-sectional design.

Setting: University-based biomechanics laboratory.

Patients or Other Participants: A total of 43 players participated, including 15 baseball pitchers, 15 volleyball players, and 13 tennis players. All participants were healthy college-aged men.

Intervention(s): Bilateral 3-dimensional scapular kinematics with the arm at rest were measured using an electromagnetic tracking device.

Main Outcome Measure(s): Bilateral scapular position and orientation were measured. Between-groups and between-sides differences in each variable were analyzed using separate analyses of variance.

Results: In tennis players, the scapula was more protracted on the dominant side than on the nondominant side ($P < .05$). In all overhead athletes, the dominant-side scapula was more internally rotated ($P = .001$) and anteriorly tilted ($P = .001$) than the nondominant-side scapula was.

Conclusions: The dominant-side scapula of the overhead athletes was more internally rotated and anteriorly tilted than the nondominant-side scapula. The dominant-side scapula of the tennis players was more protracted than that on the nondominant side. Clinicians evaluating overhead athletes need to recognize that scapular posture asymmetry in unilateral overhead athletes may be normal. Our results emphasize the importance of the baseline evaluation in this population in order to accurately assess pathologic change in bilateral scapular positions and orientations after injury.

Key Words: scapular kinematics, baseline assessment, shoulder evaluation

Key Points

- Overhead athletes displayed more anterior tilt and internal rotation of the dominant shoulder.
- Scapular postural asymmetry in unilateral overhead athletes should be documented on the baseline evaluation, because it may be normal and unrelated to injury.

Observation of the scapular posture is one of the most important components of the physical examination in overhead athletes.¹⁻⁸ During the clinical examination, clinicians observe the asymmetry in shoulder and scapular posture, such as muscle atrophy, bony contour, excessive scapular winging, inferior angle prominence, and presence of a scar.¹⁻⁶ Postural asymmetries found during the clinical examination may be related to abnormalities.^{1,9} However, many clinicians agree that asymmetric findings in shoulder posture are quite common, regardless of the presence of abnormalities.^{3,10} The dominant shoulder typically is positioned lower than the nondominant shoulder in most people.³ Anecdotally, this has been attributed to the stretching of the ligaments, joint capsules, and muscles from more frequent use of the dominant shoulder compared with that on the nondominant side.¹⁰ This asymmetry in shoulder posture is believed to be further accentuated in unilateral overhead athletes who use their dominant shoulder repetitively in a forceful manner.

Despite the importance of the postural evaluation in the physical examination, research on postural asymmetry in the shoulder is lacking. Therefore, the presence of asymmetry often is considered to be problematic without clear evidence of same.^{1,4,9,11} For example, Burkhart et al¹¹ used the acronym SICK (scapular malposition, inferior medial border prominence, coracoid pain and malposition, and dyskinesia) to describe the asymmetry of the scapula commonly seen in overhead athletes with shoulder abnormalities. Burkhart et al¹¹ theorized that this asymmetry is a sign of the underlying alteration in the muscle activation associated with various shoulder conditions, based on the assumption that the asymmetry is abnormal. Similarly, the lateral scapular slide test⁹ is a clinical examination used to identify scapular asymmetry, based on the idea that the asymmetry is an abnormality that needs to be identified and rehabilitated.⁸

A digital inclinometer and tape measure have been used to quantify scapular posture asymmetry in patients with shoulder abnormalities. However, the investigators using

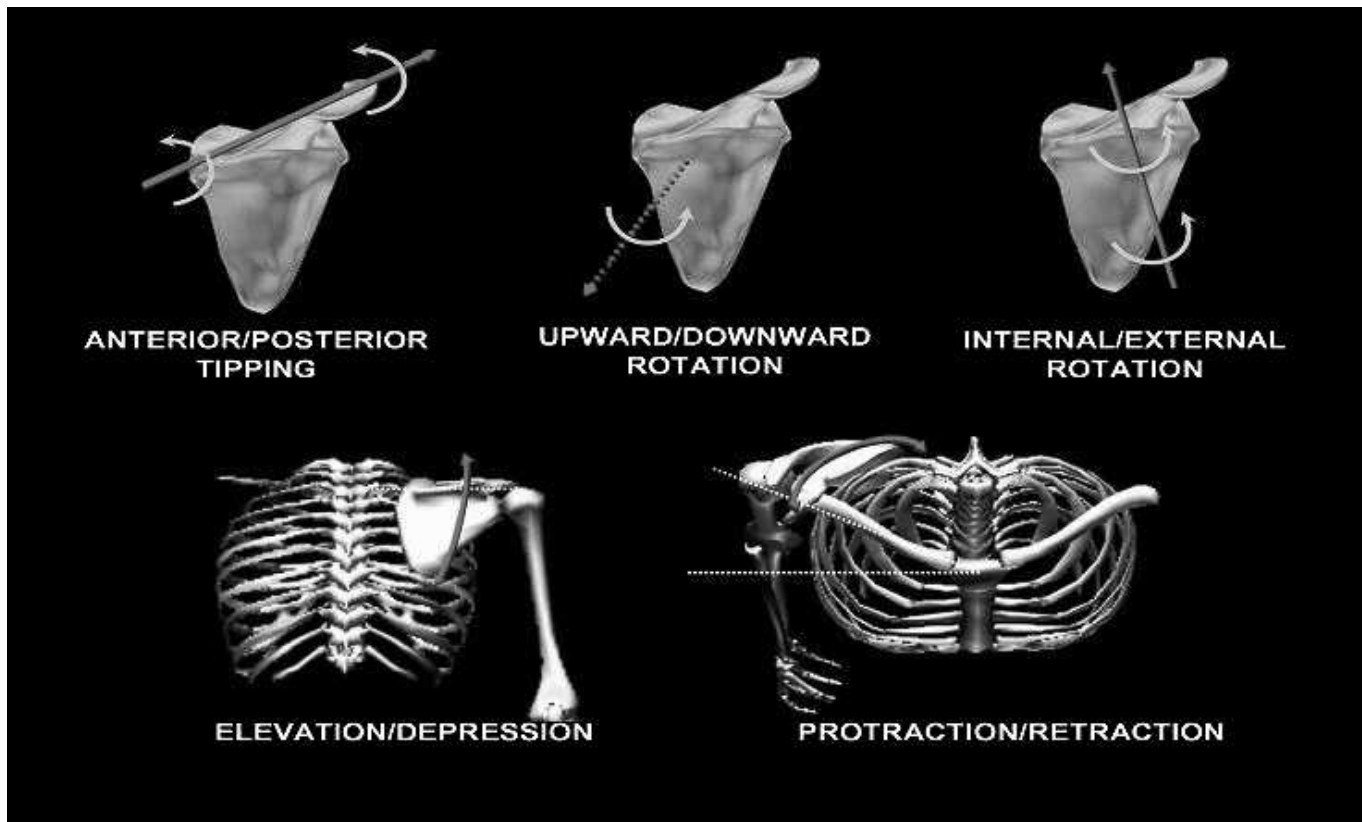


Figure 1. Three-dimensional scapular position and orientation.¹⁶

these devices have been unable to demonstrate the asymmetry in healthy groups or those with abnormalities.^{7,12,13} The inability to describe scapular posture 3-dimensionally may be a reason for the lack of significant findings in these studies. Three-dimensional evaluation of scapula posture using moiré topographic analysis has demonstrated a higher prevalence of scapular asymmetry in participants with shoulder abnormalities.¹⁴ However, the scapular position and orientation contributing to the asymmetry cannot be calculated using this method. Electromagnetic tracking devices allow calculation of 3-dimensional scapular positions and orientations¹⁵ (Figure 1). Quantification of the 3-dimensional scapular posture enables the researcher to identify the specific scapular kinematic variables that contribute to the scapular posture asymmetry.

The purpose of our study was to quantify the resting scapular posture in 3 groups of healthy overhead athletes (baseball pitchers, volleyball players, and tennis players) by using an electromagnetic tracking device and to determine whether these groups of overhead athletes displayed asymmetry in resting scapular posture. We hypothesized that the asymmetry would be present in all 3 groups of healthy overhead athletes from the repetitive use of the dominant shoulder. Identifying scapular asymmetry in healthy overhead athletes is important because it provides a basis for comparison with injured overhead athletes.

METHODS

Participants

Fifteen collegiate baseball pitchers (age = 20.0 ± 1.1 years, height = 181.5 ± 7.1 cm, mass = 88.1 ± 14.8 kg; 13

right-hand dominant, 2 left-hand dominant), 15 competitive volleyball players (university club; age = 21.5 ± 2.9 years, height = 188.4 ± 5.7 cm, mass = 85.4 ± 7.3 kg; all right-hand dominant), and 13 competitive tennis players (university club; age = 21.8 ± 2.8 years, height = 177.4 ± 5.6 cm, mass = 78.9 ± 8.2 kg; 12 right-hand dominant, 1 left-hand dominant) participated in this study. The dominant limb was identified as the arm that would be used to throw a ball. Only men were recruited for this study to control for possible sex differences. Those with a previous history of shoulder surgery or traumatic injury (dislocation, subluxation, or acromioclavicular joint sprain) were excluded from this study. Participants with shoulder or elbow pain within 6 months of testing also were excluded from the study.

Instrumentation

We used the Motion Monitor electromagnetic tracking device (Innovative Sports Training, Inc, Chicago, IL) to assess 3-dimensional scapular resting position (Figure 2). The device consists of a transmitter that creates an electromagnetic field and receivers that detect the electromagnetic field emitted by the transmitter. The receivers were attached to specific body segments as described in the previous literature.^{17,18} The electromagnetic tracking device recorded the position and orientation of the receivers about the x-axis, y-axis, and z-axis relative to the transmitter (global coordinate system).¹⁸ By digitizing the anatomical landmarks with a stylus, the orientation of one body segment was calculated with respect to another. The data were collected at 100 Hz.

All kinematic assessments were performed with the participants standing with their heels 3 ft (0.9 m) from

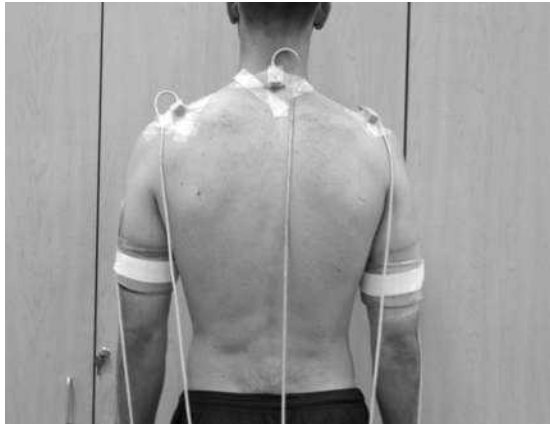

Figure 2. Scapular posture assessment using electromagnetic tracking device.

the transmitter, because it was determined previously in our laboratory¹⁹ that this region of the measurement space demonstrated the least amount of position (0.7 mm) and orientation (0.27°) error. Additionally, reliability and precision for scapulohumeral motion had been established by our laboratory as an intrasession intraclass correlation coefficient of .967 with 0.94° of error and intersession value of .889 with 2.11° of error.¹⁹

Procedures

All testing in the current study was performed in a university biomechanics research laboratory. Before testing, each participant provided informed consent as required by the institutional review board, which also approved the study.

We used 6 receivers for bilateral scapular resting position assessment, attached as follows: the spinous process of the seventh cervical vertebra, the flat portion of the acromion processes bilaterally, and the midshaft of the posterior humerus bilaterally. All receivers were secured on the skin using double-sided adhesive disks (3M Health Care, St Paul, MN), prewrap, athletic tape, and a hook-and-loop strap to minimize skin-receiver movement. The sixth receiver was attached to the stylus that was used to palpate and digitize the anatomical landmarks on the upper arm, scapula, and thorax. The anatomical landmarks digitized included the eighth thoracic vertebra, xiphoid process, seventh cervical vertebrae, jugular notch, sternoclavicular joint, acromioclavicular joint, medial scapular border where it intersects with the scapular spine, inferior scapular angle, medial epicondyle, lateral epicondyle, and glenohumeral joint center. Landmarks on the humerus and the scapula were digitized bilaterally. Because the glenohumeral joint center cannot be palpated, it was estimated as the point that moves least with respect to the scapula when the humerus is moved passively through several short arcs. Digitizing these anatomical landmarks on each segment allowed construction of the local coordinate system for each body segment (thorax, scapula, and humerus). Using local coordinate systems, we calculated the position and orientation of the scapula with respect to the thorax.

Each participant performed 10 continuous repetitions of bilateral full-shoulder elevation in the scapular plane (30° anterior to the frontal plane). The volunteer elevated the

arm in 2 seconds and lowered the arm in 2 seconds, guided by the metronome. The participants were instructed to bring their arms to rest by their sides at the end of each repetition. This procedure allowed the volunteers to be distracted from the postural assessment, which may have helped to capture their natural posture. Bilateral resting scapular posture was measured as the scapular position and orientation when the arms were at the sides between the 10 repetitions of the elevation task. The averages of the 5 middle recordings for both limbs were used for analysis.

Data Reduction

Raw scapular kinematic data were filtered with a low-pass, 10-Hz Butterworth filter. The position and orientation data of the receivers and the digitized anatomical landmarks were used to construct local coordinate systems for the thorax, scapula, and humerus. The coordinate systems used were in accordance with recommendations from the International Shoulder Group of the International Society of Biomechanics.¹⁵ When the participant stood in an anatomical position, the coordinate system for each segment was vertical (y-axis), horizontal to the right (x-axis), and posterior (z-axis). Scapular orientation was determined as rotation about the y-axis of the scapula (internal-external rotation), rotation about the z-axis of the scapula (upward-downward rotation), and rotation about the x-axis of the scapula (anterior-posterior tipping). We used Euler angle decompositions to determine scapular and humeral orientation with respect to the thorax. The rotation sequence of the Euler angles was chosen based on the recommendation of the International Shoulder Group.¹⁵ The scapula is attached to the thorax via the clavicle, a rigid body with a fixed length; therefore, the position of the scapula could be described as the orientation of the vector extending from the sternoclavicular joint to the acromioclavicular joint with respect to the local coordinate system of the thorax. Anatomically, the vector extending from the sternoclavicular joint to the acromioclavicular joint closely represents the orientation of the clavicle. The scapular protraction-retraction angle was calculated as the angle formed between the vector extending from the sternoclavicular joint points to the acromioclavicular joint points and the frontal plane of the thorax, and the scapular elevation-depression angle was calculated as an angle formed between the vector and the transverse plane of the thorax. Variables were calculated and processed using MATLAB (version 12; The MathWorks Inc, Natick, MA).

Data Analysis

Between-limbs and between-groups differences in each variable (upward-downward rotation, internal-external rotation, anterior-posterior tilt, protraction-retraction, and elevation-depression) were analyzed using separate within-subjects, between-subjects factor analyses of variance. Tukey post hoc analysis was conducted when the interaction was significant. We performed the statistical analysis using SPSS (version 12; SPSS Inc, Chicago, IL). The level of significance was set a priori at .05.

RESULTS

Three-dimensional scapular position assessment demonstrated no limb-by-group interaction in any of the scapular

Table. Scapular Resting Position and Orientation (Between-Limbs Main Effect)

Position and Orientation	Mean \pm SD	P Value
Scapular upward-downward rotation, $^{\circ}$		
Dominant	3.46 \pm 6.17	.279
Nondominant	2.00 \pm 7.42	
Bilateral difference	1.45 \pm 8.05	
Scapular internal-external rotation, $^{\circ}$		
Dominant	30.34 \pm 7.57	.001 ^a
Nondominant	26.47 \pm 7.35	
Bilateral difference	3.86 \pm 7.52	
Scapular anterior-posterior tilt, $^{\circ}$		
Dominant	15.90 \pm 4.82	.001 ^a
Nondominant	14.02 \pm 5.30	
Difference	1.88 \pm 3.57	
Scapular protraction-retraction, $^{\circ}$		
Dominant	-16.28 \pm 5.59	.003 ^a
Nondominant	-18.78 \pm 5.53	
Difference	2.50 \pm 6.03	
Scapular elevation-depression, $^{\circ}$		
Dominant	6.80 \pm 5.03	.455
Nondominant	7.38 \pm 4.58	
Difference	0.58 \pm 5.40	

^a Significant difference at α level of .05.

kinematics variables except for protraction-retraction ($P = .005$). The post hoc analysis showed a difference between the dominant and nondominant shoulders in tennis players (mean difference = 5.93° , honestly significant difference = 4.49° , $P < .05$) but not in baseball players (mean difference = 3.12° , honestly significant difference = 4.18°) or volleyball players (mean difference = -1.11° , honestly significant difference = 4.18°). A limb main effect was demonstrated, with the dominant-side scapula being more internally rotated (dominant = $30.34^{\circ} \pm 7.57^{\circ}$, nondominant = $26.47^{\circ} \pm 7.35^{\circ}$, $P = .001$) and anteriorly tilted (dominant = $15.90^{\circ} \pm 4.82^{\circ}$, nondominant = $14.02^{\circ} \pm 5.30^{\circ}$, $P = .001$) compared with the nondominant side (Table). No bilateral differences in scapular upward-downward rotation or elevation-depression were identified.

DISCUSSION

Our objective was to quantify resting scapular posture in 3 groups of healthy overhead athletes and to characterize any asymmetry. Indeed, we found resting scapular posture asymmetry between the dominant and nondominant sides in healthy overhead athletes. Specifically, the dominant shoulder of the overhead athlete was more anteriorly tilted and internally rotated. In tennis players, the dominant shoulder also was more protracted. Because the demands placed on the shoulders of baseball, volleyball, and tennis players are different, we expected to see differences in scapular posture among groups. The increased protraction found in tennis players (but not in baseball or volleyball players) may reflect the different sport demands on the shoulder. Increased moment of inertia of the upper extremity from holding a tennis racquet may result in greater stress at the shoulder. However, further biomechanical analysis of these overhead athletes is needed to examine this hypothesis.

Because all participants in this study were asymptomatic, the presence of postural asymmetry seems to be normal in the population of unilateral overhead athletes. Therefore, our results confirm that asymmetric resting scapular posture exists in healthy overhead athletes. Thus, a clinical assessment method based on the assumption that posture in a healthy population is symmetric (such as the lateral scapular slide test) must be performed with the knowledge that some level of asymmetry may exist, but it is not necessarily problematic.

Burkhart et al¹¹ reported that injured overhead athletes typically present with the asymmetrically “dropped” shoulder on the affected side, caused by increased scapular protraction, anterior tilting, and internal rotation. This pattern is similar to the scapular asymmetry we found in healthy overhead athletes. Our findings suggest that the asymmetry found in the injured athletes may not necessarily be related to the abnormality. Injured overhead athletes may display more asymmetry than healthy overhead athletes, and there may be a pathologic threshold for scapular posture asymmetry at which an asymmetry becomes problematic. However, these possibilities cannot be confirmed without comparing resting scapular posture asymmetry between healthy and injured overhead athletes.

Decreased scapular upward rotation and increased protraction, internal rotation, and anterior tipping on the injured side (the dominant side in most cases) are commonly found in patients with various shoulder conditions.²⁰⁻²³ The healthy unilateral overhead athletes in this study exhibited scapular posture characteristics similar to those found in injured patients, except for the decrease in scapular upward rotation. This finding may suggest that asymmetrically decreased upward rotation is associated with injuries. Further investigation is needed to examine the relationship between the upward rotation asymmetry and shoulder abnormalities.

The differences in scapular posture between the dominant and nondominant shoulders in this study were less than 4° . The scapular asymmetry about each rotation axis was small, which may be why authors who used 2-dimensional measuring methods, such as a tape measure^{7,12} or an inclinometer,²⁴ were unable to detect asymmetry. The asymmetric appearance of the scapula may be due to the combined effect of the rotations about multiple axes.

The anatomical structures contributing to scapular posture asymmetry are not clearly understood. However, considering the asymmetric characteristics of overhead athletes' shoulders (such as humeral retroversion,²⁵ range of motion,^{13,24} strength,²⁶ and posterior shoulder tightness^{13,27-29}), asymmetry in the resting shoulder posture is not surprising. Although assessing range of motion and posterior shoulder tightness was not the aim of this study, we (Oyama et al, unpublished data, 2007) evaluated the range of motion and posterior shoulder tightness in the participants and found 7° to approximately 9° of difference between the dominant and nondominant sides in mean internal rotation range of motion, external rotation range of motion, and posterior shoulder tightness. Furthermore, whether the postural asymmetry we found is unique to the unilateral overhead athletes due to sport participation or is common to the general population as a result of hand dominance is unknown. Unilateral overhead athletes and nonoverhead athletes need to be investigated in the future.

Clinical Applications

Clinicians evaluating overhead athletes need to keep in mind that some degree of resting scapular posture asymmetry may be present in the shoulders of healthy overhead athletes. Measuring scapular posture after the athlete is injured will not allow the clinician to determine if the asymmetry is a normal adaptation that existed before the injury or an abnormal change associated with the injury. Therefore, measuring baseline scapular posture before preseason training for comparison if the player is injured may help identify the “abnormal asymmetry” related to the injury.

Limitations

Although the healthy overhead athletes displayed asymmetry, the differences we found between the dominant and nondominant shoulders were small (differences = 1.9° to 3.9°) relative to their SDs. Combined with the standard error of the measurement technique itself, the asymmetry we found may be smaller or larger than the true value. Therefore, our results need to be used with caution, and further investigation is warranted. Additionally, resting scapular posture is a static measurement and may not reflect scapular kinematics during functional movements. Thus, when evaluating athletes with shoulder injuries, it is important to assess both resting scapular posture and dynamic scapular kinematics.

Future Directions

Assessing shoulder posture asymmetry in nonoverhead athletes and overhead athletes with various shoulder abnormalities may reveal useful information regarding the postural changes associated with participation in overhead sports and with shoulder conditions. Furthermore, obtaining baseline evaluation of scapular asymmetry and prospectively studying shoulder injuries will provide valuable information regarding the possible cause-and-effect relationship between resting scapular posture and injury.

CONCLUSIONS

The scapula on the dominant side of healthy overhead athletes was more anteriorly tilted and internally rotated during static scapular posture assessment. In tennis players, the dominant shoulder also was more protracted. Clinicians evaluating overhead athletes need to keep in mind that scapular posture asymmetry between the dominant and nondominant sides in unilateral overhead athletes may be normal and not necessarily related to injury. Our results emphasize the importance of baseline evaluation of the scapular posture in overhead athletes for the accurate assessment of the scapular asymmetry after injury.

ACKNOWLEDGMENTS

This research project was completed in the Neuromuscular Research Laboratory as part of a thesis requirement in the Department of Sports Medicine and Nutrition at the University of Pittsburgh. We are grateful for the financial support provided for this project by the University of Pittsburgh Freddie H. Fu, MD, Graduate Research Award.

REFERENCES

1. Burkhart SS, Morgan CD, Kibler WB. The disabled throwing shoulder: spectrum of pathology. Part II: evaluation and treatment of SLAP lesions in throwers. *Arthroscopy*. 2003;19(5):531–539.
2. Hoppenfeld S. *Physical Examination of the Spine and Extremities*. East Norwalk, CT: Appleton Century Crofts; 1976.
3. Kendall FP, McCreary EK. *Muscles: Testing and Function*. 3rd ed. Baltimore, MD: Williams & Wilkins; 1983.
4. Kibler WB, McMullen J. Scapular dyskinesia and its relation to shoulder pain. *J Am Acad Orthop Surg*. 2003;11(2):142–151.
5. Kibler WB, Uhl TL, Maddux JW, Brooks PV, Zeller B, McMullen J. Qualitative clinical evaluation of scapular dysfunction: a reliability study. *J Shoulder Elbow Surg*. 2002;11(6):550–556.
6. Meister K. Injuries to the shoulder in the throwing athlete, part two: evaluation/treatment. *Am J Sports Med*. 2000;28(4):587–601.
7. Greenfield B, Catlin PA, Coats PW, Green E, McDonald JJ, North C. Posture in patients with shoulder overuse injuries and healthy individuals. *J Orthop Sports Phys Ther*. 1995;21(5):287–295.
8. Kibler WB. The role of the scapula in athletic shoulder function. *Am J Sports Med*. 1998;26(2):325–337.
9. Kibler WB. Role of the scapula in the overhead throwing motion. *Contemp Orthop*. 1991;22(5):525–532.
10. Magee DJ. *Orthopedic Physical Assessment*. 3rd ed. Philadelphia, PA: WB Saunders; 1997.
11. Burkhart SS, Morgan CD, Kibler WB. The disabled throwing shoulder: spectrum of pathology. Part III: The SICK scapula, scapular dyskinesia, the kinetic chain, and rehabilitation. *Arthroscopy*. 2003;19(6):641–661.
12. Odom CJ, Taylor AB, Hurd CE, Denegar CR. Measurement of scapular asymmetry and assessment of shoulder dysfunction using the Lateral Scapular Slide Test: a reliability and validity study. *Phys Ther*. 2001;81(2):799–809.
13. Downar JM, Sauers EL. Clinical measures of shoulder mobility in the professional baseball player. *J Athl Train*. 2005;40(1):23–29.
14. Warner JJ, Micheli LJ, Arslanian LE, Kennedy J, Kennedy R. Scapulothoracic motion in normal shoulders and shoulders with glenohumeral instability and impingement syndrome: a study using moiré topographic analysis. *Clin Orthop Relat Res*. 1992;285:191–199.
15. Wu G, van der Helm FC, Veeger HE, et al. ISB recommendation on definitions of joint coordinate systems of various joints for the reporting of human joint motion, part II: shoulder, elbow, wrist, and hand. *J Biomech*. 2005;38(5):981–992.
16. Myers JB, Laudner KG, Pasquale MR, Bradley JP, Lephart SM. Scapular position and orientation in throwing athletes. *Am J Sports Med*. 2005;33(2):263–271.
17. Meskers CG, Fraterman H, van der Helm FC, Vermeulen HM, Rozing PM. Calibration of the “Flock of Birds” electromagnetic tracking device and its application in shoulder motion studies. *J Biomech*. 1999;32(6):629–633.
18. Meskers CG, Vermeulen HM, de Groot JH, van Der Helm FC, Rozing PM. 3D shoulder position measurements using a six-degree-of-freedom electromagnetic tracking device. *Clin Biomech (Bristol, Avon)*. 1998;13(4–5):280–292.
19. Myers JB, Jolly J, Nagai T, Lephart SM. Reliability and precision of in vivo scapular kinematic measurements using an electromagnetic tracking device. *J Sport Rehabil*. 2006;15(2):125–143.
20. Ellenbecker TS, Mattalino AJ. Glenohumeral joint range of motion and rotator cuff strength following arthroscopic anterior stabilization with thermal capsulorrhaphy. *J Orthop Sports Phys Ther*. 1999;29(3):160–167.
21. Ludewig PM, Cook TM. Alterations in shoulder kinematics and associated muscle activity in people with symptoms of shoulder impingement. *Phys Ther*. 2000;80(3):276–291.
22. Lukasiewicz AC, McClure P, Michener L, Pratt N, Sennett B. Comparison of 3-dimensional scapular position and orientation between subjects with and without shoulder impingement. *J Orthop Sports Phys Ther*. 1999;29(10):574–586.

23. McClure PW, Bialker J, Neff N, Williams G, Karduna A. Shoulder function and 3-dimensional kinematics in people with shoulder impingement syndrome before and after a 6-week exercise program. *Phys Ther.* 2004;84(9):832–848.
24. Downar JM, Sauers EL, Mourrtacos SL. Chronic adaptations in the throwing shoulder of professional baseball players [abstract]. *J Athl Train.* 2002;37(suppl 2):S-17–S-18.
25. Osbahr DC, Cannon DL, Speer KP. Retroversion of the humerus in the throwing shoulder of college baseball pitchers. *Am J Sports Med.* 2002;30(3):347–353.
26. Donatelli R, Ellenbecker TS, Ekedahl SR, Wilkes JS, Kocher K, Adam J. Assessment of shoulder strength in professional baseball pitchers. *J Orthop Sports Phys Ther.* 2000;30(9):544–551.
27. Myers JB, Laudner KG, Pasquale MR, Bradley JP, Lephart SM. Glenohumeral range of motion deficits and posterior shoulder tightness in throwers with pathologic internal impingement. *Am J Sports Med.* 2006;34(3):385–391.
28. Tyler TF, Nicholas SJ, Roy T, Gleim GW. Quantification of posterior capsule tightness and motion loss in patients with shoulder impingement. *Am J Sports Med.* 2000;28(5):668–673.
29. Tyler TF, Roy T, Nicholas SJ, Gleim GW. Reliability and validity of a new method of measuring posterior shoulder tightness. *J Orthop Sports Phys Ther.* 1999;29(5):262–274.

Sakiko Oyama, MS, ATC, and Joseph B. Myers, PhD, ATC, contributed to conception and design; analysis and interpretation of the data; and drafting, critical revision, and final approval of the article. Craig A. Wassinger, PhD, PT, and R. Daniel Ricci, MS, ATC, contributed to conception and design, acquisition and analysis and interpretation of the data, and drafting and final approval of the article. Scott M. Lephart, PhD, ATC, contributed to conception and design and drafting, critical revision, and final approval of the article.

Address correspondence to Joseph B. Myers, PhD, ATC, University of North Carolina at Chapel Hill, Department of Exercise and Sport Science, 305 Woollen, CB# 8605, Chapel Hill, NC 27599-8605. Address e-mail to joemyers@email.unc.edu.