

# Asymptomatic Lipoma of Corpus Callosum – Computerised Tomographic Demonstration

M Sambasivan<sup>a</sup>, P Sanal Kumar<sup>a</sup>, Mahesh<sup>a</sup>, Abeed Basheer<sup>a</sup>

a. Cosmopolitan Hospital, Thiruvananthapuram\*

## ABSTRACT

Published on 31<sup>st</sup> December 2009

Corpus callosum lipomas are rare. 50% of the corpus callosum lipomas were asymptomatic and were diagnosed during routine neuro-radiological investigations. The present case is an incidental C.T. finding while investigating a case of head trauma. In symptomatic cases 50% presented with fits, 20% with mental retardation, and 13% with hemi paresis. The article presents a 15 year old boy in whom a corpus callosum lipoma was detected during evaluation for head injury.

**Keywords:** Intracranial lipoma, Incidental detection.

\*See End Note for complete author details

A 15 year old boy was admitted with history of alleged fall with head hitting the ground while playing. The friends gave a history of transient loss of consciousness immediately after the fall from which he recovered completely within minutes. There was no history of tongue biting, froth coming from the mouth, convulsive movements or incontinence of urine. There was no past history of epilepsy.

On examination the patient was conscious, oriented, pupils were equal and reacting to light, moving all 4 limbs and no focal neurological deficit. Plantars were down going. Fundi were normal. There was evidence

of soft tissue contusion in the occipital region. BP 110/80, PR 78/mt. No abnormality was detected in the cardiovascular, respiratory and gastrointestinal system.

Computerized Tomography of head showed a hypodense lesion -83 to -108 Hounsfield unit (7.8 x 1.0 x 1.3cm in the Antero posterior x Cranio caudal x transverse) with focal anterior calcification seen along the corpus callosum. No other focal neuro parenchymal lesion seen. C.T. findings were suggestive of lipoma of corpus callosum. Since it was an incidental asymptomatic lesion patient was left alone and advised to come for periodic follow up.

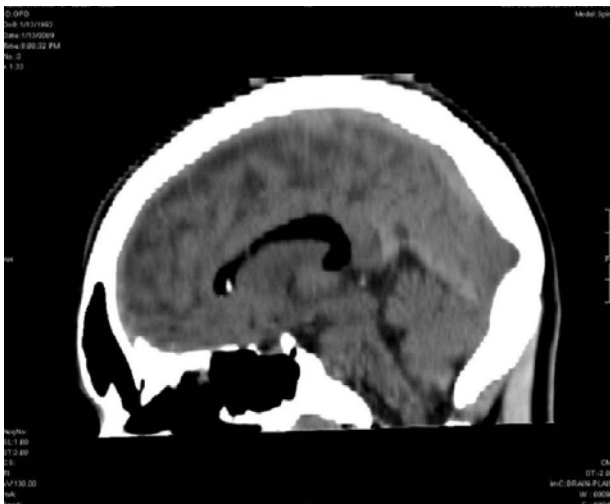


Figure 1. Sagittal section of CT brain shows homogenous hypodense lesion (-83 to -108 Hounsfield units) involving the corpus callosum from genu through the body to the splenium, 7.8 cm X 1.0 cm X 1.3 cm (anteroposterior X cranio-caudal X transverse ) with focal anterior calcification – suggestive of corpus callosum lipoma

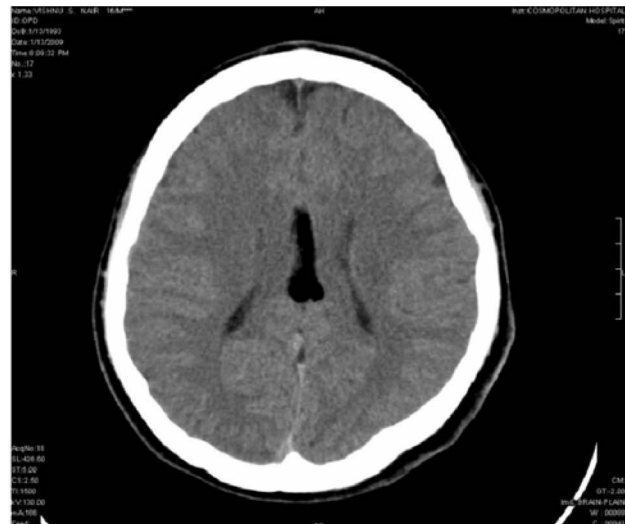

Figure 2. Axial section of CT brain. Note – Separated and parallel lateral ventricles. Midline hypodense lesion having characteristic Hounsfield value of fat (-83 to-108) suggestive of corpus callosum lipoma

## Corresponding Author:

Dr. M Sambasivan, MS, MS (Neuro Surgery), FRCS. Hon. Senior Consultant, Neuro Surgeon, Cosmopolitan Hospital Thiruvananthapuram. Phone: 04712521136. E-mail: imaksb@yahoo.co.in

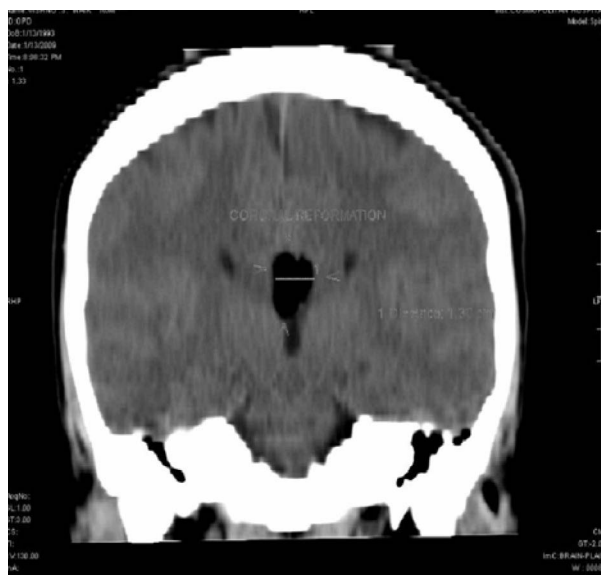


Figure 3. Coronal section of CT brain shows midline hypodense lesion with attenuation values of -83 to -108 characteristic of lipoma.

## DISCUSSION

Lipomas can occur in any part of the body but intracranial lipomas are extremely rare and are developmental in origin. Abnormal resorption of primitive meninges is said to be responsible for the development of these lipomas. During embryological development, resorption of primitive meninges usually takes place between 8<sup>th</sup> and 10<sup>th</sup> week of intrauterine life. If the primitive meninges persist longer, it may eventually differentiate into fatty tissue. This is considered to be the pathogenesis of intracranial lipomas.

Intracranial lipomas have been described in the ambient cistern, quadrigeminal plate, chiasmatic cistern, cerebellomedullary cistern, tela choroidea of lateral and third ventricles, choroid plexus, velum interpositum and callosal cistern (Kazner et al. 1980)<sup>1</sup> Intracranial lipomas frequently occur in the region of corpus callosum (40-50%) and are associated with varying degrees of dysgenesis of corpus callosum. Lipoma of corpus callosum was first described by Rokitsansky in a case of necropsy on 1856.

Review of literature revealed that 50% of the corpus callosum lipomas were asymptomatic and were diagnosed during routine neuro-radiological investigations. The present case is an incidental C.T. finding while investigating a case of head trauma. In symptomatic cases 50% presented with fits, 20% with mental retardation, and 13% with hemiparesis. We have reported a case of lipoma of corpus callosum with review of literature in Neurology India 1988 which was excised totally.<sup>3</sup>

In pre C.T. era, intracranial lipomas were rarely

encountered. Peripheral calcification of lipoma in plain x-rays is reported to be diagnostic. With the advent of C.T. and M.R.I scanning more and more cases of lipomas have been reported.

C.T. appearance of lipoma of corpus callosum was first described by New and Scott (1975)<sup>4</sup> followed by Wallace (1976), Fuerber and Wolpert (1978). A homogenous low density area with attenuation values between -60 and -200 Hounsfield unit, no contrast enhancement, regular margins and often peripheral calcification are the main characteristics of the lesion on the C.T. scan. Dermoids and teratomas should be considered in the differential diagnosis of low density lesions but they have a non homogenous low density which could be detected at a low window level

Corpus callosum lipomas are very slow growing lesions. Only very rarely they attain a large size sufficient to cause mass effect. Hence they rarely need surgery. Radical excision of the corpus callosum lipoma is almost impossible because of the firm adhesion to the surrounding brain tissue and high vascularity of the lesion. More over the lesion may encompass the anterior cerebral arteries or their branches. Hence during radical removal we may have to sacrifice both anterior cerebral arteries which may lead to compromise of anterior circulation with attendant complications.

## END NOTE

### Author Information

1. Dr. M Sambasivan, MS, MS (Neuro Surgery), FRCS. Hon., Senior Consultant, Neuro Surgeon, Cosmopolitan Hospital, Thiruvananthapuram
2. Dr. P Sanalkumar, MS (Gen), MCh (Neuro Surgery), Senior Consultant, Neuro Surgeon, Cosmopolitan Hospital, Thiruvananthapuram
3. Dr. Mahesh, MCh (Neuro Surgery), Senior Consultant, Neuro Surgeon, Cosmopolitan Hospital, Thiruvananthapuram
4. Dr. Abeer Bash, MBBS, Medical Officer, Cosmopolitan Hospital, Thiruvananthapuram

**Conflict of Interest:** None declared

### Acknowledgement:

We are greatly indebted to directors and staff of Cosmopolitan Hospital for helping and allowing us to publish this material. We are thankful to Cosmopolitan Educational and Research Foundation for providing us with the Material for researching this article. We are also thankful to Mr. M.Vijayachandran for his help in preparing the manuscript.

**Cite this article as:** M Sambasivan, P Sanal Kumar, Mahesh, Abeed Basheer. Asymptomatic Lipoma of Corpus Callosum – Computerised Tomographic Demonstration. Kerala Medical Journal. 2009 Dec 31;2(4):119-121

## REFERENCES

1. Kazner E, Stochdorph O, Wende S, Grumme T. Intracranial lipoma. Diagnostic and therapeutic considerations. J Neurosurg. 1980 Feb;52(2):234–45.
2. Rokintansky C. Lehr der pathologischen Anatomic. Braumeller Vienna 1856; 22: 468. Quoted by Wallace D, Journal of Neurology, Neurology and Psychiatry 1976; 39: 1179-1185
3. Sambasivan M, Marthanda pillai. A Sanalkumar.P. Lipoma of Corpus callosum – case report with review of literature. Neurology India 1988; 36: 369 – 375.
4. New PJ, Scott WR. Computed tomography of the brain and orbit Williams and Wilkins. Baltimore 1975; 397.