

Coronavirus Pandemic

Atypical course of COVID-19 in patient with Bruton agammaglobulinemia

Ivana Milošević^{1,2}, Jaroslava Jovanović², Olja Stevanović^{1,2}

¹ Faculty of Medicine, University of Belgrade, Serbia

² Clinic for Infectious and Tropical Diseases, Clinical Center of Serbia, Belgrade, Serbia

Abstract

We present atypical course of the novel coronavirus disease (COVID-19) in 34-year man with Bruton agammaglobulinemia. The patient was successfully treated by a combination of available drugs, including convalescent plasma and interleukin-6 (IL-6) inhibitor.

Key words: COVID-19; agammaglobulinemia; convalescent plasma; IL-6 inhibitor.

J Infect Dev Ctries 2020; 14(11):1248-1251. doi:10.3855/jidc.13840

(Received 05 September 2020 – Accepted 30 September 2020)

Copyright © 2020 Milošević *et al.* This is an open-access article distributed under the Creative Commons Attribution License, which permits unrestricted use, distribution, and reproduction in any medium, provided the original work is properly cited.

Introduction

The novel coronavirus disease pandemic, caused by severe acute respiratory syndrome coronavirus 2 (SARS-CoV-2), represents a global public health issue. COVID-19 clinical spectrum varies from asymptomatic infection to interstitial pneumonia, and even acute respiratory distress syndrome (ARDS), often combined with multiple organ failure [1]. Currently, there are no registered drugs to treat COVID-19 disease and a vaccine is not available [2].

X-linked agammaglobulinemia (XLA), known also as Bruton agammaglobulinemia, is a primary immunodeficiency (PID) caused by mutations in the gene coding for Bruton tyrosine kinase (BTK). So far, there are no data indicating whether XLA patients are at higher risk of more severe COVID-19. We present a case of atypical COVID-19 in a 34-year-old male with Bruton agammaglobulinemia.

Case Report

The thirty-four-year-old male patient was referred from the Immunology Department of the Clinical Center “Bezanijska kosa” to the Clinic for Infectious and Tropical Diseases, Clinical Center of Serbia in Belgrade at the beginning of April 2020. He has been treated by regular gamma globulin substitution due to XLA diagnosed when he was 13 months old. He was diagnosed with bronchiectasis in the age of nine. The patient was on subcutaneous (SC) gamma globulin substitution from December 2018.

Five days before admission to the Immunology Department the patient developed a low-grade fever (37.4°C). A CT scan of the chest was performed immediately after admission and showed bilateral ground glass appearance throughout the lung with predominance in the peripheral lower lobes, along with enlarged bronchial lymph nodes. He was treated with moxifloxacin 400 mg intravenously (IV) daily. After SARS-CoV-2 was confirmed by RT-PCR (Abbott RealTime SARS-CoV-2, Abbott Molecular Inc, Des Plaines, IL 60018) from nasopharyngeal exudates, he was referred to the Clinic for Infectious and Tropical Diseases.

At admission, his temperature was 39°C, blood pressure 105/70 mm Hg, heart rate of 101 beats per minute, respiratory rate of 18 per minute, and oxygen saturation of 97% on room air. Physical exam revealed discrete bilateral crackles on auscultation of the lungs, but was unremarkable otherwise. Initial laboratory analysis showed lymphopenia (440×10^9 ly/L) and elevated non-specific inflammation parameters: erythrocyte sedimentation rate (ESR 84), C-reactive protein (CRP 205.8 mg/L), fibrinogen (5 g/L), interleukin-6 (IL-6 112) and ferritin (493.2). Immunoglobulin-G (IgG) was low (5.67 g/l), while immunoglobulin A and M (IgA and IgM) were below detection limit. Total number of lymphocytes rose to normal values after seven days.

The patient received 30 g intravenous immunoglobulin (IVIG), chloroquine phosphate (500 mg/12 h, 7 days, orally), vancomycin (1g/12 h, 14 days,

IV), imipenem/cilastatin (1g/6 h, 14 days, IV), levofloxacin (750mg/24h, 14 days, IV) ascorbic acid (1000mg/12h, IV), nadroparin (0.4 ml/24h SC). On day 3, he became hypoxic (oxygen saturation was 91%, pO₂ 8.96 kPa) and complained of dyspnea, along with further increase in nonspecific inflammatory parameters and low IgG (4.65 g/l), in spite IgG substitution. Therefore, he received oxygen 3 l/min on nasal cannula, IVIG 30 g (400mg/kg for 5 days, then once weekly), and two doses of tocilizumab (400mg/12h). CT scan of the chest showed ground-glass opacification (GGO) and subpleural consolidation, along with bronchiectasis, pleural effusions (23mm and 20mm) and mediastinal lymphadenopathy (16 mm and 11 mm) (Figure 1A). In next few days, there was improvement of non-specific inflammation parameters and oxygen saturation (96% on room air), but fever persisted. Antimicrobial therapy was aimed against possible nosocomial pathogens: tigecyclin (100 mg loading dose, followed with 50mg/12h, IV), meropenem (1g/8h, IV). Repeated nasopharyngeal swabs tested positive for SARS-CoV-2. All blood cultures were negative. On day 10, patient received COVID-19 convalescent plasma (0.5 ml/kg in two doses, 12 hours apart) with methylprednisolone 60 mg IV (with tapering on an every-other-day basis). During fourth week of treatment, CT scan revealed complete resolution of consolidation and pleural effusions, biochemical analyses were within normal ranges (Figure 1B). Since SARS-CoV-2 PCR remained positive, he has to stay in hospital according to National guidelines. Antimicrobial treatment and oxygen supplementation were not required.

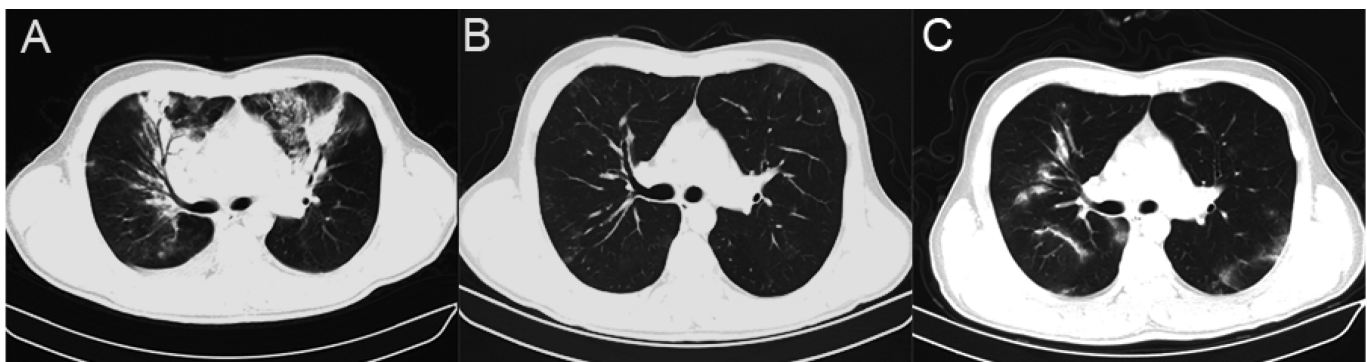
During the fifth week of hospitalization, patient developed second peak of fever (up to 38.5°C), and elevated non-specific inflammation parameters and CT scan confirmed pneumonia. New CT scan showed diffuse GGO with subpleural consolidation, bronchiectasis with fibrosis (Figure 1C). Antimicrobial

drugs were reintroduced: azithromycin (500 mg daily, 3 days, IV), cefepim (2g/12h, 14 days, IV), linezolid (600 mg/12h, IV), caspofungin (75 mg on first day, then 50 mg daily). Anti SARS CoV-2 IgG antibodies were undetectable (2019-nCoV IgG/IgM Detection Kit (Colloidal Gold Based), Vazyme Medical Technology Co, Nanjing, China), so he received COVID-19 convalescent plasma (0.5 ml/kg in two doses, 12 hours apart) with methylprednisolone 40 mg IV, again. He became SARS CoV-2 RT-PCR negative, five days after transfusion. Anti SARS CoV-2 IgG antibodies became undetectable seven days after transfusion. Fever persisted for next ten days, therefore infections by other respiratory pathogens (Coronavirus HKU1, NL63, 229E and OC43, Adenovirus, Human Metapneumovirus, Human Rhinovirus, Respiratory Syncytial Virus, Parainfluenza virus 1, 2, 3 and 4, Influenza A/H1, A/H3, A/H1-2009 and B, Bordetella pertussis, Chlamydia pneumonia and Mycoplasma pneumoniae) were excluded, as well (The BioFire® FilmArray® Respiratory 2.0 plus Panel, BioFire Diagnostics, Salt Lake City, Utah 84108). All blood cultures were negative. Other diagnostic tests were also negative (HBsAg, HCV RNK, HIV RNK, BAB, ACE, chitotriosidase, autoantibodies, tumor markers). Lymphoproliferative disease was excluded by bone biopsy. Whole body PET/CT scan revealed increased metabolism in the lung parenchyma and mediastinal lymph nodes, suggesting inflammatory etiology. Finally, eight weeks after admission, patient remarkably recovered. He was discharged in good health with normal inflammation parameters.

Discussion

The outbreak and global spread of COVID-19 rapidly became devastating worldwide pandemic at the beginning of 2020. SARS-CoV-2 has attracted great concern and scientific attention due to a lack of prior immunity, specific treatment and vaccine. Severe

Figure 1. Chest Computed Tomography; A: During first pneumonia; B: During recovery; C: During second pneumonia.



COVID-19 with development of ARDS is expected mostly among elders and men. Several comorbidities have been recognized as risk factors that greatly influence the prognosis, such as diabetes, hypertension, chronic respiratory disease, cancer and cardiovascular disease [3]. Likewise, a significant number of COVID-19 is expected among patients with PID, since they are prone to respiratory infections. Surprisingly, only a few papers dealing with COVID-19 in this particular population have been published, without conclusion whether XLA predisposes to severe COVID-19 or not [4].

Bruton agammaglobulinemia (XLA) is a consequence of BTK mutations. BTK is necessary for the maturation of pre-B cells to differentiating mature B cells. Although patients with XLA have increased susceptibility to encapsulated pyogenic bacteria, respiratory virus may be a risk for them as well. It has been considered that introduction of IV IgG regimen had eliminated the occurrence of unusual viral manifestations [5].

According to published data, COVID-19 is mostly a mild disease in patients with XLA. There are no reports of severe COVID requiring intensive care management in these patients, so far. Soresina *et al.* reported two cases of COVID in XLA patients who developed pneumonia, but recovered without necessity of mechanical ventilation [6]. Quinti *et al.* found that COVID-19 has short duration and favorable outcome in patients with XLA. They emphasize that these patients do not require treatment with IL-6-receptor inhibitor [7]. In contrast, tocilizumab treatment was necessary in presented case, not only because IL-6 level was high, but also because of persistent fever and clinical deterioration of the patient.

BTK is also expressed in myeloid cells and therefore involved in production of inflammatory cytokines, including TNF- α and IL-6. Italian authors speculate that lack of BTK in XLA patients could have protective role in preventing life-threatening inflammation known as “cytokine storm” [6-8]. These observations suggest that B-cells are important, but not crucial for recovering, since these patients lack gamma globulins. On contrary, there are many studies promoting use of convalescent plasma in patients with COVID. It has been shown that convalescent plasma transfusion leads to rapid increase in lymphocyte counts, decrease in serum CRP levels, and a notable remission of lung lesions in CT [9]. Mira *et al.* demonstrated prompt recovery of patients with XLA after convalescent plasma transfusion [10]. The presented patient has received convalescent plasma

transfusion twice, during both peaks of the disease. It is interesting that patient became anti-SARS CoV-2 IgG negative soon after transfusion. Unfortunately, quantification of anti-SARS CoV-2 IgG antibody titers was not possible. In addition, IV Ig substitution was at higher dosage than prior to COVID-19 (30 g vs. 20 g), in order to keep IgG above 10 g/l and try to achieve an immunomodulatory effect, if possible. Some studies propose that early initiation of IV Ig could improve the COVID-19 outcome [11].

One of the most interesting aspects of the case was “second peak” of disease. Since the patient tested SARS CoV-2 positive for more than 5 weeks, the second peak of disease was considered to be a “relapse” of COVID-19. After initial recovery he developed pneumonia, with an increase in inflammatory parameters (SE, CRP, IL-6). It has been shown that person recovered from COVID-19 may maintain low levels of virus for up to 3 months after diagnosis [12]. The lack of neutralizing antibodies could cause relapse of infection under these circumstances [6]. Although lymphopenia lasted just seven days, the authors believe that the analysis of the peripheral lymphocytes subsets by flow cytometry could provide additional information, but unfortunately it was not available.

Although this is an isolated case of severe COVID-19 in a patient with XLA, the authors considered it important given the extent of the SARS-CoV-2 pandemic and how vulnerable the XLA population is. Further analysis of COVID-19 in XLA patients is necessary, as the use of convalescent plasma in this particular population.

References

1. Miller R, Englund K (2020) Clinical presentation and course of COVID-19. *Cleve Clin J Med* 87: 384–388.
2. Phadke M, Saunik S (2020) COVID-19 treatment by repurposing drugs until the vaccine is in sight. *Drug Dev Res* 81: 541–543.
3. Zheng Z, Peng F, Xu B, Zhao J, Liu H, Peng J, Li Q, Jiang C, Zhou Y, Liu S, Ye C, Zhang P, Xing Y, Guo H, Tang W (2020) Risk factors of critical and mortal COVID-19 cases: A systematic literature review and meta-analysis. *J Infect* 81: e16–e25.
4. Babaha F, Rezaei N (2020) Primary Immunodeficiency Diseases in COVID-19 Pandemic: A Predisposing or Protective Factor? *Am J Med Sci* S0002-9629(20)30339-6.
5. Sanna PP, Burton DR (2000) Role of antibodies in controlling viral disease: lessons from experiments of nature and gene knockouts. *J Virol* 74: 9813–9817.
6. Soresina A, Moratto D, Chiarini M, Paolillo C, Baresi G, Foca E, Bezzi M, Baronio B, Giacomelli M, Badolato R (2020) Two X-linked agammaglobulinemia patients develop pneumonia as COVID-19 manifestation but recover. *Pediatr Allergy Immunol* 31: 565-569.

7. Quinti I, Lougaris V, Milito C, Cinetto F, Pecoraro A, Mezzaroma I, Mastroianni CM, Turriziani O, Bondioni MP, Filippini M, Soresina A, Spadaro G, Agostini C, Carsetti R, Plebani A (2020) A possible role for B cells in COVID-19? Lesson from patients with agammaglobulinemia. *J Allergy Clin Immunol* 146: 211–213.
8. Cunningham-Rundles C (2012) Human B cell defects in perspective. *Immunol Res* 54: 227–232.
9. Psaltopoulou T, Serghianis TN, Pappa V, Politou M, Terpos E, Tsiodras S, Pavlakis GN, Dimopoulos MA (2020) The Emerging Role of Convalescent Plasma in the Treatment of COVID-19. *Hemasphere* 4: e409.
10. Mira E, Yarce OA, Ortega C, Fernandez S, Pascual NM, Gomez C, Alvarez MA, Molina IJ, Lama R, Santamaria M (2020) Rapid recovery of a SARS-CoV-2-infected X-linked agammaglobulinemia patient after infusion of COVID-19 convalescent plasma. *J Allergy Clin Immunol Pract*: 2793-2795.
11. Liu X, Cao W, Li T (2020) High-Dose Intravenous Immunoglobulins in the Treatment of Severe Acute Viral Pneumonia: The Known Mechanisms and Clinical Effects. *Front Immunol* 11: 1660.
12. Centre for Disease Control and Prevention (2020) Duration of Isolation and Precautions for Adults with COVID-19. Available: <https://www.cdc.gov/coronavirus/2019-ncov/hcp/duration-isolation.html>. Atlanta. Accessed 31 August 2020.

Corresponding author

Olja Stevanović, MD

Clinic for Infectious and Tropical Diseases, Clinical Centre of Serbia, Faculty of Medicine, University of Belgrade, Bulevar oslobođena 16, 11000 Beograd

Mobile: +381 63 350708

Work: + 381 11 2684071

E-mail: oljastevanovic2020@gmail.com**Conflict of interests:** No conflict of interests is declared.