

REVIEWS

Atypical Lipomatous Tumor/Well Differentiated Liposarcoma: a Borderline Malignancy Tumor

Cornelia Nitipir^{1,2}, Florin Andrei³, Dragos Zamfirescu⁴, Florina Vasilescu⁵, Dana Terzea⁵, Irina Radu¹, Maria Alexandra Barbu¹, Bogdan Popescu¹

Abstract

Controversy exists with regard to the nomenclature, treatment and outcome of a group of well-differentiated lipomatous tumors sometimes labelled as atypical lipomatous tumors. For elimination of inadequate or excessive treatment it has been advocated that the term well-differentiated liposarcomas be retained for retroperitoneal/mediastinal tumors and atypical lipomatous tumors for the rest of the sites. The most important prognostic factor for ALT/WD liposarcoma is anatomic location, overall mortality ranging from 0% for ALT of the extremities to more than 80% for WD liposarcomas occurring in the retroperitoneum if the patients are followed up for 10-20 years. Primary treatment of ALT/WD liposarcoma is represented by a complete, preferably wide-margin surgical resection. The role of radiation therapy for atypical lipomatous tumors/well-differentiated liposarcomas is still unclear. Despite the side effects of postoperative radiation therapy it has been shown that in patients with positive surgical margins postoperative RT in doses over 64Gy, improves local control.

Keywords: atypical lipomatous tumor, well differentiated liposarcoma, positive margins

Rezumat

Există multiple controverse în literatura de specialitate în ceea ce privește nomenclatura, diagnosticul și tratamentul tumorilor lipomatoase bine diferențiate, uneori denumite și tumori lipomatoase atipice. Pentru a preveni tratamentul excesiv, s-a decis utilizarea termenilor de „liposarcom bine diferențiat” pentru tumorile retroperitoneale și pentru cele mediastinale și „tumori lipomatoase atipice” pentru restul localizărilor. Cel mai important factor de prognostic pentru aceste tipuri de tumori rămâne așadar localizarea lor, mortalitatea variind de la 0% pentru tumori lipomatoase atipice, până la 80% pentru liposarcoamele bine diferențiate din retroperitoneu, pentru pacienții urmăriți pe o perioadă îndelungată de 10-20 ani. Tratamentul inițial reprezintă rezecția chirurgicală integrală, cu margini libere. Rolul radioterapiei pentru această patologie rămâne neclar, îmbunătățind controlul local în cazurile în care există margini pozitive post chirurgicale.

Cuvinte cheie: tumoră atipică lipomatoasă, liposarcom bine diferențiat, margini pozitive

¹ Department of Medical Oncology, "Elias" Emergency Clinical Hospital, Bucharest, Romania

² "Carol Davila" University of Medicine and Pharmacy, Bucharest, Romania

³ Department of Pathology, "Elias" Emergency Clinical Hospital, Bucharest, Romania

⁴ Department of Plastic Surgery, "Zetta" Clinic, Bucharest, Romania

⁵ Department of Pathology, "Monza" Hospital, Bucharest, Romania

Corresponding author:

Maria Alexandra Barbu

Department of Medical Oncology, "Elias" Emergency Clinical Hospital, 17th Marasti Boulevard, 1st District, Bucharest, Romania.

E-mail: m.barbu86@gmail.com

INTRODUCTION

Adipocytic tumors represent the largest single group of mesenchymal tumors, due to the high prevalence of lipomas and angioliipomas. Liposarcomas are histologically divided into five subtypes: myxoid, pleomorphic, dedifferentiated, round cell and atypical lipomatous tumor (well-differentiated liposarcoma)¹. Atypical lipomatous tumor (ALT) is the most common histological subgroup, they account for 40% to 45% of all liposarcomas². Well-differentiated (WD) liposarcomas are locally aggressive but incapable of metastasis. Approximately 75% develop in the deep soft tissue of the limbs, followed by 20% in the retroperitoneum and a much smaller percentage in the inguinal region and the mediastinum³. They are usually diagnosed after the fifth decade of life, with a slight male predominance reported⁴. Atypical lipomatous tumor is an intermediate (locally aggressive) neoplasm composed either entirely or in part of a mature adipocytic proliferation showing significant variation in cell size, atypical stromal cells and a limited number of scattered monovacuolated or multivacuolated lipoblasts.

The fact that WD liposarcoma shows no potential for metastasis unless it undergoes dedifferentiation led to the introduction of terms such as atypical lipomatous tumor, particularly for lesions arising at surgically amenable locations. Because a wide excision in this locations should usually be curative the designation `sarcoma` is not justified. Atypical lipomatous tumor and WD liposarcoma are synonyms describing lesions which are identical morphologically, karyotypically and in

terms of biologic behavior. However when the tumor is localized in the retroperitoneum or the mediastinum, it is often impossible to obtain a wide surgical excision and, in such cases, local recurrence is almost inevitable, hence, at this sites, the term WD liposarcoma can be justified. Therefore, it has been advocated that the term well-differentiated liposarcomas be retained for retroperitoneal/mediastinal tumors and atypical lipomatous tumors for the rest³.

Macroscopically ALT/WD liposarcoma consists usually of a large, well-circumscribed mass. Colour varies from yellow to white, depending on the proportion of adipocytic, fibrous or myxoid areas. Retroperitoneal lesions are often asymptomatic until the tumor has exceeded 20 cm in diameter.

HISTOPATHOLOGY AND GENETICS

ALT/WD liposarcoma can be subdivided morphologically into four main subtypes: adipocytic (lipoma-like), sclerosing, inflammatory and spindle cell⁵. Tumors are often a mix of these variants. Adipocytic liposarcoma, unlike typical lipomas, has a variable cell size. We have focal nuclear atypia and hiperchromasia present. The number of lipoblasts varies. It is believed that lipoblasts represent the hallmark of any liposarcoma subtype, however it is important to know that the mere presence of lipoblast does not make a diagnosis of liposarcoma⁶. Sclerosing liposarcoma ranks second in frequency among the group of ALT/WD liposarcoma. Most commonly locations are retroperitoneal or paratesticular. There is a fibrillary stroma with scattered lipoblasts

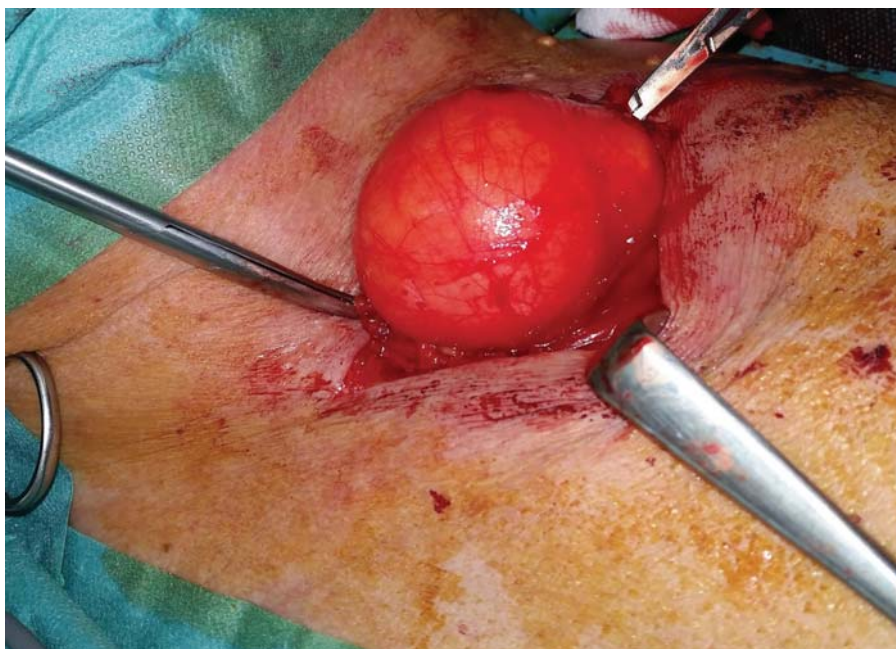


Figure 1. ALT/WD liposarcoma (personal archive Dr. Dragos Zamfirescu).

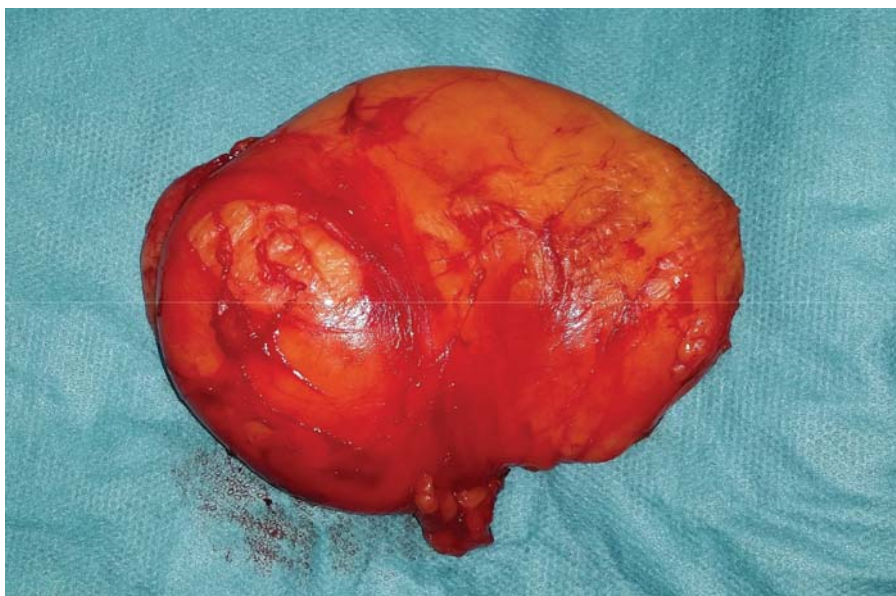

Figure 2. ALT/WD liposarcoma (personal archive Dr. Dragos Zamfirescu).

and hyperchromatic stromal cells. Lipogenic areas may be hard to find in a small tissue sample⁶. Inflammatory liposarcoma represents a rare variant of ALT/WD liposarcoma, occurring most often in the retroperitoneum. The differential diagnosis in such cases is mainly with non adipocytic lesions such as inflammatory myofibroblastic tumor, Castleman Disease and Hodgkin or non-Hodgkin lymphomas⁶. The spindle cell variant of ALT/WD liposarcoma is composed of a bland neural-like spindle cell proliferation set in a fibrous and/or myxoid background⁶.

Immunohistochemistry plays a minor role in the differential diagnosis of ALT/WD liposarcoma. Adipocytic cells usually exhibit S-100 protein immunoreactivity (Figure 3). HMB-45 immunonegativity is useful in the differential diagnosis with angiomyolipoma which may mimic liposarcoma. Also detection of CDK4

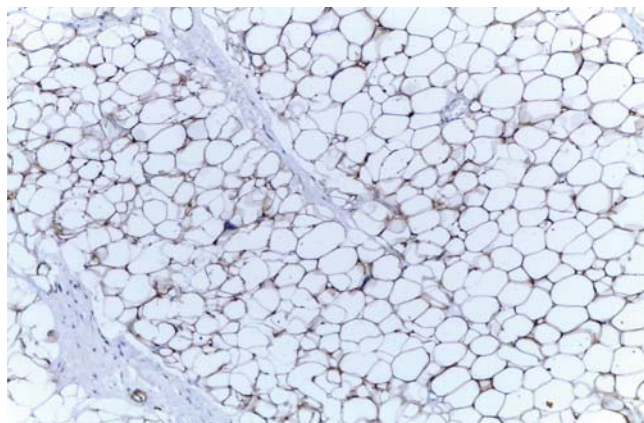


Figure 3. ALT/WD liposarcoma positive S-100 protein (personal archive Dr. Dana Terzea).

and MDM2 has been shown to be a sensitive and specific means of identifying ALT/WD liposarcoma from other benign lipomatous tumors (Figure 4)⁷.

The defining genetic features of ALT/WD liposarcoma cells are supernumerary circular and giant rod chromosomes (Image 5, 6). These rings and giant markers contain amplification of the 12q14-15 region, including the MDM2, CDK4, HMGA2, SAS and GL1 genes. The supernumerary ring and giant marker chromosomes have been observed as the sole change or concomitant with a few other numerical or structural abnormalities⁸. Cells containing rings or giant markers can be observed in the same tumor sample. Random or aleatory telomeric associations may give a

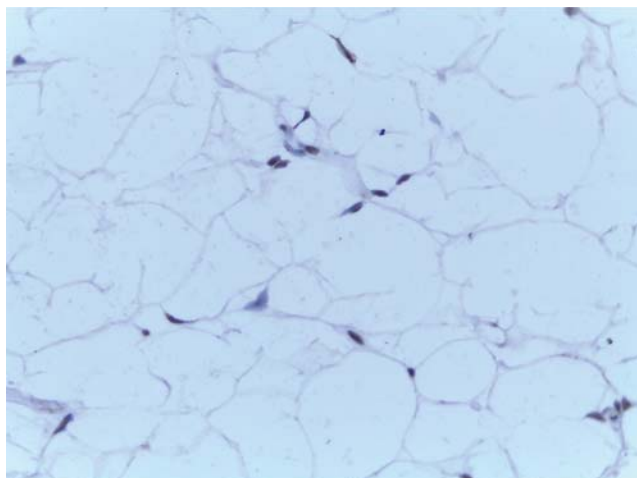


Figure 4. ALT/WD liposarcoma positive MDM2 (personal archive Dr. Dana Terzea).

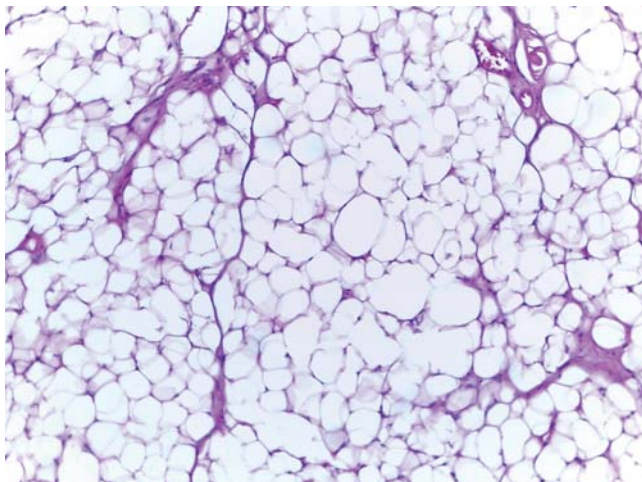


Figure 5. ALT/WD liposarcoma HE 10x (personal archive Dr. Florina Vasilescu).

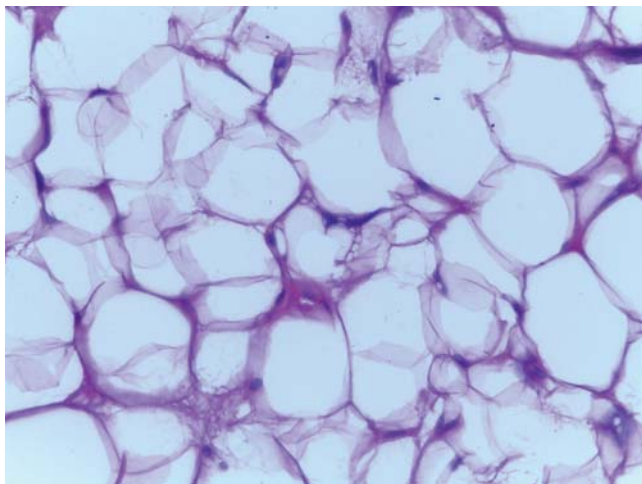


Figure 6. ALT/WD liposarcoma HE 10x (personal archive Dr. Florina Vasilescu).

false impression of complexity to ALT/WD liposarcoma karyotypes⁹.

PROGNOSTIC

The most important prognostic factor for ALT/WD liposarcoma is anatomic location. Lesions located in surgically amenable locations do not recur following complete excision with a clear margin. Tumors occurring in deep anatomic sites such as retroperitoneum, spermatic cord or mediastinum if not completely excised, tend to recur repeatedly to the extent of threatening patient's life as a result of uncontrolled local effects or of dedifferentiation. The risk of dedifferentiation varies according to site and lesional duration and is approximately 20% in the retroperitoneum and less than 2% in the limbs. Overall mortality ranges from 0% for ALT of

the extremities to more than 80% for WD liposarcomas occurring in the retroperitoneum if the patients are followed up for 10-20 years¹⁰.

TREATMENT

Primary treatment of ALT/WD liposarcoma is represented by a complete, wide surgical resection of the primary tumor (total en bloc excision of the primary tumor without cutting into tumor tissue and having an adequate margin of normal tissue completely surrounding the tumor).

The resection should take place through tissues outside the tumor pseudocapsule, if one exists, through apparently normal uninvolved tissue. The rationale for wide surgical excision of atypical lipomatous tumors is the prevention of recurrence and dedifferentiation. A statistically significant correlation between positive surgical margins and risk of recurrence for atypical lipomatous tumors/well-differentiated liposarcomas has been reported¹¹. Because it is often difficult to obtain wide margins due to the large tumor size and proximity to major nerves and vessels, marginal excision can be justified, however intralesional surgery should be avoided¹². The optimal thickness of the uninvolved tissue is debatable (traditionally 1 cm margins were recommended), and the assessment of the margin is difficult at best when the specimen leaves the wound due to the elasticity of the tissues. One cm margins seldom occur in reality, especially around neurovascular structures, and it is generally accepted that the type of tissue is important: thinner (1 to 2 mm) margins of fascia are likely adequate, whereas wider margins that consist of fat or muscle are suggested. Periosteal stripping should be avoided, if possible, because it may increase the risk of a later radiation-related pathologic fracture, particularly of the femur¹³. Major nerves can often be preserved if they are carefully resected from the tumor, leaving the nerve sheath as a margin, as it is rare that a nerve is actually invaded by tumor, but if this is the case and for neurogenic tumors arising in the nerve itself, it is necessary to resect the nerve in continuity with the tumor. At times amputation may be the only reasonable alternative, or be necessary if there is a major complication.

In the case of well-differentiated liposarcomas localized in the retroperitoneum surgical resection has traditionally been the only potentially curative treatment. The ability to perform a complete surgical resection at the time of initial presentation is the most important prognostic factor for survival¹⁴⁻¹⁷. The usual reasons for unresectability are extensive vascular invol-

vement or the presence of multiple peritoneal implants. The primary oncologic goal is R0 resection. However, the large size of most retroperitoneal tumors, coupled with the inability to obtain wide margins due to anatomic constraints, makes this goal difficult to achieve. In clinical practice, many resections are grossly complete but with microscopically positive margins (R1 resection), termed a “complete resection” in many literature reports^{18,19}. In a review of four large series of patients with retroperitoneum liposarcomas from institutions with extensive experience in management of this disease^{14,15,20}, complete resection rates were between 50 and 67 percent²¹. In the largest of these series, the “complete” (R0 plus R1) and R0 resection rates were 80 and 58 percent, respectively. Microscopically positive margins increase the risk for local recurrence^{19,22,23}, but whether they adversely influence survival is less clear. In some series^{18,22,23}, patients who have an R1 resection have higher rates of distant recurrence and inferior survival as compared with those undergoing R0 (microscopically-negative) resections, but others have failed to show a relationship between microscopically positive margins and inferior survival^{17,24}. Following an R1 or R2 resection, resection of the tumor bed is preferred, if feasible, but this is often not possible as the residual microscopic or macroscopic tumor frequently abuts structures or organs that cannot be easily or safely resected. For these patients and for those who refuse further surgery, postoperative RT can provide local tumor control^{25,26}.

The role of radiation therapy for atypical lipomatous tumors/well-differentiated liposarcomas is unclear^{27,28}. Some consider that adjuvant radiation therapy can reduce the risk of local recurrence²⁷, but others are concerned that this may potentiate dedifferentiation to a higher grade in case of recurrence²⁸.

The NCCN Guidelines states that postoperative radiotherapy is associated with higher rates of long-term treatment related side effects²⁹. In one retrospective analysis, although there was no evidence for differences in disease outcome associated with the use of pre or postoperative RT, there was a slight increase in late treatment-related side effects with postoperative RT, mainly due to the higher doses used³⁰. Despite the side effects of postoperative RT it has been shown that in patients with positive surgical margins postoperative RT in doses over 64Gy, improves local control³¹. For patients receiving 50 Gy neoadjuvant irradiation and who have positive surgical margins a postoperative RT boost of 16Gy (up to 26 Gy for gross residual disease) has been used after the wound has healed (but still within 8 weeks after tumor resection). However, the results of a retrospective analysis showed that RT

boost did not provide any advantage in preventing local recurrence³².

RECURRENT OR METASTATIC DISEASE

The most significant predictor of outcome following a local recurrence is the resectability of the recurrent disease³³. Reresection should be considered for an isolated, locally recurrent tumor; approximately 60 percent of such tumors are potentially resectable³⁴. However, with each local recurrence, there is a greater need for more complex en bloc resections, and tumor resectability dramatically diminishes with each reoperation. In one series, resectability rates were 80 percent for primary tumors, compared with 57, 33, and 14 percent for first, second, and third recurrences, respectively¹⁵. Whether there is benefit from palliative “debulking” surgery in patients who have unresectable, locally recurrent disease at the time of exploration is unclear.

The role of chemotherapy in the treatment of liposarcomas remains controversial, and is best addressed on a case-by-case basis. The best chemotherapy regimen has not been established for atypical lipomatous tumors/well-differentiated liposarcomas. Higher response rates are achieved by doxorubicin and ifosfamide containing combinations in liposarcomas but well-differentiated liposarcomas demonstrated a weaker response rate compared to other histological subtypes³⁵.

Given the limited efficacy of conventional cytotoxic chemotherapy, liposarcomas represents a fertile ground for the field of drug development. Trabectedin was approved in November 2015 in the US for unresectable or metastatic liposarcoma in patients who have received a prior anthracycline-containing regimen. It is an alkylating drug that binds guanine residues in the minor groove of DNA. Approval was based on a phase 3 trial that showed a statistically significant improvement in progression-free survival compared with dacarbazine (4.2 months vs 1.5 months). No improvement in overall survival was observed³⁶. In January 2016, Eribulin was approved by the *US Food and Drug Administration* (FDA) for unresectable or metastatic liposarcoma in patients who received a prior anthracycline-containing regimen. Eribulin inhibits microtubules via a mechanism that is distinct from other microtubule-targeting agents, such as taxanes. The FDA approval is based on the results from the subgroup of 143 patients with liposarcoma. In this subgroup, the results showed a 7-month improvement in survival (15.6 months with eribulin compared with 8.4 months with dacarbazine)³⁷. In a phase II trial with palbociclib in patients

with advanced CDK4 - amplified well-differentiated or dedifferentiated liposarcoma (WD-DDLS) an improvement in progression free survival was observed³⁸. It is a selective inhibitor of cyclin-dependent kinases CDK4 and CDK6 that inhibits growth and induces senescence in cell lines.

CONCLUSION

Soft tissue sarcomas are a rare and heterogeneous group of tumors of mesenchymal origin, which includes more than 50 different histologic subtypes. Pathologic diagnosis is based on histologic morphology, immunohistochemistry, and sometimes, molecular testing. Atypical lipomatous tumor and well-differentiated liposarcoma are synonyms describing lesions which are identical morphologically, karyotypically and in terms of biologic behavior.

The most important prognostic factor for ALT/WD liposarcoma is anatomic location. Lesions located in surgically amenable locations do not recur following complete excision with a clear margin. Tumors occurring in deep anatomic sites such as retroperitoneum, spermatic cord or mediastinum tend to recur repea-

tedly to the extent of threatening patient's life as a result of uncontrolled local effects or of dedifferentiation. Surgical resection of the primary tumor is the essential component of treatment for virtually all patients. The guiding principle is total en bloc excision of the primary tumor without cutting into tumor tissue.

Because of their rarity and the frequent need for multimodality treatment, evaluation and management of liposarcomas should ideally be carried out in a center with expertise in the treatment of sarcomas, including surgical, orthopedic, medical, pediatric, and radiation oncology. The benefit of adjuvant chemotherapy following optimal local therapy remains uncertain. This approach cannot be adopted as the standard of practice for all liposarcomas. However, patients with high-risk tumors should be considered for clinical trials of adjuvant therapy. Where commercially available, trabectedin is recommend for the treatment for liposarcomas that have failed standard anthracycline or ifosfamide-based therapy. For patients with unresectable or metastatic liposarcoma who were previously treated with an anthracycline-containing regimen, eribulin is another treatment alternative.

References

1. Dei Tos AP, Pedeutour F. Atypical lipomatous tumor/well-differentiated liposarcoma; in Fletcher CDM, Unni K, Mertens F (eds): Pathology and Genetics of Tumours of Soft Tissue and Bone, WHO Classification of Tumours, Lyon, IARC Press, 2002, pp 35-46
2. Laurino L, Furlanetto A, Orvieto E, Dei Tos AP. Well-differentiated liposarcoma (atypical lipomatous tumors). *Semin Diagn Pathol*. 2001; 18(4):258-262
3. Weiss SW, Rao VK: Well-differentiated liposarcoma (atypical lipoma) of deep soft tissue of the extremities, retroperitoneum, and miscellaneous sites. A follow-up study of 92 cases with analysis of the incidence of 'dedifferentiation'. *Am J Surg Pathol* 1992;16:1051-1058
4. Billing V, Mertens F, Domanski HA, Rydholm A. Deep-seated ordinary and atypical lipomas: histopathology, cytogenetics, clinical features, and outcome in 215 tumours of the extremity and trunk wall. *J Bone Joint Surg Br*. 2008; 90(7):929-933
5. D. A. Kooby, C. R. Antonescu, M. F. Brennan, and S. Singer, "Atypical lipomatous tumor/well-differentiated liposarcoma of the extremity and trunk wall: importance of histological subtype with treatment recommendations," *Annals of Surgical Oncology*, vol. 11, no. 1, pp. 78-84, 2004
6. Evans HL. Atypical lipomatous tumor, its variants, and its combined forms: a study of 61 cases, with a minimum follow-up of 10 years. *Am J Surg Pathol*. 2007; 31(1):1-14
7. Binh MB, Sastre-Garau X, Guillou L, de Pinieux G, Terrier P, Lagacé R, Aurias A, Hostein I, Coindre JM: MDM2 and CDK4 immunostainings are useful adjuncts in diagnosing well-differentiated and dedifferentiated liposarcoma subtypes: a comparative analysis of 559 soft tissue neoplasms with genetic data. *Am J Surg Pathol* 2005;29:1340-1347
8. Mitelman Database of Chromosome Aberrations in Cancer (2002). <http://cgapnci.nih.gov/Chromosomes/Mitelman>
9. Mandahl N, Mertens F, Willén H, Rydholm A, Kreicbergs A, Mitelman F(1998). Nonrandom pattern of telomeric associations in atypical lipomatous tumors with ring and giant marker chromosomes. *Cancer Genet Cytogenet* 103: 25-34.
10. Weiss SW, Rao VK (1992). Well-differentiated liposarcoma (atypical lipoma) of deep soft tissue of the extremities, retroperitoneum, and miscellaneous sites. A follow-up study of 92 cases with analysis of the incidence of „dedifferentiation". *Am J Surg Pathol* 16: 1051-1058
11. Rozental TD, Khoury LD, Donthineni-Rao R, Lackman RD. Atypical lipomatous masses of the extremities: outcome of surgical treatment. *Clin Orthop Relat Res*. 2002; (398):203-211
12. Serpell JW, Chen RY. Review of large deep lipomatous tumours. *ANZ J Surg*. 2007; 77(7):524-529
13. Gortzak Y, Lockwood GA, Mahendra A, et al. Prediction of pathologic fracture risk of the femur after combined modality treatment of soft tissue sarcoma of the thigh. *Cancer* 2010; 116:1553.
14. Stoeckle E, Coindre JM, Bonvalot S, et al. Prognostic factors in retroperitoneal sarcoma: a multivariate analysis of a series of 165 patients of the French Cancer Center Federation Sarcoma Group. *Cancer* 2001; 92:359.
15. Lewis JJ, Leung D, Woodruff JM, Brennan MF. Retroperitoneal soft-tissue sarcoma: analysis of 500 patients treated and followed at a single institution. *Ann Surg* 1998; 228:355.
16. Pham TH, Iqbal CW, Zarroug AE, et al. Retroperitoneal sarcomas in children: outcomes from an institution. *J Pediatr Surg* 2007; 42:829.

17. Hassan I, Park SZ, Donohue JH, et al. Operative management of primary retroperitoneal sarcomas: a reappraisal of an institutional experience. *Ann Surg* 2004; 239:244.
18. Anaya DA, Lev DC, Pollock RE. The role of surgical margin status in retroperitoneal sarcoma. *J Surg Oncol* 2008; 98:607.
19. Pierie JP, Betensky RA, Choudry U, et al. Outcomes in a series of 103 retroperitoneal sarcomas. *Eur J Surg Oncol* 2006; 32:1235.
20. Van Dalen T, Hoekstra HJ, van Geel AN, et al. Locoregional recurrence of retroperitoneal soft tissue sarcoma: second chance of cure for selected patients. *Eur J Surg Oncol* 2001; 27:564.
21. Mendenhall WM, Zlotecki RA, Hochwald SN, et al. Retroperitoneal soft tissue sarcoma. *Cancer* 2005; 104:669.
22. Lehnert T, Cardona S, Hinz U, et al. Primary and locally recurrent retroperitoneal soft-tissue sarcoma: local control and survival. *Eur J Surg Oncol* 2009; 35:986.
23. Stojadinovic A, Leung DH, Hoos A, et al. Analysis of the prognostic significance of microscopic margins in 2,084 localized primary adult soft tissue sarcomas. *Ann Surg* 2002; 235:424.
24. Zagars GK, Ballo MT, Pisters PW, et al. Surgical margins and resection in the management of patients with soft tissue sarcoma using conservative surgery and radiation therapy. *Cancer* 2003; 97:2544.
25. Raut CP, Pisters PW. Retroperitoneal sarcomas: Combined-modality treatment approaches. *J Surg Oncol* 2006; 94:81.
26. Delaney TF, Kepka L, Goldberg SI, et al. Radiation therapy for control of soft-tissue sarcomas resected with positive margins. *Int J Radiat Oncol Biol Phys* 2007; 67:1460.
27. Zagars GK, Goswitz MS, Pollack A. Liposarcoma: outcome and prognostic factors following conservation surgery and radiation therapy. *Int J Radiat Oncol Biol Phys*. 1996; 36(2):311–319
28. Sommerville SM, Patton JT, Luscombe JC, Mangham DC, Grimmer RJ. Clinical outcomes of deep atypical lipomas (well-differentiated lipoma-like liposarcomas) of the extremities. *ANZ J Surg*. 2005; 75(9):803–806
29. https://www.nccn.org/professionals/physician_gls/pdf/sarcoma.pdf (Accessed on november 20,2016)
30. Zagars GK, Ballo MT, Pisters PWT, et al. Preoperative vs. postoperative radiation therapy for soft tissue sarcoma: a retrospective comparative evaluation of disease outcome. *Int J Radiat Oncol Biol Phys* 2003;56:482-488
31. Delaney TF, Kepka L, Goldberg SI, et al. Radiation therapy for control of soft-tissue sarcomas resected with positive margins. *Int J Radiat Oncol Biol Phys* 2007;67:1460-1469
32. Al Yami A, Griffin AM, Ferguson PC, et al. Positive surgical margins in soft tissue sarcoma treated with preoperative radiation: is a postoperative boost necessary? *Int J Radiat Oncol Biol Phys* 2010;77:1191-1197
33. Gyorki DE, Brennan MF. Management of recurrent retroperitoneal sarcoma. *J Surg Oncol* 2014; 109:53.
34. Wang YN, Zhu WQ, Shen ZZ, et al. Treatment of locally recurrent soft tissue sarcomas of the retroperitoneum: report of 30 cases. *J Surg Oncol* 1994; 56:213.
35. Robin I. Jones, Cyril Fisher, Omar Al-Muderis, Ian R. Judson Differential sensitivity of liposarcoma subtypes to chemotherapy. *European Journal of Cancer* 41 2005, 2853-2860.
36. Schöffski P, Chawla S, Maki RG, et al. Eribulin versus dacarbazine in previously treated patients with advanced liposarcoma or leiomyosarcoma: a randomised, open-label, multicentre, phase 3 trial. *Lancet* 2016; 387:1629..
37. <http://www.fda.gov/NewsEvents/Newsroom/PressAnnouncements/ucm483714.htm> (Accessed on november 20, 2016).
38. Dickinson MA, Tap WD, Keohan ML, et al. Phase II trial of the CDK4 inhibitor PD0332991 in patients with advanced CDK4-amplified well-differentiated and dedifferentiated liposarcoma. *J Clin Oncol* 2013, 31-2024-2028.