



Audit of the efficacy and complications of cyanoacrylate glue embolisation to treat varicose veins in primary care

Isaac Weaver BSc;¹ Paul Weaver MBBS, Dip. Obst., FRNZCGP^{1,2}

¹0800VEINDR, 811 Heretaunga St., East Hastings 4122, New Zealand.

²Corresponding author. Email: paul.weaver@0800veindr.com

ABSTRACT

INTRODUCTION: Cyanoacrylate glue embolization (CAGE) is a non-surgical procedure that uses a proprietary medical adhesive, delivered endovenously to close truncal, varicose veins.

AIM: To describe CAGE administered by a New Zealand general practitioner (GP) in primary care.

METHODS: The procedures were performed by a single GP with a special interest and 19 years' clinical experience in procedural phlebology. The clinical records of 107 consecutive patients who underwent CAGE over a 2-year period were retrospectively reviewed. Some patients had bilateral disease and some had more than one truncal vein per leg treated. Data on 173 truncal veins were included in the audit. Clinical data, procedural details and postprocedural course were recorded and analysed for 71 females and 36 males.

RESULTS: In total, 173 truncal veins were treated. They included the anterior accessory saphenous vein, the great saphenous vein, the small (lesser) saphenous vein and the thigh extension with a range of clinical severity. The most commonly treated truncal vein was the great saphenous vein with an average truncal diameter of 8.8 mm (2.9 s.d.). Of the 173 treated truncal veins, two failed to seal with CAGE, but were sealed after adjuvant ultrasound-guided foam sclerotherapy treatment. Post CAGE, 14.5% of treated truncal veins developed a phlebitis.

DISCUSSION: This audit shows that varicose veins can be treated in general practice with high levels of anatomic efficacy and few adverse effects.

KEYWORDS: Clinical audit; VenasealTM; varicose veins; phlebitis; special interest; general practitioner

J PRIM HEALTH CARE

2019;11(3):249–258.

doi:10.1071/HC19001

Received 03 January 2019

Accepted 22 July 2019

Published 06 September 2019

Introduction

In the lower limbs, varicose veins are the result of chronic venous insufficiency. The venous or muscle pump opposes gravity and returns blood from the lower extremities to the heart (venous return). When the muscles contract, they constrict veins, increasing venous pressure and push blood towards the heart. The non-return valves ensure that the blood only moves in a cephalad direction. Chronic venous disease prevents valves fulfilling this role. Chronic venous insufficiency occurs in veins with weakened walls, increasing the size of the vein and preventing full closure of the valve

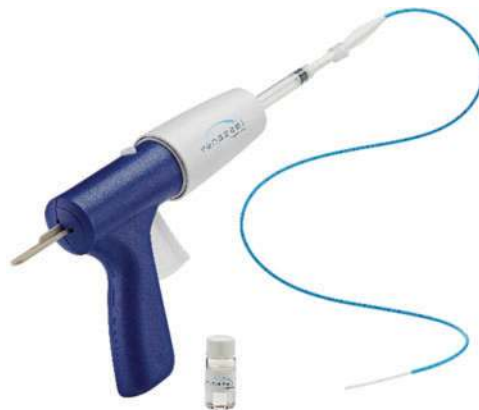leaflets.¹ Caudal flow, with gravity, allows blood to pool in the damaged vein leading to bulbous, enlarged and sometimes painful veins, commonly known as varicose veins. Untreated varicose veins may result in dermatological complications and superficial thrombophlebitis in affected limbs.² Chronic venous insufficiency has traditionally been treated surgically by high ligation, saphenous vein stripping and phlebectomy.³ However, over the last 20 years, there has been a trend towards less-invasive office-based, non-surgical procedures with equal efficacy and fewer complications than surgical options.⁴

Non-surgical modalities continue to evolve. Compression sclerotherapy and ultrasound-guided foam sclerotherapy have been followed by endovenous thermal ablation using laser or radio-frequency to generate heat inside the target vein.^{5,6} Now, sclerotherapy and endovenous treatments are often combined to achieve the best outcome. The resultant endothelial damage leads to fibrotic occlusion and ablation.⁷ Endovenous thermal ablation has at least the same efficacy as surgery, but with shorter recovery periods (functional recovery within 1–2 days vs. 7 days for surgery; normal activity within 7 days vs. 14+ days for surgery).⁴ Furthermore, endovenous thermal ablation removes the need for general anaesthesia and inpatient treatment, thereby lowering post-operative pain and financial cost.⁸ However, endovenous thermal ablation has a risk of sensory nerve damage and requires tumescent local anaesthesia (TLA) and compression stockings.⁹ TLA is large volume, low-strength local anaesthesia placed circumferentially around the saphenous trunk by injection into the saphenous sheath under ultrasound control, providing analgesia, insulation to prevent heat damage beyond the vein and compression to maintain good contact of the vein walls with the heat treatment catheter. Although TLA is effective, the multiple needle punctures required for its administration make it unpopular with some patients.

The Venaseal™ Closure System (Medtronic Inc., Minneapolis, MN, USA) was approved by the United States Food and Drug Administration in February 2015 and was introduced into New Zealand in October 2015. Other cyanoacrylate glue embolization (CAGE) systems are available such as Biolas VariClose® (FG Group, Ankara, Turkey),¹⁰ but they do not yet have enough published evidence to support their routine use. CAGE is available in New Zealand, in the form of the Venaseal™ Closure System, as shown in Figure 1. CAGE removes the need for TLA and use of compression stockings and reduces the risk of sensory nerve damage.^{11,12} It is an office-based procedure that uses a medical adhesive (*n*-butyl-2-cyanoacrylate (CA)) to seal the target truncal varicose vein, requiring only a small stab incision for insertion under local anaesthesia.¹¹

In our practice, all patients have an initial assessment with explanation and information regarding all possible treatments, their benefits and potential adverse

Figure 1. Venaseal™ closure system using *n*-butyl-2-cyanoacrylate glue.



effects and complications. Before treatment, patients are encouraged to ask questions and then complete a written consent form. A duplex ultrasound mapping scan is performed and recorded, to determine the functional venous anatomy of the deep and superficial systems. The varicose truncal vein is cannulated by using the Seldinger Technique, where ultrasound-guided venepuncture is made with a small (18- or 20-gauge) needle and a 'J' wire is threaded through that needle to guide a dilator and catheter-introduction cannula into the lumen of the vein. The Venaseal™ Closure System catheter is threaded through the introduction cannula to 5 cm below either the sapheno-femoral or sapheno-popliteal junction. Tip location is confirmed by ultrasound guidance before injection of CA glue through the catheter with the Venaseal™ gun. Then, 0.1 mL of CA is placed at 5 and again at 6 cm below the junction. Pressure is applied to the vein by ultrasound probe and free hand for 3 min until the glue has cured. Then, 0.1 mL of CA glue is injected at every 3 cm as the catheter is withdrawn caudally. At each injection, site pressure is applied for 30 seconds and the catheter is withdrawn another 3 cm. The final injection is at 5 cm from the exit point. The catheter is withdrawn and the skin is closed by steristrip and dry dressing. Post procedure instructions to the patient include walking for 30 min immediately after the procedure and then a minimum of 30 min walking daily. Analgesia is discussed and a contact number supplied for advice and emergencies.

If patients have significant tributary varicose veins leading from the truncal veins, they receive

adjuvant ultrasound-guided foam sclerotherapy to the tributaries either with the original CAGE procedure or 6–12 weeks later as a secondary procedure. They wear a class II compression stocking for 2 weeks. Standard follow-up visits are at 2 weeks and 4, 8 and 12 months' post procedure. Each follow-up visit includes a duplex ultrasound scan to ensure anatomic closure. Anatomic closure is defined as a loss of vein patency due to hyperechoic solid, cured CA glue and no blood flow. Areas of patency with blood flow are treated at subsequent visits with adjuvant ultrasound-guided foam sclerotherapy.

Phlebitis (inflammation of the treated truncal vein associated with erythema, itching, swelling, pain and tenderness) sometimes occurs with CAGE. Phlebitis associated with CAGE is more superficial than traditional phlebitis, self-limiting and may cause discomfort for 7–14 days post procedure.¹³ The Venaseal™ Closure System's good safety profile and high efficacy shows that CAGE offers an alternative to other options when treating superficial truncal vein incompetence.¹⁴

We aimed to audit the efficacy and safety of CAGE when administered by a GP with a special interest and extensive clinical experience in procedural phlebology. Medical audit is an annual requirement of the New Zealand Medical Council for all registered doctors. We wished to establish whether our CAGE procedures have similar efficacy and adverse events rates as are reported in the literature.^{9–13,15,16}

Methods

Data were collected from 0800 Vein Dr, a primary care vein clinic with branches in Hastings, Palmerston North and Auckland. We retrospectively reviewed the clinical records of 107 consecutive patients who underwent CAGE with the Venaseal™ Closure System between 11 November 2015 and 12 December 2017. Data on 173 truncal varicose veins were included in the audit. All patients had symptomatic varicose veins or aesthetic indications, assessed by clinical and duplex mapping ultrasound examination. Limbs were classified according to the CEAP (clinical, etiologic, anatomic, pathophysiologic) clinical classification^{17,18} and incompetence was defined as reflux of

>0.5 second during duplex mapping ultrasound examination.^{19,20} Truncal vein diameters were measured in mm just distal to the sapheno femoral or sapheno popliteal junctions.²¹ Clinical data, procedural details and post-procedural course were recorded and analysed for 71 females (average age 53 years) and 36 males (average age 52 years). Two case studies: a typical and an atypical patient, are included to demonstrate the results. Phlebitis in Venaseal™ Closure System-treated truncal veins was recorded as post Venaseal™ Closure System phlebitis.²² Thrombophlebitis associated with sclerotherapy in the tributaries was not included as this has a different aetiology.²³ The two were distinguished by clinical and duplex ultrasound examination to pinpoint the location of the inflammation in either the CAGE truncal vein or sclerosed tributaries for patients treated with adjuvant ultrasound-guided foam sclerotherapy.

Results

The audit included 173 treated veins: seven anterior accessory saphenous veins (AASV: average size 6.3 mm, standard deviation (s.d.) 1.9 mm, range 4.9–9.8 mm), 139 great saphenous veins (GSV: average size 8.8 mm, s.d. 2.9, range 3.4–21.4 mm), 26 small (lesser) saphenous veins (SSV: average size 6.4 mm, s.d. 1.7 mm, range 4.1–11.1 mm) and one thigh extension (TE: size = 5.4 mm). Most were GSVs with a C2 CEAP classification (Fig. 2), but overall, CEAP classifications ranged from C2 to C5.

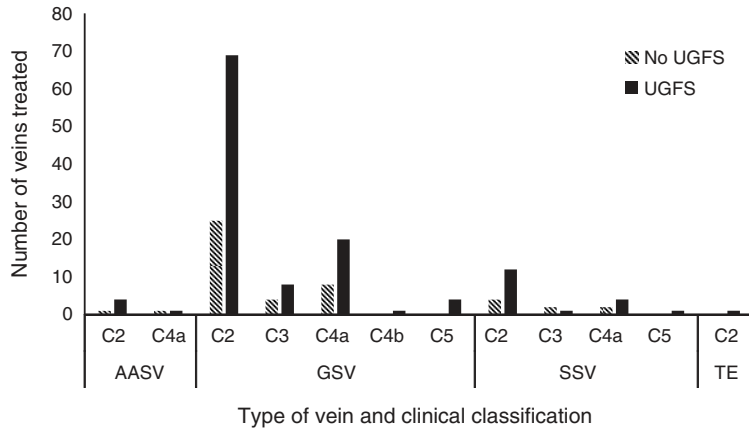
CAGE with Venaseal™ Closure System was used to treat truncal veins of sizes ranging from 3.4 to 21.4 mm. Most veins treated were GSVs with an average truncal diameter of 8.8 mm (2.9 s.d.) (Table 1). Of the 173 treated truncal veins, only two failed to seal with CAGE. Both these veins were sealed after adjuvant ultrasound-guided foam sclerotherapy treatment. One-fifth (21.0%) of patients and 14.5% of treated truncal veins developed a phlebitis post CAGE with the Venaseal™ Closure System. Figure 3 shows phlebitis events in different veins.

Case studies

Case study 1

A female aged 41 years presented with bilateral varicose veins noticeable since her first pregnancy

Figure 2. Number of different veins treated from each clinical, etiologic, anatomic and pathophysiologic (CEAP) Clinical Classification with or without adjuvant ultrasound-guided foam sclerotherapy (UGFS).



13 years prior. The patient complained of restless, heavy legs with pruritis and occasional mild swelling of the ankles. Her medical history was uneventful and she was a non-smoker. She was

uncertain about her family medical history, but she was on no medication and had no known allergies. Examination revealed bilateral varicose veins with both legs at C2 on the CEAP Classification. Figure 4 shows her veins on initial presentation. Duplex ultrasound mapping shown in Figure 5 revealed right GSV incompetence at 12.4 mm diameter and left SSV incompetence at 6.2 mm diameter.

CAGE was performed on both the right GSV and left SSV using the ‘Seldinger’ entry technique at the ankle, as marked on the duplex mapping scan (Fig. 5). CA glue was introduced by standard regime with manual compression and starting 5 cm below the sapheno-femoral and sapheno-popliteal junctions;⁹ 3.5 mL of CA glue was used in total for both veins. Ultrasound-guided foam sclerotherapy was performed on incompetent tributaries and incompetent inter-saphenous veins, as marked on the scan shown in Figure 5. The legs were placed in class II compression stockings (20–30 mmHg at the ankle) for 14 days continuously.

Table 1. Average diameter, standard deviation, minimum size and maximum size of treated varicose veins

Veins treated	Number of veins treated	Average size (mm)	Standard deviation	Minimum size (mm)	Maximum size (mm)
AASV	7	6.3	1.9	4.9	9.8
GSV	139	8.8	2.9	3.4	21.4
SSV	26	6.4	1.7	4.1	11.1
TE	1	5.4	N/A	N/A	N/A

AASV (anterior accessory saphenous vein); GSV (great saphenous vein); SSV (small saphenous vein); TE (thigh extension).

Figure 3. Type of veins, efficacy (sealed or not sealed) during follow up and prevalence of cyanoacrylate glue embolization (CAGE) phlebitis.

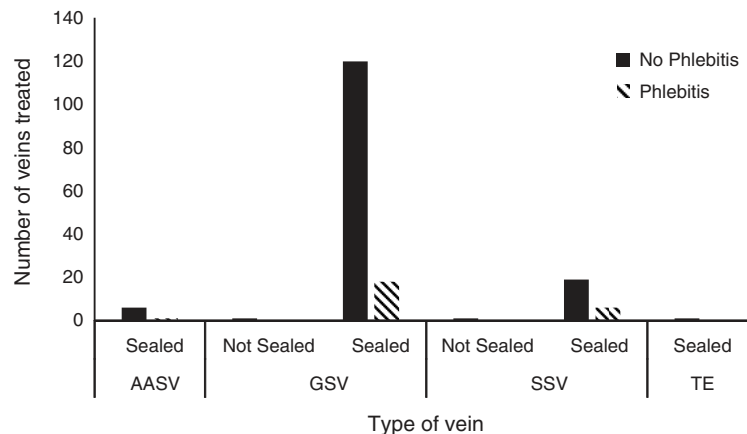
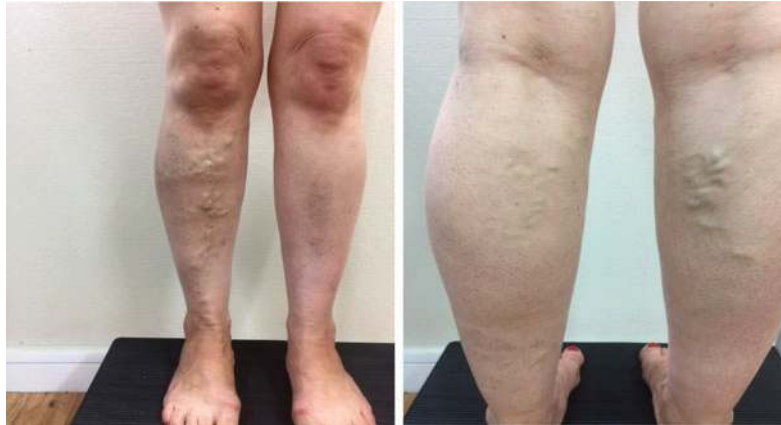

Figure 4. Case study 1: before cyanoacrylate glue embolization (CAGE).



Follow up at 4 weeks post procedure revealed a few small tributaries still patent on the left leg. Two small 18-g needle thrombectomies were performed. At 9 months' follow up, duplex ultrasound demonstrated the Venaseal™ CA glue adhesion was excellent. Post procedure photographs were taken (Fig. 6) and minor cosmetic sclerotherapy was performed. This patient had no post procedure phlebitis.

Case study 2

A 60-year-old male presented with bilateral varicose veins that had been noticeable for many years prior. The patient complained of heavy legs, swelling of the ankles and feet and cramps. His medical history included treated hypertension and he was a non-smoker. His father had had varicose vein stripping and there was a family history of heart attack and strokes. He had no known allergies.

Examination revealed bilateral varicose veins with both legs at C3 on the CEAP classification (shown in Fig. 7). Duplex ultrasound mapping (Fig. 8) revealed bilateral GSV incompetence with the right 11.4 mm and the left 7.0 mm close to the sapheno-femoral junctions. Both GSVs gave rise to large, tortuous, incompetent anterior thigh circumflex veins. The right SSV was completely blocked with calcified chronic thrombus.

CAGE was performed on both the right and left GSVs using the 'Seldinger' entry technique at the

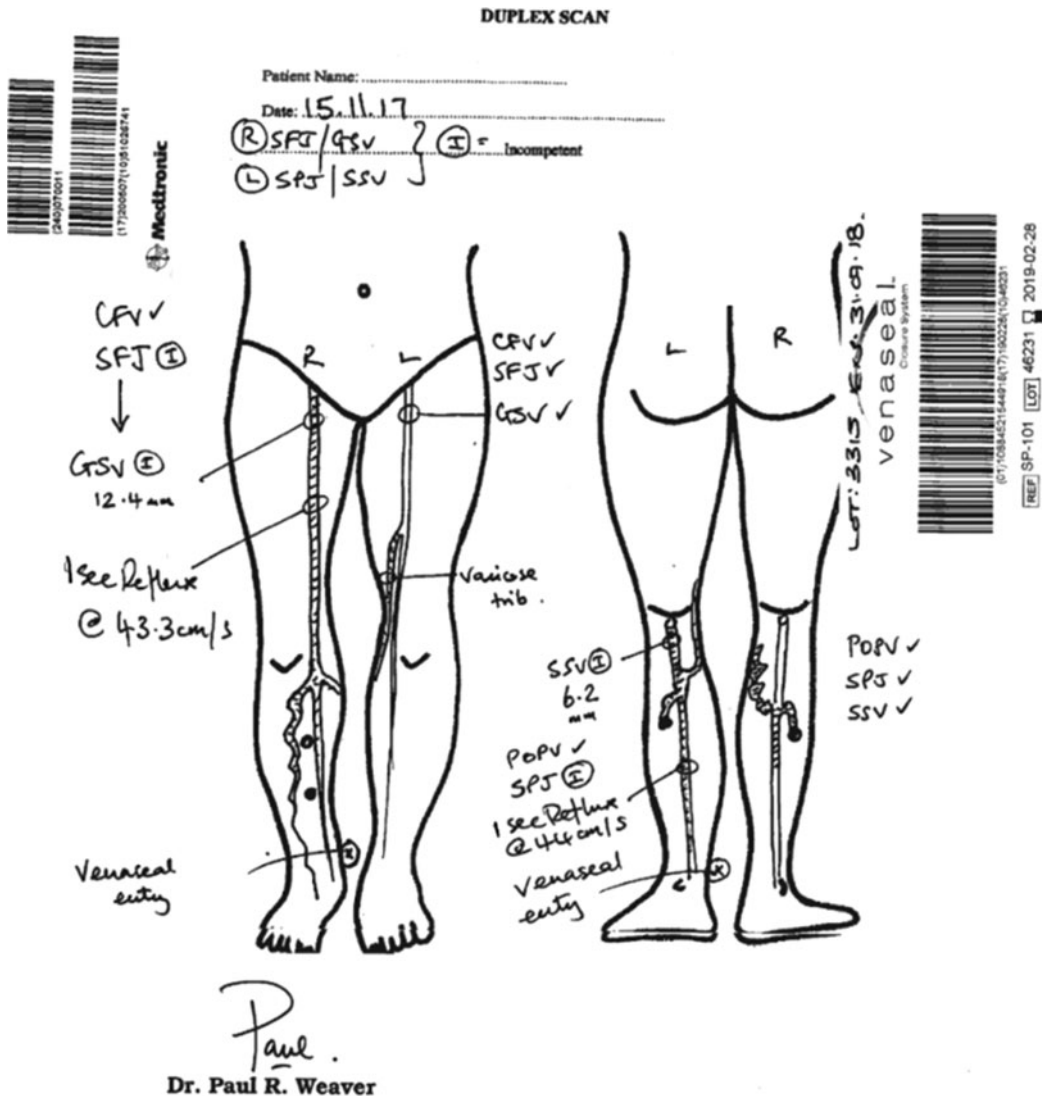
ankle, as marked on the duplex mapping scan (Fig. 8). CA glue was introduced by standard regime with manual compression and starting 5 cm below the sapheno-femoral junctions.¹⁰ Due to tortuosity of the treated veins, two entry sites were required on each leg. In total for both veins, 4.5 mL of CA glue was used.

Follow up at 1-week post procedure revealed an extensive superficial thrombophlebitis in the right anterior thigh circumflex vein, which was evacuated by thrombectomies under local anaesthetic. Thrombectomies were repeated at 3 weeks post procedure with good effect. From 4 to 14 months' post CAGE, the patient underwent five ultrasound-guided foam sclerotherapy sessions to the anterior thigh circumflex veins and tributaries bilaterally. The patient was discharged at 15 months' post CAGE with excellent clinical and scan results (shown in Fig. 9). There was no truncal phlebitis in the veins treated by CAGE.

Discussion

This audit demonstrates that CAGE with the Venaseal™ Closure System is a non-surgical procedure that can seal a wide variety of varicose veins with varying clinical severity. It was successful in treating AASV (C2–C4a), SSV (C2–C5) and a TE (C2). However, the most common vein treated in the study was the GSV with a C2 CEAP Classification. CAGE was also effective at sealing veins of varying size. Both case studies demonstrate that

Figure 5. Case study 1: duplex ultrasound mapping scan. Shaded veins demonstrate reflux of >0.5s.



varicose veins of varying clinical severity and size can be successfully treated by using CAGE with or without adjuvant ultrasound-guided foam sclerotherapy for associated tributaries. The patient in Case study 1 had a typical C2 CEAP Classification GSV and SSV that were sealed effectively and safely using CAGE. Case Study 2 is an atypical patient with more severe bilateral C3 GSVs that were sealed by CAGE and large tributaries sclerosed with ultrasound-guided foam sclerotherapy.

The first in-human 36-month follow up of the Venaseal™ Closure System had complete closure

rates of 100% after 3 months, with only two anatomic failures reported as resulting in incomplete closure.²⁴ In the Roll-in phase study for Venaseal™ Closure System, complete closure rates at 3-months follow up were 99%, with only 1% incomplete closure.²⁵ In this audit, only two out of 173 veins showed incomplete closure following CAGE with the Venaseal™ Closure System. Duplex ultrasound scanning revealed a right GSV (5.7 mm diameter) had reflux in a proximal section at 9-months' post procedure and a left SSV (11.1 mm diameter) showed reflux in multiple sections at 6 months. However, the two veins sclerosed effectively after

Figure 6. Case study 1: 9 months' post procedure.

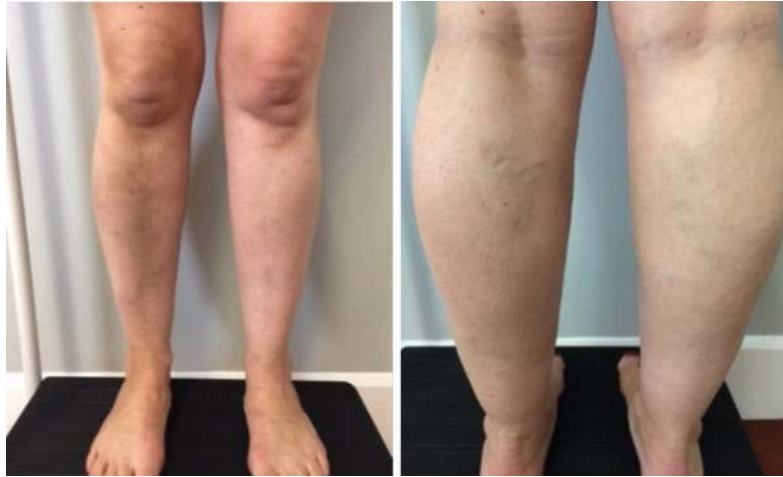
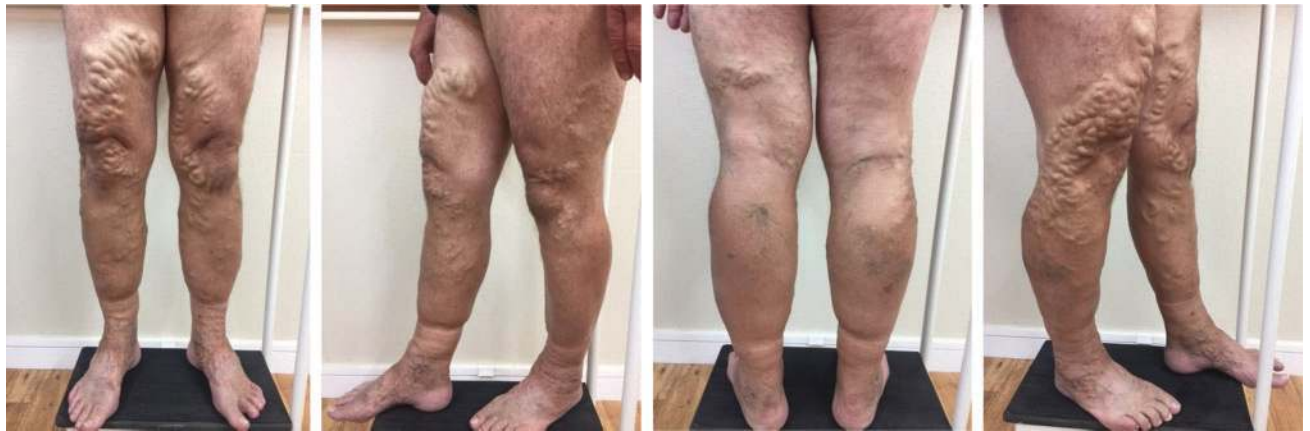
Figure 7. Case study 2: before cyanoacrylate glue embolization (CAGE).

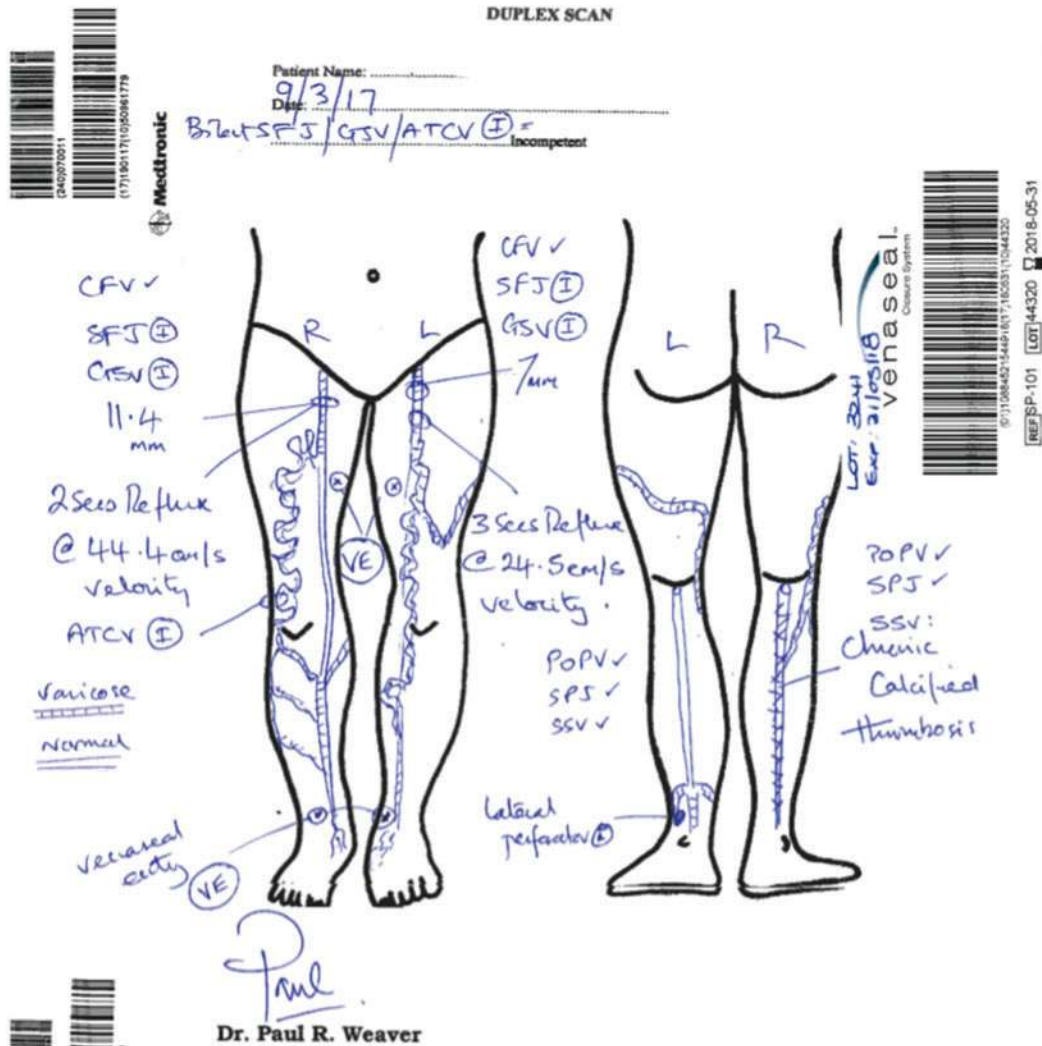


adjuvant ultrasound-guided foam sclerotherapy treatment. This shows that CAGE, with the Venaseal™ Closure System, when administered in primary care by an experienced GP, has high levels of efficacy similar to the current literature.^{10,13,15,16,24,25} It also shows that incomplete closures can be countered using ultrasound-guided foam sclerotherapy, raising the efficacy of Venaseal™ with adjuvant foam sclerotherapy to 100%.

Truncal phlebitis associated with erythema, itching, swelling, pain and tenderness of varying degrees developed post CAGE in 14.5% of veins and 21% of patients. This percentage is in line with other

reports.^{11,12,15} Current discussion on post Venaseal™ phlebitis argues that it is not true phlebitis but a phlebitis-like, abnormal reaction due to type IV hypersensitivity, because it is too widespread, lasting 7–14 days with predilection to CAGE-treated truncal veins.²² Our current practice is to allow the condition to run its course and prescribe anti-inflammatories and class II compression stockings for symptomatic relief only. Further research is needed before the condition can be established as a separate condition from traditional thrombophlebitis. However, it is still important to consider that management of the condition may change if a distinction is shown because

Figure 8. Case study 2: duplex ultrasound mapping scan. Shaded veins demonstrate reflux of >0.5 s except R. small saphenous vein (SSV), which was thrombosed. The points marked VE are the entry points for insertion of the glue catheter.



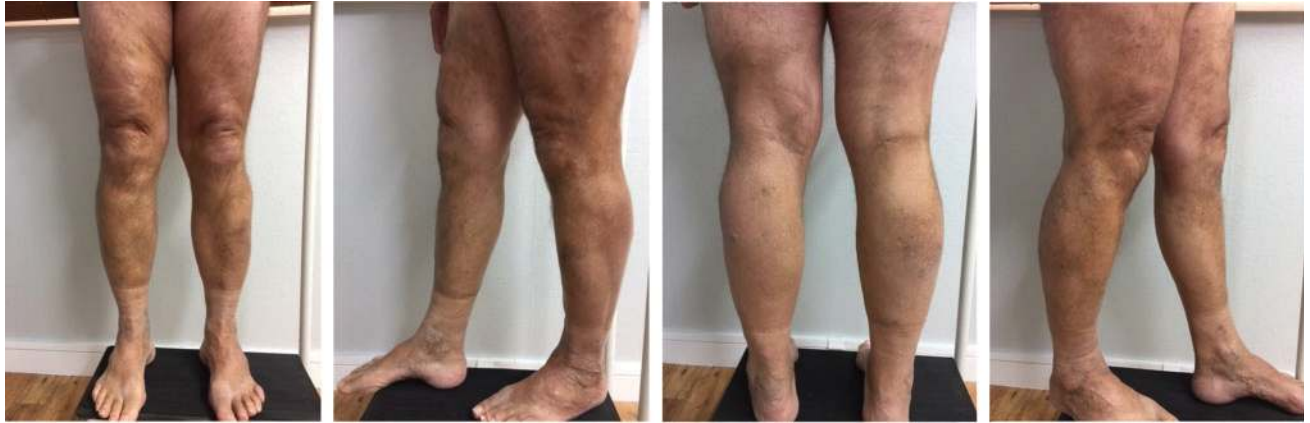treatment with antihistamines and steroids may become indicated.¹²

This audit lacked long-term follow-up data. All patients were followed up after the treatment, but the follow-up period ranged from 1 to 62 weeks. Some patients were also lost to follow up. However, because the focus of this audit was the immediate anatomical success of CAGE, as defined by ultrasound examination, our data support immediate efficacy of CAGE with the Venaseal™ Closure System. A second cycle of this audit is planned to access efficacy at 36 months' post procedure and the clinical template will be modified to simplify data collection.²⁴

We acknowledge inequity of access to the treatment as most patients were self-funded. Some patients had private medical insurance and others used an interest-free credit facility. The initial assessment was free-of-charge and a 20% discount was quoted for treatment to all Community Service Card holders. However, patients who were denied or who did not wish to use credit have been disadvantaged in their access to this treatment based on cost.

This audit of the first 107 patients to receive CAGE with the Venaseal™ Closure System from a New Zealand GP shows that varicose veins with a variety of clinical severity and size can be treated with high

Figure 9. Case study 2: 15 months' post procedure.



levels of immediate and short-term (1–62 weeks) anatomic efficacy and low levels of serious adverse effects.^{25,26} The two anatomic failures, where the veins were found to have incomplete closure at subsequent follow up, were successfully sclerosed using adjuvant ultrasound-guided foam sclerotherapy. The low rate of serious adverse effects relating to VenasealTM make it a safe option for treatment of truncal varicose veins. Post VenasealTM phlebitis affected only 21% of patients, was self-limiting and easily managed with anti-inflammatories and class II compression stockings.

Competing interests

Dr Paul R. Weaver is a GP with experience in procedural phlebology including CAGE of varicose veins using the VenasealTM Closure System. All Dr Weaver's patients are self-funded or have private medical insurance. The authors declare no other conflicts of interest.

Acknowledgements

This audit did not receive any specific funding. No funding or assistance was provided by Medtronic New Zealand Limited, the distributor of the VenasealTM Closure System.

References

- Rose SS, Ahmed A. Some thoughts on the aetiology of varicose veins. *J Cardiovasc Surg (Torino)*. 1986;27(5):534–43.
- Guex JJ. Thrombotic complications of varicose veins: a literature review of the role of superficial venous thrombosis. *Dermatol Surg*. 1996;22(4):378–82. doi:10.1111/j.1524-4725.1996.tb00336.x
- Sarin S, Scurr JH, Smith PC. Stripping of the long saphenous vein in the treatment of primary varicose veins. *Br J Surg*. 1994;81(10):1455–8. doi:10.1002/bjs.1800811017
- Murad MH, Coto-Yglesias F, Zumaeta-Garcia M, et al. A systematic review and meta-analysis of the treatments of varicose veins. *J Vasc Surg*. 2011;53(5):49S–65S. doi:10.1016/j.jvs.2011.02.031
- Rasmussen LH, Lawaetz M, Bjoern L, et al. Randomized clinical trial comparing endovenous laser ablation, radiofrequency ablation, foam sclerotherapy and surgical stripping for great saphenous varicose veins. *Br J Surg*. 2011;98(8):1079–87. doi:10.1002/bjs.7555
- de Maeseneer MM. Endovenous thermal ablation for varicose veins: strengths and weaknesses. *Phlebology*. 2012;19(4):163–9.
- Gale SS, Lee JN, Walsh ME, et al. A randomized, controlled trial of endovenous thermal ablation using the 810-nm wavelength laser and the ClosurePLUS radiofrequency ablation methods for superficial venous insufficiency of the great saphenous vein. *J Vasc Surg*. 2010;52(3):645–50. doi:10.1016/j.jvs.2010.04.030
- Schoonover JP, King JT, Gray C, et al. 3 alternatives to standard varicose vein treatment: for many patients with chronic venous insufficiency, thermal and chemical ablation could mean less pain and a speedier recovery. *J Fam Pract*. 2009;58(10):522–26.
- Proebstle TM, Alm J, Dimitri S, et al. The European ulticentre cohort study on cyanoacrylate embolization of refluxing great saphenous veins. *J Vasc Surg*. 2015;3(1):2–7.
- Tekin Aİ, Tuncer ON, Memetoğlu ME, et al. Nonthermal, nontumescent endovenous treatment of varicose veins. *Ann Vasc Surg*. 2016;36:231–5. doi:10.1016/j.avsg.2016.03.005
- Gibson K, Ferris B. Cyanoacrylate closure of incompetent great, small and accessory saphenous veins without the use of post-procedure compression: initial outcomes of a post-market evaluation of the VenaSeal System (the WAVES Study). *Vascular*. 2017;25(2):149–56. doi:10.1177/1708538116651014
- Park I, Jeong MH, Park CJ, et al. Clinical features and management of “phlebitis-like abnormal reaction” after cyanoacrylate closure for the treatment of incompetent saphenous veins. *Ann Vasc Surg*. 2019;55:239–45. doi:10.1016/j.avsg.2018.07.040

13. Alm J. VenaSeal™ closure treatment of saphenous varicosis. *Phlebologie*. 2014;43(05):242–8. doi:10.12687/phleb2216-5-2014
14. London NJ, Nash R. Varicose veins. *BMJ*. 2000;320(7246):1391–4. doi:10.1136/bmj.320.7246.1391
15. Park I. Initial outcomes of cyanoacrylate closure, Venaseal System, for the treatment of the incompetent great and small saphenous veins. *Vasc Endovascular Surg*. 2017;51(8):545–9. doi:10.1177/1538574417729272
16. Morrison N, Gibson K, McEnroe S, et al. Randomized trial comparing cyanoacrylate embolization and radiofrequency ablation for incompetent great saphenous veins (VeClose). *J Vasc Surg*. 2015;61(4):985–94. doi:10.1016/j.jvs.2014.11.071
17. Allegra C, Antignani PL, Bergan JJ, et al. The “C” of CEAP: suggested definitions and refinements: an International Union of Phlebology conference of experts. *J Vasc Surg*. 2003;37(1):129–31. doi:10.1067/mva.2003.47
18. Rabe E, Pannier F. Clinical, aetiological, anatomical and pathological classification (CEAP): gold standard and limits. *Phlebology*. 2012;27:114–18. doi:10.1258/phleb.2012.012s19
19. Labropoulos N, Tiongson J, Pryor L. Definition of venous reflux in lower-extremity veins. *J Vasc Surg*. 2003;38(4):793–8. doi:10.1016/S0741-5214(03)00424-5
20. Evans CJ, Allan PL, Lee AJ, et al. Prevalence of venous reflux in the general population on duplex scanning: the Edinburgh vein study. *J Vasc Surg*. 1998;28(5):767–76. doi:10.1016/s0741-5214(98)70051-5
21. Navarro TP, Delis KT, Ribeiro AP. Clinical and hemodynamic significance of the greater saphenous vein diameter in chronic venous insufficiency. *Arch Surg*. 2002;137(11):1233–7. doi:10.1001/archsurg.137.11.1233
22. Tang TY, Tiwari A. The VenaSeal™ abnormal red skin reaction: looks like but is not phlebitis! *Eur J Vasc Endovasc Surg*. 2018;55(6):841. doi:10.1016/j.ejvs.2018.02.003
23. Ikeda M, Kambayashi JI, Iwamoto SI, et al. Hemostasis activation during sclerotherapy of lower extremity varices. *Thromb Res*. 1996;82(1):87–95. doi:10.1016/0049-3848(96)00054-0
24. Almeida JI, Javier JJ, Mackay EG, et al. Thirty-sixth-month follow-up of first-in-human use of cyanoacrylate adhesive for treatment of saphenous vein incompetence. *J Vasc Surg*. 2017;5(5):658–66.
25. Kolluri R, Gibson K, Cher D, et al. Roll-in phase analysis of clinical study of cyanoacrylate closure for incompetent great saphenous veins. *J Vasc Surg*. 2016;4(4):407–15.
26. Morrison N, Gibson K, McEnroe S, et al. Randomized trial comparing cyanoacrylate embolization and radiofrequency ablation for incompetent great saphenous veins (VeClose). *J Vasc Surg*. 2015;61(4):985–94. doi:10.1016/j.jvs.2014.11.071