

AUTOLOGOUS ADIPOSE-DERIVED REGENERATIVE CELLS ARE EFFECTIVE FOR CHRONIC INTRACTABLE RADIATION INJURIES

Akita S^{1*}, Yoshimoto H¹, Ohtsuru A², Hirano A¹, Yamashita S^{2,3}

¹ Division of Plastic and Reconstructive Surgery, Department of Developmental and Reconstructive Medicine
Nagasaki University, Graduate School of Biomedical and Sciences

² Takashi Nagai Memorial International Hibakusha Medical Center, Nagasaki University Hospital

³ Department of Molecular Medicine, Atomic Bomb Disease Institute, Nagasaki University School of Medicine

Received month date year, amended month date year, accepted month date year

Abstract:

Effective therapy for chronic radiation injuries such as ulcer, prone to infection and stiffness are expected. As the therapeutic radiation is often involve wider and deeper tissues and often require extensive debridement and reconstruction, which are not sometimes appropriate for elderly and compromised hosts.

Autologous adipose-derived regenerative cells (ADRCs) are highly yielding form relatively elderly aged consecutive 10 cases, 63.6 ± 14.9 years (52 to 89 years), with mean radiation dose of 75.0 ± 35.4 Gy (50 to 120 Gy) were included with at least 10-month follow-ups. Minimal debridement and ADRC injection in the wound bed and margin along with injection of mixture of fat and ADRCs in the periphery were tested for efficacy and regenerated tissue quality by clinically as well as imaging by CT and MRI.

Uncultured ADRCs of $1.6 \pm 1.3 \times 10^7$ cells were obtained. All cases healed uneventfully after 6.6 ± 3.2 weeks (2 to 10 weeks) post-operatively. The done site morbidity was negligible and no major complications such as paralysis or massive hematoma. The regenerated tissue quality was significantly superior to the pre-operatively and the mixture of fat and ADRCs connected to the intact tissue demonstrated very soft and pliable quality. Mean follow-up at 1.9 ± 0.8 years (0.9 to 2.9 years) revealed no recurrence or new ulceration after treatment. Thus, the ADRC s treatment for decades-long radiation injuries is effective, safe and improves the quality of wounds.

Key words: Adipose-derived regenerative cells, ADRCs, intractable radiation injury, autologous

INTRODUCTION

Local radiation injuries are caused during medical therapy for malignant tumors (1), heart disease (2), may be accompanied with systemic symptoms of hematologic, neurologic, gastrointestinal symptoms such as neutropenia, thrombocytopenia, fatigability, nausea and diarrhea by contact to the scrap yard radioactive wastes without notice (3) or exposure to the radiation accidents (4) by touching gammagraphy radioactive source by mistake (5). In a cutaneous adverse reaction observed after estimated 15 Gy to 20 Gy dose of radiation caused by fluoroscopic procedure for ablative treatment to supraventricular arrhythmia, painful ulceration developed in four months and extensive plastic surgery was required (2). In Thailand, a stolen Co-60 orphan source was found in a scrapyard and ten victims developed radiation sickness syndromes and 3 were killed soon after exposure in 2000 (3). In 1987,Goiania, 50 people were both internally and externally exposed to 137Cs and 15

people demonstrated bone marrow suppression characterized by neutropenia and thrombocytopenia. 8 people received intravenous GM-CSF treatment, however, 8 of 14 died due to hemorrhage and infection (4). In 2005, Chile, a 27-year-old man picked up a gammagraphy radioactive source (¹⁹²Ir, 3.3TBq) with his left hand and inserted in his left pocket of the trouser in the buttock resulted severe pain, erythema, swelling and lastly necrosis continued to several weeks (5). Since radiated tissues demonstrate locally decreased or insufficient vascularity and tissue damage, demonstrating erythema, teleangietasia, pigmentation or dermal atrophy, once wound is developed, it is often intractable and further leading to tissue necrosis, infection and later fibrosis in demonstrating chronic radiation injury syndrome (6). Therefore radiation-injured wounds tend to persist for a long time, be present impaired healing and prone to recurrence even by minor trauma. Radiated wounds are treated by adequate debridement both in the depth and in the width and covered with well-vascularized tissues or by cultured bone-derived mesenchymal stem cells (5); however, the long-term outcome is not warranted and

*Corresponding author: akitas@hf.rim.or.jp

donor-site morbidity and the duration for treatment are sometimes concerned, especially for the aged patients or patients who somehow contain problems in harvesting the donors or limited due to the co-existing diseases.

Application of Stem cell therapies for repair and regeneration has recently been investigated at a clinical level in variously defected or injured tissues (7-9). Among which stem cells, adipose-derived regenerative cells (ADRCs) can be harvested with a minimally invasive procedure by liposuction procedure through a small incision. The ADRCs contain several types of stem and regenerative cells, including Adipose-Derived Stem (or stromal) Cells (ADSCs), endothelial and smooth muscle cells and their progenitors and pre-adipocytes (10). The ADSCs have the capacity to differentiate into multiple lineages and cell types including mesodermal tissues such as fat, bone, cartilage, endothelial cells of endodermal origin and neurons and epidermis of ectodermal origin as seen in the mesenchymal stem cells (11).

We succeeded to treat four patients of chronically persisted chronic radiation injuries, which suffered the patients over a few decades, with autologous ADRCs therapy.

MATERIALS AND METHODS

This study was approved by the Ethics Committee of the Nagasaki University Graduate School of Biomedical and Sciences and written informed consent was obtained from all patients (approved number 08070296) and partly supported by the Global COE (Center of Excellence) program E08, Global Strategic Center for Radiation Health Risk Control, funded by the Japan Society for the Promotion of Science.

PATIENTS

10 patients of consecutive series with chronic radiation injuries with ulcers and severe fibrosis in the surrounding tissue. The mean age was 63.6 ± 14.9 years (52 to 89 years), and a mean weight was 48.6 ± 3.9 kg with BMI 22.91 ± 3.30 (21.17- 25.45). The patients were all female. The average post-operative follow up was 1.9 years, minimally for 10 months and maximum of 2 years 10 months. Radiation injuries to sacrococcygeal, neck, anterior chest and knee regions after 75.0 ± 35.4 Gy therapeutic radiation, were enrolled in this clinical treatment.

HARVESTING OF ADIPOSE TISSUE BY LIPOSUCTION AND ISOLATION OF ADRCs

A few 3-5mm incisions were made on the abdominal region, the thigh, and the gluteal region. The subcutaneous layer was infiltrated with a lactated Ringer's solution with addition of 0.5 ml of

epinephrine and 25 ml of 1% lidocaine per 500ml. Adipose tissue was suctioned using an 18-G Becker cannula with a 50ml syringe.

ADRCs were isolated from the suctioned adipose tissue by using the Celution system™ (Cytori Therapeutics, Inc., USA). Briefly, the suctioned adipose tissue was introduced into the Celution cell-processing device, which automatically and aseptically extracts and concentrates the mononuclear fraction of adipose tissue and removes unwanted or deleterious cells, cell and matrix fragments such lipids. By using the Celution system, a final 5ml solution containing concentrated ADRCs in an averagely 1.5-hour from 250 ml of lipoaspirated tissue was obtained (12). Whole procedure is performed in a closed circuit and this reduces the chance of the contamination.

The small portion of processed ADRCs were immediately used for cell counting and then the ex vivo cell culture and confirmed the proliferation and differentiation potential in all cases.

ADIPOSE-DERIVED REGENERATIVE CELL GRAFTING AND POSTOPERATIVE MANAGEMENT

For the scaffold to the wound, an artificial dermis (Terudermis®, Olympus-Terumo Biomaterials Co., Ltd., Japan) is applied. The Terudermis® is composed of two layers: a lower layer of bovine atelo-collagen, and an upper layer comprising a silicone sheet which protects against infection and desiccation from the outside. After deep-enough and wide-enough debridement, the Terdermis® was multi-layered stacked over freshly re-surfaced wounds. The silicone sheets were removed except top Terudermis®. The two-third of an isolated ADRCs alone was injected; around wounds after debridement, at the base and at the edges of the wounds and into Terudermis®. Another approximately one-third of ADRCs were mixed with the autologous adipose which was rinsed with a lactated Ringer's solution. After mixed, it was injected to a zone of hard fibrotic tissue around the wounds (Figure 1).

One week after surgery, removing the silicone layer, human recombinant fibroblast growth factor (bFGF: Fiblast®, Kaken Co., Ltd., Japan) was sprayed. The wound was covered with non-adherent occlusive foam dressing.

RESULTS

All wounds demonstrated bone exposure and tissue surrounding the bone such as tendon, ligament and periosteum was carefully removed. There were no significant side effects in the donor-sites. All cases uneventfully and all the patients improved the activity of daily living on bathing, social activity and walking. Wound care was followed as standardized and no excessive secretion or wound infection was observed.

Case 2: A 52-year-old female was suffering from intractable chronic radiation wounds, which limited her neck movement forward and circumnutates. 335ml of adipose tissue was harvested by liposuction. The harvested adipose tissue contained 4.1×10^7 ADRCs. After careful surgical debridement, with identifying the carotid artery by ultrasonic during surgery, which is unexpectedly mal-positioned due to contracture after radiation, the defect was sized 25×17 mm and reached deep partially to the left thyroid cartilage. ADRCs were injected to the debrided wound margin and in the wound base. Total 250 ml suctioned fat was processed for ASRCs and 4 ml of which (3.28×10^7 cells) from the final of 5 ml ADRCs were soaked with multi-layered stacked Terudermis® or directly injected in the bed, side and the surrounding tissue and 1 ml out of final 5 ml of ADRCs (0.82×10^7 cells) mixed with 80 ml rinsed suctioned fat was injected into the subcutaneous area in radiating manner. In 75 days, the wound was healed and the neck forward movement was improved. At 75 days after surgery, complete wound healing is obtained and at 6 months, the injected subcutaneous lesion has still kept its soft texture and demonstrated the thick and vascularized soft tissue (Figure 2).

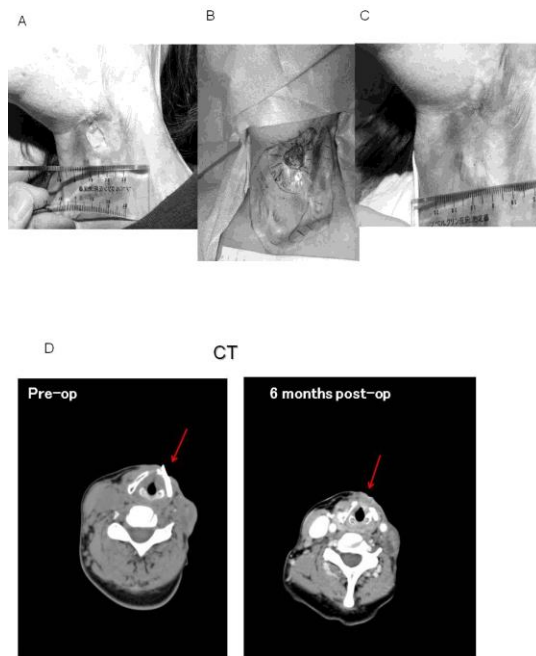


Figure 2:

52-year-old neck radiation injury in the neck

A: thyroid cartilage is exposed and the carotid artery is adjacent to the exposed cartilage.

B: Surgical debridement over the fistula and exposed cartilage.

C: 6 months postoperatively. Wound healed completely.

D: CT scanning pre- and post-operatively

The exposed cartilage is removed and the vascularized soft tissue is covering the defect at 6 months post-operatively (right).

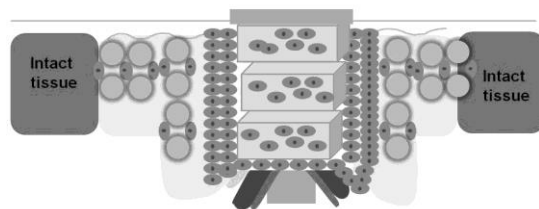


Figure 1:

Conceptual scheme of regenerative wound healing using autologous stem cells and fat tissue

DISCUSSION

Chronic radiation ulcer often demonstrates poor response to the conventional therapy. The standardized treatment of radiation ulcer is a wide-enough and deep-enough excision of potentially involved as well as grossly apparently affected tissues, followed by coverage with well-vascularized tissue such as musculocutaneous free or local flaps. However lack and limitation of tissue transplantation and inability of selecting such donor-site and possible donor-site morbidity lead to incomplete treatment in the long-term. .

The adipose tissue can be easily harvested from patients by a minimally invasive method through the small port incisions. Freshly isolated adipose-derived stem cells in our method demonstrated significant subjective improvement such as pain, discomfort and irritability as well as remarkably improved wound healing.

The human subcutaneous adipose tissue is abundant and contains greater number of various stem cells than bone marrow (10, 11). As freshly isolated ADSC or ADRCs are greater in yielding, application of freshly isolated ADSCs are comparable to the cultured ADSCs, which demonstrates phenotypic and functional similarity in mice model (13). ADRCs are the cellular fraction derived from the enzymatic digestion of the adipose tissue. ADRCs contain several types of stem and regenerative cells, including ADSCs, endothelial and smooth muscle cells, and preadipocytes. ADSCs delivered into an injured or diseased tissue may secrete cytokines and growth factors that stimulate recovery possibly in a paracrine manner. Indeed, human adipose stromal cells play a role in producing angiogenic and antiapoptotic growth factors such as vascular endothelial growth factor, hepatocyte growth factor and transforming growth factor- β (14). Also, fibroblast growth factor-2-induced hepatocyte growth factor secretion from adipose-derived stromal cells are able to inhibit post-injury fibrogenesis through a c-Jun N-terminal kinase-dependent mechanism (15). In our study, exogenously administered human recombinant bFGF may target the ADRC and thus the improved scar may be enhanced. In animal models, although it is cultured, topical administration of adipose tissue-derived stromal cells (ATSCs) is effective for rat cutaneous wounds induced by mitomycin C-treatment (16) and in diabetic mice wounds (17). Clinically purified autologous lipoaspirates were used as treatment for radiotherapy tissue damage of consecutive 71 patients. 67 out of 71 patients were able to follow and evaluated. 29 cases resulted in improved and 35 cases sustained unchanged by LENT-SOMA scale for breast radiotherapy morphology. 50 out of 67 reported satisfactory in quality of life scale by SF-36v2 and there was an improvement in blinded MRI assessment in 54 out of 65 cases(18). ADRCs mixed

with fat tissue have potential in cell therapy for radiation injury due to increasing neovascularization and retention of the fat property.

Even though there is no clear evidence of ADRC or fat grafting increasing the risk of potential cancer, one report demonstrating a small apparent increase in recurrence rate in patients with intraepithelial cancer, this difference may arise from the unusually low rate of recurrence in the matched control group rather than an unusually high rate in the group receiving fat grafts (19). However, careful and long-term follow-up of patients treated with ADRCs are recommended.

We have also shown that administration of ADRCs or the fat with ADRCs is a highly effective method for treatment of chronic radiation injury after several decades. The transplanted subcutaneous lesion keeps its soft texture and subjectively more comfortable and activity of daily living markedly improved. Using ultrasonography, we detected an increase on local blood circulation at the site in which the ADRCs were injected or alternatively, where the fat with ADRCs was transplanted. (data not shown)

Thus, ADRCs are highly accessible as a therapeutic option for intractable chronic radiation injury.

REFERENCES

1. Aquilina D, Darmanin FX, Briffa J, Gatt D. Chest wall reconstruction using an omental flap and Integra. *J Plast Reconstr Aesthet Surg* 2009; 62:e200-2.
2. Wong L, Rehm J. Images in clinical medicine. Radiation injury from a fluoroscopic procedure. *N Engl J Med* 2004; 350:350:e23.
3. Thongpraparn T, Chaudakshetrin P, Buranapong P. Lesson learned from Co-60 accident in Thailand. *Australas Phys Eng Sci Med* 2002; 25: 172-174.
4. Brandao-Mello CE, Oliveira AR, Valverde NJ, Farina R, Cordeiro JM. Clinical and hematological aspects of 137Cs: the Goiania radiation accident. *Health Phys* 1991; 60: 31-39.
5. Lataillade JJ, Doucet C, Bey E, Carsin H, Huet C, Clairand I, et al. New approach to radiation burn treatment by dosimetry-guided surgery combined with autologous mesenchymal stem cell therapy. *Regen Med* 2007; 2: 785-794.
6. Scherthan H, Abend M, Muller K, Beinke C, Braselmann H, Zitzelsberger H, et al. Radiation-induced late effects in two affected individuals of the Lilo radiation accident. *Radiat Res* 2007; 167: 615-623.
7. Ebrahimi TG, Pouzoulet F, Squiban C, Buard V, André M, Cousin B, et al. Cell therapy based on adipose tissue-derived stromal cells promotes physiological and pathological wound healing. *Arterioscler Thromb Vasc Biol* 2009; 29: 503-10.
8. Benderitter M, Gourmelon P, Bey E, Chapel A, Clairand I, Prat M, Lataillade JJ. New emerging concepts I the medical management of local radiation injury. *Health Phys* 2010; 98: 851-7.
9. Bey E, Prat M, Duhamel P, Benderitter M, Brachet M, Tromprier F, et al. Emerging therapy for improving wound repair of severe radiation burns using local bone marrow-derived stem cell administrations. *Wound Repair Regen* 2010; 18: 50-8.
10. Zuk PA, Zhu M, Ashjian P, De Ugarte DA, Huang, JJ, Mizuno H, et al. Human adipose tissue is a source of multipotent stem cells. *Mol Biol Cell* 2002; 13: 4279-4295.
11. Peroni D, Scambi I, Pasini A, Lisi V, Bifari F, Krampera M, et al. Stem molecular signature of adipose-derived stromal cells. *Exp Cell Res* 2008; 314: 603-615.
12. Yamamoto T, Gotoh M, Hattori R, Toriyama K, Kamei Y, Iwaguro H, et al. Periurethral injection of autologous adipose-derived stem cells for the treatment of stress urinary incontinence in patients undergoing radical prostatectomy: report of two initial cases. *Int J Urol* 2010; 17:75-82.
13. Bai X, Yan Y, Song YH, Seidensticker M, Rabinovich B, Metzger R, et al. Both cultured and freshly isolated adipose-derived stem cells enhance cardiac function after acute myocardial infarction. *Eur Heart J* 2010; 31: 489-501.
14. Rehman J, Traktuev D, Li J, Merfeld-Clauss S, Temm-Grove CJ, Bovenkerk JE, et al. Secretion of angiogenic and antiapoptotic factors by human adipose stromal cells. *Circulation* 2004; 109: 1292-1298.
15. Suga H, Eto H, Shigeura T, Inoue K, Aoi N, Kato H, et al. IFATS collection: Fibroblast growth factor-2-induced hepatocyte growth factor secretion by adipose-derived stromal cells inhibits postinjury fibrogenesis through a c-jun N-terminal kinase-dependent mechanism. *Stem Cells* 2009; 27: 238-249.
16. Nambu M, Ishihara M, Nakamura S, Mizuno H, Yanagibayashi S, Kanatani Y, et al. Enhanced healing of mitomycin C-treated wounds in rats using inbred adipose tissue-derived stromal cells within an atelocollagen matrix. *Wound Repair Regen* 2007; 15: 505-510.
17. Nambu M, Kishimoto S, Nakamura S, Mizuno H, Yanagibayashi S, Yamamoto N, et al. Accelerated wound healing in healing-impaired db/db mice by autologous adipose-derived tissue derived stromal cells combined with atelocollagen matrix. *Ann Plast Surg* 2009; 62: 317-321.
18. Perez-Cano R, Vranckx JJ, Lasso JM, Calabrese C, Merck B, Milstein AM, Sassoon E, Delay E, Weiler-Mithoff EM. Prospective trial of adipose-derived regenerative cell (ADRC)-enriched fat grafting for partial mastectomy defects: The RESTORE-2 trial. *Eur J Surg Oncol* 2012; 38: 382-389.
19. Petit JY, Botteri E, Lohsiriwat V, Rietjens M, Lorenzi F, Garusi C, et al. Locoregional recurrence risk after lipofilling in breast cancer patients. *Ann Oncol* 2012; 23: 582-8.

FIGURE LEGENDS

Figure 1: Scheme of the ARDCs treatment for chronic intractable radiation ulcer

Only externally exposed tissues are performed meticulous debridement, ADRCs are injected at the base and periphery of the wound and soaked and staked artificial dermis were placed. The mixture adipose tissue and ADRCs are bridged between the intact tissue and the ulcer area.

Figure 2: A 52-year-old neck radiation stiffness and ulcer
 A: A 25 × 17 mm sized wound reached deep partially to the left thyroid cartilage.
 B: Complete debridement was performed and only thinner mucous membrane was observed. After ADRCs and mixed ADRCs and fat are injected wound bed and adjacent area, the wound was cover with stacked artificial dermis.
 C: 75 days post-operatively, complete wound healing was obtained.
 D: CT demonstrates the protruded exposed left thyroid cartilage was observed pre-operatively.
 E: In 6 months post-operatively, enhanced CT demonstrated removal of the protruded cartilage and the thick vascularized soft tissue was regenerated.

FUNDING SOURCES

This work is financially supported by the Global COE (Center of Excellence) program E08, Global Strategic Center for Radiation Health Risk Control (Shunichi Yamashita), Grants-in-Aid for scientific research B ((21390479)(Akiyoshi Hirano), 22406030(Sadanori Akita)) by the Japan Society for the Promotion of Science.