

Manuscript Information	
Journal Acronym	TIDS
Volume and issue	
Author name	
Manuscript No. (if applicable)	_A_290774

Disability & Rehabilitation



Typeset by  
KnowledgeWorks Global Ltd.

for

**informa**  
healthcare

# QUERIES: to be answered by AUTHOR

**AUTHOR:** The following queries have arisen during the editing of your manuscript. Please answer the queries by making the necessary corrections on the CATS online corrections form. Once you have added all your corrections, please press the SUBMIT button.

QUERY NO.	QUERY DETAILS
	No Author Queries.
	<b>PUBLISHER QUERIES</b>
1	Please provide Super Title.
2	Please provide Accepted Date.

## ① SUPERTITLE

**Autologous platelet rich plasma for arthroscopic rotator cuff repair.  
A pilot study**PIETRO S. RANDELLI<sup>1</sup>, PAOLO ARRIGONI<sup>1</sup>, PAOLO CABITZA<sup>1</sup>, PIERO VOLPI MD<sup>2</sup>, &  
NICOLA MAFFULLI<sup>3</sup>

<sup>1</sup>Dipartimento di Scienze Medico-Chirurgiche, Policlinico San Donato, Università degli Studi di Milano, Milano, <sup>2</sup>Centro di Traumatologia dello Sport, Istituto Ortopedico Galeazzi, Milano, Italy, and <sup>3</sup>Department of Trauma and Orthopaedic Surgery, Keele University, Stoke-on-Trent, Staffordshire, UK

## ② Accepted ????

**Abstract**

**Background and purpose.** Arthroscopic repair of rotator cuff tears can produce excellent results. The application of platelet rich plasma during arthroscopic rotator cuff repair is safe, and produces results which do not deteriorate over time.

**Methods.** A total of 14 patients undergoing arthroscopic repair of a rotator cuff tear received an intra-operative application of autologous platelet rich plasma in combination with an autologous thrombin component after tear repair. Following the procedure, patients were given a standardized rehabilitation protocol, and followed for 24 months. Outcome measures included a pain score (VAS) as well as functional scoring (UCLA and Constant scores).

**Results.** Of the original 14 patients, 13 were seen to a final follow-up 24 months post-operative. Patients demonstrated a significant decrease in VAS scores and significant increases in the UCLA and Constant scores at 6, 12 and 24-month follow-ups compared to a pre-operative score.

**Conclusion.** No adverse events related to this application were noted during the procedure. The application of platelet rich plasma during arthroscopic rotator cuff repair is safe and effective, and produces results which seem to be stable with time. A prospective randomized investigation will be necessary to ascertain the efficacy of platelet rich plasma application to improve or expedite the surgical outcome following arthroscopic rotator cuff repair.

**Keywords:** Platelet-rich plasma (PRP), arthroscopic, rotator cuff repair, tendon healing

**Introduction**

Most patterns and sizes of rotator cuff tears can now be repaired arthroscopically [1,2], with outcomes comparable to those achieved by open techniques [1,2–5]. Nevertheless, post-operative complications, including surgical site infection, impaired healing, shoulder stiffness, and iatrogenic tendon injury, have a relatively high prevalence at 6–11% [6,7]. *In vitro* and animal models demonstrate enhanced tendon repair following application of growth factors [8]. Platelet derived growth factor (PDGF), epidermal growth factor (EGF), vascular endothelial growth factor, and transforming growth factor beta (TGF- $\beta$ ) are key cytokines present at high levels in platelet rich plasma (PRP) [9]. Also, PRP seems to exert an

antibacterial effect against *Escheria coli* and *Staphylococcus pneumoniae* [10,11]. The application of autologous PRP, typically in conjunction with a clotting agent, has been advocated for numerous orthopaedic conditions [8,12–14]. In general, the aim of PRP application is to accelerate the natural healing cascade through the action of elevated cytokine concentrations released during platelet degranulation, probably from stimulation of capillary regeneration [15].

This study evaluated the safety and outcome of local application of autologous PRP in patients who underwent arthroscopic rotator cuff repair. This prospective study was designed to establish an appropriate model for randomized, controlled studies investigating the efficacy of PRP application in

arthroscopic rotator cuff repair. We wished to test the null hypothesis that there were not statistically significant differences between pre-operative and post-operative Constant, UCLA and VAS scores in patients in whom a rotator cuff repair was augmented by local application of PRP.

## Methods

### *Patient enrolment*

All procedures described in the present study were approved by our local ethics committee. Patients were enrolled in the present study if they: (i) Had a complete rotator cuff tear on pre-operative clinical and imaging findings, confirmed at operation; (ii) elected to undergo to an arthroscopic repair of their rotator cuff tear; (iii) agreed to wear a dedicated brace for four weeks post-operatively; (iv) gave written informed consent; (v) had a pre-operative platelet count greater than 150,000; (vi) had a minimum pre-operative haemoglobin of 11.0 g/dl or more; (vii) had no infectious diseases or diseases which may have limit follow-up (e.g., immunocompromission, hepatitis, active tuberculosis, neoplastic disease, septic arthritis etc.); and (viii) had unilateral rotator cuff tears.

We excluded patients who: (i) Had a tear involving the subscapularis or biceps tendons; (ii) had undergone a previous rotator cuff repair; (iii) had moderate-to-severe osteoarthritis of the glenohumeral joint; (iv) had loss of  $> 20^\circ$  of passive elevation in any direction when compared to the contralateral shoulder; (v) showed a fatty infiltration greater than 50% of the cross sectional area of supraspinatus or infraspinatus assessed on the most lateral image on which the scapular spine is in contact with the scapular body [16,17]; (vi) had a massive tear in a contracted immobile cuff [18]; (vii) had an active infection, osteomyelitis or sepsis, or distant infections, which may spread to the site of operation; (viii) had osteomalacia or other metabolic bone disorders, which may impair bone or soft tissue function; (ix) were unco-operative or had disorders which made them incapable of following directions, or who were unwilling to return for follow-up examinations; and (x) had vascular insufficiency, muscular atrophy, or neuromuscular diseases of the affected arm.

### *Follow-up*

Each patient filled out a comprehensive shoulder evaluation form at pre-operative clinical evaluations (T0) as well as at 6 (T1), 12 (T2) and 24 (T3) months post-operative follow-ups. This included a visual analog score for pain (VAS), a questionnaire for the subjective Constant score [19], and the

subjective questions of the University of California (UCLA) score [20]. Additionally, pain was assessed using the VAS at a 1 month post-operative follow-up.

Constant score was calculated following a detailed physical examination in a standardized fashion [21]. The Constant score was calculated both as an absolute numerical value and as a percentage of an age and gender-matched normal score (the relative Constant score) [19]. The strength for the UCLA score was assessed in external rotation according to the modified UCLA parameters [20]. The active strength in forward flexion for the Constant score was tested as an average of three pulls in  $90^\circ$  of abduction in the scapular plane. The wrist was fixed in pronation with the hand facing the floor, and the elbow was fully extended. The result was recorded with a digital dynamometer (Kern, series HBC 20K50). Patients with active abduction of  $< 90^\circ$  were given 0 points for strength [21]. In addition to these measures, all local or general complications during the operative or follow-up phases were recorded.

### *Operative technique*

All the operations were performed in a lateral decubitus position with a scapula block with sedation. The arm was maintained approximately at  $30^\circ$  of abduction and  $30^\circ$  of forward flexion with 4 kg of traction. Diagnostic gleno-humeral arthroscopy was completed using a  $30^\circ$  arthroscope through a standard posterior portal and an arthroscopic pump maintaining a pressure of 50 mmHg. Standard anterior and lateral portals were introduced via an outside-in technique.

The cuff tear was marked initially via a PDS shuttle inserted percutaneously and retrieved from the anterior portal. The optic camera was then switched to the subacromial space and the suture marker used to localize the lesion. The shape of the lesion was classified as U, L and crescent [20]. The dimensions of the lesion were measured with an arthroscopic millimetre caliber and recorded according to DeOrto and Cofield's classification as less than 1 cm (small), from 1–3 cm (medium), 3–5 cm (large), and greater than 5 cm (massive) in the antero-posterior diameter [22]. The most lateral edges of the lesion were debrided with a combination of margin convergence techniques and direct lateral repair used depending on the tear shapes and mobility [18]. A standard acromionplasty was always performed.

### *Autologous platelet rich plasma (PRP) preparation*

Using a sterile technique, 54 ml of whole blood was drawn from all patients pre-operatively. The blood

sample was mixed with 6 ml of anticoagulant Citrate Dextrose Solution (Solution A Citra Anticoagulant, Inc., Braintree, Mass, USA). The anticoagulated blood was then transferred to a specially designed disposable tube (GPS<sup>®</sup> II Platelet Concentration System, Biomet Biologics, Warsaw, Ind, USA), and the disposable tube was placed in a centrifuge (Centra CL2, IEC International Equipment Company, Needham Heights, Mass, USA), and centrifuged for 12 min at 3200 RPM. Following centrifugation, the platelet poor plasma at the top of the tube was removed. The concentrated platelets, on top of the floating buoy, were re-suspended to form the PRP, and stored in a dedicated sterile syringe.

During the initial blood letting procedure, additional 20 ml of whole blood were taken patient without addition of anticoagulant. Two 9 ml vacuum tubes were filled and shaken to enhance the blood coagulation process. The tubes were then centrifuged (Centra CL2, IEC International Equipment Company, Needham Heights, Mass, USA) for 2.5 min at 3200 RPM. The vacuum tubes were then pulled out and the floating serum, containing autologous thrombin, was aspirated (Kassolis 2000). A ratio of 1:5 of 10% calcium chloride solution was added to the serum to counteract the citrate-based anticoagulant when the autologous serum was mixed with the PRP.

The PRP and autologous thrombin were then transferred to the sterile field and drawn up into a dedicated spray applicator kit (Micromedics, Saint Paul, MN, USA). This kit enabled simultaneous application of the PRP at a 10:1 ratio with the autologous thrombin.

#### *Surgical application of PRP*

At the end of the arthroscopic procedure, the traction was released and the resistance to pullout of the repaired construct was tested by gently mobilizing the arm. Using the lateral portal, the spray applicator kit loaded with syringes of PRP and autologous thrombin was positioned in between the bone and the repaired rotator cuff without a cannula. The inflow was then closed and the arthroscopic fluid carefully aspirated via the outflow cannula. All other cannulae were removed, producing a dry subacromial space. The blood products were then slowly injected. During this phase the assistant put their fingers on the portals to reduce out-flow of the injected solutions. Approximately 1 min after complete injection of the autologous blood products, about 100 cc of air was introduced through a sterile syringe connected with the camera inflow. A dry arthroscopic check was performed to evaluate the clot formation of the applied solution.

#### *Post operative rehabilitation*

All the patients were discharged the day after the operation wearing a sling (Ultrasling II, Don Joy, Carlsbad, CA, USA). Patients were instructed to wear the sling continuously for 10 days post operatively. From day 10 to day 28, patients were allowed to remove the sling during the day and wear it while sleeping. At post-operative day 10, passive assisted exercises were begun. Once the passive ROM was completely restored (approximately one month after the operation), patients were instructed to start active exercises to progressively regain strength.

#### *Statistical analysis*

Statistical analysis was carried out using SPSS for Windows Release 10.0 (SPSS Inc, Chicago, Ill, USA). Data are represented as mean  $\pm$  SD for continuous variables, and as percentages for categorical variables. Differences between pre-operative and post-operative continuous variables were measured with a paired Student's *t*-test or Wilcoxon Signed Ranks Test according to the characteristics of the data distribution. Multivariate analysis of variance (MANOVA) for repeated measurements was performed to investigate the presence of a significant change over time for continuous variables; contrasts analysis for repeated measurements were used to investigate the shape of the relationship between the mean values of continuous variables and time. For all analysis, a value of  $p < 0.05$  was considered significant.

## **Results**

#### *Demographics*

From January 2004 to May 2004, 14 patients (eight males and six females; average age at operation  $66.6 \pm 9.04$  years; 10 tears involving the dominant arm, and four involving the non-dominant arm) entered the study, according to the inclusion and exclusion criteria specified above, and underwent a rotator cuff repair with local application of autologous PRP activated by autologous thrombin (Table I).

Table I. Details of the main lesion, and surgical features. Values are expressed as mean  $\pm$  standard deviation or *n* (%).

Item	Results
Sutures ( <i>n</i> )	3.64 $\pm$ 1.39
Anchors ( <i>n</i> )	1.43 $\pm$ 0.65
Tear dimension	2.85 $\pm$ 0.86
Tear shape	Crescent: 9 (64.3); U: 5 (35.7)

No local or general complications were observed during the operative phase or the follow-up period. At the last follow-up appointment (T3 – 24 months), a female patient was not available, as she experienced symptoms and clinical findings consistent with a re-tear following a fall onto the operated arm.

#### VAS score

The mean pre-operative VAS score ( $5.64 \pm 2.17$  for all patients undergoing a rotator cuff repair;  $5.31 \pm 1.84$  for all patients available at the last post-operative follow-up evaluation) was significantly different from the post-operative score at 6 months ( $0.57 \pm 0.76$ ), 12 months ( $1.29 \pm 0.99$ ) and 24 months ( $1.00 \pm 0.58$ ) ( $p < 0.001$ ). There was no significant difference in VAS score ( $p = 0.056$ ) between pre-operative and 1 month post-operative value ( $3.86 \pm 2.66$ ) (Table II).

#### UCLA score

The mean UCLA score increased from 16.54 ( $\pm 5.46$ ) pre-operatively to 32.92 ( $\pm 1.19$ ) post-operatively at 24 months of follow-up ( $p < 0.001$ ). Three patients achieved excellent results and 10 good results according to the UCLA scoring system at the T3 (24 months) follow-up evaluation.

#### Constant score

The mean Constant score improved from a pre-operative value of 54.62 ( $\pm 16.98$ ) to 85.23 ( $\pm 7.22$ ) at the latest post-operative follow-up ( $p = 0.001$ ) with excellent final results according to the rating system in all the case. On average, the age and gender-adjusted Constant score improved from an average pre-operative score of 70.4% ( $\pm 22.6$ ) to 111.8% ( $\pm 10.5$ ) at the final follow-up.

#### MANOVA

MANOVA for the UCLA and Constant scores showed a significant change over time (UCLA –  $p < 0.001$ ; Constant –  $p < 0.001$ ). The results of contrast analyses to investigate the shape of the relationship between clinical outcomes scores and time are shown in Table III.

The mean values of Constant and UCLA scores increased linearly over time. However, a quadratic component was also observed, implying that the increase levelled off and even seemed to invert the trend at the last measurement (Figures 1 and 2).

Both the linear ( $p < 0.001$ ) and quadratic ( $p < 0.001$ ) components for the Constant and UCLA scores were highly significant.

Table II. Paired differences between pre-operative and all follow-up visits. The difference at 6, 12 and 24 months' post-operative were statistically significant. All values are mean  $\pm$  standard deviation.

Time periods	Paired differences	<i>p</i> value	<i>n</i>
Pre-operative vs. 1 month	$1.79 \pm 3.12$	0.05	14
Pre-operative vs. 6 months	$5.07 \pm 1.86$	<0.001	14
Pre-operative vs. 12 months	$4.36 \pm 2.21$	<0.001	14
Pre-operative vs. 24 months	$4.31 \pm 1.93$	<0.001	13

Table III. Mean  $\pm$  standard deviation values for the UCLA and Constant scores are presented for T0 = pre-operative, T1 = 6 months, T2 = 12 months, and T3 = 24 months.

Time point	UCLA	Constant	<i>n</i>
T0	$16.54 \pm 5.46$	$54.62 \pm 16.98$	13
T1	$31.92 \pm 3.82$	$85.23 \pm 17.31$	13
T2	$33.54 \pm 2.07$	$89.46 \pm 7.83$	13
T3	$32.92 \pm 1.19$	$85.23 \pm 7.22$	13

*p* value by MANOVA (UCLA –  $p < 0.001$ ; Constant –  $p < 0.001$ ); *p* value by Linear contrasts (UCLA –  $p < 0.001$ ; Constant –  $p < 0.001$ ); *p* value by Linear Quadratic (UCLA –  $p < 0.001$ ; Constant –  $p < 0.001$ ).

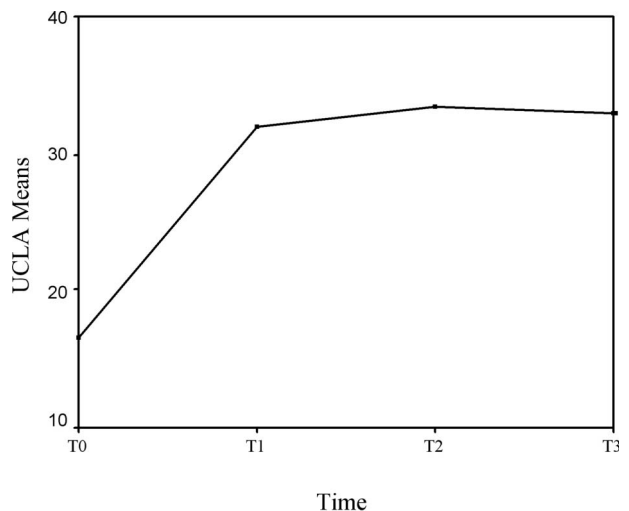


Figure 1. Mean values of UCLA score. MANOVA for repeated measurements; graphical representation. T0 = pre-operative, T1 = 6 months, T2 = 12 months, and T3 = 24 months.

#### Discussion

This study demonstrates that the use of autologous PRP in combination with an autologous thrombin between the bone and the cuff repair is safe and effective: During the course of the study, no adverse event related to the application of these products was observed. The application of PRP produces clinical

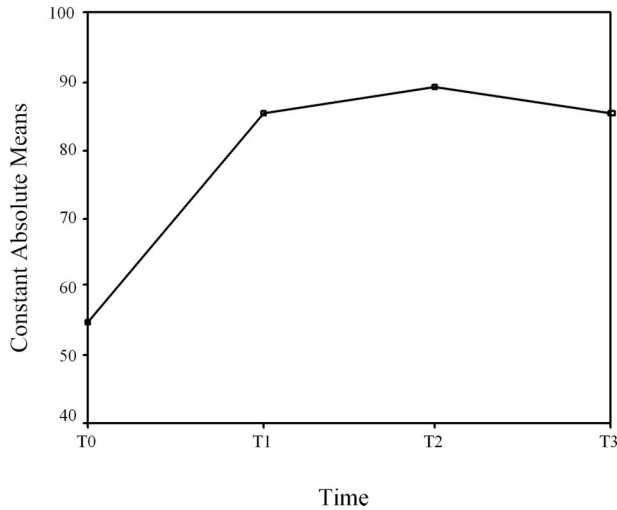


Figure 2. Mean values of Constant score. MANOVA for repeated measurements; graphical representation. T0 = pre-operative, T1 = 6 months, T2 = 12 months, and T3 = 24 months.

results which appear to be stable during the observed period (24 months). One patient did not complete the follow-up; however this was due to the presentation of a re-tear caused during an accidental fall. The surgical application was consistent across all the cases with good clot formation seen between the repair site and bone. During a follow-up period of 24 months, the 13 patients remaining in the study demonstrated statistically significant decreases in pain scores (VAS pain score) and statistically significant improvement in function scores (UCLA and Constant scores).

Our results are in accordance with reports of similar applications in orthopaedic [7,8,11–14, 23,24] and non-orthopaedic procedures [11,25]. A recent study on local application of PRP in chronic elbow tendinosis demonstrates a significant reduction (93% in a 100-points based VAS) of pain compared to the level expressed before the treatment [13]. This is consistent with our findings and supports a possible effect of PRP on reduction of postoperative pain. Despite the mechanism of this action remains unclear a possible explanation is the related control of post-operative bleeding with consequent reduction of hematomas and tensions of the soft tissues [7]. Painless patients are able to start rehabilitation earlier and need a reduced prescription of oral pain medications, with consequent implications on social costs.

An early recovery after on local application of platelet rich fibrin matrices has been demonstrated during open Achilles tendon repair in athletes. These subjects were able to return to their previous sport activity at an average of 14 weeks, compared with an average of 22 weeks in the untreated group. This evidence reinforces the possibility of a faster

abandon of the sling. This is in consistent with our protocol [8].

The tendency of PRP and fibrin sealant to reduce the post-operative stiffness rate has been recently analysed on total knee arthroplasties [23]. Patients who received the treatment reached significantly higher ROM compared to the control group. Regain of full passive ROM is a primary goal after arthroscopic rotator cuff surgery. All our patients were able to begin the active phase of their rehabilitation within one month from surgery, after that full passive ROM was obtained. This was a more aggressive rehabilitation then typically performed in our setting, but a true comparison to a control population would be necessary to attribute this factor to the application of the PRP.

To our knowledge, this is the first report on the application of a concentrated fraction of autologous platelets during arthroscopic rotator cuff repair. The results of this case series are of value as further demonstration of the safety of PRP application. However, a true assessment of the effect of the application of platelet concentrate on surgical outcome would require a prospective randomized controlled clinical trial. This study was performed, in part, to confirm the appropriateness of the selected model and the results will be used to appropriately power the sample size determination for the prospective, randomized trial. Considering the Constant score to define the power a 7-point difference has been recognized as clinically relevant [24]. Setting the power at 80%, the alpha level of 5%, and the standard deviation at 8%, a total enrolment of 44 patients would be adequate to satisfy the comparison.

This study presents some weaknesses: The population is small with no control group, and there is no direct demonstration of the histological quality of the repair. However, it would have been ethically untenable to perform second look arthroscopies to harvest a biopsy sample for study purposes. Also, no post-operative imaging studies or second look procedures were performed. We decided to put ourselves in the position of a clinician who took decisions based on clinical examination alone, as most physicians will not have easy access sophisticated imaging instruments.

The results of this study offer the basis to accelerate the recovery process with a indirect fast return to previous activities. Future lines of research need to include cost analysis, quality of the repaired tendon, evaluation of maintenance of the obtained results at longer follow-ups and social impact of a reduced need of post-operative immobilization. Early clinical evidences, such as this case series, confirm the inherent safety of PRP application.

## References

1. Burkhart SS, Lo IK. Arthroscopic rotator cuff repair. *J Am Acad Orthop Surg* 2006;14:333–346.
2. Lo IK, Burkhart SS. Arthroscopic repair of massive, contracted, immobile rotator cuff tears using single and double interval slides: Technique and preliminary results. *Arthroscopy* 2004;20:22–33.
3. Buess E, Steuber KU, Waibl B. Open versus arthroscopic rotator cuff repair: A comparative view of 96 cases. *Arthroscopy* 2005;21:597–604.
4. Lo IK, Burkhart SS. Arthroscopic repair of massive, contracted, immobile rotator cuff tears using single and double interval slides: Technique and preliminary results. *Arthroscopy* 2004;20:22–33.
5. McCluskey GM 3rd, Gaunt BW. Mini-open rotator cuff repair. *J Surg Orthop Adv* 2006;15:145–153.
6. Brislin KJ, Field LD, Savoie FH 3rd. Complications after arthroscopic rotator cuff repair. *Arthroscopy* 2007;23(2):124–128.
7. Gardner MJ, Demetrakopoulos, Klepchick PR, Pekka AM. The efficacy of autologous platelet gel in pain control and blood loss in total knee arthroplasty. *Int Orthopaedics* 2007;31:309–313.
8. Sanchez M, Anitua E, Azofra J, Andia I, Padilla S, Muljika I. Comparison of surgically repaired Achilles tendon tears using platelet-rich fibrin matrices. *Am J Sports Med* 2007;35:245–251.
9. Eppley BL, Woodell JE, Higgins J. Platelet quantification and growth factor analysis from platelet-rich plasma: implications for wound healing. *Plast Reconstr Surg* 2004;114:1502–1508.
10. Bielecki TM, Gazdzik TS, Arendt J, Szczepanski T, Krol W, Wielkoszynski T. Antibacterial effect of autologous platelet gel enriched with growth factors and other active substances: An *in vitro* study. *J Bone Joint Surg (Br)* 2007;89-B:417–420.
11. Trowbridge CC, Stammers AH, Woods E, Yen BR, Klayman M, Gilbert C. Use of platelet gel and its effects on infection in cardiac surgery. *J Extra Corporeal Tech* 2005;37:381–386.
12. Everts PA, Devilee RJ, Brown Mahoney C, Eeftinck-Schattenkerk M, Box HA, Knape JT, Van Zundert A. Platelet gel and fibrin sealant reduce allogeneic blood transfusions in total knee arthroplasty. *Acta Anaesthesiol Scand* 2006;50:593–599.
13. Mishra A, Pavelko T. Treatment of chronic elbow tendinosis with buffered platelet-rich plasma. *Am J Sports Med* 2006;34:1774–1778.
14. Ventura A, Terzaghi C, Borgo E, Verdoia C, Gallazzi M, Failoni S. Use of growth factors in ACL surgery: Preliminary study. *J Orthopaed Traumatol* 2005;6:76–79.
15. Lindeboom JA, Mathura KR, Aartman IH, Kroon FH, Milstein DM, Ince C. Influence of the application of platelet-enriched plasma in oral mucosal wound healing. *Clin Oral Impl Res* 2007;18:133–139.
16. Fuchs B, Weishaupt D, Zanetti M, Hodler J, Gerber C. Fatty degeneration of the muscles of the rotator cuff: Assessment by computed tomography versus magnetic resonance imaging. *J Shoulder Elbow Surg* 1999;8:599–605.
17. Goutallier D, Postel JM, Gleyze P, Leguilloux P, Van Driessche S. Influence of cuff muscle fatty degeneration on anatomic and functional outcomes after simple suture of full-thickness tears. *J Shoulder Elbow Surg* 2003;12:550–554.
18. Burkhart SS. The principle of margin convergence in rotator cuff repair as a means of strain reduction at the tear margin. *Ann Biomed Eng* 2004;32:166–170.
19. Constant CR. Age related recovery of shoulder function after injury [thesis]. Cork, Ireland: University College; 1986.
20. Burkhart SS, Danaceau SM, Pearce CE Jr. Arthroscopic rotator cuff repair: Analysis of results by tear size and by repair technique – margin convergence versus direct tendon-to-bone repair. *Arthroscopy* 2001;17:905–912.
21. Constant CR, Murley AH. A clinical method of functional assessment of the shoulder. *Clin Orthop Relat Res* 1987;214:160–164.
22. DeOrto JK, Cofield RH. Results of a second attempt at surgical repair of a failed initial rotator cuff repair. *J Bone Joint Surg Am* 1984;66:563–567.
23. Everts PA, Devilee RJ, Oosterbos CJ, Mahoney CB, Schattenkerk ME, Knape JT, van Zundert A. Autologous platelet gel and fibrin sealant enhance the efficacy of total knee arthroplasty: Improved range of motion, decreased length of stay and a reduced incidence of arthrofibrosis. *Knee Surg Sports Traumatol Arthrosc* 2007;15:888–894.
24. Lichtenberg S, Liem D, Magosch P, Habermeyer P. Influence of tendon healing after arthroscopic rotator cuff repair on clinical outcome using single-row Mason-Allen suture technique: A prospective, MRI controlled study. *Knee Surg Sports Traumatol Arthrosc* 2006;14:1200–1206.
25. Kassolis JD, Rosen PS, Reynolds MA. Alveolar ridge and sinus augmentation utilizing platelet-rich plasma in combination with freeze-dried bone allograft: Case series. *Periodontology* 2000;71(10):1654–1661.