

# Circulation

JOURNAL OF THE AMERICAN HEART ASSOCIATION



## **$\beta$ -Particle-Emitting Radioactive Stent Implantation : A Safety and Feasibility Study**

A. J. Wardeh, I. P. Kay, M. Sabaté, V. L. M. A. Coen, A. L. Gijzel, J. M. R. Ligthart, A. den Boer, P. C. Levendag, W. J. van der Giessen and P. W. Serruys

*Circulation* 1999;100;1684-1689

Circulation is published by the American Heart Association, 7272 Greenville Avenue, Dallas, TX 72514

Copyright © 1999 American Heart Association. All rights reserved. Print ISSN: 0009-7322. Online ISSN: 1524-4539

The online version of this article, along with updated information and services, is located on the World Wide Web at:

<http://circ.ahajournals.org/cgi/content/full/100/16/1684>

Subscriptions: Information about subscribing to *Circulation* is online at  
<http://circ.ahajournals.org/subscriptions/>

Permissions: Permissions & Rights Desk, Lippincott Williams & Wilkins, 351 West Camden Street, Baltimore, MD 21202-2436. Phone 410-5280-4050. Fax: 410-528-8550. Email:  
[journalpermissions@lww.com](mailto:journalpermissions@lww.com)

Reprints: Information about reprints can be found online at  
<http://www.lww.com/static/html/reprints.html>

## $\beta$ -Particle-Emitting Radioactive Stent Implantation A Safety and Feasibility Study

A.J. Wardeh, MD; I.P. Kay, MBChB; M. Sabaté, MD; V.L.M.A. Coen, MD;  
A.L. Gijzel, MD; J.M.R. Ligthart, BSc; A. den Boer, BSc; P.C. Levendag, MD, PhD;  
W.J. van der Giessen, MD, PhD; P.W. Serruys, MD, PhD

**Background**—This study represents the Heart Center Rotterdam's contribution to the Isostents for Restenosis Intervention Study, a nonrandomized multicenter trial evaluating the safety and feasibility of the radioactive Isostent in patients with single coronary artery disease. Restenosis after stent implantation is primarily caused by neointimal hyperplasia. In animal studies,  $\beta$ -particle-emitting radioactive stents decrease neointimal hyperplasia by inhibiting smooth muscle cell proliferation.

**Methods and Results**—The radioisotope  $^{32}\text{P}$ , a  $\beta$ -particle emitter with a half-life of 14.3 days, was directly embedded into the Isostent. The calculated range of radioactivity was 0.75 to 1.5  $\mu\text{Ci}$ . Quantitative coronary angiography measurements were performed before and after the procedure and at 6-month follow-up. A total of 31 radioactive stents were used in 26 patients; 30 (97%) were successfully implanted, and 1 was embolized. Treated lesions were in the left anterior descending coronary artery (n=12), the right coronary artery (n=8), or the left circumflex coronary artery (n=6). Five patients received additional, nonradioactive stents. Treated lesion lengths were  $13 \pm 4$  mm, with a reference diameter of  $2.93 \pm 0.47$  mm. Minimum lumen diameter increased from  $0.87 \pm 0.28$  mm preprocedure to  $2.84 \pm 0.35$  mm postprocedure. No in-hospital adverse cardiac events occurred. All patients received aspirin indefinitely and ticlopidine for 4 weeks. Twenty-three patients (88%) returned for 6-month angiographic follow-up; 17% of them had in-stent restenosis, and 13% had repeat revascularization. No restenosis was observed at the stent edges. Minimum lumen diameter at follow-up averaged  $1.85 \pm 0.69$  mm, which resulted in a late loss of  $0.99 \pm 0.59$  mm and a late loss index of  $0.53 \pm 0.35$ . No other major cardiac events occurred during the 6-month follow-up.

**Conclusions**—The use of radioactive stents with an activity of 0.75 to 1.5  $\mu\text{Ci}$  is safe and feasible. (*Circulation*. 1999;100:1684-1689.)

**Key Words:**  $\beta$ -rays ■ angioplasty ■ radioactive isotopes ■ restenosis ■ stents

Percutaneous transluminal coronary angioplasty (PTCA) is an accepted treatment for coronary artery disease.<sup>1</sup> However, angiographic restenosis is reported in 40% to 60% of patients after a successful PTCA.<sup>1,2</sup> The main mechanisms of restenosis include late constriction of the arterial wall (vascular shrinkage) and neointimal hyperplasia,<sup>3-6</sup> which are due to the migration and proliferation of smooth muscle cells and myofibroblasts after balloon-induced trauma of the arterial wall and the deposition of an extracellular matrix by the smooth muscle cells.<sup>6-9</sup> Stent implantation reduces the restenosis rate<sup>10,11</sup> by preventing elastic recoil and late constrictive remodeling.<sup>12</sup> However, the occurrence of restenosis after stent implantation remains unresolved, especially in small vessels and long lesions, in which it may occur in >30% of cases.<sup>13</sup> Restenosis is primarily caused by neointimal hyperplasia, which occurs due to trauma of the arterial wall by the stent struts.<sup>5</sup>

Irradiation is used to decrease neointimal proliferation because the actively proliferating cells have an increased sensitivity to the lethal effects of radiation, which inhibits benign hyperplastic reactions such as keloid formation and heterotopic ossification.<sup>14,15</sup> Several experimental and clinical trials showed that brachytherapy with a radioactive source after PTCA or stent implantation can reduce restenosis by inhibiting neointimal hyperplasia,<sup>16-19</sup> and several animal studies demonstrated a dose-related reduction of in-stent restenosis with the use of radioactive stents.<sup>20-22</sup> Furthermore, a dose-dependent delay in the endothelialization of the stent occurred, which increased the chance of subacute thrombosis.<sup>20,23</sup>

This study evaluated the safety and feasibility of radioactive stent implantation (activity level, 0.75 to 1.5  $\mu\text{Ci}$ ) in single-lesion, native coronary artery disease.

Received February 8, 1999; revision received June 28, 1999; accepted July 2, 1999.

From the Thoraxcenter, Heartcenter, University Hospital Rotterdam, Dijkzigt (A.J.W., I.P.K., M.S., A.L.G., J.M.R.L., A.d.B., W.J.v.d.G., P.W.S.), and the Daniel den Hoed, Cancer Center (V.L.M.A.C., P.C.L.), Rotterdam, The Netherlands.

Correspondence to Prof Patrick W. Serruys, MD, PhD, Head of the Department of Interventional Cardiology, Thoraxcenter Bd 418, University Hospital Dijkzigt, Dr Molewaterplein 40, 3015 GD Rotterdam, The Netherlands. E-mail Serruys@card.azr.nl

© 1999 American Heart Association, Inc.

*Circulation* is available at <http://www.circulationaha.org>

TABLE 1. Balloon Inflation and Stent Deployment Data

Patient	Type of Stent	Predilatation			Stent Deployment		Postdilatation			Lesion Length, mm
		Diam, mm	Atm	Length, mm	Diam, mm	Atm	Diam, mm	Atm	Length, mm	
1	PS‡	3.0	6	20	3.0	10	3.5	16	30	17
2	PS	3.0	8	20	3.5	8	3.0	16	15	11
3	PS	3.5	14	30	3.5	10	3.5	16	13	10
4	PS	3.5	8	30	3.5	12	ND	ND	ND	15
5	BX*	2.5	14	20	3.0	12	3.5	16	13	15
6	BX	3.5	6	20	3.5	10	4.0	12	13	12
7	PS	3.0	10	20	3.0	12	3.5	10	13	11
8	BX	4.0	6	15	3.5	12	4.5	16	15	10
9	BX	2.5	6	15	3.5	16	2.5	12	15	14
10	BX	3.5	10	20	3.5	11	4.0	18	13	19
11	BX*	3.0	12	13	3.5	11	4.0	18	13	8
12	BX†*	3.0	10	20	3.0	12	3.0	18	20	17
13	BX*	3.0	10	20	3.0	8	3.5	16	13	17
14	BX	3.0	8	15	3.5	12	ND	ND	ND	14
15	BX	3.0	12	13	3.0	10	4.0	14	13	7
16	BX	3.0	12	13	3.0	10	4.0	16	13	10
17	BX	3.5	12	20	3.5	8	4.0	16	13	12
18	BX†	3.0	8	20	3.0	10	4.0	18	20	23
19	BX	3.5	7	20	3.5	7	4.0	14	13	10
20	BX†	3.0	14	29	3.0	18	3.5	16	29	15
21	BX	3.5	8	20	3.5	8	ND	ND	ND	12
22	BX	3.5	8	15	3.5	8	4.0	12	13	10
23	BX†	3.0	10	20	3.5	10	4.0	16	20	16
Mean		3.2	10	19	3.3	11	3.7	15	16	13
SD		0.4	3	5	0.2	3	0.5	2	5	4

Atm indicates maximum atmospheres; Diam, maximum diameter; ND, not done; PS, Palmaz-Schatz. \*1 additional nonradioactive stent implanted; †2 BX stents implanted; ‡2 additional nonradioactive stents implanted.

Methods

Patient Population

The Isostents for Restenosis Intervention Study (IRIS) is a nonrandomized, multicenter trial evaluating the safety and feasibility of radioactive stents. The data presented here represent the experience of the Heart Center Rotterdam. Patients who had single coronary lesions with a maximum lesion length of 28 mm (maximum, 2 radioactive stents of 15 mm implanted in tandem position) and objective evidence of ischemia were eligible. Exclusion criteria included the following: a recent myocardial infarction (MI; creatine kinase [CK] isoenzyme containing M and B subunits [MB] >3 times the upper limit of normal within 5 days of the intervention); left ventricular ejection fraction <40%; allergy or contraindication to aspirin, ticlopidine, or stainless steel; and lesions located in the left main artery or at the ostium of the right coronary artery. The Medical Ethical Committee of the University Hospital Rotterdam approved the study. All patients provided written, informed consent before the procedure.

Radioactive Stent, Dosimetry, and Safety Issues

Two types of stents were implanted in this study: the Palmaz-Schatz (Cordis Corp, Johnson and Johnson Interventional Systems Co) and BX stent (Isostent Inc). Phosphorus-32 (<sup>32</sup>P), a pure β-emitter with a half-life of 14.3 days, was produced by neutron irradiation of red amorphous <sup>31</sup>P for 10 days to achieve a concentration of 20×10<sup>-6</sup> <sup>32</sup>P/<sup>31</sup>P (100 mCi). The irradiated phosphorus was then placed into a mass separator, ionized, and accelerated. A dipole magnet separated

the <sup>32</sup>P and <sup>31</sup>P. Subsequently, <sup>32</sup>P was directly implanted into the metal stent surface.<sup>21</sup> The calculated radioactivity of the stents at implantation was 0.75 to 1.5 μCi, and the dose delivered over 100 days at 1 mm from the stent surface was calculated for each stent. All personnel were trained in the appropriate handling of radioactive materials. During implantation, the lucite shield enclosing the stent and the sheathed introduction system prevented exposure of the operator to the radiation of the stent. Background measurements of radioactivity were made by means of a Geiger counter (Model 14c, Ludlum Measurements Inc). All disposable materials that were in contact with the stent were immediately disposed of in a plexiglas container, and radioactivity measurements were made by the radiation technician.

Quantitative Coronary Angiography

Quantitative coronary angiography (QCA) was performed preprocedure, postprocedure, and at 6-month follow-up. Coronary angiography was performed after intracoronary administration of nitrates. The off-line analysis of ≥2 orthogonal projections was performed by the CAAS II analysis system (Pie Medical BV). Calibration of the system was based on dimensions of the catheters not filled with contrast medium. This method of analysis has been extensively validated and applied in numerous clinical trials.<sup>24-26</sup> The following measurements were obtained in each projection: minimum lumen diameter (MLD), reference diameter, percent diameter stenosis (%DS), and lesion length. Lesion length was user-defined.<sup>26</sup> Procedural success was defined as <20% DS as measured by online QCA. Short-term gain was defined as MLD postprocedure minus MLD

preprocedure. Late loss was defined as MLD postprocedure minus MLD at follow-up. Late loss index was defined as short-term gain divided by late loss.<sup>27</sup> Restenosis was defined as >50% DS at follow-up located within the stent or  $\leq 5$  mm from the stent edges. The latter represents an area where tissue is subjected both to balloon-induced trauma and to a lower dose of radiation,<sup>21</sup> which may stimulate restenosis. This edge-effect phenomenon has recently been described in patients and called the "candy-wrapper effect."<sup>28</sup> To quantify an edge effect, a QCA segmental analysis was performed. At both postprocedure and follow-up, the treated vessels were first divided into segments  $\approx 5$  mm in length; then, the mean diameter of the 5-mm segments distal and proximal to the stent edges were calculated using the CAAS II analysis system. Careful comparison of the proximal and distal edges was performed postprocedure and at follow-up.

### Procedure and Follow-Up

Patients received 250 mg of aspirin and 10 000 IU of heparin at the start of the procedure. The activation clotting time was maintained at >300 s. After balloon predilatation, the radioactive stent was implanted at a nominal deployment pressure of 8 to 10 atm. If needed, stent deployment was optimized using shorter postdilatation balloons of longer diameters to higher pressures (Table 1). Extreme care was taken to avoid inflating the balloon outside the edges of the stent. Because of the poor radiopacity of the Palmaz-Schatz and the BX stents, the best angiographic view was selected, and images were filmed in a magnified field (5 inch) with digital zoom enhancement to optimize stent visualization. All patients received ticlopidine 250 mg BID for 4 weeks after stent implantation and aspirin 80 mg daily indefinitely. CK and CK-MB measurements were made, and the ECG was recorded at 6 and 12 to 18 hours postprocedure in all patients.

Patients returned for 1- and 6-month clinical follow-up. An ECG was performed at each visit. The 30-day and 6-month clinical end points were death, Q-wave MI (using the Minnesota code criteria<sup>29</sup>), non Q-wave MI (CK-MB rise >2 times normal upper limit), bypass surgery, target segment revascularization, sustained abrupt closure, or subacute thrombosis of the target vessel.

At the 6-month visit, an exercise stress test was performed. Target vessel revascularization was performed on the basis of clinical symptoms and/or evidence of ischemia on exercise testing.

### Statistical Analysis

Data are presented as mean  $\pm$  SD. Continuous data were compared by 2-tailed Student's *t* test or linear regression when appropriate.

## Results

### Baseline Characteristics

Baseline demographics, anginal status, and lesion characteristics are shown in Table 2.

### Procedural Success

A total of 30 of the 31 stents (97%) were successfully implanted (26 were BX Isostent and 4 were Palmaz-Schatz) in 26 patients. One stent (BX) was lost in the peripheral circulation without clinical sequelae. Eighteen patients were successfully treated with a single radioactive stent, and 4 required a second radioactive stent to cover lesions >15 mm. Five patients received additional nonradioactive stents: 2 due to procedural dissection not covered by the radioactive stent, 2 because a second radioactive stent was not available, and 1 because a second radioactive stent became dislodged when trying to implant it distal to the first radioactive stent. All procedures were successful, and no complications occurred.

**TABLE 2. Patient Demographics**

Sex, male/female	18/8 (69/31%)
Age, y	
Average	60
Range	43–74
Risk factors	
Diabetes mellitus	1 (4%)
Hypercholesterolaemia	16 (62%)
Hypertension	11 (42%)
Smoking	15 (58%)
Family history	11 (42%)
AP CCS	
2	3 (12%)
3	10 (38%)
4	13 (50%)
Lesion type, AHA/ACC	
B1	8 (31%)
B2	18 (69%)

Data are n (%) unless otherwise indicated. AHA indicates American Heart Association, and ACC, American College of Cardiology.

### Follow-Up

The mean hospital stay was 1.8 days. All patients were angina-free at hospital discharge. At 30-day follow-up, no clinical end points had occurred: 24 patients (92%) were asymptomatic, and 2 patients (8%) had recurrent angina pectoris (AP) of Canadian Cardiovascular Society Classification (CCS) 1 (n=1) and CCS 2 (n=1). All 26 patients returned for 6-month clinical follow-up. Twenty-one (81%) were asymptomatic, and 5 patients (19%) had AP CCS 1 (n=1), CCS 2 (n=2), CCS 3 (n=1), or CCS 4 (n=1).

Six-month angiographic follow-up was performed in 23 patients (88%). The remaining 3 patients (12%) refused: 2 of them were asymptomatic, and the third had AP CCS 1. Four patients had angiographic restenosis (17%). All restenotic lesions were diffuse (located throughout the entire length of the stent). One of the 4 restenoses occurred in a patient with a single radioactive stent, 1 restenosis was in a patient receiving 2 radioactive stents in combination with a nonradioactive stent, and 2 restenoses were observed in patients receiving a combination of 1 radioactive and 1 nonradioactive stent. In the restenotic patients who received an additional nonradioactive stent, restenosis occurred in both the radioactive and the nonradioactive stent. On QCA, no discernible differences existed between the patterns of proliferation between the Palmaz-Schatz and BX stents. No cases of restenosis at the stent edges were noted. Two of the 4 restenotic patients underwent a re-PTCA. One was referred for bypass surgery for in-stent restenosis in the proximal left anterior descending coronary artery and progression of a previously nonsignificant lesion in the proximal left circumflex artery (main stem equivalent). One was treated medically; this patient was asymptomatic, with a negative stress test. No other clinical end points existed at 6-month follow-up.

TABLE 3. Dosimetry and QCA Analyses

Patient	Type of Stent	Activity, $\mu$ Ci	Dose, cGy	Artery	Lesion Length, mm	Preintervention			Postintervention			Follow-Up			Acute Gain	Late Loss	LLI
						MLD	DS	RD	MLD	DS	RD	MLD	DS	RD			
1	PS‡	1.07	712	RCA	17	0.65	76	2.64	2.48	19	3.04	1.74	30	2.51	1.83	0.74	0.40
2	PS	1.07	712	LAD	11	1.02	52	2.12	2.56	8	2.78	0.54	77	2.39	1.54	2.02	1.31
3	PS	0.97	647	LCX	10	0.46	85	3.05	2.93	15	3.41	2.77	18	3.36	2.47	0.16	0.06
4	PS	0.97	647	RCA	15	0.75	79	3.50	2.91	22	3.73	1.60	47	3.01	2.16	1.31	0.61
5	BX*	1.07	712	LAD	15	0.90	59	2.22	2.80	9	3.07	0.47	87	3.61	1.90	2.33	1.23
6	BX	1.50	1000	RCA	12	1.64	53	3.49	3.06	15	3.59	2.45	23	3.18	1.42	0.61	0.43
7	PS	0.75	500	LAD	11	0.67	75	2.67	2.64	15	3.12	1.58	39	2.58	1.97	1.07	0.54
8	BX	1.24	824	RCX	10	0.99	74	3.65	3.51	19	4.31	2.76	44	4.20	2.52	0.75	0.30
9	BX	1.12	748	RCX	14	0.50	77	2.08	1.92	12	2.19	1.77	26	2.39	1.43	0.16	0.11
10	BX	1.73	1157	LAD	19	0.99	71	3.31	3.18	18	3.87	2.39	16	2.82	2.19	0.79	0.36
11	BX*	0.88	587	LAD	8	0.59	79	2.73	3.42	17	4.11	2.65	20	3.32	2.83	0.77	0.27
12	BX†*	1.24	827	LAD	17	1.00	58	2.37	2.36	16	2.81	0.86	55	1.90	1.37	1.51	1.10
13	BX*	1.36	908	LAD	17	0.69	72	2.45	2.48	14	2.87	1.73	11	1.94	1.80	0.76	0.42
14	BX	1.12	748	LAD	14	0.62	79	2.96	2.75	12	3.12	1.61	44	2.86	2.13	1.15	0.54
15	BX	1.02	678	RCX	7	0.49	83	2.81	3.03	16	3.59	2.20	25	2.91	2.54	0.83	0.33
16	BX	1.06	712	LAD	10	1.10	67	3.36	3.27	10	3.63	1.87	34	2.81	2.17	1.41	0.65
17	BX	1.43	953	RCA	12	0.85	75	3.44	2.92	9	3.19	0.83	70	3.29	2.07	2.09	1.01
18	BX†	1.00	678	RCA	23	0.83	73	3.08	2.99	5	3.07	2.51	28	3.47	2.15	0.48	0.22
19	BX	1.02	677	RCX	10	0.96	71	3.28	2.90	17	3.50	2.87	17	3.46	1.94	0.03	0.02
20	BX†	0.75	500	LAD	15	1.13	60	2.81	2.81	17	2.81	1.97	39	3.23	1.69	0.84	0.50
21	BX	1.43	953	RCX	12	1.23	62	3.31	2.89	21	3.61	2.03	39	3.34	1.66	0.85	0.51
22	BX	1.06	700	RCA	10	1.16	66	3.37	2.91	9	3.18	1.72	45	3.12	1.75	1.20	0.68
23	BX†	0.75	500	RCA	16	0.90	68	2.75	2.66	23	3.45	1.73	42	2.99	1.76	0.93	0.53
Mean		1.10	743		13	0.87	70	2.93	2.84	15	3.31	1.85	38	2.99	1.97	0.99	0.53
SD		0.25	165		4	0.28	9	0.47	0.35	5	0.48	0.69	20	0.54	0.39	0.59	0.35

Dose indicates dose over 100 days at 1 mm from the stent surface; DS, percentage diameter stenoses; LAD, left anterior descending artery; LCX, left circumflex artery; LLI, late loss index; PS, Palmaz-Schatz stent; RCA, right coronary artery; and RD, reference diameter. QCA measurements are in mm.

\*1 additional nonradioactive stent implanted; †2 BX stents implanted; ‡2 additional nonradioactive stents implanted.

**QCA Measurements**

QCA and procedural data are presented in Table 3. MLD increased from  $0.87 \pm 0.28$  mm preprocedure to  $2.84 \pm 0.35$  mm postprocedure ( $P < 0.0001$ ). MLD at follow-up was  $1.85 \pm 0.69$  mm ( $P < 0.0001$  relative to post-procedure), resulting in a late loss index of  $0.53 \pm 0.35$ . Segmental analysis of the mean diameter of the 5-mm segments distal and proximal to the stent edges showed significant changes. The proximal diameter decreased from  $3.19 \pm 0.42$  mm postprocedure to  $2.78 \pm 0.62$  mm at follow-up ( $P = 0.006$ ). The distal diameter decreased from  $2.69 \pm 0.49$  mm postprocedure to  $2.45 \pm 0.50$  mm at follow-up ( $P = 0.0167$ ).

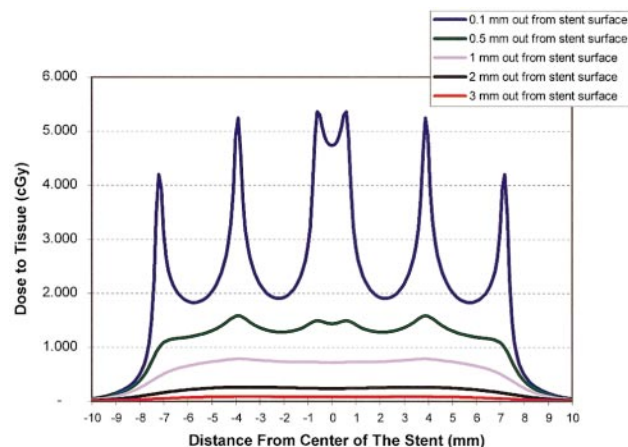
**Radiation Doses**

Stent activity level and the cumulative dose over 100 days that was delivered to a 1 mm depth outside the stent are presented in Table 3. No correlation existed between stent activity or delivered dose and MLD or late loss index at follow-up. No additional environmental radiation was measured during the procedure.

**Discussion**

This nonrandomized study illustrates that  $\beta$ -particle-emitting radioactive stent implantation is safe and feasible, with no subacute or 30-day clinical events recorded. Subacute thrombosis was not seen, despite the concern regarding delay in endothelialization, as previously reported in animal studies.<sup>20,23</sup> The embolization of the radioactive stent had no clinical sequelae at this level of activity. When stents with higher levels of radioactivity are implanted, this may not remain true. Detecting an embolized radioactive stent is a problem because (1) the  $\beta$ -radiation of the stent is not measurable outside the body and (2) the stents have a relatively low radiopacity. Clearly, there is room to increase the radiopacity or to add markers to the stents.

Using a multivariate model constructed from the data of the Benestent trials that was based on similar lesions, vessel size, and short-term result, a predicted restenosis rate of 12% and an MLD at follow-up of 2.05 mm was calculated.<sup>30,31</sup> Thus, the actual results achieved are somewhat less favorable; however, in such a small patient cohort, no definite conclusions can be drawn except that the late results are within the



**Figure 1.** Two-dimensional dose representation for 1- $\mu\text{Ci}$   $^{32}\text{P}$  Palmaz-Schatz stent. Cumulative dose given over 100 days is shown (source, Isostent Inc).

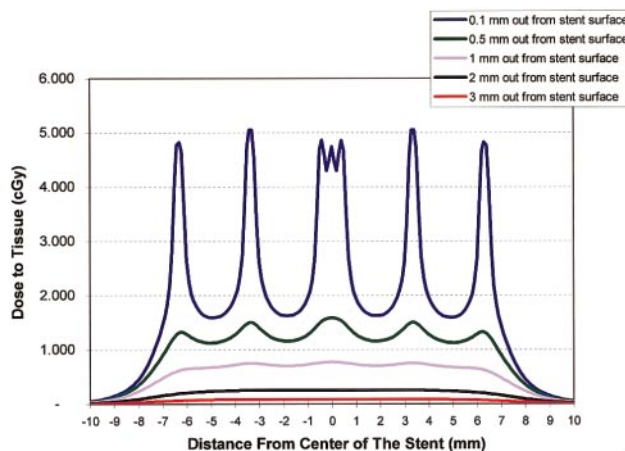
acceptable limits for safety and feasibility of this stent. It must be noted that 3 of the 4 patients who had in-stent restenosis had multiple stents implanted, which increases the risk of restenosis; in the group of 18 patients who had a single radioactive stent implanted, only 1 had restenosis. Overall, these 6-month clinical and angiographic results are similar to the published results of nonradioactive stents.<sup>10,11</sup>

The Milan group was the first to report restenosis within the stent and at the edges of the stent (the candy-wrapper phenomenon); this restenosis was possibly caused by increased balloon injury (barotrauma) and the lower radiation dose at the stent edges.<sup>21,28</sup> In the Rotterdam series, particular attention was paid to avoiding balloon injury outside the stent to minimize the edge effect. No cases of edge restenosis were seen in this cohort; however, the proximal and distal mean diameter at the stent edges, measured postprocedure and at follow-up, decreased significantly. Because extreme care was taken to avoid inflating the balloon outside the stent edges, this edge effect may be caused by the lower radiation dose.

### Dosimetry

Previous work by Janicki et al<sup>32</sup> on the 1.0- $\mu\text{Ci}$  Palmaz-Schatz stent demonstrated the nonuniformity of dosing in areas adjacent to stent strut wires and those areas between the wires. Models showed that for a  $^{32}\text{P}$  stent of 1.0  $\mu\text{Ci}$  that was 15 mm in length, at a distance of 0.1 mm, dose values of 2500 cGy were delivered at the strut wires (peaks) and 800 cGy between the wires (valleys) over 1 half-life (14.3 days). The nonuniformity of dosing, reflective of stent geometry, decreased at distances 1 to 2 mm from the stent surface. Although these data provide an in-vitro analysis of dosing from a radioactive stent, the actual dose distribution is probably affected by variations in atherosclerotic plaque morphology and the symmetry of the lesion and stent expansion. The 2D dosimetry representation of the Palmaz-Schatz and BX stent were done using the Janicki model<sup>32</sup> (Figures 1 and 2).

Currently, dose-finding studies examining restenosis after implantation of  $^{32}\text{P}$  BX stents in patients with lesion morphology similar to that described in this study are underway. It is



**Figure 2.** Two-dimensional dose representation for 1- $\mu\text{Ci}$   $^{32}\text{P}$  BX stent. Cumulative dose given over 100 days is shown (source, Isostent Inc).

possible that increased doses will decrease in-stent restenosis, as has been described in animal studies.<sup>21–23</sup> Therefore, a European Dose Response trial has been started with activities ranging from 1.5 to 3, 3 to 6, 6 to 12, and 12 to 20  $\mu\text{Ci}$ .

### Conclusion

This study reports that the implantation of  $\beta$ -particle-emitting radioactive stents with an activity of 0.75 to 1.5  $\mu\text{Ci}$  is safe and feasible.

### Acknowledgments

The Wenckebach prize was awarded to P.W. Serruys by the Dutch Heart Foundation; it is used for brachytherapy research in the catheterization laboratory. Dr Kay is supported by the National Heart Foundation of New Zealand. The authors appreciate the efforts of the catheterization laboratory staff, the radiation staff, and the Department of clinical epidemiology.

### References

- Holmes DR Jr, Vlietstra RE, Smith HC, Vetrovec GW, Kent KM, Cowley MJ, Faxon DP, Gruentzig AR, Kelsey SF, Detre KM. Restenosis after percutaneous transluminal coronary angioplasty (PTCA): a report from the PTCA Registry of the National Heart, Lung, and Blood Institute. *Am J Cardiol.* 1984;53:77C–81C.
- Serruys PW, Luijten HE, Beatt KJ, Geuskens R, de Feyter PJ, van den Brand M, Reiber JH, ten Katen HJ, van Es GA, Hugenholtz PG. Incidence of restenosis after successful coronary angioplasty: a time-related phenomenon: a quantitative angiographic study in 342 consecutive patients at 1, 2, 3, and 4 months. *Circulation.* 1988;77:361–371.
- Mintz GS, Pichard AD, Kent KM, Satler LF, Popma JJ, Leon MB. Intravascular ultrasound comparison of restenotic and de novo coronary artery narrowings. *Am J Cardiol.* 1994;74:1278–1280.
- Currier JW, Faxon DP. Restenosis after percutaneous transluminal coronary angioplasty: have we been aiming at the wrong target? *J Am Coll Cardiol.* 1995;25:516–520.
- Mintz GS, Popma JJ, Pichard AD, Kent KM, Satler LF, Wong C, Hong MK, Kovach JA, Leon MB. Arterial remodeling after coronary angioplasty: a serial intravascular ultrasound study. *Circulation.* 1996;94:35–43.
- Nobuyoshi M, Kimura T, Ohishi H, Horiuchi H, Nosaka H, Hamasaki N, Yokoi H, Kim K. Restenosis after percutaneous transluminal coronary angioplasty: pathologic observations in 20 patients. *J Am Coll Cardiol.* 1991;17:433–439.
- MacLeod DC, Strauss BH, de Jong M, Escaned J, Umans VA, van Suylen RJ, Verkerk A, de Feyter PJ, Serruys PW. Proliferation and extracellular matrix synthesis of smooth muscle cells cultured from human coronary atherosclerotic and restenotic lesions. *J Am Coll Cardiol.* 1994;23:59–65.

8. Guarda E, Katwa LC, Campbell SE, Tanner MA, Weibel RM, Laughlin H, Jenkins S, Myers PR. Extracellular matrix collagen synthesis and degradation following coronary balloon angioplasty. *J Mol Cell Cardiol.* 1996; 28:699–706.
9. Hamon M, Bauters C, McFadden EP, Wernert N, Lablanche JM, Dupuis B, Bertrand ME. Restenosis after coronary angioplasty. *Eur Heart J.* 1995;16(suppl I):33–48.
10. Serruys PW, de Jaegere P, Kiemeneij F, Macaya C, Rutsch W, Heyndrickx G, Emanuelsson H, Marco J, Legrand V, Materne P. A comparison of balloon-expandable-stent implantation with balloon angioplasty in patients with coronary artery disease: Benestent Study Group. *N Engl J Med.* 1994;331:489–495.
11. Fischman DL, Leon MB, Baim DS, Schatz RA, Savage MP, Penn I, Detre K, Veltri L, Ricci D, Nobuyoshi M. A randomized comparison of coronary-stent placement and balloon angioplasty in the treatment of coronary artery disease. Stent Restenosis Study Investigators. *N Engl J Med.* 1994;331:496–501.
12. Haude M, Erbel R, Issa H, Meyer J. Quantitative analysis of elastic recoil after balloon angioplasty and after intracoronary implantation of balloon-expandable Palmaz-Schatz stents. *J Am Coll Cardiol.* 1993;21:26–34.
13. Dussaillant GR, Mintz GS, Pichard AD, Kent KM, Satler LF, Popma JJ, Wong SC, Leon MB. Small stent size and intimal hyperplasia contribute to restenosis: a volumetric intravascular ultrasound analysis. *J Am Coll Cardiol.* 1995;26:720–724.
14. Kovalic JJ, Perez CA. Radiation therapy following keloidectomy: a 20-year experience. *Int J Radiat Oncol Biol Phys.* 1989;17:77–80.
15. Sylvester JE, Greenberg P, Selch MT, Thomas BJ, Amstutz H. The use of postoperative irradiation for the prevention of heterotopic bone formation after total hip replacement. *Int J Radiat Oncol Biol Phys.* 1988;14: 471–476.
16. Wiedermann JG, Marboe C, Amols H, Schwartz A, Weinberger J. Intracoronary irradiation markedly reduces restenosis after balloon angioplasty in a porcine model. *J Am Coll Cardiol.* 1994;23:1491–1498.
17. Waksman R, Robinson KA, Crocker IR, Gravanis MB, Cipolla GD, King SB 3rd. Endovascular low-dose irradiation inhibits neointima formation after coronary artery balloon injury in swine: a possible role for radiation therapy in restenosis prevention. *Circulation.* 1995;91:1533–1539.
18. Wiedermann JG, Marboe C, Amols H, Schwartz A, Weinberger J. Intracoronary irradiation markedly reduces neointimal proliferation after balloon angioplasty in swine: persistent benefit at 6-month follow-up. *J Am Coll Cardiol.* 1995;25:1451–1456.
19. Liermann D, Bottcher HD, Kollath J, Schopohl B, Strassmann G, Strecker EP, Breddin KH. Prophylactic endovascular radiotherapy to prevent intimal hyperplasia after stent implantation in femoropopliteal arteries. *Cardiovasc Intervent Radiol.* 1994;17:12–16.
20. Hehrlein C, Gollan C, Donges K, Metz J, Riessen R, Fehsenfeld P, von Hodenberg E, Kubler W. Low-dose radioactive endovascular stents prevent smooth muscle cell proliferation and neointimal hyperplasia in rabbits. *Circulation.* 1995;92:1570–1575.
21. Hehrlein C, Stintz M, Kinscherf R, Schlosser K, Huttel E, Friedrich L, Fehsenfeld P, Kubler W. Pure  $\beta$ -particle-emitting stents inhibit neointima formation in rabbits. *Circulation.* 1996;93:641–645.
22. Carter AJ, Laird JR, Bailey LR, Hoopes TG, Farb A, Fischell DR, Fischell RE, Fischell TA, Virmani R. Effects of endovascular radiation from a beta-particle-emitting stent in a porcine coronary restenosis model: a dose-response study. *Circulation.* 1996;94:2364–2368.
23. Carter AJ, Laird JR. Experimental results with endovascular irradiation via a radioactive stent. *Int J Radiat Oncol Biol Phys.* 1996;36:797–803.
24. Haase J, Escaned J, van Swijndregt EM, Ozaki Y, Gronenschild E, Slager CJ, Serruys PW. Experimental validation of geometric and densitometric coronary measurements on the new generation Cardiovascular Angiography Analysis System (CAAS II). *Cathet Cardiovasc Diagn.* 1993;30:104–114.
25. Di Mario C, Hermans WR, Rensing BJ, Serruys PW. Calibration using angiographic catheters as scaling devices: importance of filming the catheters not filled with contrast medium. *Am J Cardiol.* 1992;69: 1377–1378.
26. Serruys PW, Foley DP, de Feyter PJ. *Quantitative Coronary Angiography in Clinical Practice.* Dordrecht: Kluwer Academic Publishers; 1994.
27. Kuntz RE, Gibson CM, Nobuyoshi M, Baim DS. Generalized model of restenosis after conventional balloon angioplasty, stenting and directional atherectomy. *J Am Coll Cardiol.* 1993;21:15–25.
28. Albiero R, Di Mario C, van der Giessen WJ, De Gregorio J, Kobayashi N, Wardeh AJ, Amato A, Coen VLMA, Serruys PW, Colombo A. Procedural results and 30-day clinical outcome after implantation of  $\beta$ -particle emitting radioactive stents in human coronary arteries. *Eur Heart J.* 1998;19:457.
29. Blackburn H, Keys A, Simonson E, Rautaharju P, Punsar S. The electrocardiogram in population studies: a classification system. *Circulation.* 1960;21:1160–1175.
30. Serruys PW, Kay P, Deshpande NV, de Feyter PJ. Periprocedural QCA following Palmaz-Schatz stent implantation predicts restenosis rate at 6 months: results of a meta-analysis of Benestent I, Benestent II pilot, Benestent II, and MUSIC trials. *J Am Coll Cardiol.* In press.
31. Serruys PW, Emanuelsson H, van der Giessen W, Lunn AC, Kiemeneij F, Macaya C, Rutsch W, Heyndrickx G, Suryapranata H, Legrand V, Goy JJ, Materne P, Bonnier H, Morice MC, Fajadet J, Belardi J, Colombo A, Garcia E, Ruygrok P, de Jaegere P, Morel MA. Heparin-coated Palmaz-Schatz stents in human coronary arteries: early outcome of the Benestent-II Pilot Study. *Circulation.* 1996;93:412–422.
32. Janicki C, Duggan DM, Coffey CW, Fischell DR, Fischell TA. Radiation dose from a phosphorous-32 impregnated wire mesh vascular stent. *Med Phys.* 1997;24:437–445.