

“Benign” early repolarization versus malignant early abnormalities: Clinical-electrocardiographic distinction and genetic basis

Andrés Ricardo Pérez-Riera¹, Luiz Carlos de Abreu², Frank Yanowitz³,
 Raimundo Barbosa Barros⁴, Francisco Femenía⁵, William F. McIntyre⁶, Adrian Baranchuk⁶

¹ABC Faculty of Medicine, ABC Foundation, Santo André, Sao Paulo, Brazil

²Federal University of Sao Paulo (UNIFESP), Sao Paulo, SP, Brazil

³University of Utah School of Medicine and Intermountain Healthcare, Salt Lake City, Utah, USA

⁴Coronary Center Hospital de Messejana Dr. Carlos Alberto Studart Gomes Fortaleza, Ceará, Brazil

⁵Unidad de Arritmias, Departamento de Cardiología, Hospital Espanol de Mendoza, Argentina

⁶Heart Rhythm Service, Queen’s University, Kingston, Ontario, Canada

Abstract

In the great majority of cases the ECG pattern of early repolarization (ERP) is a benign phenomenon observed predominantly in teenagers, young adults, male athletes and the black race. The universally accepted criterion for its diagnosis is the presence, in at least two adjoining leads, of ≥ 1 mm or 0.1 mV ST segment elevation. In benign ERP reciprocal ST segment changes are possible only in lead aVR. In contrast, reciprocal ST segment changes can be observed in several leads in idiopathic ventricular fibrillation (IVF) and acute coronary syndrome. In benign ERP the ST segment and T wave patterns have a relative temporal stability.

IVF is an entity with low prevalence, possibly familiar, and characterized by the occurrence of VF events in a young person. More frequently this occurs in male subjects without structural heart disease and with otherwise with normal ECG even using high right accessory leads and/or after ajmaline injection. Several clinical entities cause ST segment elevation include asthenic habitus, acute pericarditis, ST segment elevation myocardial infarction, Brugada syndrome, congenital short QT syndrome, and idiopathic VF. In these circumstances clinical and ECG data are most important for differential diagnosis. In IVF the modifications could be dramatic and predominantly at night during vagotonic predominance when J waves > 2 mm in amplitude. The ST/T abnormalities are dynamic, inconstant, and reversed with isoproterenol.

Convex upward J waves, with horizontal/descending ST segments or “lambda-wave” ST shape are suggestive of IVF with early repolarization abnormalities. Premature ventricular contractions with very short coupling and “R on T” phenomenon are characteristics with two pattern: When originate from right ventricular outflow tract left bundle branch block morphology and from peripheral Purkinje network, left bundle branch block pattern. The inherited-familial forms are not frequent in IVF; however mutations were identified in the genes KCNJ8, DPP6, SCN5A, SCN3B, CACNA1C, CACNB2, and CACNA2D1.

The management of IVF has class I indication for ICD implantation. Ablation therapy is considered additional to ICD implantation in those patients with repetitive ventricular arrhythmia. Quinidine is a highly efficient drug that prevents recurrence. (Cardiol J 2012; 19, 4: 337–346)

Key words: early repolarization pattern, idiopathic ventricular fibrillation, early repolarization syndrome

Address for correspondence: Andrés Ricardo Pérez-Riera, MD, PhD, ABC Faculty of Medicine, ABC Foundation, Sebastiao Afonso 885 CEP: 04417-100, Sao Paulo, Brazil, tel: (011) 56212390, e-mail: riera@uol.com.br

Received: 30.03.2012

Accepted: 28.04.2012

The so-called very common benign early repolarization pattern

Early repolarization pattern (ERP) is an enigmatic common electrocardiographic (ECG) finding, occurring in 1% to 2% of the general population [1] with preponderance in men, young adults, adolescent Africans [2], Afro-descendants (African Americans), and athletes's preponderance. There is a decreasing prevalence of ERP with advancing age. The ST-segment elevation in ERP is typical of the athlete's ECG. High T wave voltages and predominant U waves are frequent ECG findings along with sinus bradycardia in athletes. The frequency of J-point or J wave elevation among young athletes is intermediate (higher than seen in healthy adults but lower than seen in patients with idiopathic ventricular fibrillation (IVF) [3].

Although ERP is more prevalent in African Americans, it is not predictive of cardiovascular death in this population, and it may represent a distinct electrophysiological phenomenon [4].

On the 12-lead ECG the ERP is characterized as "notching" or "slurring" of the terminal portion of the R wave and beginning of the ST-segment (i.e., the J point*) that produces a positive hump known as J wave. The J wave is a deflection with a dome that appears immediately after the end of QRS complex followed by ST-segment elevation ≥ 0.1 mV (or 1 mm, varying from 1 to 4 mm) above isoelectric line (relative to the subsequent TP interval) concave upward in at least two contiguous ECG leads. This ECG finding is most frequently seen in the precordial leads from V3 to V5 and often in the inferior leads II, III, and aVF.

ST-segment elevation is occasionally seen only in right precordial leads or only in the inferior leads [5]. Additionally, the ST-segment elevation is followed by a large, upright and symmetrical T wave with a broad base (similar in shape on ascending and descending limb) [6].

In benign ERP reciprocal (or mirror image) ST-segment depression is only seen in lead aVR. The presence of ST segment depression in several other leads strongly suggests the diagnosis of ST segment elevation myocardial infarction (STEMI). In these cases, reciprocal ST segment depression is of considerable value in establishing the ECG diagnosis of STEMI [7]. Figure 1 shows the typical features of benign ERP. ERP pattern has been considered a benign and normal ECG variant for over six decades [8].

Critical observations. The J point is sometimes used as a marker for the end of ventricular depolarization. Comparison of the ECG waveform

with the complete body-surface potential distribution or, when available, epicardial electrograms, shows that the J point only approximately marks the end of depolarization with an overlap of potentials ending depolarization and beginning repolarization from 4 to 16 ms [9, 10]. Standard precordial leads do not accurately predict maximal torso potentials during the S-T segment, and the degree of overlap between repolarization and depolarization is not a major determinant of precordial voltage. Hence, the term "early repolarization" in healthy individuals to describe this ECG pattern is not substantiated.

Differential diagnosis of "benign" early repolarization pattern

Normal ERP should be differentiated from others conditions with ST segment elevation such as asthenic habitus [11, 12], acute pericarditis, STEMI, Brugada syndrome (BrS), congenital short QT syndrome (SQTS), and IVF. Additionally, it is important to include in the differential diagnosis others channelopathies without ST-segment elevation but with unexpected syncope and cardiac arrest such as congenital Long QT syndrome (LQTS) and catecholaminergic polymorphic ventricular tachycardia (VT). In ERP the ST-segment elevation tends to persist unchanged for a period of years, whereas ST-segment elevation in acute pericarditis and STEMI evolves over a period of days to weeks.

In BrS ST-segment elevation is confined to the right precordial leads, is convex upward with a rectilinear descendent and negative T wave (type 1 ECG Brugada pattern, Brugada phenotype or Brugada sign). Additionally, this ECG pattern can be transient, intermittent and is frequently not present in the standard precordial leads. It is sometimes necessary to perform accessory high right precordial leads in the third and second intercostal spaces in suspected or uncertain cases. The high right precordial leads are more sensitive than the conventional 12-lead ECG alone, and initial observations suggest that they remain specific for BrS, while standard and high lead V3 offer redundant data. A vertical relationship of type 1 pattern may have a similar diagnostic value to that of a horizontal pair [13].

Congenital SQTS is observed in young individuals with features of paroxysmal atrial fibrillation, syncope, and cardiac arrest. The ECG is characterized by extremely short QT intervals (QTc interval ≤ 330 ms) that are not significantly modified with heart rate changes (reduced QT interval adaptation to tachycardia during exercise). Also seen are very tall T waves with narrow bases resembling

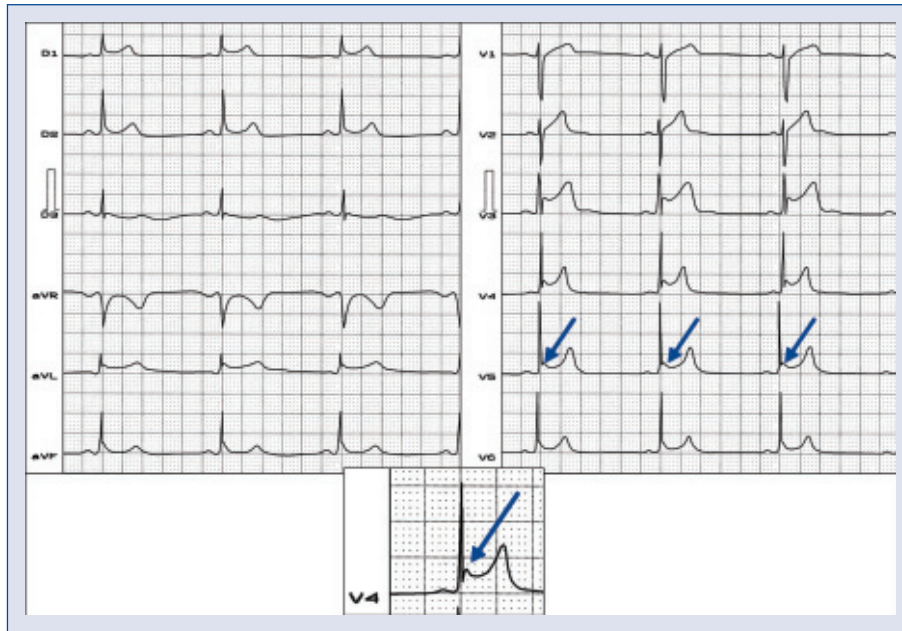


Figure 1. Typical features of early repolarization pattern. **Name:** DAS; **Age:** 24-year-old of age; **Sex:** Male; **Ethnic group:** Afro-descendant; **Weight:** 82 kg; **Height:** 1.91 m; **Biotype:** Athletic; **Occupation:** Professional basketball player; **ECG diagnosis:** Sinus bradycardia, (HR 50 bpm). “Notching” and “slurring” of the terminal portion of the R wave and beginning of the ST-segment, (J point/J wave) and ST-segment elevation (> 4 mm) in precordial leads from V3–V5 of concave upward. Above the isoelectric line (relative to the subsequent TP interval); **Conclusion:** Sinus bradycardia, early repolarization pattern.

the T wave in a “desert tent” pattern similar to those seen in hyperkalemia.

Congenital LQTS, like IVF, is present in young individuals with unexplained syncope or cardiac arrest. Syncope during exercise in pediatric patients should be considered malignant and suspected of LQT1 variant until otherwise ruled out. Family history of dizziness or deafness is sometimes a feature. LQTS is characterized by QT/QTc prolongation. If the QTc exceeds 440 ms in males and 460 ms in females, the QT interval should be considered as prolonged. Unfortunately, this feature has relative value because in 20% of cases of congenital LQTS the QTc interval is normal [14]. Another important ECG feature in the differential diagnosis of LQTS phenotypes is the characteristic morphology of the T wave: wide-based T-waves with large amplitude (LQT1), low amplitude bimodal or notched T waves (LQT2), and delayed appearance of T waves resulting from ST segment prolongation (LQT3). The hallmark arrhythmia of congenital LQTS is an atypical polymorphic VT called torsade de pointes. This VT is usually initiated by a premature ventricular complex (PVC) with delayed or telediastolic coupling but with R on T phenomenon, frequently after pauses (“long-short” sequence) or during slow

heart rates. The characteristic QRS pattern shows typical 180° rotation of the QRS axis around the baseline with phasic variations in polarity and width of QRS complexes. The VT may be suppressed by establishing a faster heart rate.

Catecholaminergic polymorphic VT is a rare clinically and genetically heterogeneous disease of uncertain etiology usually observed in the pediatric or juvenile age group. It is characterized by recurrent syncope or sudden cardiac death (SCD) after physical or acute emotional stress. Familial occurrence has been noted in about 30% of cases. Episodes of VT are usually precipitated by exercise or other adrenergic stressors. Bidirectional VT is characterized by beat-to-beat alternations of QRS morphologies around a 180° QRS axis. Some individuals also have polymorphic VT without beat-to-beat alterations in QRS complexes. The two genes in which mutations are currently known to cause catecholaminergic polymorphic VT are *RYR2* (autosomal dominant) and *CASQ2* (autosomal recessive). The presence of other as-yet unidentified loci is postulated. Molecular genetic testing for *RYR2* and *CASQ2* is available on a clinical basis.

Finally, in IVF the arrhythmias can be dramatic and occurring predominantly at night during vago-

tonic slowing of heart rate. J waves > 2 mm in amplitude in asymptomatic adults are associated with a threefold increased incidence of arrhythmic death during long-term follow-up. Individuals with J waves have some degree of increased dispersion of repolarization that places them at increased risk for arrhythmic death, but only in the presence of additional proarrhythmic factors or triggers. Convex upward J waves were present in 32% IVF patients [15]. In addition a “lambda-wave” ST segment shape can be seen [16, 17]. Horizontal and descending ST segments were observed in IVF by Rosso et al. [18].

In benign ERP the ST segment and T wave patterns have a relative temporal stability. Contrarily, in malignant early repolarization syndromes the ST/T waves are dynamic, inconstant, and dramatic changes in morphology are the rule. In contrast to benign ERP where T waves are large, positive and concordant from V2 to V4, in IVF T waves are discordant relative to the ST segment deviation. In benign ERP reciprocal ST changes are seen only in aVR, whereas in IVF mirror image ST segment changes can be observed in several leads.

Ventricular myocardium is composed of at least three electrophysiologically distinct cell types: epicardial, endocardial, and M cells. In ERP the ST segment elevation is attributed to shortening of ventricular action potential durations in epicardial regions resulting in a current similar to the subepicardial injury current of BrS and IVF. ST-segment elevation in a structurally normal heart is associated with a J wave which can be observed in benign ERP, IVF, and BrS. A transmural voltage gradient during early ventricular repolarization resulting from the presence of a prominent action potential notch (spike and dome) mediated by the transient outward potassium current (I_{to}) in epicardial cells but not endocardium, is responsible for the J wave on the ECG [19, 20]. This partially explains why exercise and isoproterenol infusion abolishes the ST segment elevation in benign ERP as well as in BrS and IVF patients [21].

In IVF the presence of PVCs with very short coupling and R-on-T phenomenon are characteristic features. Additionally, mapping of these PVCs show two different origins, which were confirmed by ablation [22]. Right ventricular outflow tract (RVOT) and right-sided peripheral Purkinje network PVCs have a left bundle branch block pattern with superior axis morphology, whereas left-sided Purkinje PVCs have a right bundle branch block pattern. The axis of activation show variation from inferior to superior depending on the area of origin from the Purkinje network and the exit site to the myocar-

dium. Purkinje network PVCs have shorter coupling interval and QRS durations relative to RVOT PVCs. Ablation of these typical PVC is feasible in order to reduce implantable cardioverter-defibrillator (ICD) shock. Recently, Mittadodla et al. [23] describe a previously healthy 32-year-old pregnant woman with recurrent IVF that failed to respond to standard therapy but terminated with isoproterenol infusion.

ERP with global ST segment elevation in the inferior, lateral, and right precordial leads is associated with increased risk for life-threatening arrhythmias. This lethal entity is named the early repolarization syndrome (ERS). ERS and BrS share similar ECG characteristics, clinical outcomes, risk factors, as well as a common arrhythmic platform related to amplification of I_{to} -mediated J waves. Although BrS and ERS differ with respect to the magnitude and lead location of abnormal J waves, according to Antzelevitch and Yan [24], both represent a continuous spectrum of phenotypic expression termed J-wave syndromes. These authors proposed three subtypes: Type 1: ERS observed predominantly in the lateral precordial leads, prevalent among healthy male athletes and rarely seen in IVF survivors; Type 2: ERS predominantly in the inferior or inferolateral leads and associated with a higher level of risk; Type 3: ERS globally in the inferior, lateral, and right precordial leads and associated with the highest level of risk for development of malignant arrhythmias. Type 3 is often associated with IVF storms.

Benign ERP is an ECG finding characterized by a distinct J wave and ST-segment elevation in precordial leads V4–V6. In contrast, IVF is characterized by J waves and ST-segment elevation in the inferior, inferolateral or globally in the precordial leads, and the BrS is confined only in right precordial leads. These two entities are the leading causes for SCD in young Southeast Asian males. The underlying mechanism for such a difference in clinical consequences among these syndromes is due to a difference in I_{to} density and I_{to} -mediated epicardial spike and dome configuration. When I_{to} is prominent, complete loss of the dome may occur due to either a decrease in inward currents or an increase in outward currents leading to phase 2 reentry capable of initiating ventricular fibrillation (VF) as in IVF and the BrS. When I_{to} is relatively small as in the ERP, partial depression of the dome occurs without the development of phase 2 reentry [25].

Type 0 ECG Brugada pattern (coved-type ST elevation without a negative T wave) is characterized by loss-of-dome type action potentials. The conversion from type 0 to type 1 ECG pattern (spike-and-dome action potentials) results in sig-

nificant action potential heterogeneity that can initiate VF in BrS [26].

ERP and BrS share many remarkable cellular, ionic, and ECG similarities and behave similarly in terms of their response to heart rate, pharmacologic agents, and neuromodulation. The extent to which ERP and BrS may overlap remains unclear. Recently, we presented an illustrated case of a symptomatic patient whose ECG signature evolved spontaneously from ERP alone to ERP with a concomitant Brugada type 1 ECG pattern over a short number of days. This case lends further strength to the notion that these 2 ECG patterns may be more closely related than had been initially thought [27].

IVF is an arrhythmogenic entity characterized by spontaneous VF occurring in patients with structurally normal hearts [28]. It is a functional abnormality or a pure electrical entity as demonstrated by transthoracic echocardiography and coronary angiography. On the ECG frequent J-wave elevation is seen in the inferolateral leads. These are strongly augmented during bradycardia, increased vagal activity, and with nocturnal predominant occurrence [29]. As a result unexplained syncope and sudden death occurs mostly during sleep. Early repolarization is present in a significant proportion of patients with IVF [30]. It is often intermittent and can be more pronounced in IVF patients. Additionally, the QTc interval duration is between 340 ms and 440 ms. Viskin et al. [31] observed that 35% of men who were classified as patients with IVF presented a QTc interval < 360 ms compared with only 10% of healthy control subjects.

Incidence. The annual incidence of SCD has been decreasing during the second half of the 20th century coinciding with the decreased mortality from coronary artery disease. In the United States it is in the range of 180,000 to 250,000 cases per year. It is still an important public-health problem with multiple etiologies, risk factors, and changing temporal trends [3]. In this population 90% to 95% have documented structural heart disease. It is estimated that IVF accounts for 9000 or 12,500 cases of SCD per year in the United States [19, 32]. Patients who die of SCD without structural heart disease are usually younger than 40 years of age.

Mechanism and genetic basis of idiopathic ventricular fibrillation

Perez et al. [4] demonstrated spatial heterogeneity of action potential durations between the shorter monophasic action potential durations of the right ventricular apex and the longer action poten-

tials of the RVOT. Such spatial heterogeneity and its restitution may facilitate functional reentry, predisposing to VF.

A growing number of sporadic case reports, basic electrophysiology research, and case-control studies indicate that in some ERP variants inferolateral J-waves are related to an increased risk of IVF and SCD. Haissaguerre et al. [33] studied data from 206 patients who were resuscitated from cardiac arrest due to IVF, compared to 412 age-, sex-, race-, and physical activity-matched controls without structural heart disease. Patients with short or long QT intervals and BrS were excluded. ERP was observed in 64 (31%) of 206 patients compared to 21 (5%) of 412 controls. The magnitude of ERP in cases was 2.0 mm vs. 1.2 mm in controls. After adjustment for age, sex, race, and level of physical activity, the odds ratio for the presence of ERP in cases compared to controls was 10.9 (95% confidence interval 6.3–18.9). Patients with ERP were more likely to be male, to have events during sleep, and to have a shorter QTc intervals than those without ERP. All patients had an ICD implanted. Arrhythmic recurrences were more frequent in patients with ERP than in those without (41% vs. 23%, respectively). Of the 64 patients with ERP, 10 had a family history of SCD. Among patients with a history of IVF, there is an increased prevalence of ERP. Myerburg and Castellanos [34] noted that case-control associations do not prove causality, and until prospective population data were available physicians should continue to view this common ECG variant as benign. However careful attention should be paid to patients with ERP and J-point elevations > 2.0 mm, particularly in patients with otherwise unexplained arrhythmias or a family history of unexplained SCD. Subsequent studies reinforced Haissaguerre results [6, 18]. Additionally, ERP seems to be associated with ventricular tachyarrhythmias in the setting of acute myocardial infarction [35]. The presence of J waves on ECGs is related to IVF with the eponym “Le Syndrome d’Haissaguerre” [36]. Figure 2 shows a personal case report, published in 2004 [17].

Abe et al. [15] enrolled 22 IVF patients divided into two groups according to the presence or absence of J waves. The following risk markers were assessed: late potentials (LPs) — a depolarization abnormality marker for 24 h using a newly developed signal-averaging system, T-wave alternans, QT dispersion — a repolarization abnormality marker, and frequency-domain heart rate variability reflecting autonomic modulation. The results were compared to 30 control subjects with J waves and 30 control

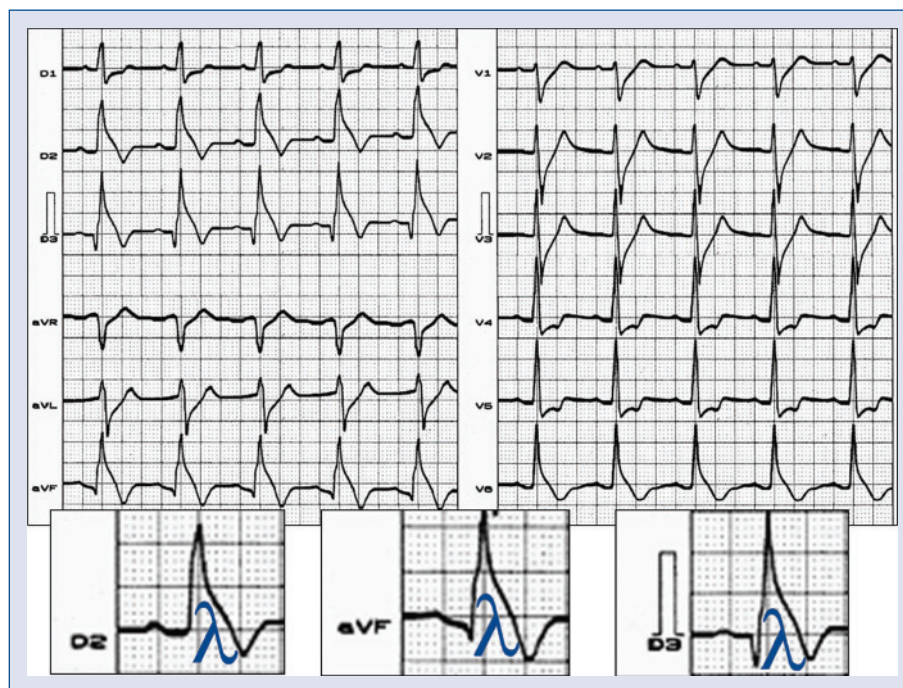


Figure 2. History: The patient was a young symptomatic (repetitive syncope episodes) Thailand man, with positive familial background of sudden cardiac death in young first degree relatives. He died 24 h after this ECG was performed. **ECG diagnosis:** Downsloping ST segment elevation is present in inferior and apical (V6) leads. Idiopathic J waves or Osborn wave. Mirror image seen in anterior wall. Absence of hypothermia, ischemia or electrolytic disorders. This J wave was labeled by Gussak as “lambda-wave” [16] because of its similarity with the Greek small lambda letter.

subjects without J waves, matched for age and gender to the IVF patients. J waves were present in 32% IVF patients. The incidence of LPs in the IVF J-wave group was higher than in the IVF non-J-wave group. Repolarization abnormality markers did not differ between the two groups. In the IVF J-wave group, dynamic changes in LP parameters, fQRS, RMS (40), LAS (40), were observed and were pronounced at nighttime; this was not the case in the IVF non-J-wave group and the control J-wave group. High-frequency components (vagal tone index) on frequency-domain heart rate variability analysis were associated with J waves in IVF patients. IVF patients with J waves had a high incidence of LP showing circadian variation with night ascendancy. J waves may be more closely associated with depolarization abnormality and autonomic modulation than with repolarization abnormality. The authors conclude that IVF patients with J waves had a high incidence of LPs showing circadian variation with night-time predominance. J waves may be more closely associated with depolarization abnormality and autonomic modulation than with repolarization abnormality.

Gussak et al. [37] reported four cases of IVF in individuals with a family history of SCD that exhibited very short QT intervals. They labeled the disease: SQTS. A short QT interval has also been noticed in some patients with other arrhythmic syndromes such as IVF, BrS and ERP. There is a high prevalence of ERP in patients with SQTS. ERP may be useful in identifying risk of cardiac events in SQTS [38], but the role of a short QT interval in these settings not yet known.

Martinek and Purerfellner [39] presented a case of a young male with phenotypic combination of IVF and BrS. The patient had a nearly normal baseline ECG but had a positive ajmaline drug challenge including extremely short-coupled (coupling interval 318 ± 21 ms) monomorphic PVCs triggering VF.

ERP with notched or slurred J-point elevations in the inferolateral leads is not an uncommon finding in BrS (12% of cases) and is not associated with a worse outcome. Additionally, there are no significant differences in spontaneous ECG type 1 Brugada pattern, symptoms, family history of SCD, and positive genetic tests between subjects with and without ERP [40].

Akai et al. [41] screened 25 Japanese patients with IVF (OMIM number: 603829). The diagnoses were based on the occurrence of at least one episode of syncope and/or cardiac arrest and documented VF without structural heart diseases. They identified a heterozygous missense mutation (Serine 1710 to Leucine) in the human cardiac Na⁺ channel alpha-subunit gene (SCN5A) in one symptomatic IVF patient that did not exhibit the Brugada ECG pattern. BrS was not present. The mutation showed marked acceleration in the current decay together with a large hyperpolarizing shift of steady-state inactivation and depolarizing shift of activation. The paternal grandfather and a paternal uncle had died suddenly in their sixth decade of unknown cause. The authors conclude that SCN5A is one of the responsible genes for IVF patients who do not show typical ECG manifestations of the BrS. An ICD was implanted. It is unlikely that SCN5A should be attributed to IVF because this report clearly shows conduction defects (as expected), so this is not IVF but conduction delay at different levels in the heart.

Potet et al. [42] described a novel Brugada SCN5A missense (G752R) mutation leading to ST segment elevation in the inferior or the right precordial leads (atypical Brugada ECG pattern or IVF). In the proband, the G752R mutation produced ST segment elevation and prominent J waves in leads II, III, and aVF. In four other relatives, ST segment elevation in the right precordial but not in the inferior leads was observed either spontaneously or under flecainide challenge. Recombinant G752R mutant exhibited markedly reduced Na⁺ current amplitude and a voltage shift in both activation and inactivation curves. The mutant was found in all affected but not in non-affected family members. One additional gene-carrier had an almost normal ECG (silent gene-carrier). They provided genetic demonstration that Brugada ECG anomalies related to a unique SCN5A mutation can be observed either in the inferior or the right precordial leads.

Mohler et al. [43] found that humans with ankyrin-B mutations display varying degrees of cardiac dysfunction, including bradycardia, sinus arrhythmia, IVF, catecholaminergic polymorphic VT, and increased risk of SCD. However a prolonged rate-corrected QT interval was not a consistent feature, indicating that ankyrin-B dysfunction represents a clinic entity distinct from classic LQTS. The mutations were localized in the ankyrin-B regulatory domain, which distinguishes function of ankyrin-B from ankyrin-G (ANK3; 600465) in cardiomyocytes. This study supports a previously undescribed paradigm for human disease due to

abnormal coordination of multiple functionally related ion channels and transporters, in this case the Na/K_{ATPase}, Na/Ca exchanger, and InsP(3) receptor.

Early repolarization abnormalities in the inferolateral leads have been recognized as a frequent syndrome associated with IVF. Haissaguerre et al. [44] reported the case of an adolescent with dramatic changes in the ECG in association with recurrent VF. All examinations including coronary angiogram with ergonovine injection, magnetic resonance imaging, and flecainide or isoproterenol infusion were normal. The patient had unresponsive electric storms. Recurrences of VF were associated with massive accentuation of the ST segment elevation. Coronary angiography during an episode with 1.2 mV J-point elevation was normal. Isoproterenol infusion acutely suppressed electrical storms, while quinidine eliminated all recurrences of VF and restored a normal ECG over a follow-up of 65 months. Genomic DNA sequencing of K(ATP) channel genes showed missense variant in exon 3 of the KCNJ8 gene, a subunit of the K(ATP) channel.

Alders et al. [45] identified three probands descendent from the same ancestor with a family history of IVF present in up to 20% of probands with the disorder, suggesting that at least a subset of IVF is hereditary. A genome-wide haplotype-sharing analysis was performed for identification of the responsible gene in three distantly related families in which several individuals had SCD or were successfully resuscitated at young age. The authors identified a haplotype on chromosome 7q36 that was conserved in these three families and was also shared by 7 of 42 independent IVF patients. The shared chromosomal segment harbors part of the DPP6 gene, which encodes a putative beta-subunit component of human cardiac I_{to} current [46]. They demonstrated a 20-fold increase in DPP6 mRNA levels in the myocardium of carriers as compared to controls. Clinical evaluation of 84 risk-haplotype carriers and 71 noncarriers revealed no ECG or structural parameters indicative of cardiac disease. Penetrance of IVF was high; 50% of risk-haplotype carriers experienced (aborted) SCD before the age of 58 years (very malignant phenotype). The authors propose DPP6 as a gene for IVF and increased DPP6 expression as the likely pathogenetic mechanism. If there is a positive family history of unexplained SCDs and/or PVCs with very short coupling intervals ($\approx 300 \pm 50$ ms) within 40 ms of the T peak of the preceding beat in the absence of pause-dependency or other identifiable causes, a link to the DPP6 gene should be suspected [45]. In 3 related Dutch families segregating for IVF (VF2;

612956), the authors mapped the disease locus to a segment of chromosome 7 that includes the DPP6 gene. Direct sequencing of the probands in these 3 families as well as in 42 other Dutch probands segregating IVF identified no mutations in the coding sequences of DPP6, but a C-to-T transition 340 bases upstream from the ATG initiation codon of isoform 2 of the DPP6 gene (612956.0001) was identified in the 3 related probands and in 7 others. The 340C-T variant was not present in a control group of 350 Dutch individuals. Clinical evaluation of 84 risk-haplotype carriers and 71 noncarriers revealed no ECG or structural parameters indicative of cardiac disease. Penetrance of IVF was high; 50% of risk-haplotype carriers experienced (aborted) SCD before the age of 58 years. Alders proposed increased DPP6 expression as the likely pathogenetic mechanism of VF in these families. The characteristics genetic bases are: Gene mutation: *DPP6* gene. HGNC Approved Gene Symbol: DPP6 (DIPEPTIDYL PEPTIDASE VI); Protein: Dipeptidyl aminopeptidase-like protein 6.; Locus: 7q26. (Cytogenetic location: 7q36.2.); Channel on chromosome: Voltage-gated potassium channels. *DPP6* is putatively involved in the transient outward potassium current I_{to} in heart. This current is active in phase 1 of the cardiac action potential [47]; OMIM NO: 126141.; Phenotype MIM number: 612956.; Inheritance pattern: autosomal dominant and gain of channel function.

Loss-of-function mutations in the SCN5A-encoded sodium channel SCN5A or Nav1.5 have been identified in IVF patients in the absence of BrS phenotype. Nav1.5 is regulated by four sodium channel auxiliary beta subunits. Valdivia et al. [48] reported a case with IVF with a novel mutation in the SCN3B-encoded sodium channel beta subunit Nav beta3 that causes a loss of function of Nav1.5 channels *in vitro* and provides molecular and cellular evidence implicating mutations in Nav beta3 as a cause of IVF. Mutation in this SCN3B gene causes also BrS type 7 [49].

L-type calcium channel (LTCC) mutations have been associated with BrS, SQTS, and Timothy syndrome (LQT8). Little is known about the extent to which LTCC mutations contribute to the J-wave syndromes associated with SCD. Mutations in the LTCCs are detected in a high percentage of probands with J-wave syndromes associated with inherited cardiac arrhythmias, suggesting that genetic screening of Ca(v) genes may be a valuable diagnostic tool in identifying individuals at risk.

Burashnikov et al. [50] identified CACNA2D1 as a novel BrS susceptibility gene and CACNA1C, CACNB2, and CACNA2D1 as possible novel ERS susceptibility genes.

Sinner et al. [51] founded a high prevalence of ERP in a Finnish community-based sample cohort of middle-aged individuals. ERP was associated with about a 2- to 4-fold increased risk of cardiac mortality in individuals between 35 and 54 years. An inferior localization of ERP was particularly associated with a increased risk.

ERP and, in particular, notching in the inferior leads is associated with increased risk of life-threatening ventricular arrhythmias in patients with chronic coronary artery disease, even after adjustment for left ventricular ejection fraction. These findings suggest ERP, and a notching morphology of the terminal portion of the R wave should be considered in a risk prediction model for arrhythmias in patients with coronary artery disease [52].

Management

Symptomatic IVF patients have class I indication of ICD implantation because recurrence rate is high ($\approx 30\%$ in a three year follow up). Multiple recurrences occur in about 30% of patients with IVF, and early repolarization abnormality may be life threatening with isoproterenol as an adjunct in acute cases and quinidine in chronic cases. Although it is one of the oldest drugs in our armamentarium, quinidine continues to have a role in modern cardiology. Oral quinidine seems more effective than other antiarrhythmic drugs in this condition. No recurrences were reported during 15 years follow up with this drug The efficacy of quinidine in patients with IVF and BrS is excellent. Electrophysiologic efficacy-guided quinidine therapy represents a valuable long-term alternative to ICD therapy in these patients [53]. There is an isolated case report of IVF whose arrhythmias were successfully controlled with phenytoin therapy [54]. Emergency catheter ablation can be justified in critical patients with an electrical storm of the ICD or in patients with IVF [55]. Ablation for IVF that targets short coupled PVC triggers and Purkinje potentials is associated with a short-term and long-term freedom from VF recurrence [56, 57].

Conflict of interest: none declared

References

1. Parisi AF, Beckmann CH, Lancaster MC. The spectrum of ST segment elevation in the electrocardiograms of healthy adult men. *J Electrocardiol*, 1971; 4: 137–144.
2. Di Paolo FM, Schmied C, Zerguini YA. The athlete's heart in adolescent Africans: An electrocardiographic and echocardiographic study. *J Am Coll Cardiol*, 2012; 59: 1029–1036.

3. Rosso R, Kogan E, Belhassen B et al. J-point elevation in survivors of primary ventricular fibrillation and matched control subjects: incidence and clinical significance. *J Am Coll Cardiol*, 2008; 52: 1231–1238.
4. Perez MV, Uberoi A, Jain NA, Ashley E, Turakhia MP, Froelicher V. The prognostic value of early repolarization with ST-segment elevation in African Americans. *Heart Rhythm*, 2011 [in press].
5. Edeiken J. Elevation of the RS-T segment, apparent or real, in the right precordial leads as a probable normal variant. *Am Heart J*, 1954; 48: 331–339.
6. Wasserburger RH, Alt WJ. The normal RS-T segment elevation variant. *Am J Cardiol*, 1961; 8: 184–192.
7. Brady WJ, Perron AD, Syverud SA et al. Reciprocal ST segment depression: impact on the electrocardiographic diagnosis of ST segment elevation acute myocardial infarction. *Am J Emerg Med*, 2002; 20: 35–38.
8. Benito B, Guasch E, Rivard L, Nattel S. Clinical and mechanistic issues in early repolarization of normal variants and lethal arrhythmia syndromes. *J Am Coll Cardiol*, 2010; 56: 1177–1186.
9. Spach MS, Barr RC, Benson W, Walston A 2nd, Warren RB, Edwards SB. Body surface low-level potentials during ventricular repolarization with analysis of the ST segment: variability in normal subjects. *Circulation*, 1979; 59: 822–836.
10. Mirvis DM. Evaluation of normal variations in S-T segment patterns by body surface isopotential mapping: S-T segment elevation in absence of heart disease. *Am J Cardiol*, 1982; 50: 122–128.
11. Fenichel NN. A long term study of concave RS-T elevation: A normal variant of the electrocardiogram. *Angiology*, 1962; 13: 360–366.
12. Nakamoto K, Yonezawa A, Iwamoto H. Psychosomatic significance of a concave rs-t elevation in chemically normal hearts. *Jpn Cir J*, 1965; 29: 223–241.
13. Govindan M, Batchvarov VN, Raju H et al. Utility of high and standard right precordial leads during ajmaline testing for the diagnosis of Brugada syndrome. *Heart*, 2010; 96: 1904–1908.
14. Schwartz PJ, Priori SG, Spazzolini C et al. Genotype-phenotype correlation in the long-QT syndrome: gene-specific triggers for life-threatening arrhythmias. *Circulation*, 2001; 103: 89–95.
15. Abe A, Ikeda T, Tsukada T, Ishiguro H, Miwa Y, Miyakoshi M. Circadian variation of late potentials in idiopathic ventricular fibrillation associated with J waves: Insights into alternative pathophysiology and risk stratification. *Heart Rhythm*, 2010; 7: 675–682.
16. Gussak I, Bjerregaard P, Kostis J. Electrocardiographic “lambda” wave and primary idiopathic cardiac asystole: a new clinical syndrome? *J Electrocardiol*, 2004; 37: 105–107.
17. Riera AR, Ferreira C, Schapachnik E, Sanches PC, Moffa PJ. Brugada syndrome with atypical ECG: Downsloping ST-segment elevation in inferior leads. *J Electrocardiol*, 2004; 37: 101–104.
18. Rosso R, Glikson E, Belhassen B et al. Distinguishing “benign” from “malignant early repolarization”: the value of the ST-segment morphology. *Heart Rhythm*, 2012; 9: 225–229.
19. Yan GX, Antzelevitch C. Cellular basis for the electrocardiographic J wave. *Circulation*, 1996; 93: 372–379.
20. Hlaing T, DiMino T, Kowey PR, Yan GX. ECG repolarization waves: their genesis and clinical implications. *Ann Noninvasive Electrocardiol*, 2005; 10: 211–223.
21. Bernard A, Genée O, Grimard C, Sacher F, Fauchier L, Babuty D. Electrical storm reversible by isoproterenol infusion in a striking case of early repolarization. *J Interv Card Electrophysiol*, 2009; 25: 123–127.
22. Sacher F, Victor J, Hocini M et al. Characterization of premature ventricular contraction initiating ventricular fibrillation. *Arch Mal Coeur Vaiss*, 2005; 98: 867–873.
23. Mittadodla PS, Salen PN, Traub DM. Isoproterenol as an adjunct for treatment of idiopathic ventricular fibrillation storm in a pregnant woman. *Am J Emerg Med*, 2012; 30: 251.e3–5.
24. Antzelevitch C, Yan GX. J-wave syndromes. from cell to bedside. *J Electrocardiol*, 2011; 44: 656–661.
25. Shu J, Zhu T, Yang L, Cui C, Yan GX. ST-segment elevation in the early repolarization syndrome, idiopathic ventricular fibrillation, and the Brugada syndrome: cellular and clinical linkage. *J Electrocardiol*, 2005; 38: 26–32.
26. Take Y, Morita H, Wu J et al. Spontaneous electrocardiogram alterations predict ventricular fibrillation in Brugada syndrome. *Heart Rhythm*, 2011; 8: 1014–1021.
27. McIntyre WF, Pérez-Riera AR, Femenía F, Baranchuk A. Coexisting early repolarization pattern and Brugada syndrome: recognition of potentially overlapping entities. *J Electrocardiol*, 2012; 45: 199–202.
28. Hofman N, van Lochem LT, Wilde AA. Genetic basis of malignant channelopathies and ventricular fibrillation in the structurally normal heart. *Future Cardiol*, 2010; 6: 395–408.
29. Mizumaki K, Nishida K, Iwamoto J et al. Vagal activity modulates spontaneous augmentation of J-wave elevation in patients with idiopathic ventricular fibrillation. *Heart Rhythm*, 2012; 9: 249–255.
30. Derval N, Simpson CS, Birnie DH et al. Prevalence and characteristics of early repolarization in the CASPER registry: Cardiac arrest survivors with preserved ejection fraction registry. *J Am Coll Cardiol*, 2011; 58: 722–728.
31. Viskin S, Zeltser D, Ish-Shalom M et al. Is idiopathic ventricular fibrillation a short QT syndrome? Comparison of QT intervals of patients with idiopathic ventricular fibrillation and healthy controls. *Heart Rhythm*, 2004; 1: 587–591.
32. Deo R, Albert CM. Epidemiology and genetics of sudden cardiac death. *Circulation*, 2012; 125: 620–637.
33. Haissaguerre M, Derval N, Sacher F et al. Sudden cardiac arrest associated with early repolarization. *N Engl J Med*, 2008; 358: 2016–2023.
34. Myerburg RJ, Castellanos A. Early repolarization and sudden cardiac arrest: theme or variation on a theme? *Nature Clin Pract*, 2008; 5: 760–761.
35. Rudic B, Veltmann C, Kuntz E et al. Early repolarization pattern is associated with ventricular fibrillation in patients with acute myocardial infarction. *Heart Rhythm*, 2012 [Epub ahead of print].
36. Viskin S. Idiopathic ventricular fibrillation “Le Syndrome d’Haissaguerre” and the fear of J waves. *J Am Coll Cardiol*, 2009; 53: 620–622.
37. Gussak I, Brugada P, Brugada J et al. Idiopathic short QT interval: A new clinical syndrome? *Cardiology*, 2000; 94: 99–102.
38. Watanabe H, Makiyama T, Koyama T et al. High prevalence of early repolarization in short QT syndrome. *Heart Rhythm*, 2010; 7: 647–652.
39. Martinek M, Purerfellner H. A phenotypic combination of idiopathic VF and Brugada syndrome. *Pacing Clin Electrophysiol*, 2010; 33: e 84–e87.
40. Letsas KP, Sacher F, Probst V et al. Prevalence of early repolarization pattern in inferolateral leads in patients with Brugada syndrome. *Heart Rhythm*, 2008; 5: 1685–1689.
41. Akai J, Makita N, Sakurada H et al. A novel SCN5A mutation associated with idiopathic ventricular fibrillation without typical ECG findings of Brugada syndrome. *FEBS Lett*, 2000; 479: 29–34.

42. Potet F, Mabo P, Le Coq G et al. Novel Brugada SCN5A mutation leading to ST segment elevation in the inferior or the right precordial leads. *J Cardiovasc Electrophysiol*, 2003; 14: 2000–2003.
43. Mohler PJ, Splawski I, Napolitano C et al. A cardiac arrhythmia syndrome caused by loss of ankyrin-B function. *Proc Nat Acad Sci*, 2004; 101: 9137–9142.
44. Haissaguerre M, Chatel S, Sacher F et al. Ventricular fibrillation with prominent early repolarization associated with a rare variant of KCNJ8/KATP channel. *J Cardiovasc Electrophysiol*, 2009; 20: 93–98.
45. Alders M, Koopmann TT, Christiaans I et al. Haplotype-sharing analysis implicates chromosome 7q36 harboring DPP6 in familial idiopathic ventricular fibrillation. *Am J Hum Genet*, 2009; 84: 468–476.
46. Radicke S, Cotella D, Sblattero D, Ravens U, Santoro C, Wettwer E. The transmembrane beta-subunits KCNE1, KCNE2, and DPP6 modify pharmacological effects of the antiarrhythmic agent tedisamil on the transient outward current I_{to}. *Naunyn Schmiedebergs Arch Pharmacol*, 2009; 379: 617–626.
47. Radicke S, Cotella D, Graf EM, Ravens U, Wettwer E. Expression and function of dipeptidyl-aminopeptidase-like protein 6 as a putative beta-subunit of human cardiac transient outward current encoded by Kv4.3. *J Physiol*, 2005; 565: 751–756.
48. Valdivia CR, Medeiros-Domingo A, Ye B et al. Loss-of-function mutation of the SCN3B-encoded sodium channel beta3 subunit associated with a case of idiopathic ventricular fibrillation. *Cardiovasc Res*, 2010; 86: 392–400.
49. Hu D, Barajas-Martinez H, Burashnikov E et al. A mutation in the beta-3 subunit of the cardiac sodium channel associated with Brugada ECG phenotype. *Circ Cardiovasc Genet*, 2009; 2: 270–278.
50. Burashnikov E, Pfeiffer R, Barajas-Martinez H et al. Mutations in the cardiac L-type calcium channel associated with inherited J-wave syndromes and sudden cardiac death. *Heart Rhythm*, 2010; 7: 1872–1882.
51. Sinner MF, Reinhard W, Müller M et al. Association of early repolarization pattern on ECG with risk of cardiac and all-cause mortality: a population-based prospective cohort study (MONICA/KORA). *PLoS Med*, 2010; 7: e1000314.
52. Patel RB, Ng J, Reddy V et al. Early repolarization associated with ventricular arrhythmias in patients with chronic coronary artery disease. *Circ Arrhythm Electrophysiol*, 2010; 3: 489–495.
53. Belhassen B, Glick A, Viskin S. Excellent long-term reproducibility of the electrophysiologic efficacy of quinidine in patients with idiopathic ventricular fibrillation and Brugada syndrome. *Pacing Clin Electrophysiol*, 2009; 32: 294–301.
54. Golian M, Bhagirath KM, Sapp JL, Jassal DS, Khadem A. Idiopathic ventricular fibrillation controlled successfully with phenytoin. *J Cardiovasc Electrophysiol*, 2011; 22: 472–474.
55. Tebbenjohanns J, Rühmkorf K. Emergency catheter ablation in critical patients. *J Emerg Trauma Shock*, 2010; 3: 160–163.
56. Knecht S, Sacher F, Wright M et al. Long-term follow-up of idiopathic ventricular fibrillation ablation: A multicenter study. *J Am Coll Cardiol*, 2009; 54: 522–528.
57. Wright M, Sacher F, Haissaguerre M. Catheter ablation for patients with ventricular fibrillation. *Curr Opin Cardiol*, 2009; 24: 56–60.