

Benign Osteblastoma of the Temporal Bone: Case Report and Literature Review

Lídio Granto*, **Renata de Almeida****, **Hea Jung Yoo*****, **Alessandra Inácio****, **Paulo Roberto Lazarini*****.

* Professor Doctor. Associate Professor.

** MD. Otorhinolaryngologist.

*** MD. Assistant Professor.

Institution: Department of Otorhinolaryngology and Department of Radiology of the Irmandade da Santa Casa de Misericórdia de São Paulo, Santa Casa de São Paulo - Faculty of Medical Sciences.
São Paulo / SP – Brazil.

Address for correspondence: Lídio Granato – Departamento de Otorrinolaringologia, Faculdade de Ciências Médicas da Santa Casa de São Paulo – Rua Dr. Cesário Motta Júnior, 112 - 4º andar – Vila Buarque – São Paulo / SP – Brazil – Zip code: 01277-900 – Telephone/Fax: (+55 11) 222-8405 – E-mail: drlidio@terra.com.br
Artigo recebido em 25 de setembro de 2007. Artigo aceito em 17 de maio de 2008.

SUMMARY

- Introduction:** Osteblastoma is defined as a lesion of bone, which is rich in osteoblasts, well-vascularized, and affects mainly the spinal cord. Although it is benign, it presents malignant features and simulates osteosarcoma. It affects mainly young adults between 20 and 40 years old. It rarely compromises the temporal bone.
- Objective:** To present a rare case in the temporal bone with clinical malignant features whose the anatomopathological study has revealed to be a benign tumor.
- Method:** The patient presented a tumor which affected the middle ear cleft, the mastoid, and the right middle fossa. The patient underwent a surgery and, in association with otorhinolaryngology, the tumor was completely dried out from the middle fossa and the middle ear. Fascia lata was used to repair the dural impairment and an acrylic plate was used to cover the bone impairment.
- Result:** Post-surgery evolved positively, however the acrylic plate has moved itself and has stenosed the right external acoustic meato, which had to be removed 3 years later. The patient has had a good follow-up, which is still being carried through.
- Conclusion:** Osteblastoma is a multiform tumor that might affect the temporal bone with malignant features, which simulates osteosarcoma, but, in histological terms, it does not present any malignant signals. However, there is a need for a long post-surgery follow-up.
- Keywords:** neoplasm, osteblastoma, temporal bone, bone neoplasm.

INTRODUCTION

Osteoblastoma was first described in 1956 with the authors defining these neoplasms as “tumors that form bone tissue, rich in osteoblasts, well-vascularized, and more frequently found in the vertebral column”. This neoplasia may affect various other regions of the skeleton and may determine functional disability, depending on its location.

The age group most commonly affected is between 20 to 40 years, corresponding to 75% of the cases.

As to the radiological aspects, two types of osteoblastomas can be observed: the benign and the aggressive type. The latter, due to its aggressiveness, is similar to a malignant tumor, with clinical behavior like that of an osteosarcoma.

Due to the fact that the temporal bone is rarely associated with this tumor and because it may suggest an entity of malignant nature, the authors considered reporting the following case important.

CASE REPORT

Forty-four year old male patient, reports a reduction in hearing accompanied by tinnitus in the right year, having onset 3 months earlier. For two months the patient has noticed a protuberance in the pre-auricular region, with progressive growth, painful to touch and during mastication. There were no inflammatory signs present on the skin.

The ENT exam revealed protuberance in the pre-auricular region of the right ear that advanced to the anterior zygomatic region. The retro-auricular region presented edema. Pain was present during palpation in all of these regions.

The external auditory canal presented collapse of the posterior-superior wall, completely occluding the tympanic membrane.

Evaluation with the 500 Hz tuning fork demonstrated enhanced hearing of the left ear in comparison to the right, positive Rinne's test to the left and negative to the right, Weber test tilting to the right, and auditory test with a moderate conductive hearing loss in the right ear.

The imaging exam using computerized tomography showed a destructive lesion on the cortex of the retro-auricular region, with soft-tissue attenuation expanding in the direction of the zygomatic bone with destruction of the mastoid tegmen, consequently invading the external hearing

canal determining stenosis of the same. There was partial invasion of mastoid cells (Figure 1).

The magnetic resonance imaging exam revealed extensive extra-meningeal tumor mass invasion into the middle fossa (Figure 2).

The patient was submitted to a biopsy with specimen collection of the external hearing canal through a small retro-auricular incision.

The histological exam revealed an aggressive osteoblastoma (Figure 3).

The patient was referred to neurosurgery, at which time he was submitted to a right temporal craniotomy for tumor resection. During surgery, it was observed that the tumor was compressing the meninges of the middle fossa, and in some locations it was strongly adhered to the meninges, which determined tearing of the same during resection. Repair was done using fascia lata, and the surgery finished without any complications. The cranial bone defect was reconstructed using an acrylic plate

The patient evolved well during the first two postoperative years and only reported occasional otorrhea that was preceded by itching and mild otalgia. In general, this condition improved within a few days with auricular drops. The acrylic plate caused stenosis of the auditory canal and can be evidenced using MRI (Figure 4). There was granulation tissue next to the skin erosion provoked by the acrylic plate, which was the cause of the otorrhea and otalgia.

The physical examination evidenced stenosis of the internal third portion of the right external auditory canal, with the tympanic membrane being partially visible. Bulging still persists in the zygomatic region.

The postoperative computerized tomography study revealed signs of antral mastoidectomy with sclerosis on the remnant bone and material with attenuation for soft tissue filling the residual mastoid cells, tympanic cavity and external auditory canal. There was an osseous continuity solution through the mastoid to the temporal fossa, middle ear and external ear. The acrylic plate partially occluded the external auditory canal.

This condition worsened progressively with the dislocation of the plate and with an increase of granulation tissue, which was accompanied by mucopurulent secretion and occasional pain during the 3rd postoperative year

In a conjoint surgery with the neurosurgery team, the acrylic plate was removed and intact meninges was

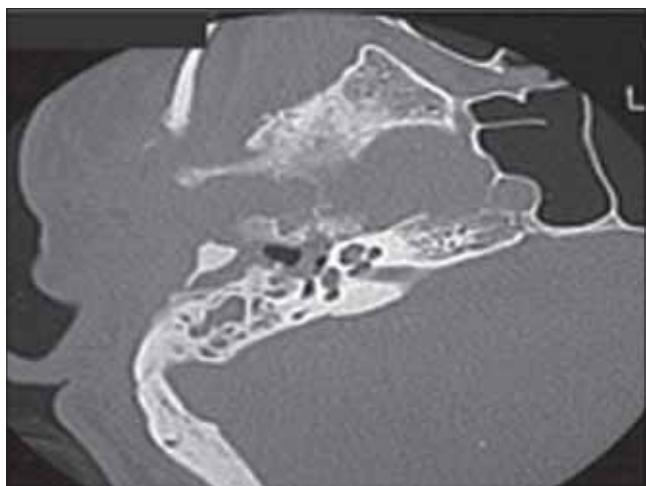

Figure 1. Preoperative axial image: osteolytic lesion with destruction of the temporal scale and petrous pyramid.

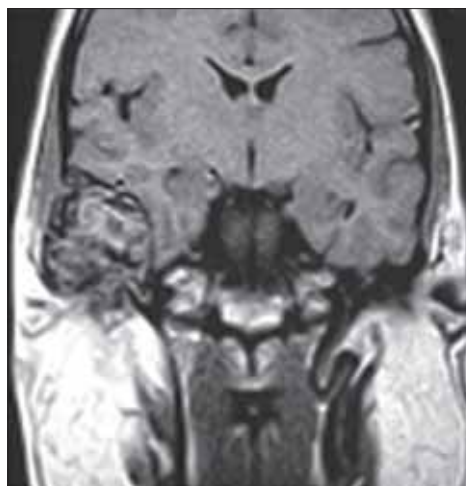


Figure 2. Preoperative coronal image in T1 without contrast demonstrating an extra-axial lesion having an intermediate signal compressing the temporal lobe.

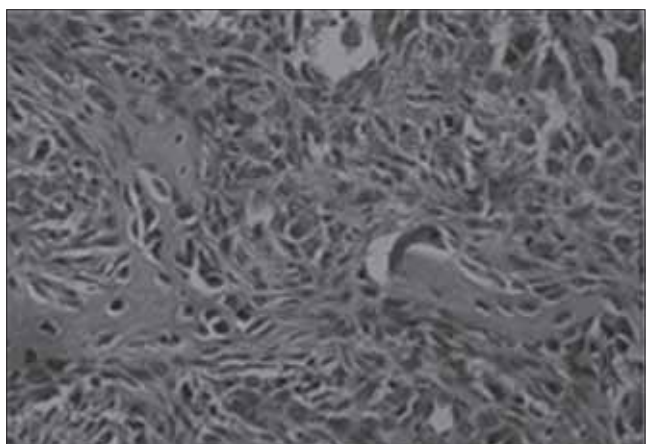


Figure 3. Anatomic-pathological: mesenchymal neoplasia fragment that, in several fields, is characterized by irregular osteoid trabeculae circumvented by osteoblasts.

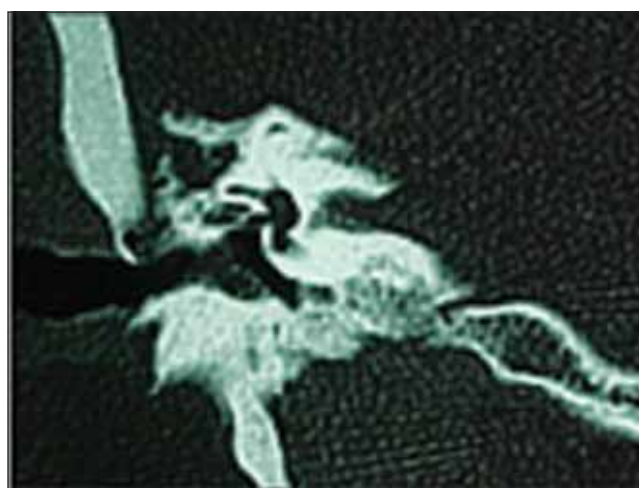


Figure 4. Postoperative coronal image shows a discontinuity of the tympanic tegmen and discrete stenosis provoked by the acrylic plate on the medial portion of the external acoustic meatus.

observed, having very good aspects without signs of inflammation. There was a discrete duct that determined communication between the middle fossa and auditory canal. This was sealed using temporal fascia and muscle, in addition to biological glue.

The canal was rectified and the granulation tissue was removed.

The patient demonstrated good evolution within a two-month follow-up without complaints, with a normal external auditory canal (Figure 5).

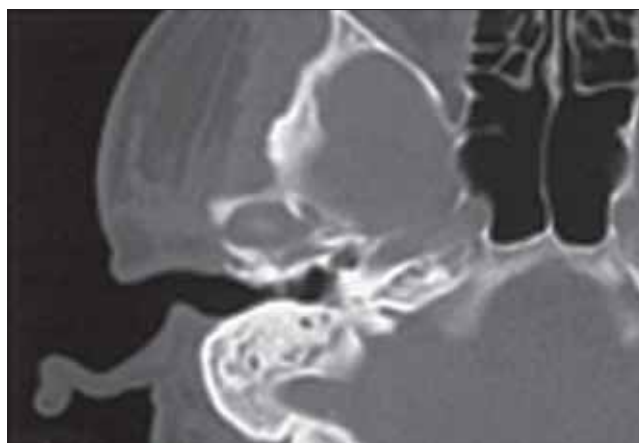

Figure 5. A normal external auditory canal is seen two months after the surgery in which the acrylic plate was removed.

DISCUSSION

Osteoblastoma is a rare, benign bone tumor, described separately by JAFFE (1) and LICHTENSTEIN (2) in 1956. It occurs in 1% of the primary bone tumors and it predominantly affects young patients (3). There are reports describing this tumor in children, but the most affected age group is the young adults. In the Pathology Department of the Irmandade da Santa Casa de Misericórdia de São Paulo, it was observed that 50% of the patients were in their second decade of life, while 26.5% belonged to the third, totaling approximately 75% of the cases of patients between 20 and 40 years of age (4), confirming the findings of HUVOS (5). The age of our patient was within the aforementioned age group.

As to gender and race of the patients, no significant differences have been found.

Clinically, these tumors mainly affect the bones of the vertebral column; however, it may occur in other bones in several regions of the skeleton, mainly affecting the long bones of the inferior limbs. It may affect the base of the cranium in 15 to 20% of the cases (6). It rarely occurs in the temporal bone. The symptoms are mainly local pain, edema, and erythema in the area affected by the tumor. These tumors cause dysfunction by mechanical compression of the adjacent structures (4).

When located in the temporal bone, the osteoblastoma may present itself as a benign tumor, circumscribed to the region or it may be aggressive, simulating a malignant neoplasia (7).

The radiological findings, which demonstrate benign characteristics, show osteolytic lesions with or without varying degrees of calcification. DOSHI et al. (8) published a case in 2001, in which the tumor had typical benign characteristics.

When the tumor exceeds 4 cm, it suggests an invasive character and should be considered aggressive. Its capacity for destruction is great and, in certain cases, may be undistinguishable from an osteosarcoma. OKHAWA et al. (9) in 1997 report a case of a patient with an amorphous mass with a calcified matrix, compressing the meninges of the middle fossa, with precise delimitations, and presenting a small and translucent marginal zone.

The MRI may be useful for delimitating the extension of the tumor. Our patient had an extensive tumor affecting both bone and soft tissue and showing internal calcifications.

Regarding the histological findings, there are several

differential hypotheses. SCHAJOWICZ and LEMOS (7), in 1970 and LUCAS et al. (10) observed that there was a significant similarity between osteoblastoma and osteoid osteoma and considered the two as the same disease. Though there is a similarity between the two from the histological, clinical, radiological and developmental point of view, they may be considered as distinct neoplasias (4).

Histologically, the osteoblastoma shows a greater number of cells around the bone periphery. The osteoblasts form irregular agglomerates and assume an epithelial aspect, with a greater number of always typical mitoses (3).

Clinically, the osteoid osteoma measures less than 1 cm, while the osteoblastoma is greater than 1 cm, and is more vascularized (11), demonstrating to be more aggressive through the cortical cortex.

The osteoid osteoma is surrounded by sclerotic bone and seems to be more painful than the osteoblastoma (12).

When treating benign osteoblastoma of the temporal bone, eosinophilic granuloma should be considered as a possibility for the differential diagnosis, because of its incidence in the same age group and identical location (3).

The most important differential diagnosis of aggressive osteoblastoma is osteosarcoma. Initially, our patient was suspected of having a malignant tumor until the histological results confirmed osteoblastoma.

Osteosarcoma is more aggressive and determines greater bone destruction; however, it should be difficult to differentiate them by the radiological images.

The presence of atypical mitoses is characteristic of the osteosarcoma, and may even present greater mitotic activity and cartilage proliferation than the osteoblastoma. Osteoblastoma, however, does not present metastasis (10).

Currently, it is still difficult to characterize aggressive osteoblastoma with certainty and its evolution should be considered aggressive when postoperative recurrences occur, which may be very severe (4).

Treatment is always surgical with the complete resection of the tumor including the normal marginal adjacent tissue. If it is impossible to completely remove the tumor, curettage is also indicated, though 20% of the cases of recurrence are due to the incomplete removal of the tumor (13).

Our patient was submitted to neurosurgery remaining

without complaints and without macroscopic disease in the mastoid and middle ear. The patient only reported occasional otorrhea preceded by pruritus and mild otalgia. The patient has a conductive hearing loss.

Three years after the surgery the patient presented stenosis of the auditory canal that was provoked by the dislocation of the acrylic plate and was submitted to removal of the same with sealing of the fault of the superior portion of the canal; surgical complementation was done through the auditor canal.

Radiotherapy is also considered for therapy, and may be used in cases in which the tumor has not been completely removed, though the possibility of malignant degeneration should be taken into consideration when a benign tumor is irradiated (4). Our patient was not submitted to any complementary treatment.

CONCLUSION

An important aspect of the osteoblastoma is that it is multiform in its presentation, and may have characteristics of a benign tumor, with growth limited to the middle ear and its consequences, or may present characteristics of a malignant neoplasia, simulating an osteosarcoma.

Even though uncommon, when the mastoid and cleft of the middle ear is afflicted, accompanied by pain and expansion into the neighboring regions, osteoblastoma should be considered a possible diagnosis. Because this illness rarely presents itself on the temporal bone, identification of the same remains difficult.

ACKNOWLEDGMENTS

We are grateful to the Support Center for Scientific Publications of Santa Casa de São Paulo - Faculty of Medical Sciences for the editorial assistance.

BIBLIOGRAPHICAL REFERENCES

1. Jaffe HL. Benign osteoblastoma. *Bull Hosp Joint Dis.* 1956, 17:141-51.

2. Lichtenstein L. Benign osteoblastoma; a category of osteoid-and bone-forming tumors other than classical osteoid osteoma, which may be mistaken for giant-cell tumor or osteogenic sarcoma. *Cancer.* 1956, 9:1044-52.

3. Dahlin DC. Bone tumors - General aspect and data on 8542 cases. Springfield, III: Charles C. Thomas Publisher; 1986.

4. Próspero JD. Tumores Produtores de Tecido Ósseo. In: Próspero JD ed. *Tumores Ósseos.* São Paulo; Ed. Roca; 2001, pp. 12.

5. Huvos AG. Bone tumors - diagnosis, treatment and prognosis. Philadelphia, Pa: WB. Saunders Co.; 1979.

6. Ronis ML, Obando M, Bucko MI, Liebman EP. Benign osteoblastoma of the temporal bone. *Laryngoscope.* 1974, 84:857-62.

7. Schajowicz F, Lemos C. Osteoid osteoma and osteoblastoma. Closely related entities of osteoblastic derivation. *Acta Orthop Scand.* 1970, 41:272-91.

8. Doshi SV, Frantz TD, Korol HW. Benign osteoblastoma of the temporal bone: case report and literature review. *Am J Otolaryngol.* 2001, 22:211-4.

9. Ohkawa M, Fujiwara N, Tanabe M, Takashima H, Satoh K, Mori Y et al. Benign osteoblastoma of the temporal bone. *AJNR Am J Neuroradiol.* 1997, 18:324-6.

10. Lucas DR, Unni KK, McLeod RA, OConnor MI, Sim FH. Osteoblastoma: clinicopathologic study of 306 cases. *Hum Pathol.* 1994, 25:117-34.

11. Gellad FE, Hafiz MA, Blanchard CL. Osteoblastoma of the temporal bone: CT findings. *J Comput Assist Tomogr.* 1985, 9:577-9.

12. Potter C, Conner GH, Sharkey FE. Benign osteoblastoma of the temporal bone. *Am J Otol.* 1983, 4:318-22.

13. Clutter DJ, Leopold DA, Gould LV. Benign osteoblastoma. Report of a case and review of the literature. *Arch Otolaryngol.* 1984, 110:334-6.