

Benign Ulceration of Ileocecal Valve: A New Cause of Low Gastrointestinal Bleeding?

C Papanikolaou, G Anthimidis, I Tsadila, G Komninos, K Zervas, G Mahia, G Hatzitheoharis

Citation

C Papanikolaou, G Anthimidis, I Tsadila, G Komninos, K Zervas, G Mahia, G Hatzitheoharis. *Benign Ulceration of Ileocecal Valve: A New Cause of Low Gastrointestinal Bleeding?*. The Internet Journal of Surgery. 2009 Volume 22 Number 1.

Abstract

A case of massive lower gastrointestinal bleeding (LGIB) in a patient treated by urgent right hemicolectomy is described. After macro- and microscopical examination of the specimen, an ileocecal valve mucosal ulceration was recognized as the cause of bleeding. It appears that this case is the first report of LGIB from a benign non-inflammatory and non-neoplastic ileocecal valve ulcer, comprising a unique pathologic entity.

INTRODUCTION

The most common causes of lower gastrointestinal bleeding (LGIB) are diverticulosis, angiodysplasia, and colorectal cancer. In 10-25% of cases of LGIB, no cause is found¹; therefore, it is important to be aware of rare causes of LGIB. However, attempts to localize the source of bleeding never precede appropriate resuscitative measures. In this case report, we describe an unusual case of a patient with massive, life-threatening LGIB originating from an ulcerated ileocecal valve.

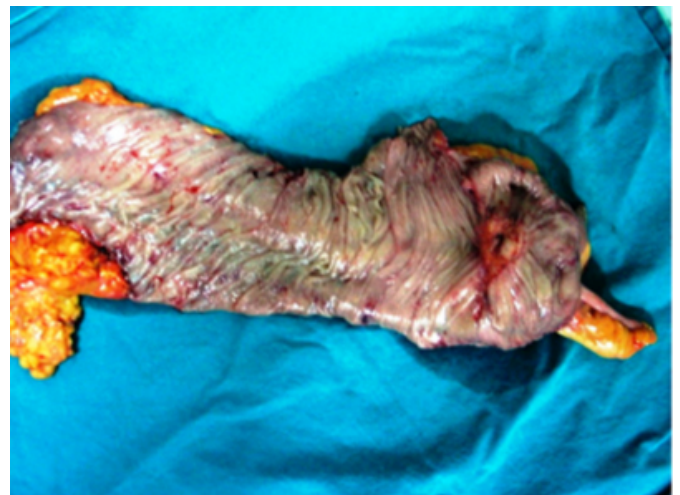CASE REPORT

A 70-year-old man presented to the emergency department due to lower gastrointestinal bleeding for the last two hours. He denied any hematemesis, abdominal pain, weight loss or change in bowel pattern. He was admitted to the internal medicine department and treatment began with intravenous fluid resuscitation and transfusion of units of packed red blood cells (pRBCs). From the nasogastric tube only bilious gastric contents but no blood was aspirated. On surgical consultation the patient was pale, diaphoretic, cool, and tachycardic. The patient's Hct was 21%, with a pulse rate of 130/min and a systolic blood pressure of 65mmHg. Rectal examination revealed normal sphincteric tone and a large quantity of bright red blood and blood clots, with no evidence of a rectal mass. The prothrombine time and partial thromboplastin time were both normal. Consequently, an emergency exploratory laparotomy was decided with the preoperative diagnosis being obscure. On opening the

abdomen, a rather dilated colon but non-dilated ileum was encountered. Assuming that the massive lower gastrointestinal bleeding originates from the right colon, we performed a right hemicolectomy as the first step of subtotal colectomy if the patient would not stabilize. After the removal, an intraoperative examination of the specimen revealed a bleeding ulcer at the ileocecal valve as well as a cecal diverticulum without any evidence of bleeding (Fig. 1).

Figure 1

Figure 1: Macroscopic appearance. A bleeding ulcer at the ileocecal valve and a cecal diverticulum with no evidence of bleeding



The patient became haemodynamically stable and a side-to-side ileotransverse anastomosis was performed. Histological

examination of the lesion of the ileocecal valve displayed mucosal ulceration along with focal reactive atypia and epithelial hyperplasia, stromal fibrosis and proliferation of the capillaries, characterized by thrombosis (Fig. 2, 3, 4).

Figure 2

Figure 2: Medium-power view showing an ulcerated mucosa accompanied with granulation tissue.

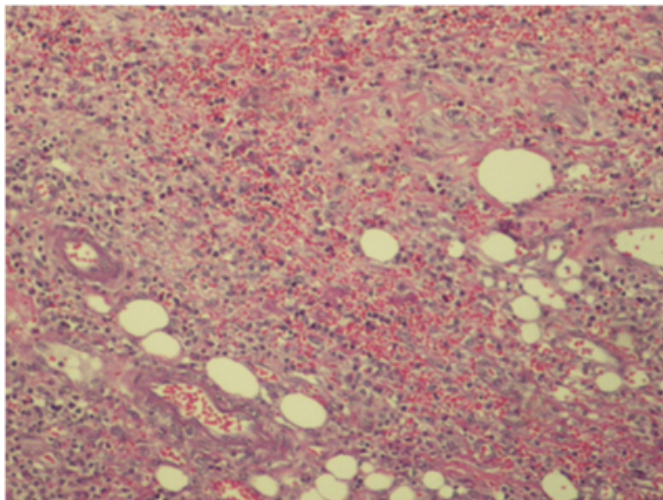


Figure 3

Figure 3: High-magnification view displaying marked extravasation of red blood cells

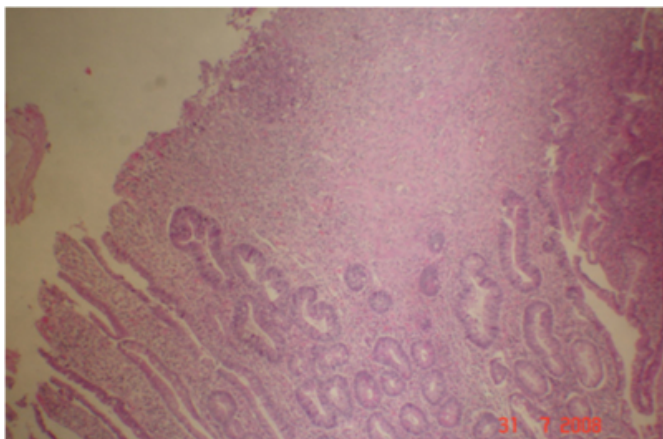
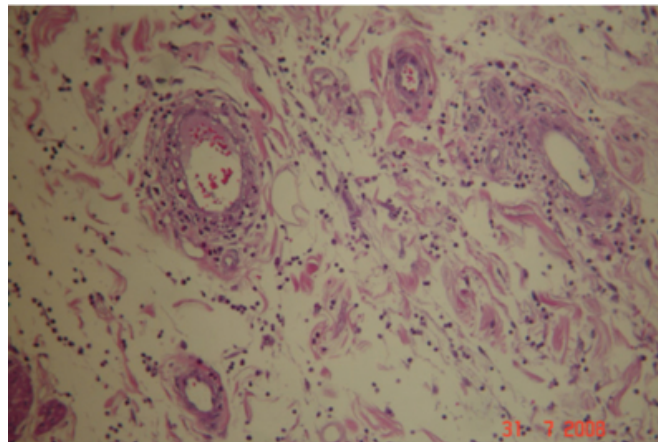


Figure 4

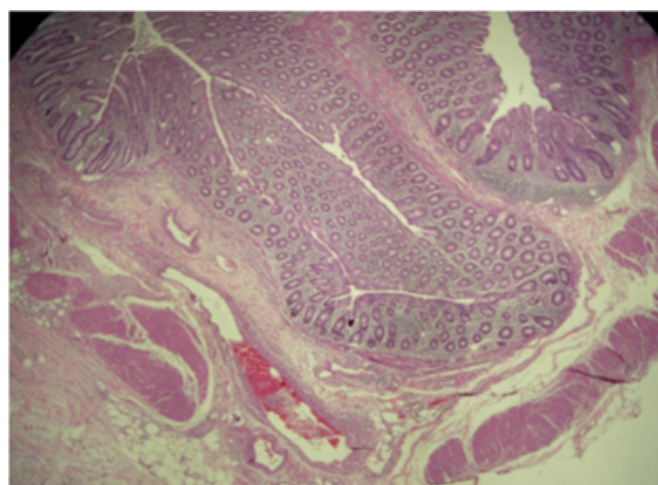
Figure 4: High-magnification view demonstrating proliferation of dilated vessels



In addition, a diverticulum of the cecum was demonstrated with chronic inflammation of its mucosa and underlying tissue. The latter also showed acute inflammatory changes but no evidence of haemorrhage (Fig. 5).

Figure 5

Figure 5: Medium-power view showing a diverticulum of the large intestine with no signs of haemorrhage



Pathological examination of the lymph nodes showed histological findings consistent with reactive lymphadenopathy.

The patient recovered uneventfully and did not experience any further gastrointestinal bleeding episodes.

DISCUSSION

Lower gastrointestinal bleeding is a common cause for hospital admission and may be life-threatening, if massive². The most common causes of LGIB are diverticulosis, angiodysplasia, colorectal cancer, inflammatory bowel

disease, colonic ischemia, and haemorrhoids (Table 1)^{3,4}. In 10-25% of cases the cause is unknown¹. The optimal diagnostic and therapeutic approach to patients with massive LGIB remains controversial. Depending on the source of bleeding, a variety of therapeutic choices are available. These include pharmacologic, endoscopic, angiographic, and surgical modalities. Pharmacologic, endoscopic, and surgical treatments are, mostly, site-specific. Angiographic methods are rather nonspecific and include selective angiography with either infusion of a vasoconstrictor, usually vasopressin, or embolization. Embolic agents include temporary materials such as gelatin sponge and autologous clot or permanent devices such as coils⁶.

The majority of lower gastrointestinal bleedings stop spontaneously. However, about 10-15% of patients require urgent surgical treatment⁷. Surgical intervention for LGIB is required when - despite aggressive resuscitation - haemodynamic instability persists, when the blood transfusion requirement is greater than 6 units of pRBCs, or when severe bleeding recurs⁸. Attempts to localize the site of acute LGIB and to diagnose its aetiology can be challenging. The unstable patient who continues to bleed and requires ongoing aggressive resuscitation is admitted for expeditious diagnosis, determination of the site of bleeding, and surgical intervention.

In our case, surgical intervention was not delayed. An emergency exploratory laparotomy was performed with the preoperative diagnosis being obscure. On opening the abdomen, a rather dilated colon but non-dilated ileum was encountered. The two most common causes of massive LCIB are diverticular hemorrhage and bleeding vascular ectasias⁹. Although diverticular disease is much more common on the left side, right-sided disease is responsible for more than half of the episodes of bleeding. Haemorrhage, secondary to angiodysplasia, tends to arise from the right colon, with the cecum being the most common location, although angiodysplasias can occur anywhere in the colorectum and small bowel⁶. Thus, since the exact source of bleeding was uncertain, serial clamping and resection was carried out, beginning from the right colon. Besides, subtotal colectomy does not eliminate the risk for recurrent haemorrhage and, when compared with segmental resection, is accompanied by a significant increase in the morbidity (diarrhoea in the elderly, in whom the remaining rectum may never adapt effectively). The mortality rate of emergent subtotal colectomy for bleeding is as high as 30%¹⁰. Directly after the right hemicolectomy, the patient began to stabilize

hemodynamically. Intraoperative examination of the specimen revealed mucosal ulceration and blood clots at the ileocecal valve. Recognizing that the massive lower gastrointestinal bleeding must be due to this bleeding ulcer, a side-to-side ileotransversal anastomosis was performed.

This case, to the best of our knowledge, is the first report of LGIB from a benign non-inflammatory and non-neoplastic ileocecal valve ulcer. However, diseases of the ileocecum are mostly ulcerative. The ileocecum originates in the ascending colon and includes the cecum, appendix, and terminal filament of the ileum. The causes of ileocecal ulcer are intestinal tuberculosis, Crohn's disease, carcinoma of the cecum, ulcerative colitis, solitary ulcer of the colon, lymphoma, and leiomyoma¹¹. In particular, the ileocecal valve is a normal structure, with several anatomical variants, possibly involved by different pathologic conditions, either neoplastic or inflammatory. The most frequent variants of ileocecal valve and pathologic conditions include idiopathic and post-traumatic edema, submucosal fat accumulation, herniation of ileal mucosa, benign tumors (lipomas, polyps), malignant tumors (adenocarcinomas, lymphosarcoma, lymphomas) and inflammatory lesions (Crohn's disease, ulcerative colitis, tuberculosis, amoebiasis, typhoid fever and actinomycosis)¹².

A literature search, on PubMed (May 31st, 2009) revealed no other case of ileocecal valve ulcer LGIB reported. To our knowledge, it appears our case would be the first such case to be reported that has also been histologically confirmed. In conclusion, ileocecal valve mucosal ulceration is a unique pathologic condition, recognized after macro- and microscopical examination of the specimen. It can cause massive acute LGIB, which mandates early intervention.

Figure 6

Table 1. Pathologic findings in massive lower gastrointestinal hemorrhage

Pathologic finding	Number of patients
Diverticulosis	18 (33%)
Arteriovenous malformation	16 (30%)
Adenocarcinoma	5 (9%)
Inflammatory bowel disease	3 (5%)
Intestinal ischemia	3 (5%)
Lymphoma	2 (4%)
Coagulopathy	2 (4%)
Carcinoid	1 (2%)
Leiomyoma	1 (2%)
Adenomatous polyp	1 (2%)
Cytomegalovirus colitis	1 (2%)
Haemorrhoid	1 (2%)

References

1. Strate LL: Lower gastrointestinal bleeding: Epidemiology and diagnosis. *Gastroenterol Clin North Am* 2005;34:643-64.
 2. Longstreth GF. Epidemiology and outcome of patients

hospitalized with acute lower gastrointestinal hemorrhage: a population-based study. *Am J Gastroenterol* 1997;92:419-24.
 3. Bounds BC, Friedman LS. Lower gastrointestinal bleeding. *Gastroenterol Clin North Am* 2003;32:1107-25.
 4. Leitman IM, Paull DE, Shires GT 3rd. Evaluation and management of massive lower gastrointestinal hemorrhage. *Ann Surg* 1989;209(2):175-80.
 5. Hoedema RE, Luchtefeld MA. The management of lower gastrointestinal hemorrhage. *Dis Colon Rectum* 2005;48:2010-24.
 6. Ali Tavakkolizadeh, Joel E. Goldberg, Stanley W. Ashley. Acute Gastrointestinal Hemorrhage. In: Townsend CM, Beauchamp RD, Evers BM, Mattox KL. *Sabiston Textbook of Surgery, The Biological Basis of Modern Surgical Practice*. 18th ed., Philadelphia: Saunders, 2008
 7. Al Qahtani AR, Satin R, Stern J, Gordon PH. Investigative modalities for massive lower gastrointestinal bleeding. *World J Surg* 2002;26:620-5.
 8. Farrell JJ, Friedman LS. The management of lower gastrointestinal bleeding. *Aliment Pharmacol Ther* 2005;21:1281-98.
 9. Kathleen Liscum. Lower Gastrointestinal Bleeding. In: Harken Alden H., Abernathy Charles, Moore Ernest Eugene. *Abernathy's Surgical Secrets*, Elsevier Mosby; 5th Bk. & Acc. Edition. 2004.
 10. Gralnek IM: Obscure-overt gastrointestinal bleeding. *Gastroenterol* 2005;128:1424-30.
 11. Jia Cai, Fan Li, Wei Zhou, He-sheng Luo. Ileocecal ulcer in central china: Case Series. *Dig Dis Sci* 2007;52: 3169-73
 12. Lafrate F, Rengo M, Ferrari R, Paolantonio P, Celestre M, Laghi A. Spectrum of normal findings, anatomic variants and pathology of ileocecal valve: CT colonography. Appearances and endoscopic correlation. *Abdom Imaging* 2007;32:589-95.

Author Information

Christos Papanikolaou, MD, PhD

1st Surgical Unit, Hippokration General Hospital

George V. Anthimidis, MD

1st Surgical Unit, Hippokration General Hospital

Ioanna Tsadila, MD

Dept. of Gen. Pathology, Hippokration General Hospital

George Komninos Komninos, MD

1st Surgical Unit, Hippokration General Hospital

Konstantinos Zervas, MD

1st Surgical Unit, Hippokration General Hospital

Georgia Mahia, MD

1st Surgical Unit, Hippokration General Hospital

George Hatzitheoharis, MD, PhD

1st Surgical Unit, Hippokration General Hospital