



University of Dundee

Best practices for the diagnosis and evaluation of infants with robin sequence

Breugem, Corstiaan C.; Evans, Kelly N.; Poets, Christian F; Suri, Sunjay; Picard, Arnaud; Filip, Charles

Published in:
JAMA Pediatrics

DOI:
[10.1001/jamapediatrics.2016.0796](https://doi.org/10.1001/jamapediatrics.2016.0796)

Publication date:
2016

Document Version
Publisher's PDF, also known as Version of record

[Link to publication in Discovery Research Portal](#)

Citation for published version (APA):

Breugem, C. C., Evans, K. N., Poets, C. F., Suri, S., Picard, A., Filip, C., Paes, E. C., Mehendale, F. V., Saal, H. M., Basart, H., Murthy, J., Joosten, K. F. M., Speleman, L., Collares, M. V. M., van den Boogaard, M-J. H., Muradin, M., Andersson, M. E-M., Kogo, M., Farlie, P. G., ... Hong, P. (2016). Best practices for the diagnosis and evaluation of infants with robin sequence: a clinical consensus report. *JAMA Pediatrics*, 170(9), 894-902. <https://doi.org/10.1001/jamapediatrics.2016.0796>

General rights

Copyright and moral rights for the publications made accessible in Discovery Research Portal are retained by the authors and/or other copyright owners and it is a condition of accessing publications that users recognise and abide by the legal requirements associated with these rights.

- Users may download and print one copy of any publication from Discovery Research Portal for the purpose of private study or research.
- You may not further distribute the material or use it for any profit-making activity or commercial gain.
- You may freely distribute the URL identifying the publication in the public portal.

Take down policy

If you believe that this document breaches copyright please contact us providing details, and we will remove access to the work immediately and investigate your claim.

Best Practices for the Diagnosis and Evaluation of Infants With Robin Sequence

A Clinical Consensus Report

Corstiaan C. Breugem, MD, PhD; Kelly N. Evans, MD; Christian F. Poets, MD, PhD; Sunjay Suri, MDS, MOrthRCS; Arnaud Picard, MD, PhD; Charles Filip, MD, PhD; Emma C. Paes, MD, PhD; Felicity V. Mehendale, MS, FRCS(Plast); Howard M. Saal, MD; Hanneke Basart, MD, PhD; Jyotsna Murthy, MD; Koen F. M. Joosten, MD, PhD; Lucienne Speleman, MD; Marcus V. M. Collares, MD, PhD; Marie-José H. van den Boogaard, MD, PhD; Marvick Muradin, MD, DMD, PhD; Maud Els-Marie Andersson, PhD; Mikihiro Kogo, DDS, PhD; Peter G. Farlie, PhD; Peter Don Griot, MD, PhD; Peter A. Mossey, BDS, PhD; Rona Slator, DPhil, FRCS, FRCS(Plast); Veronique Abadie, MD, PhD; Paul Hong, MD

IMPORTANCE Robin sequence (RS) is a congenital condition characterized by micrognathia, glossoptosis, and upper airway obstruction. Currently, no consensus exists regarding the diagnosis and evaluation of children with RS. An international, multidisciplinary consensus group was formed to begin to overcome this limitation.

OBJECTIVE To report a consensus-derived set of best practices for the diagnosis and evaluation of infants with RS as a starting point for defining standards and management.

EVIDENCE REVIEW Based on a literature review and expert opinion, a clinical consensus report was generated.

FINDINGS Because RS can occur as an isolated condition or as part of a syndrome or multiple-anomaly disorder, the diagnostic process for each newborn may differ. Micrognathia is hypothesized as the initiating event, but the diagnosis of micrognathia is subjective. Glossoptosis and upper airway compromise complete the primary characteristics of RS. It can be difficult to judge the severity of tongue base airway obstruction, and the possibility of multilevel obstruction exists. The initial assessment of the clinical features and severity of respiratory distress is important and has practical implications. Signs of upper airway obstruction can be intermittent and are more likely to be present when the infant is asleep. Therefore, sleep studies are recommended. Feeding problems are common and may be exacerbated by the presence of a cleft palate. The clinical features and their severity can vary widely and ultimately dictate the required investigations and treatments.

CONCLUSIONS AND RELEVANCE Agreed-on recommendations for the initial evaluation of RS and clinical descriptors are provided in this consensus report. Researchers and clinicians will ideally use uniform definitions and comparable assessments. Prospective studies and the standard application of validated assessments are needed to build an evidence base guiding standards of care for infants and children with RS.

JAMA Pediatr. 2016;170(9):894-902. doi:10.1001/jamapediatrics.2016.0796
Published online July 18, 2016.

+ Supplemental content at
jamapediatrics.com

Author Affiliations: Author affiliations are listed at the end of this article.

Corresponding Author: Kelly N. Evans, MD, Seattle Children's Craniofacial Center, Department of Pediatrics, University of Washington, 4800 Sandpoint Way NE, OB 9.520, Seattle, WA 98105 (knevans@uw.edu).

Currently, no consensus exists regarding the diagnosis or evaluation of a newborn with Robin sequence (RS), a congenital condition occurring in approximately 1 in 8500 live births.¹ The literature addressing RS has focused on the experience of single centers based on study-specific definitions. Multidisciplinary collaboration and prospective studies using similar definitions are required to advance care in RS. To further this goal, an international consensus meeting was convened in Utrecht, the Netherlands, from October 31 to November 1, 2014, at which 145 participants from 24 countries attended. An expert panel was convened to develop a RS clinical consensus report (CCR) based on synthesis of available literature and expert opinion. The objective of this article is to report the resulting consensus-derived set of best practices for the diagnosis and evaluation of children with RS as a starting point for defining standards and management.

Methods

The CCR was developed after the completion of 7 predetermined steps. These included (1) evaluation of the suitability of RS for a CCR, (2) panel selection and recruitment, (3) vetting of potential conflicts of interest, (4) a panel meeting to determine the CCR scope and focus, (5) a systematic literature review and generation of the CCR, (6) iterative revision of the CCR based on survey results, and (7) CCR review and agreement.

Determination of RS as the Topic of a Consensus Report, Panel Recruitment, and Vetting

Robin sequence was considered as a possible subject of a CCR based on discussions at a craniofacial meeting in 2013 (12th International Congress on Cleft Lip/Palate and Related Craniofacial Anomalies; May 10, 2013; Orlando; Florida). The consensus leadership (C.C.B., K.N.E., and P.H.) developed a panel of international consensus meeting faculty, with a strategic aim to cultivate participation from the pertinent specialty groups. The panel membership was surveyed to generate an agenda and specific objectives. Endorsements for the meeting were obtained from numerous societies and associations (<http://www.robinsequence.nl/home.html>). The panel, selected based on clinical and research expertise focusing on RS, contained representatives from pediatrics (K.N.E. and V.A.), sleep medicine (K.F.M.J.), neonatology (C.F.P.), genetics (H.M.S., M.H.V., and M.E.A.), plastic surgery (C.C.B., C.F., J.M., P.D.G., R.S., F.V.M., E.P., A.P., H.B., and M.V.C.), otolaryngology (P.H. and L.S.), maxillofacial surgery (M.M. and M.K.), developmental biology (P.G.F.), dentistry, and orthodontics (S.S. and P.A.M.). All members were vetted by the panel chair (C.C.B.), and no conflicts of interest were identified.

Literature Review and Determination of the Scope of the Consensus Report

The expert panel defined the scope and current controversies in diagnosing and evaluating children with RS during the international consensus meeting. Aiming to build a report that would identify gaps in evidence and prioritize clinical focus areas in RS care, the panel assembled topic-specific subgroups. The stepwise development of each report included a systematic literature review to identify up-to-date evidence focused on the designated topic. These topic areas were deliberated by the multidisciplinary subgroups at the interna-

Key Points

Question What are the agreed-on clinical features of and evaluations for infants and children with Robin sequence?

Findings In this consensus report and review, an international, multidisciplinary panel of clinical experts agreed that the diagnosis of Robin sequence can be made in children with micrognathia, glossoptosis, and upper airway obstruction. Gaps in evidence in this uncommon condition have limited advances in care and outcomes assessments in children with Robin sequence.

Meaning Using uniform definitions and comparable assessments of the functional and phenotypic features has a global application and the potential to improve care and outcomes in this fragile population with Robin sequence.

tional consensus meeting and subsequently used as the framework for developing the CCR.

Generation of Consensus Document

After the international consensus meeting, the panel divided into 6 groups, each with a designated group leader. The topics, agreed on by all conference attendees, included (1) micrognathia (M.M.), (2) glossoptosis (P.H.), (3) airway obstruction (K.F.M.J.), (4) feeding problems (V.A.), (5) cleft palate (R.S.), and (6) etiology (H.M.S.). The CCR was developed using software (<http://www.projectplace.com>) that allowed each group to collaborate and work concurrently. The respective groups devised initial drafts. The entire membership was then invited to provide comments and suggestions. Three members (C.C.B., K.N.E., and P.H.) integrated all documents into one CCR. All members were given another opportunity to review and edit the manuscript and make suggestions.

Clinical Consensus Report

Definition of RS

Consensus was reached that micrognathia is the primary characteristic of RS. Other mandatory diagnostic characteristics include glossoptosis and airway obstruction. Cleft palate is considered a common and additional feature. It was agreed on that management for all newborns with RS begins with assessing and treating airway obstruction (Table 1).

Micrognathia

Definition of Micrognathia

Several attempts have been made to define micrognathia. A cephalometry protocol by Pruzansky and Richmond² investigates mandibular size and craniofacial growth in patients with RS. However, the limited 2-dimensional nature of these images and the difficulty in accurately positioning and immobilizing the awake infant that is required to obtain precise cephalograms reduce the usefulness of this method. Computed tomography (CT) can generate 3-dimensional reconstructed images; however, the additional risks of radiation exposure during infancy and the lack of normative CT data are shortcomings. Hence, for most clinicians, the diagnosis of micrognathia is largely subjective. The literature is ambiguous in regard to catch-up mandibular growth in infancy.³⁻⁷ Studies^{8,9} show that

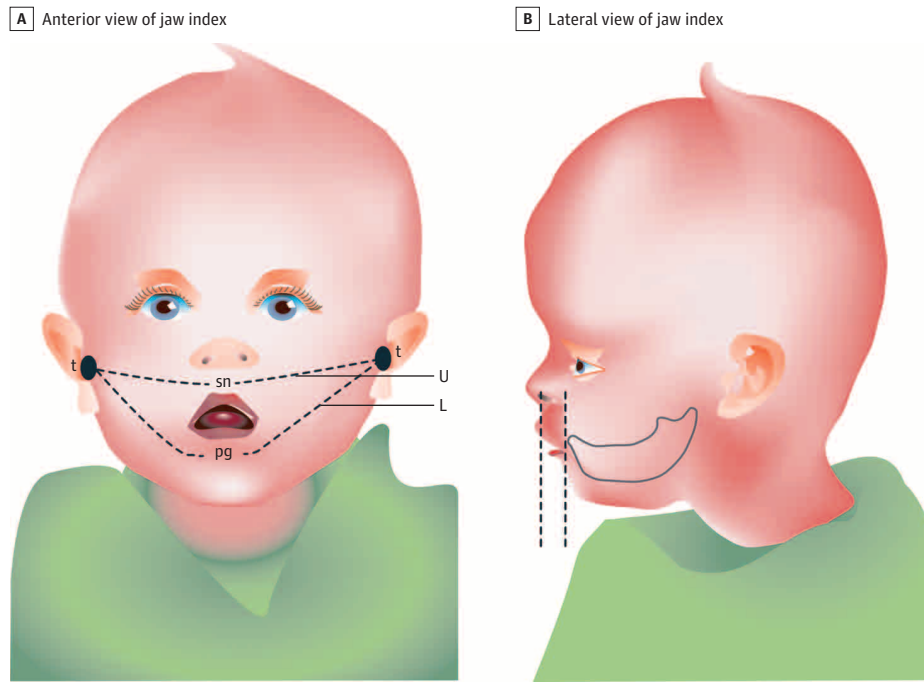
Table 1. Assessment of Diagnostic Features in Infants With Robin Sequence^a

Variable	Micrognathia	Glossoptosis	Upper Airway Obstruction
Initial assessment	Physical examination	Physical examination	Physical examination
Descriptors	Mandibular hypoplasia, overjet or MMD, and Jaw Index	Tongue tip position, base of tongue position	Stertor or stridor, increased work of breathing (supine)
Additional assessments	2-Dimensional and 3-dimensional photographs	Intraoral photographs, endoscopy	Gas exchange, sleep study
Descriptors	Facial angles	Intraoral crowding, level of airway narrowing	Desaturations and carbon dioxide retention, elevated apnea indexes (obstructive, mixed, and central), and growth velocity

Abbreviation: MMD, maxillomandibular discrepancy.

^a The Jaw Index is shown in the Figure. Images of glossoptosis are shown in eFigure 1 in the Supplement, and images of upper airway obstruction are shown in eFigure 2 in the Supplement.

Figure. The Jaw Index



A, Using a measurement tape, the distance from tragus (t) to tragus (t) is measured through subnasal (sn) and through pogonion (pg), producing upper arch distance (U) and lower arch distance (L) measurements, respectively. B, With a micrometer depth gauge (or tongue depressor), the anteroposterior distance between the alveolar processes of the upper and lower jaw (overbite) is measured. The Jaw Index is calculated using the following formula: $\text{Overbite} \times (\text{Upper Arch} / \text{Lower Arch})$. Published with permission from Ingrid Jansen (University Medical Center Utrecht, Utrecht, the Netherlands).

the micrognathic mandible in children with RS is small and retrognathic throughout childhood and adolescence, with characteristic morphological features, including deficiencies in the mandibular body and ramal lengths, more open gonial angle, and posteriorly inclined chin. Many individuals with RS also have upper jaw hypoplasia. Mandibular morphology and position in RS vary based on the specific diagnosis, the existence of mandibular hypodontia, and the presence of associated syndromes.^{8,10}

Assessment of Micrognathia

The objective evaluation of micrognathia varies depending on the severity of clinical findings and available investigative and treatment options. Mandibular size can be assessed using multiple modalities, including low-dose multisection CT, cone beam CT, lateral cephalograms, plaster casts, 3-dimensional photography, and direct measurements with rulers and calipers. Access to these modalities varies, and no criterion standard method exists to diagnose, characterize, and monitor micrognathia. The optimal tool to measure micrognathia during childhood should be widely available, reproducible, and cost-effective. The Jaw Index is a simple, in-person measure that may fulfill some of these requirements

(Figure).¹¹ The advantages of the Jaw Index are its simplicity, usability, and potential application to early screening and characterization of micrognathia in newborns. However, the Jaw Index may not reflect functional airway compromise, and validation of this tool in multiple populations is needed before adoption.^{12,13}

Glossoptosis

Definition of Glossoptosis

Glossoptosis is a dynamic clinical entity defined as displacement of the tongue base into the oropharynx and hypopharynx. The degree of glossoptosis and resultant upper airway obstruction can vary. In severe cases, the child will have inspiratory stertor or stridor with increased respiratory effort, possibly accompanied by apnea and cyanotic episodes. Children with mild glossoptosis may maintain an adequate airway when awake, sucking on a pacifier, or crying but have a heightened risk for sleep-disordered breathing (SDB).¹⁴ It is unclear whether the size of the tongue is consistent across the phenotypic spectrum of RS, and there is no definitive correlation between the degree of micrognathia and severity of glossoptosis.¹⁵ The findings of an electromyography study¹⁶ also suggest the presence of abnormal neuromuscular tone of the tongue in RS.

Assessment of Glossoptosis

Intraoral examination of the infant with glossoptosis may reveal a minimally visible, posteriorly positioned tongue, occasionally pulled up into a palatal cleft (eFigure 1 in the [Supplement](#)). While no criterion standard test exists to diagnose glossoptosis, at minimum, endoscopy allows for visualization of the tongue position in the oral cavity and oropharynx. Although some physicians prefer a transoral approach with a flexible endoscope, nasopharyngolaryngoscopy may be required to obtain a holistic view of the oropharyngeal region. Endoscopy can identify additional levels of airway narrowing other than at the tongue base, which is essential for determining optimal management.¹⁷ There are reports of using endoscopic images to further localize and categorize the oropharyngeal obstruction and to grade the severity of airway compromise.^{18,19} However, this technique is difficult to reproduce in the crying, awake infant, and small endoscopes produce less optimal image resolution. Also, respiratory problems primarily occur when a child with RS is relaxed or sleeping, especially when positioned supine. During nasopharyngolaryngoscopy, the awake child is often agitated, resulting in muscular tension, and the endoscopic characteristics may not mimic the crucial moments when obstruction occurs. Radiographic studies are considered to be of limited value and are not routinely used to diagnose glossoptosis. Newer dynamic imaging techniques, such as cine magnetic resonance imaging and multidetector CT, can better delineate and quantify the degree of obstruction at various sites in the upper airway but are not universally available and require the patient to be cooperative or intubated.^{20,21}

Respiratory Problems Due to Upper Airway Obstruction

Definition of Respiratory Problems

Glossoptosis is the primary cause of respiratory problems in RS (eFigure 2 in the [Supplement](#)), although multiple factors will influence a child's respiratory status. Associated with considerable morbidities affecting health, growth, and development, the recognition and treatment of respiratory problems are essential.²²⁻²⁶ The spectrum of respiratory compromise in RS is broad. Sleep-disordered breathing is a complex phenomenon of upper airway dysfunction during sleep and is characterized by snoring or increased respiratory effort due to upper airway resistance and pharyngeal collapsibility. Obstructive SDB includes a spectrum of clinical entities, including primary snoring, upper airway resistance syndrome, obstructive hypoventilation, and obstructive sleep apnea (OSA) syndrome.

Assessment of Respiratory Problems

The respiratory assessment in RS begins immediately after birth, although symptoms of respiratory compromise may develop over time. The intermittent nature of upper airway obstruction may lead to a delay in diagnosis and referral to a specialized team. While infants with life-threatening respiratory distress require direct respiratory support, most infants with RS can be observed clinically. Clinical signs of respiratory compromise in infants with RS include stertor or stridor, labored breathing, diaphoresis, apnea, and restlessness and can be assessed during sleep, in wakefulness, and with feeding.^{27,28} Positioning the child in a prone or lateral decubitus position will help to determine whether airway obstruction can be lessened. A jaw thrust maneuver pulls the tongue forward and is a tool that helps to illustrate airway obstruction localized to the tongue base. Additional airway-affected manifestations include feeding difficulties, aspiration,

and poor weight gain. Growth in children with RS may be reduced in early childhood relative to standard growth curves and counterparts with isolated cleft palate.²⁹⁻³² Poor growth may be a sign of chronic airway obstruction and increased energy expenditures due to greater work of breathing and feeding challenges.^{33,34} The presentation, timing, and severity of airway obstruction vary in RS, and reassessment of respiratory function and growth is crucial.

Objective tools can help to identify and quantify airway obstruction in RS. Carbon dioxide retention and hypoxemia are suggestive of more severe respiratory compromise. Although criteria to assess the degree of respiratory involvement in RS have been proposed,^{35,36} no widely accepted standards exist. Polysomnography (PSG) or polygraphy can quantify airway obstruction and identify comorbidities, such as central apnea.³⁷ Centers with efficient access to quality sleep studies likely detect a higher burden of SDB. A 3-tiered approach to decision making regarding PSG in infants with RS may be used. First, if no respiratory symptoms in the supine position during sleep and wakefulness are observed by an experienced clinician over an adequate duration of time, PSG may not be mandatory. Second, if any signs of respiratory distress are present in a patient with RS, referral to a specialized center with experience in airway assessments, including PSG, will optimize timely care. Third, if severe obstructive breathing necessitating immediate respiratory support is present, urgent treatment should be started, and PSG may not be feasible. While sleep studies offer valuable diagnostic usefulness and some centers advocate for polygraphy or PSG in all infants with RS, limited access prevents global acceptance.

PSG, Polygraphy, and Oximetry

Polygraphy or PSG performed for at least 4 to 6 hours with at least 3 hours of sleep allows adequate sleep assessment in infants with RS. Overnight PSG requires specialized equipment and personnel in a sleep laboratory. Polygraphy includes a measurement of body position, actigraphy, nasal flow, thoracic and abdominal belts, oxygen saturation, transcutaneous carbon dioxide, and video or nursing staff observation. Scoring respiratory events during sleep is guided by the American Academy of Sleep Medicine.³⁸ The numbers of mixed, obstructive, and central apneas and hypopneas per hour of total sleep time are recorded and can be expressed as an Apnea-Hypopnea Index or Mixed Obstructive Apnea Index.³⁹ Diagnostic thresholds for OSA in infants and young children remain debated, and various cutoff values have been reported in RS ([Table 2](#)). Multiple authors used only the number and depth of desaturations to describe the severity of respiratory distress, and inconsistent criteria were applied for those using PSG. Oximetry may be specific for detecting OSA, but it is not sensitive for detecting airway obstruction and OSA.⁵¹ Future algorithms stratifying respiratory severity in RS will likely take into account the physical examination, gas exchange abnormalities, PSG results, feeding problems, and growth.

Cleft Palate

Definition of Cleft Palate

Cleft palate in individuals with RS is traditionally described as being U-shaped. Clinically, this finding is not always the case. Current publications are contradictory about whether the cleft in RS is more extensive than the non-RS cleft palate, and existing studies have not sufficiently explored links between cleft shape and clinical severity.^{32,52-54}

Table 2. Overview of Criteria for Respiratory Compromise and Obstructive Sleep Apnea in Infants With Robin Sequence

Source	Oximetry Criteria
van den Elzen et al, ³⁰ 2001	Repeated Sao ₂ <90%
Wagener et al, ⁴⁰ 2003	Sao ₂ <90% saturation for >5% of 24 h or Sao ₂ <80%
Breugem et al, ⁴¹ 2008	Sao ₂ <93% for >5% total sleep time
Pradel et al, ⁴² 2009	Repeated cyanotic episodes and respiratory adaption disorder
Baciliero et al, ⁴³ 2011	Single Sao ₂ value <80% during sleeping, feeding, or wakefulness
Rogers et al, ⁴⁴ 2011	Sao ₂ consistently <90%
Abel et al, ⁴⁵ 2012	Mild is 3 clusters of desaturation with at least 3 dips <90%, moderate is 3 dips <85%, and severe is 3 dips <80%
Source	Polysomnography Measure and Criteria
Monasterio et al, ⁴⁶ 2002	Apnea: 5 episodes of apnea >10 s/h
Bravo et al, ²³ 2005	ORDI: >5 events per hour
Buchenau et al, ³⁹ 2007	MOAI: significant is >3 events per hour
Muntz et al, ⁴⁷ 2008	RDI: 1 to 5 events per hour is mild, >5 to 15 is moderate, and >15 is severe
MacLean et al, ⁴⁸ 2008	RDI: 1 to 5 events per hour is mild, >5 to <10 is moderate, ≥10 is severe
Anderson et al, ²² 2011	OAHl: 1 to <5 events per hour is mild, 5 to 10 is moderate, ≥10 is severe
Poets and Bacher, ⁴⁹ 2011	MOAI: ≥3 events per hour
van Lieshout et al, ⁵⁰ 2014	OAHl: 1 to 5 events per hour is mild, >5 to 24 is moderate, and >24 is severe

Abbreviations: MOAI, Mixed Obstructive Apnea Index; OAHl, Obstructive Apnea-Hypopnea Index; ORDI, Obstructive Respiratory Distress Index; RDI, Respiratory Distress Index; Sao₂, arterial oxygen saturation.

Table 3. Cleft Palate Classifications

Classification by Jensen et al ⁵⁵
0 Submucous cleft palate
1 Soft palate only
2 Soft palate and less than one-third hard palate
3 Soft palate and greater than one-third but less than two-thirds hard palate
4 Complete: soft and hard to incisive foramen
LAHSHAL code
Length: from Randall et al ⁵⁶
Measurements of the extent of the cleft at the time of surgery
Minimum to be measured: width at hard or soft palate junction with calipers at the time of surgery, both soft-tissue width and bony width
For investigation: methods by Godbout et al ⁵⁴ and Filho et al ⁵⁷
Shape: U-shaped or V-shaped
Photograph at the time of palate repair (with mirror)
Impression and model

Abbreviation: LAHSHAL indicates lip (right), alveolus (right), hard palate, soft palate, hard palate, alveolus (left), lip (lip).

Assessment of Cleft Palate

The extent of cleft palate can be documented in several ways. Characterization of the cleft width, length, extent, and shape can be performed using various cleft classification schemes (Table 3). Whether different aspects of the cleft influence either the degree of airway obstruction in the neonatal period or long-term speech development is unknown. Some evidence suggests that the cleft palate extent affects speech outcomes.^{56,58}

Feeding Problems

Definition of Feeding Problems

A spectrum of feeding problems in RS exists, which can be categorized into prolonged feeding times, reduced oral intake, unsafe oral feeding, and precipitation of respiratory compromise.⁵⁹ We propose that feeding disorders in infants with RS can be defined as the inability to take in adequate oral feeds efficiently to support normal growth (eg, >30 minutes with 1 bottle feed) or oral feeding that potentiates airway or respiratory compromise (eg, worsening airway obstruction and aspiration).

Successful feeding depends on a chain of complex, rhythmically coordinated, successive movements: suction is followed by swallowing, intermitted by breathing. Factors contributing to feeding problems in RS include the anatomic tongue position, upper airway obstruction, oropharyngeal dysfunction, and weak sucking mechanics, compounded by nasal regurgitation and difficulty generating adequate negative intraoral pressure with palatal clefting.⁶⁰ In addition, central or neuromotor disabilities may affect sucking and swallowing coordination,⁶¹ and feeding impairment is anticipated in children with RS and specific syndromes and genetic conditions.⁶⁰ Aspiration can result from disorganized suck-swallow-breath or primary swallowing dysfunction.^{12,62} Tachypnea and increased work of breathing negatively affect feeding mechanics and potentiate gastroesophageal reflux. Reflux-induced secretion production and airway inflammation disrupt the feeding-respiratory balance. Feeding problems may worsen during the first weeks of life and tend to improve from 4 months through the first year of life.

Assessment of Feeding Problems

Given the association with failure to thrive, swallowing dysfunction, and developmental delays, the recognition and treatment of feeding problems in RS are priorities. A clinical feeding assessment performed by experienced health care professionals in the first days and weeks of life will include evaluations of (1) quality of bottle feeding and feeding time, (2) effect of feeding on respiratory status, and (3) quality of weight gain and growth (expressed as the standard deviation for weight or weight gain). Complementary feeding investigations can help diagnose swallowing problems and guide therapeutic interventions. Fiber-optic endoscopic evaluation, videofluoroscopy, swallowing electromyography, and esophageal manometry have been described; however, there is no consensus regarding the validity and interpretation of these investigations in infants with RS.⁶¹⁻⁶⁴ Infant feeding specialists are valuable in delineating unique feeding problems. It is essential to define feeding problems together with parents and feeding experts as early as possible.

Etiological Diagnosis

Thorough assessment by a pediatrician and a clinical geneticist is advised for all children with suspected RS, with reassessment because a syndrome may become apparent at a later age. When patients have a co-occurring syndrome, such as Stickler syndrome, RS with Stickler syndrome is an appropriate diagnostic description. Because RS occurs as an isolated condition or as part of a syndrome or multiple-anomaly disorder, the diagnostic process in each context differs. Micrognathia is the hypothesized initiating event in RS.⁶⁵ However, micrognathia may be caused by multiple different etiologies. The OMIM catalog⁶⁶ lists 483 genetic disorders in which micrognathia is a clinical component,

and POSSUMweb lists 1080 genetic and teratogenic disorders with micrognathia.⁶⁷ The presence of additional anomalies suggests the possibility of an associated syndrome. In one series of 117 individuals with RS, 48% had isolated RS, 35% had identifiable syndromes, and 17% had RS presumed to be caused by a unique or unidentified syndrome.⁶⁸ In a 2012 analysis of genetic diagnoses in 125 patients with RS, 58% had associated syndromes, most commonly Stickler and Marshall syndromes.⁶⁷ Provision of a genetic diagnosis to a child and family has substantial effect on long-term management, including surveillance recommendations, perioperative precautions, and additional health care needs. **Table 4** summarizes the comprehensive examination and assessments of etiology for infants with RS. In addition, an echocardiogram is recommended if 22q11.2 deletion is suspected or if there is a murmur, with brain magnetic resonance imaging if there is abnormal muscle tone, fetal akinesia, arthrogryposis, or microcephaly, as well as skeletal radiographs for any child with RS who is suspected to have a skeletal dysplasia. Radiographs of the scapula, ribs, and long bones may help identify anomalies associated with genetic lesions around the *SOX9* gene.^{69,70} Ultimately, it may not be possible to advance the diagnosis beyond the concept of RS plus, in which the affected individual has RS with 1 or more additional anomalies that do not constitute a recognizable syndrome.

Summary and Future Directions

This CCR provides the basis and framework for the minimum assessment that is recommended for children with RS based on the opinions of a carefully chosen expert panel. Future consensus meetings will focus on measuring outcomes and identifying platforms for collaboration. Infrastructure development for standardized data collection and sharing is needed to build the evidence base that will inform future clinical practice guidelines.

Micrognathia

Currently, the diagnosis of micrognathia is largely subjective, and future studies should be conducted to define objective parameters. Reference guides for "normal" mandibular dimensions within various age, sex, and racial/ethnic groups have the potential for clinical application, may be useful in monitoring facial growth, and will help answer clinically important questions regarding the severity of the small mandible and mandibular catch-up growth in children with RS.

Glossoptosis

A careful physical examination with endoscopy is necessary to make the definitive diagnosis of glossoptosis. Currently, there are no objective parameters to describe glossoptosis severity. Future research should address 4 questions. First, is the tongue size, anatomy, and attachment to the mandible normal in children with RS? Second, is the tongue malposition related to poor neuromuscular control? Third, what is the role of newer dynamic imaging modalities in the workup of glossoptosis? Fourth, are there other contributing features, such as increased intrathoracic negative pressure?

Respiratory Problems

No widely accepted criteria exist to classify respiratory compromise in infants with RS. There is a scarcity of data concerning long-

Table 4. Comprehensive Assessment of the Etiology of Robin Sequence

Complete medical history and maternal health history	Focus attention on any teratogenic exposures, including medications, tobacco, and alcohol
3-Generation family history (pedigree)	Establish any history of similarly affected individuals, infant death, eye or vision problems, intellectual disabilities and developmental delays, and mode of inheritance if possible
Physical examination of the child	Include growth parameters, comprehensive dysmorphology assessment, and skeletal evaluation looking for skeletal dysplasias (eTable in the Supplement)
Physical assessment of both parents performed by a clinical geneticist	May identify microform cleft features, bifid uvula, micrognathia, or other features of a specific syndrome with variable phenotypic expression
Ophthalmologic examination	Check for the ocular features of Stickler syndrome during the neonatal period and 6 to 12 mo later in all infants with Robin sequence
Cytogenetic and/or molecular genetic investigations	Are recommended for children with Robin sequence and other congenital anomalies. Chromosomal disorders are common in children with multiple congenital anomalies, for whom chromosomal analysis or single-nucleotide polymorphism microarray is indicated. Although 22q11.2 deletion syndrome is an uncommon cause of Robin sequence, testing for 22q11.2 microdeletion can be considered, particularly in the presence of cardiac or renal anomalies, dysphagia, or hypocalcemia. Genetic testing for Stickler syndrome targeting the collagen genes (<i>COL2A1</i> , <i>COL11A1</i> , <i>COL11A2</i> , <i>COL9A1</i> , <i>COL9A2</i> , <i>COL9A3</i>) can be performed
Longitudinal follow-up by a clinical geneticist	Identify syndromic diagnoses that may become apparent later in childhood

term follow-up after airway treatment. Treatment efficacy is measurable when the same evaluation methods are used before and after an intervention in similar populations. In principle, treatment should be guided by clinical symptoms and available tests. Centers treating patients with RS will ideally have access to comprehensive respiratory evaluations, including overnight laboratory PSG. Simple, accessible tools that reliably diagnose respiratory problems in RS in the clinical and home settings will be useful. Home respiratory polygraphy in children may be a promising diagnostic tool.⁷¹ Telemonitoring and wearable home monitoring recorders warrant further study. Ideally, the tools and decision-making thresholds will be integrated into a respiratory treatment algorithm.

Cleft Palate

Clear phenotypic description of the cleft palate should be collected for all infants with RS. Collection of photographs or dental models can allow for independent blind assessment of the cleft and address reliability limitations. Cleft phenotypic information will help determine which, if any, methods of describing the extent of the cleft are most predictive of outcome.

Feeding Problems

Integration of parents' perception of feeding challenges and success will be useful in evaluating feeding in RS. Feeding assessments will ideally measure phenotype, oropharyngeal function, and standard feeding outcomes. Evaluations to consider with a research program include systematic assessment of feeding behaviors in infancy,⁷² cervical auscultation during feeding, esophageal manometry, and swallowing electromyography.

Etiological Diagnosis

There are thousands of single-gene disorders, many of which are exceedingly rare or possibly unique. While making a genetic diagnosis is challenging for many infants with RS, next-generation sequencing technologies allow for identification of rare disorders and may be informative in RS.⁷³ Clinical whole-exome sequencing has led to the diagnoses in up to one-third of individuals who had not received a diagnosis with other methods and will continue to be applied in research settings.^{74,75}

Conclusions

The diagnosis of RS can be made in children when there is micrognathia, glossoptosis, and upper airway obstruction. Using uni-

form definitions and comparable assessments of the functional and phenotypic features is a necessary first step in creating an evidence base. Prospective studies and the standard application of validated assessments will be necessary to guide standards and best practices for infants and children with RS. Research defining objective parameters on how we describe and compare these criteria will fill a large gap. Well-designed, prospective studies should also consider (1) engagement of parent stakeholders and (2) development of data standards for phenotypic, functional, and clinical descriptions. Comprehensive phenotypic and genetic investigations combined with a systematic severity classification have the potential to both guide care and facilitate outcome studies needed to advance care in RS. Collaboration will be essential to the progress in this rare yet important condition with lifelong effects on health and quality of life.

ARTICLE INFORMATION

Accepted for Publication: March 17, 2016.

Published Online: July 18, 2016.

doi:10.1001/jamapediatrics.2016.0796.

Author Affiliations: Department of Pediatric Plastic Surgery, Wilhelmina Children's Hospital, University Medical Centre Utrecht, Utrecht, the Netherlands (Breugem, Paes); Seattle Children's Craniofacial Center, Department of Pediatrics, University of Washington, Seattle (Evans); Department of Neonatology, University Hospital, Tübingen, Germany (Poets); Faculty of Dentistry, University of Toronto and The Hospital for Sick Children, Toronto, Ontario, Canada (Suri); Division of Plastic and Maxillofacial Surgery, Necker Children's Hospital, Paris, France (Picard); Department of Plastic and Reconstructive Surgery, Oslo University Hospital, Rikshospitalet, Oslo, Norway (Filip); Cleft Lip and Palate Service, University of Edinburgh, Royal Hospital for Sick Children, Edinburgh, Scotland (Mehendale); Division of Human Genetics, Department of Pediatrics, University of Cincinnati College of Medicine, Cincinnati Children's Hospital Medical Center, Cincinnati, Ohio (Saal); Division of Plastic Surgery, Academic Medical Center, Amsterdam, the Netherlands (Basart); Cleft and Craniofacial Center, Department of Plastic Surgery, Sri Ramachandra University, Chennai, India (Murthy); Department of Pediatric Intensive Care, Erasmus Medical Center, Sophia Children's Hospital, Rotterdam, the Netherlands (Joosten); Division of Ear, Nose and Throat Surgery, Wilhelmina Children's Hospital, University Medical Centre Utrecht, Utrecht, the Netherlands (Speleman); Department of Plastic and Craniomaxillofacial Surgery, Hospital de Clínicas de Porto Alegre, Rio Grande do Sul Federal University, Porto Alegre, Brazil (Collares); Department of Clinical Genetics, Wilhelmina Children's Hospital, University Medical Centre Utrecht, Utrecht, the Netherlands (van den Boogaard); Department of Maxillofacial Surgery, Wilhelmina Children's Hospital, University Medical Centre Utrecht, Utrecht, the Netherlands (Muradin); Department of Orthodontics, Dental Faculty, University of Oslo, Oslo, Norway (Andersson); Oslo Cleft Team, Department of Plastic Surgery, Oslo University Hospital, Rikshospitalet, Oslo, Norway (Andersson); Division of Maxillofacial Surgery, Osaka University Cleft Palate Center, Osaka, Japan (Kogo); Murdoch Children's Research Institute, Department of

Paediatrics, University of Melbourne, Royal Children's Hospital, Parkville, Australia (Farlie); Department of Plastic, Reconstructive and Hand Surgery, Vrije Universiteit University Medical Center, Amsterdam, the Netherlands (Don Griot); Dundee University Dental School, Dundee, Scotland (Mossey); West Midlands Cleft Service, Birmingham Children's Hospital, Birmingham, England (Slator); Department of General Pediatrics, National Referral Center for Pierre Robin Sequence, Necker Hospital, Paris Descartes University, Paris, France (Abadie); Division of Otolaryngology, Department of Surgery, Izaak Walton Killam Health Centre, Dalhousie University, Halifax, Nova Scotia, Canada (Hong).

Author Contributions: Dr Hong had full access to all the data in the study and takes responsibility for the integrity of the data and the accuracy of the data analysis. Drs Breugem and Evans are co-first authors.

Study concept and design: Breugem, Evans, Hong.

Drafting of the manuscript: All authors.

Administrative, technical, or material support: All authors.

Conflict of Interest Disclosures: None reported.

Funding/Support: No funding was obtained for this study. Nederlandse Organisatie voor Wetenschappelijk Onderzoek/Zorg-Onderzoek Nederland funding was obtained for the international consensus meeting.

Role of the Funder/Sponsor: The funding source had no role in the design and conduct of the study; collection, management, analysis, and interpretation of the data; preparation, review, or approval of the manuscript; and decision to submit the manuscript for publication.

Additional Contributions: We acknowledge all of the attendees of the first Robin sequence international consensus meeting and the community of Robin sequence researchers, whose valuable voices are appreciated.

REFERENCES

1. Vatlach S, Maas C, Poets CF. Birth prevalence and initial treatment of Robin sequence in Germany: a prospective epidemiologic study. *Orphanet J Rare Dis.* 2014;9:9.
2. Pruzansky S, Richmond JB. Growth of mandible in infants with micrognathia: clinical implications. *AMA Am J Dis Child.* 1954;88(1):29-42.

3. Figueroa AA, Glupker TJ, Fitz MG, BeGole EA. Mandible, tongue, and airway in Pierre Robin sequence: a longitudinal cephalometric study. *Cleft Palate Craniofac J.* 1991;28(4):425-434.
4. Amaratunga NA. A comparative clinical study of Pierre Robin syndrome and isolated cleft palate. *Br J Oral Maxillofac Surg.* 1989;27(6):451-458.
5. Hermann NV, Kreiborg S, Darvann TA, Jensen BL, Dahl E, Bolund S. Early craniofacial morphology and growth in children with nonsyndromic Robin Sequence. *Cleft Palate Craniofac J.* 2003;40(2):131-143.
6. Hermann NV, Kreiborg S, Darvann TA, Jensen BL, Dahl E, Bolund S. Craniofacial morphology and growth comparisons in children with Robin Sequence, isolated cleft palate, and unilateral complete cleft lip and palate. *Cleft Palate Craniofac J.* 2003;40(4):373-396.
7. Eriksen J, Hermann NV, Darvann TA, Kreiborg S. Early postnatal development of the mandible in children with isolated cleft palate and children with nonsyndromic Robin sequence. *Cleft Palate Craniofac J.* 2006;43(2):160-167.
8. Suri S, Ross RB, Tompson BD. Mandibular morphology and growth with and without hypodontia in subjects with Pierre Robin sequence. *Am J Orthod Dentofacial Orthop.* 2006;130(1):37-46.
9. Suri S, Ross RB, Tompson BD. Craniofacial morphology and adolescent facial growth in Pierre Robin sequence. *Am J Orthod Dentofacial Orthop.* 2010;137(6):763-774.
10. Rogers GF, Lim AA, Mulliken JB, Padwa BL. Effect of a syndromic diagnosis on mandibular size and sagittal position in Robin sequence. *J Oral Maxillofac Surg.* 2009;67(11):2323-2331.
11. van der Haven I, Mulder JW, van der Wal KG, Hage JJ, de Lange-de Klerk ES, Haumann TJ. The jaw index: new guide defining micrognathia in newborns. *Cleft Palate Craniofac J.* 1997;34(3):240-241.
12. Abadie V, Morisseau-Durand MP, Beyer C, Manach Y, Couly G. Brainstem dysfunction: a possible neuroembryological pathogenesis of isolated Pierre Robin sequence. *Eur J Pediatr.* 2002;161(5):275-280.
13. Vegter F, Hage JJ, Mulder JW. Pierre Robin syndrome: mandibular growth during the first year of life. *Ann Plast Surg.* 1999;42(2):154-157.

14. MacLean JE, Fitzsimons D, Fitzgerald DA, Waters KA. The spectrum of sleep-disordered breathing symptoms and respiratory events in infants with cleft lip and/or palate. *Arch Dis Child.* 2012;97(12):1058-1063.
15. Hong P, Kearns D. Airway characteristics of infants with Pierre Robin sequence who undergo mandibular distraction osteogenesis. *Ear Nose Throat J.* 2015;94(8):E25-E29.
16. Baudon JJ, Renault F, Goutet JM, et al. Motor dysfunction of the upper digestive tract in Pierre Robin sequence as assessed by sucking-swallowing electromyography and esophageal manometry. *J Pediatr.* 2002;140(6):719-723.
17. Hong P. A clinical narrative review of mandibular distraction osteogenesis in neonates with Pierre Robin sequence. *Int J Pediatr Otorhinolaryngol.* 2011;75(8):985-991.
18. Sher AE. Mechanisms of airway obstruction in Robin sequence: implications for treatment. *Cleft Palate Craniofac J.* 1992;29(3):224-231.
19. Soares D, Folbe AJ, Yoo G, Badr MS, Rowley JA, Lin HS. Drug-induced sleep endoscopy vs awake Müller's maneuver in the diagnosis of severe upper airway obstruction. *Otolaryngol Head Neck Surg.* 2013;148(1):151-156.
20. Slaats MA, Van Hoorenbeeck K, Van Eyck A, et al. Upper airway imaging in pediatric obstructive sleep apnea syndrome. *Sleep Med Rev.* 2015;21:59-71.
21. Cheung T, Oberoi S. Three dimensional assessment of the pharyngeal airway in individuals with non-syndromic cleft lip and palate. *PLoS One.* 2012;7(8):e43405. doi:10.1371/journal.pone.0043405.
22. Anderson IC, Sedaghat AR, McGinley BM, Redett RJ, Boss EF, Ishman SL. Prevalence and severity of obstructive sleep apnea and snoring in infants with Pierre Robin sequence. *Cleft Palate Craniofac J.* 2011;48(5):614-618.
23. Bravo G, Ysunza A, Arrieta J, Pamplona MC. Videonasopharyngoscopy is useful for identifying children with Pierre Robin sequence and severe obstructive sleep apnea. *Int J Pediatr Otorhinolaryngol.* 2005;69(1):27-33.
24. Gilhooly JT, Smith JD, Howell LL, Deschaine BL, Richey SL. Bedside polysomnography as an adjunct in the management of infants with Robin sequence. *Plast Reconstr Surg.* 1993;92(1):23-27.
25. Spicuzza L, Leonardi S, La Rosa M. Pediatric sleep apnea: early onset of the "syndrome"? *Sleep Med Rev.* 2009;13(2):111-122.
26. Wilson AC, Moore DJ, Moore MH, Martin AJ, Staugas RE, Kennedy JD. Late presentation of upper airway obstruction in Pierre Robin sequence. *Arch Dis Child.* 2000;83(5):435-438.
27. Kahn A, Groswasser J, Sottiaux M, et al. Clinical symptoms associated with brief obstructive sleep apnea in normal infants. *Sleep.* 1993;16(5):409-413.
28. Leiberman A, Tal A, Brama I, Sofer S. Obstructive sleep apnea in young infants. *Int J Pediatr Otorhinolaryngol.* 1988;16(1):39-44.
29. Becker M, Svensson H, Källén B. Birth weight, body length, and cranial circumference in newborns with cleft lip or palate. *Cleft Palate Craniofac J.* 1998;35(3):255-261.
30. van den Elzen AP, Semmekrot BA, Bongers EM, Huygen PL, Marres HA. Diagnosis and treatment of the Pierre Robin sequence: results of a retrospective clinical study and review of the literature. *Eur J Pediatr.* 2001;160(1):47-53.
31. Marques IL, Bettiol H, de Souza L, Barbieri MA, Bachega MI. Longitudinal study of the growth of infants with isolated Robin sequence considered being severe cases. *Acta Paediatr.* 2008;97(3):371-375.
32. Filip C, Feragen KB, Lemvik JS, et al. Multidisciplinary aspects of 104 patients with Pierre Robin sequence. *Cleft Palate Craniofac J.* 2015;52(6):732-742.
33. Daniel M, Bailey S, Walker K, et al. Airway, feeding and growth in infants with Robin sequence and sleep apnoea. *Int J Pediatr Otorhinolaryngol.* 2013;77(4):499-503.
34. Maas C, Poets CF. Initial treatment and early weight gain of children with Robin Sequence in Germany: a prospective epidemiological study. *Arch Dis Child Fetal Neonatal Ed.* 2014;99(6):F491-F494.
35. Cole A, Lynch P, Slator R. A new grading of Pierre Robin sequence. *Cleft Palate Craniofac J.* 2008;45(6):603-606.
36. Shen W, Jie C, Chen J, Zou J, Ji Y. Mandibular distraction osteogenesis to relieve Pierre Robin severe airway obstruction in neonates: indication and operation. *J Craniofac Surg.* 2009;20(suppl 2):1812-1816.
37. DeHaan KL, Seton C, Fitzgerald DA, Waters KA, MacLean JE. Polysomnography for the diagnosis of sleep disordered breathing in children under 2 years of age. *Pediatr Pulmonol.* 2015;50(12):1346-1353.
38. Berry RB, Brooks R, Gamaldo CE, et al. *The AASM Manual for the Scoring of Sleep and Associated Events: Rules, Terminology and Technical Specifications.* Vol 2.2. Darien, IL: American Academy of Sleep Medicine; 2015.
39. Buchenau W, Urschitz MS, Sautermeister J, et al. A randomized clinical trial of a new orthodontic appliance to improve upper airway obstruction in infants with Pierre Robin sequence. *J Pediatr.* 2007;151(2):145-149.
40. Wagener S, Rayatt SS, Tatman AJ, Gornall P, Slator R. Management of infants with Pierre Robin sequence. *Cleft Palate Craniofac J.* 2003;40(2):180-185.
41. Breugem CC, Olesen PR, Fitzpatrick DG, Courtemanche DJ. Subperiosteal release of the floor of the mouth in airway management in Pierre Robin sequence. *J Craniofac Surg.* 2008;19(3):609-615.
42. Pradel W, Lauer G, Dinger J, Eckelt U. Mandibular traction: an alternative treatment in infants with Pierre Robin sequence. *J Oral Maxillofac Surg.* 2009;67(10):2232-2237.
43. Baciliero U, Spanio di Spilimbergo S, Riga M, Padula E. Respiratory distress in Pierre Robin sequence: an experience with mandible traction by wires. *Int J Oral Maxillofac Surg.* 2011;40(5):464-470.
44. Rogers GF, Murthy AS, LaBrie RA, Mulliken JB. The GILLS score, part I: patient selection for tongue-lip adhesion in Robin sequence. *Plast Reconstr Surg.* 2011;128(1):243-251.
45. Abel F, Bajaj Y, Wyatt M, Wallis C. The successful use of the nasopharyngeal airway in Pierre Robin sequence: an 11-year experience. *Arch Dis Child.* 2012;97(4):331-334.
46. Monasterio FO, Drucker M, Molina F, Ysunza A. Distraction osteogenesis in Pierre Robin sequence and related respiratory problems in children. *J Craniofac Surg.* 2002;13(1):79-83.
47. Muntz H, Wilson M, Park A, Smith M, Grimmer JF. Sleep disordered breathing and obstructive sleep apnea in the cleft population. *Laryngoscope.* 2008;118(2):348-353.
48. MacLean JE, Fitzsimons D, Hayward P, Waters KA, Fitzgerald DA. The identification of children with cleft palate and sleep disordered breathing using a referral system. *Pediatr Pulmonol.* 2008;43(3):245-250.
49. Poets CF, Bacher M. Treatment of upper airway obstruction and feeding problems in Robin-like phenotype. *J Pediatr.* 2011;159(6):887-892.
50. van Lieshout MJ, Joosten KF, Hoeve HL, Mathijssen IM, Koudstaal MJ, Wolvius EB. Unravelling Robin sequence: considerations of diagnosis and treatment. *Laryngoscope.* 2014;124(5):E203-E209. doi:10.1002/lary.24437.
51. Marcus CL, Brooks LJ, Draper KA, et al; American Academy of Pediatrics. Diagnosis and management of childhood obstructive sleep apnea syndrome. *Pediatrics.* 2012;130(3):576-584.
52. Andersson EM, Sandvik L, Abyholm F, Semb G. Clefts of the secondary palate referred to the Oslo Cleft Team: epidemiology and cleft severity in 994 individuals. *Cleft Palate Craniofac J.* 2010;47(4):335-342.
53. Genisca AE, Frías JL, Broussard CS, et al; National Birth Defects Prevention Study. Orofacial clefts in the National Birth Defects Prevention Study, 1997-2004. *Am J Med Genet A.* 2009;149A(6):1149-1158.
54. Godbout A, Leclerc JE, Arteau-Gauthier I, Leclerc LD. Isolated versus Pierre Robin sequence cleft palates: are they different? *Cleft Palate Craniofac J.* 2014;51(4):406-411.
55. Jensen BL, Kreiborg S, Dahl E, Fogh-Andersen P. Cleft lip and palate in Denmark, 1976-1981: epidemiology, variability, and early somatic development. *Cleft Palate J.* 1988;25(3):258-269.
56. Randall P, LaRossa D, McWilliams BJ, Cohen M, Solut C, Jawad AF. Palatal length in cleft palate as a predictor of speech outcome. *Plast Reconstr Surg.* 2000;106(6):1254-1259.
57. Filho FR, Collares MV, Pinto R. Comparing three palatoplasty techniques to elongate the soft palate: a morphometric study. *Rev Soc Bras Cir Craniomaxilofac.* 2008;11:55.
58. Mahoney MH, Swan MC, Fisher DM. Prospective analysis of presurgical risk factors for outcomes in primary palatoplasty. *Plast Reconstr Surg.* 2013;132(1):165-171.
59. de Vries IA, Breugem CC, van der Heul AM, Eijkemans MJ, Kon M, Mink van der Molen AB. Prevalence of feeding disorders in children with cleft palate only: a retrospective study. *Clin Oral Investig.* 2014;18(5):1507-1515.
60. Miller CK. Feeding issues and interventions in infants and children with clefts and craniofacial syndromes. *Semin Speech Lang.* 2011;32(2):115-126.
61. Baujat G, Faure C, Zauouche A, Viarme F, Couly G, Abadie V. Oroesophageal motor disorders in Pierre Robin syndrome. *J Pediatr Gastroenterol Nutr.* 2001;32(3):297-302.

62. Renault F, Flores-Guevara R, Soupre V, Vazquez MP, Baudon JJ. Neurophysiological brainstem investigations in isolated Pierre Robin sequence. *Early Hum Dev.* 2000;58(2):141-152.
63. Marques IL, Prado-Oliveira R, Leirião VH, Jorge JC, de Souza L. Clinical and fiberoptic endoscopic evaluation of swallowing in Robin sequence treated with nasopharyngeal intubation: the importance of feeding facilitating techniques. *Cleft Palate Craniofac J.* 2010;47(5):523-529.
64. Pinheiro Neto CD, Alonso N, Sennes LU, Goldenberg DC, Santoro PP. Polysomnography evaluation and swallowing endoscopy of patients with Pierre Robin sequence. *Braz J Otorhinolaryngol.* 2009;75(6):852-856.
65. Robin P. A fall of the base of the tongue considered as a new cause of nasopharyngeal respiratory impairment: Pierre Robin sequence, a translation. 1923. *Plast Reconstr Surg.* 1994;93(6):1301-1303.
66. OMIM. Online Mendelian Inheritance in Man. <http://omim.org/>. Updated 2015. Accessed September 9, 2015.
67. Izumi K, Konczal LL, Mitchell AL, Jones MC. Underlying genetic diagnosis of Pierre Robin sequence: retrospective chart review at two children's hospitals and a systematic literature review. *J Pediatr.* 2012;160(4):645-650.e2. doi:10.1016/j.jpeds.2011.09.021.
68. Holder-Espinasse M, Abadie V, Cormier-Daire V, et al. Pierre Robin sequence: a series of 117 consecutive cases. *J Pediatr.* 2001;139(4):588-590.
69. Gordon CT, Tan TY, Benko S, Fitzpatrick D, Lyonnet S, Farlie PG. Long-range regulation at the *SOX9* locus in development and disease. *J Med Genet.* 2009;46(10):649-656.
70. Fukami M, Tsuchiya T, Takada S, et al. Complex genomic rearrangement in the *SOX9* 5' region in a patient with Pierre Robin sequence and hypoplastic left scapula. *Am J Med Genet A.* 2012;158A(7):1529-1534.
71. Alonso-Álvarez ML, Terán-Santos J, Ordax Carbajo E, et al. Reliability of home respiratory polygraphy for the diagnosis of sleep apnea in children. *Chest.* 2015;147(4):1020-1028.
72. Llewellyn CH, van Jaarsveld CH, Johnson L, Carnell S, Wardle J. Development and factor structure of the Baby Eating Behaviour Questionnaire in the Gemini birth cohort. *Appetite.* 2011;57(2):388-396.
73. Biesecker LG, Green RC. Diagnostic clinical genome and exome sequencing. *N Engl J Med.* 2014;370(25):2418-2425.
74. Yang Y, Muzny DM, Xia F, et al. Molecular findings among patients referred for clinical whole-exome sequencing. *JAMA.* 2014;312(18):1870-1879.
75. Biesecker LG, Biesecker BB. An approach to pediatric exome and genome sequencing. *Curr Opin Pediatr.* 2014;26(6):639-645.