

Bevacizumab Treatment for Subfoveal Choroidal Neovascularization From Causes Other Than Age-Related Macular Degeneration

Louis K. Chang, MD, PhD; Richard F. Spaide, MD; Claudia Brue, MD; K. Bailey Freund, MD; James M. Klancnik Jr, MD; Jason S. Slakter, MD

Objective: To report the results of intravitreal bevacizumab (Avastin) treatment for choroidal neovascularization (CNV) from causes other than age-related macular degeneration (AMD).

Methods: We performed a retrospective analysis of eyes that received intravitreal bevacizumab, 1.25 mg, for subfoveal non-AMD CNV at a referral-based retinal practice. Repeated treatment with intravitreal bevacizumab occurred if there were signs of persistent or recurrent exudation. The main outcome measure was visual acuity (VA).

Results: The study included 39 eyes of 36 patients with subfoveal CNV secondary to multifocal choroiditis (n=12), angioid streaks (n=11), myopic degeneration (n=10), idiopathic disease (n=4), or other disease (n=2).

The median baseline VA was 20/60 (logMAR, 0.48). The mean follow-up was 58.8 weeks, and the mean number of injections per eye was 3.4. After 3-month follow-up, the median VA was 20/30 (logMAR, 0.18) ($P=.004$ vs baseline). At last follow-up, the median VA was 20/40 (logMAR, 0.30). This remained an improvement compared with baseline ($P<.02$) but was worse than 3-month follow-up ($P<.03$). There was no correlation between underlying diagnosis and VA change during follow-up.

Conclusion: Subfoveal CNV secondary to non-AMD causes treated with intravitreal bevacizumab responded favorably and similarly, despite varying underlying etiologies.

Arch Ophthalmol. 2008;126(7):941-945

CHOROIDAL NEOVASCULARIZATION (CNV) may cause vision loss from the exudation of intraretinal or subretinal fluid, hemorrhage, or fibrosis. It most commonly occurs in the setting of age-related macular degeneration (AMD), but it may result from any perturbation of the retinal pigment epithelium-Bruch's membrane complex, including myopia, angioid streaks, multifocal choroiditis and panuveitis (MCP), presumed ocular histoplasmosis syndrome, and trauma.¹ Because of the high prevalence of AMD, much of our experience with treatment options, including photocoagulation,² photodynamic therapy (PDT),³ and pharmacotherapy,⁴⁻⁹ has been driven by our experience with AMD-related CNV. Inhibition of vascular endothelial growth factor A with intravitreal injection of an antibody fragment directed against vascular endothelial growth factor A, ranibizumab (Lucentis; Genentech, South San Francisco, California), was associated with improvement in visual and anatomical outcomes in randomized trials involving AMD-related CNV.^{6,7} Uncontrolled studies^{8,9} ex-

aminating intravitreal injection of a full-length antibody directed against vascular endothelial growth factor A, bevacizumab (Avastin; Genentech), showed anatomical and visual results that mirrored those seen in randomized trials of ranibizumab.

Based on the assumption of a common pathophysiology, intravitreal bevacizumab has been used in the treatment of CNV from etiologies other than AMD, including myopia,¹⁰⁻¹⁶ angioid streaks,^{17,18} central serous chorioretinopathy,¹⁹ punctate inner choroidopathy,¹⁹ and idiopathic CNV.²⁰ However, the sample size and follow-up of these studies were limited. Herein, we report the results of a retrospective analysis of 39 eyes treated with bevacizumab for CNV secondary to non-AMD causes.

METHODS

We conducted a retrospective study of 39 eyes in 36 patients with subfoveal non-AMD CNV treated with off-label intravitreal bevacizumab. Billing and medical record reviews were used to identify all patients who had received

Author Affiliations: Vitreous, Retina, Macula Consultants of New York, New York.

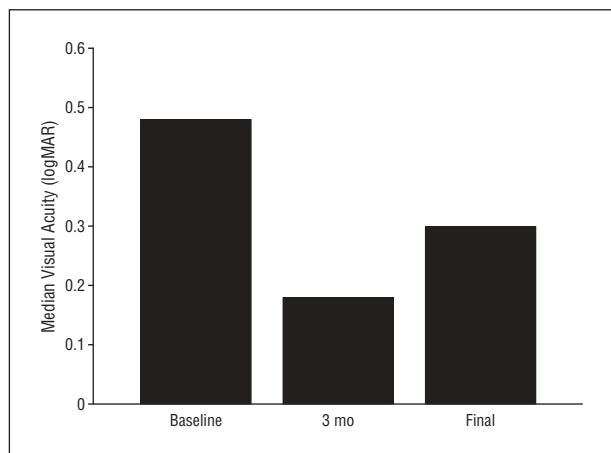


Figure 1. Median logMAR visual acuities of 39 eyes treated with intravitreal bevacizumab for non-age-related macular degeneration choroidal neovascularization at baseline, 3 months, and final follow-up (mean, 58.8 weeks). $P = .02$ for the difference between baseline and final follow-up, $P = .004$ for the difference between baseline and the 3-month follow-up, and $P = .03$ for the difference between the 3-month follow-up and the final follow-up.

bevacizumab injections. One patient who was treated with intravitreal bevacizumab elsewhere before the initial visit in our office was excluded from this analysis because baseline information could not be verified. Three patients were excluded for limited follow-up: 2 patients who were comanaged with other retina specialists were first treated in our office and had follow-up care with their referring physicians and 1 patient who was switched to ranibizumab therapy at the patient's request 4 weeks after the initial bevacizumab injection. This retrospective study had Western Institutional Review Board approval and was compliant with the Health Insurance Portability and Accountability Act.

Informed consent, including discussion of the off-label use of bevacizumab, was obtained from all the patients. Intravitreal bevacizumab (1.25 mg/0.05 mL) was administered according to a standard protocol.²¹ Patients were treated again at the discretion of the treating physician for evidence of persistent or recurrent exudation based on clinical examination, including fluorescein angiography and optical coherence tomography (OCT) (performed using the Stratus OCT; Zeiss Stratus, Dublin, California), although there were no formal predetermined criteria owing to the retrospective nature of this study. Patients were examined 1 week after intravitreal injection and at 4- to 6-week intervals. The OCT was used to assess central retinal thickness, which was measured manually. All concurrent local and systemic treatments, other than intravitreal ranibizumab, were allowed during the study.

All patients injected with bevacizumab for subfoveal non-AMD CNV were entered into a database. Statistical analysis for descriptive statistics was performed using a software program (SPSS version 12.0; SPSS Inc, Chicago, Illinois). Visual acuity (VA) was converted to logMAR before the analysis. The data obtained were analyzed using frequency and descriptive statistics. A decrease in VA was considered to have occurred if there was a doubling of the visual angle. If the visual angle at follow-up was half or less than the pretreatment value, VA was considered to be improved. Any outcome in between was considered to be the same as the pretreatment value. The main outcome measurements were VA and central retinal thickness measured using OCT. For each paired statistical test, casewise deletion of missing data was performed in case a variable had a missing value. The data were analyzed at 3-month intervals and at the most recent follow-up examination. A 1-sample Kol-

mogorov-Smirnov test was performed to determine whether the VA data analyzed were normally distributed. The distribution of the data was not normal, so VA data were analyzed using nonparametric tests. $P < .05$ was considered significant. The main outcome measure was VA, and the secondary outcome measure was change in central macular thickness.

RESULTS

BASELINE CHARACTERISTICS

The mean (SD) age of the 36 patients was 44.9 (13.7) years, and there were 24 women and 12 men. The underlying diagnoses associated with the subfoveal CNV were MCP in 12 eyes (31%), angioid streaks in 11 (28%), pathologic myopia in 10 (26%), idiopathic cause in 4 (10%), and other cause in 2 (5%). One patient in the other category had nanophthalmos with successful treatment of uveal effusion by the creation of scleral windows. However, several years later she developed CNV. The second patient in the other category had birdshot chorioretinopathy. Because of the few patients in the idiopathic and other cause groups, these categories were combined into a single group (idiopathic and other causes). Of the 39 eyes, 21 (54%) were previously treated with PDT, and 1 (3%) was previously treated with a single dose of intravitreal ranibizumab. Previous corticosteroid use was noted in 17 eyes (44%) (9 with MCP, 2 with pathologic myopia, 5 with angioid streaks, and 1 with birdshot chorioretinopathy).

The mean baseline VA was 20/89 (logMAR, 0.89), and the median VA was 20/60 (interquartile range [IQR], 20/30-20/200) (**Figure 1**). Baseline OCT was performed on 37 patients; the mean (SD) central foveal thickness was 249 (95) μm . The baseline logMAR VA showed no relation to the underlying cause of the CNV ($P = .75$, Kruskal-Wallis test).

FOLLOW-UP

At the third month of follow-up, median VA improved to 20/30 ($P = .004$ compared with baseline, Wilcoxon signed rank test; interquartile range, 20/25-20/60) (Figure 1). The most recent follow-up occurred a mean (SD) of 58.8 (29.1) weeks (median, 60 weeks; range, 9.9-111.7 weeks) after the first injection. The median VA at the most recent follow-up was 20/40 (interquartile range, 20/25-20/200), and mean (SD) central macular thickness was 204 (83) μm (Figure 1, **Figure 2**, and **Figure 3**). The VA at the most recent follow-up was significantly better than at baseline ($P = .02$) and worse than at 3-month follow-up ($P = .03$). The change in VA at the most recent follow-up did not show a strong relationship with the underlying retinal condition ($P = .07$, Kruskal-Wallis test). The mean (SD) number of intravitreal injections given was 3.4 (2.3), and the number given showed no relationship with the underlying condition ($P = .48$). At the most recent follow-up, VA was better in 12 eyes (31%), worse in 3 (8%), and the same in 24 (62%) compared with baseline. The magnitude of VA change was similar in patients undergoing PDT vs those not undergoing PDT before starting treatment with bevacizumab ($P = .91$).

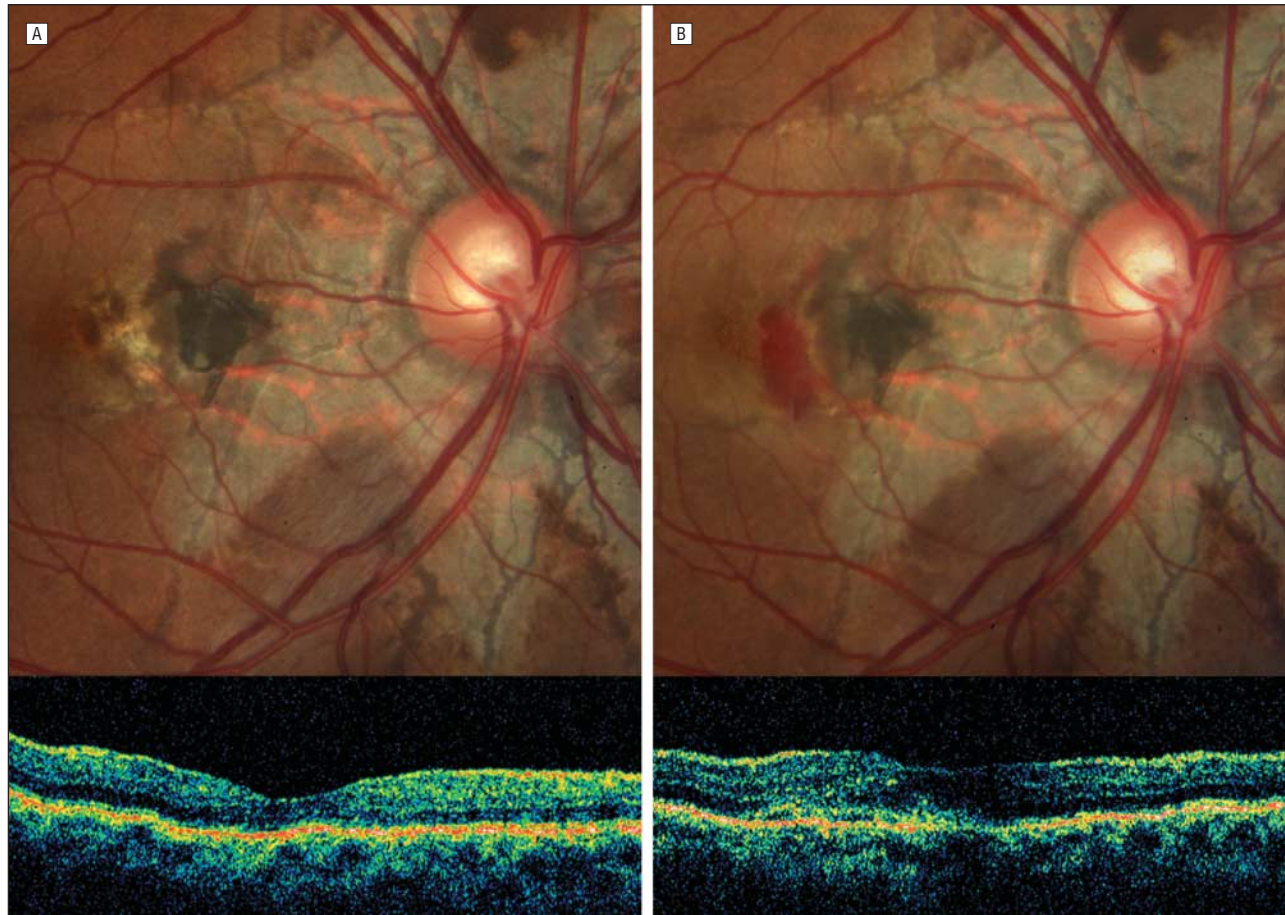


Figure 2. A 45-year-old man with pseudoxanthoma elasticum and choroidal neovascularization secondary to angioid streaks was previously treated with photodynamic therapy and intraocular triamcinolone. His visual acuity improved from 20/50 at baseline (A) to 20/25 with 9 bevacizumab injections during 70 weeks of follow-up (B).

CONCURRENT TREATMENT

Five eyes received concurrent local therapy during follow-up. One eye each with CNV from birdshot chorioretinopathy and MCP received intravitreal triamcinolone acetate. In the MCP group, 2 eyes also received sub-Tenon triamcinolone and 1 eye received sub-Tenon and intravitreal triamcinolone and PDT and underwent placement of a sustained-release fluocinolone acetonide insert (Retisert; Bausch & Lomb Inc, Rochester, New York). Five patients in the MCP group received oral prednisone during the study, 4 of whom also received mycophenolate mofetil (2 of whom also received tacrolimus).

SAFETY

A total of 132 intravitreal bevacizumab injections were given. No serious complications, including endophthalmitis, retinal tear or detachment, vitreous hemorrhage, or glaucoma, were observed. No study participants experienced stroke syndrome or a transient ischemic attack during follow-up.

COMMENT

Eyes with subfoveal CNV secondary to causes other than AMD that were treated with intravitreal bevacizumab

in this retrospective study had anatomical and functional improvement. We found that the underlying diagnosis was not related to either the visual outcome or the number of injections required. The median VA improved at 3-month follow-up and seemed to decline somewhat from that point to the most recent follow-up, which was slightly more than 1 year after the first injection.

In this study population, the response to bevacizumab treatment did not vary according to CNV etiology because there was no correlation between underlying cause of CNV and either final VA or number of injections. Bevacizumab treatment resulted in improved VA (halving of the visual angle) in 31% of eyes at the most recent follow-up. These results are in agreement with previous small studies of bevacizumab for non-AMD CNV, including idiopathic CNV (40% at 3 months)²⁰ or idiopathic CNV and CNV secondary to central serous chorioretinopathy or punctate inner choroidopathy (40% at 6 months)¹⁹ when the same criteria for visual improvement were applied. The observed rate of visual improvement was also similar to that seen in eyes with AMD-related CNV treated with either ranibizumab or bevacizumab, although obvious differences in methods exist.⁶⁻⁹ *Moderate vision gain* (defined by improvement of >15 letters) was reported in 33% and 40% of eyes treated with ranibizumab for CNV from AMD in

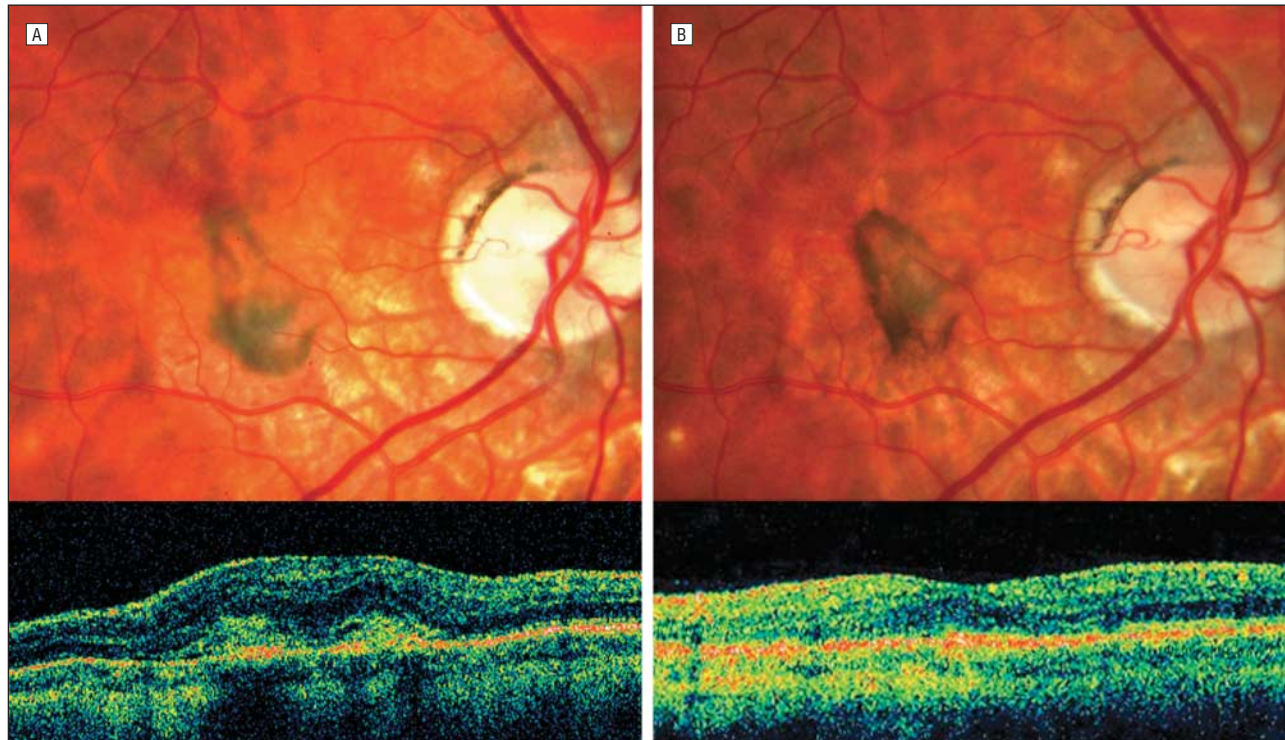


Figure 3. A 36-year-old man with choroidal neovascularization from multifocal choroiditis and panuveitis without previous treatment had a visual acuity of 20/50 OD at baseline (A) that improved to 20/40 after 5 bevacizumab injections 40 weeks later (B) (lower panel).

the ANCHOR (Anti-VEGF Antibody for the Treatment of Predominantly Classic Choroidal Neovascularization in Age-Related Macular Degeneration) and MARINA (Minimally Classic/Occult Trial of the Anti-VEGF Antibody Ranibizumab in the Treatment of Neovascular Age-Related Macular Degeneration) trials, respectively.^{6,7} The similar effect of anti-vascular endothelial growth factor treatment on CNV secondary to differing etiologies suggests that the VA response depends more on the CNV than on the underlying cause of the CNV.

The VA results in these patients compare favorably with those reported either for the natural history or with earlier treatments for cases of non-AMD CNV. Patients with CNV related to pathologic myopia have a poor natural history,²² and those treated with PDT in a randomized trial²³ did not show benefit compared with untreated controls. The risk of severe VA loss in patients with MCP seems to be reduced with immunosuppressive therapy,²⁴ and the most frequent cause of severe loss of acuity in patients with MCP is CNV.²⁴ However, once CNV starts and causes VA loss, additional therapy for CNV is indicated. Studies²⁵⁻²⁷ examining VA change after PDT for CNV secondary to MCP showed that there was no significant change from baseline. The VA outcome in patients with angioid streaks and CNV is poor. A group of untreated patients lost 6 lines in 18 months.²⁸ The VA results with PDT vary widely depending on the study cited; however, all outcomes were a loss of VA, including a 1-line VA loss after 1-year follow-up,²⁹ a 3-line loss at 42 months,³⁰ a 4.9-line loss at 18 months,²⁸ and a 9-line loss at 1 year.³¹ Most patients in this series, no matter what the underlying cause, underwent previous PDT before receiving intravitreal bevacizumab. It is possible that

the high proportion of previously treated eyes in this study may bias the visual outcomes because greater visual response to intravitreal bevacizumab has been seen in treatment-naïve eyes with AMD-related CNV.³²

The present patients showed a statistically significant improvement in VA at 3-month and last follow-up, but median VA was better at 3 months than at 58.8 weeks. In the PIER trial,³³ patients with CNV secondary to AMD received 3 monthly injections of ranibizumab followed by 1 injection every 3 months. Maximal improvement in mean VA compared with baseline was seen within 3 months and regressed to baseline levels at the end of 12-month follow-up, in contrast to the MARINA and ANCHOR trials,^{6,7} in which the visual gains were maintained after 3 months for the duration of the trials. The regression toward baseline suggests that this fixed dosing schedule may be suboptimal and may have resulted in some patients being undertreated. However, the PrONTO (Prospective Optical Coherence Tomography Imaging of Patients With Neovascular AMD Treated With Intravitreal Ranibizumab) study³⁴ used a strategy of 3 monthly injections of ranibizumab followed by as-needed treatment based largely on OCT evaluation—achieved visual outcomes at 12 months that seemed similar to those of the MARINA and ANCHOR trials but with fewer than half the number of intravitreal injections. Another consideration is that all the patients in the present study had an underlying disease associated with CNV that may have independently affected VA.

We used criteria for treatment somewhat similar to those used in the PrONTO study,³⁴ and we gave the patients a mean of 3.4 injections during the year of follow-up. However, this strategy may not be valid for non-AMD CNV,

and perhaps the patients were undertreated. Comparison of the PrONTO study with the present study to determine dosing frequency and treatment duration for AMD-related vs non-AMD-related CNV is confounded by important differences in study designs, including treatment protocol and frequency of follow-up, and the intraocular half-lives of bevacizumab and ranibizumab.³⁵ In addition, important qualitative differences exist between the populations in the 2 studies because the mean baseline retinal thickness in the present study, 249 μm , was much lower than the 394 μm seen in the PrONTO study,³⁴ suggesting that non-AMD-related CNV causes less macular thickening than does CNV secondary to AMD. By monitoring macular thickness in these patients, we may be setting a threshold that is not particularly sensitive.

The limitations of this study include a limited sample size, nonprotocol VA measurements performed using Snellen charts, lack of a control arm, and a retrospective design. However, the low prevalence of some of the underlying causes will likely preclude large, prospective, randomized, controlled trials similar to those for CNV secondary to AMD. Therefore, future treatment in these settings will likely be guided by smaller, uncontrolled, retrospective studies. The results of this study suggest that CNV from non-AMD-related causes may respond similarly in terms of anatomical and visual outcomes to intravitreal bevacizumab treatment and that extrapolation of experience from AMD-related CNV to non-AMD-related CNV cases may be valid.

Submitted for Publication: October 22, 2007; final revision received December 30, 2007; accepted January 9, 2008.

Correspondence: Richard F. Spaide, MD, Vitreous, Retina, Macula Consultants of New York, 460 Park Ave, Fifth Floor, New York, NY 10022 (rickspaide@yahoo.com).

Financial Disclosure: Dr Spaide receives research grant support from Genentech; and Dr Freund is on the Genentech Advisory Board.

Funding/Support: This study was supported in part by the LuEsther T. Mertz Retinal Research Center, the Manhattan Eye, Ear, and Throat Hospital, the Macula Foundation Inc, and the Heed Ophthalmic Foundation (Dr Chang).

REFERENCES

- Grossniklaus HE, Green WR. Choroidal neovascularization. *Am J Ophthalmol*. 2004;137(3):496-503.
- Macular Photocoagulation Study Group. Argon laser photocoagulation for senile macular degeneration: results of a randomized clinical trial. *Arch Ophthalmol*. 1982;100(6):912-918.
- Bressler NM; Treatment of Age-Related Macular Degeneration with Photodynamic Therapy (TAP) Study Group. Photodynamic therapy of subfoveal choroidal neovascularization in age-related macular degeneration with verteporfin: two-year results of 2 randomized clinical trials: TAP report 2. *Arch Ophthalmol*. 2001;119(2):198-207.
- Gragoudas ES, Adamis AP, Cunningham ET Jr, Feinsod M, Guyer DR; VEGF Inhibition Study in Ocular Neovascularization Clinical Trial Group. Pegaptanib for neovascular age-related macular degeneration. *N Engl J Med*. 2004;351(27):2805-2816.
- Heier JS, Antoszyk AN, Pavan PR, et al. Ranibizumab for treatment of neovascular age-related macular degeneration: a phase I/II multicenter, controlled, multidosage study [published online ahead of print February 14, 2006]. *Ophthalmology*. 2006;113(4):633-642.e4. doi:10.1016/j.ophtha.2005.10.052.
- Brown DM, Kaiser PK, Michels M, et al. Ranibizumab versus verteporfin for neovascular age-related macular degeneration. *N Engl J Med*. 2006;355(14):1432-1444.
- Rosenfeld PJ, Brown DM, Heier JS, et al. Ranibizumab for neovascular age-related macular degeneration. *N Engl J Med*. 2006;355(14):1419-1431.
- Spaide RF, Laud K, Fine HF, et al. Intravitreal bevacizumab treatment of choroidal neovascularization secondary to age-related macular degeneration. *Retina*. 2006;26(4):383-390.
- Avery RL, Pieramici DJ, Rabena MD, Castellarin AA, Nasir MA, Giust MJ. Intravitreal bevacizumab (Avastin) for neovascular age-related macular degeneration. *Ophthalmology*. 2006;113(3):363-372.
- Laud K, Spaide RF, Freund KB, et al. Treatment of choroidal neovascularization in pathologic myopia with intravitreal bevacizumab. *Retina*. 2006;26(8):960-963.
- Tewari A, Dhalla MS, Apte RS. Intravitreal bevacizumab for treatment of choroidal neovascularization in pathologic myopia. *Retina*. 2006;26(9):1093-1094.
- Sakaguchi H, Ikuno Y, Gomi F, et al. Intravitreal injection of bevacizumab for choroidal neovascularisation associated with pathologic myopia. *Br J Ophthalmol*. 2007;91(2):161-165.
- Yamamoto I, Rogers AH, Reichel E, et al. Intravitreal bevacizumab (Avastin) as treatment for subfoveal choroidal neovascularisation secondary to pathological myopia. *Br J Ophthalmol*. 2007;91(2):157-160.
- Hernández-Rojas ML, Quiroz-Mercado H, Dalma-Weiszhausz J, et al. Short-term effects of intravitreal bevacizumab for subfoveal choroidal neovascularization in pathologic myopia. *Retina*. 2007;27(6):707-712.
- Chan WM, Lai TY, Liu DT, Lam DS. Intravitreal bevacizumab (Avastin) for myopic choroidal neovascularization: six-month results of a prospective pilot study. *Ophthalmology*. 2007;114(12):2190-2196.
- Mandal S, Venkatesh P, Sampangi R, Garg S. Intravitreal bevacizumab (Avastin) as primary treatment for myopic choroidal neovascularization. *Eur J Ophthalmol*. 2007;17(4):620-626.
- Teixeira A, Moraes N, Farah ME, Bonomo PP. Choroidal neovascularization treated with intravitreal injection of bevacizumab (Avastin) in angioid streaks. *Acta Ophthalmol Scand*. 2006;84(6):835-836.
- Bhatnagar P, Freund KB, Spaide RF, et al. Intravitreal bevacizumab for the management of choroidal neovascularization in pseudoxanthoma elasticum. *Retina*. 2007;27(7):897-902.
- Chan WM, Lai TY, Liu DT, Lam DS. Intravitreal bevacizumab (Avastin) for choroidal neovascularization secondary to central serous chorioretinopathy, secondary to punctate inner choroidopathy, or of idiopathic origin. *Am J Ophthalmol*. 2007;143(6):977-983.
- Gomi F, Nishida K, Oshima Y, et al. Intravitreal bevacizumab for idiopathic choroidal neovascularization after previous injection with posterior subtenon triamcinolone. *Am J Ophthalmol*. 2007;143(3):507-510.
- Aiello LP, Brucker AJ, Chang S, et al. Evolving guidelines for intravitreal injections. *Retina*. 2004;24(5)(suppl):S3-S19.
- Bottoni F, Tilanus M. The natural history of juxtafoveal and subfoveal choroidal neovascularization in high myopia. *Int Ophthalmol*. 2001;24(5):249-255.
- Blinder KJ, Blumenkranz MS, Bressler NM, et al. Verteporfin therapy of subfoveal choroidal neovascularization in pathologic myopia: 2-year results of a randomized clinical trial: VIP report No. 3. *Ophthalmology*. 2003;110(4):667-673.
- Thorne JE, Wittenberg S, Jabs DA, et al. Multifocal choroiditis with panuveitis incidence of ocular complications and of loss of visual acuity. *Ophthalmology*. 2006;113(12):2310-2316.
- Spaide RF, Freund KB, Slakter J, et al. Treatment of subfoveal choroidal neovascularization associated with multifocal choroiditis and panuveitis with photodynamic therapy. *Retina*. 2002;22(5):545-549.
- Parodi MB, Di Crecchio L, Lanzetta P, et al. Photodynamic therapy with verteporfin for subfoveal choroidal neovascularization associated with multifocal choroiditis. *Am J Ophthalmol*. 2004;138(2):263-269.
- Gerth C, Spital G, Lommatzsch A, et al. Photodynamic therapy for choroidal neovascularization in patients with multifocal choroiditis and panuveitis. *Eur J Ophthalmol*. 2006;16(1):111-118.
- Arias L, Pujol O, Rubio M, Caminal J. Long-term results of photodynamic therapy for the treatment of choroidal neovascularization secondary to angioid streaks. *Graefes Arch Clin Exp Ophthalmol*. 2006;244(6):753-757.
- Browning AC, Chung AK, Ghanchi F, et al. Verteporfin photodynamic therapy of choroidal neovascularization in angioid streaks: one-year results of a prospective case series. *Ophthalmology*. 2005;112(7):1227-1231.
- Jurkles B, Bornfeld N, Schilling H. Photodynamic therapy using verteporfin for choroidal neovascularization associated with angioid streaks: long-term effects. *Ophthalmic Res*. 2006;38(4):209-217.
- Heimann H, Gelissen F, Wachtlin J, et al. Photodynamic therapy with verteporfin for choroidal neovascularization associated with angioid streaks. *Graefes Arch Clin Exp Ophthalmol*. 2005;243(11):1115-1123.
- Yoganathan P, Deramo VA, Lai JC, et al. Visual improvement following intravitreal bevacizumab (Avastin) in exudative age-related macular degeneration. *Retina*. 2006;26(9):994-998.
- Brown DM, Regillo CD. Anti-VEGF agents in the treatment of neovascular age-related macular degeneration: applying clinical trial results to the treatment of everyday patients. *Am J Ophthalmol*. 2007;144(4):627-637.
- Fung AE, Lalwani GA, Rosenfeld PJ, et al. An optical coherence tomography-guided, variable dosing regimen with intravitreal ranibizumab (Lucentis) for neovascular age-related macular degeneration. *Am J Ophthalmol*. 2007;143(4):566-583.
- Bakri SJ, Snyder MR, Reid JM, et al. Pharmacokinetics of intravitreal ranibizumab (Lucentis). *Ophthalmology*. 2007;114(12):2179-2182.