

Bilateral Nodular Pulmonary Tuberculosis Simulating Metastatic Lung Cancer

S Kant, R Kushwaha, S Verma, Sanjay

Citation

S Kant, R Kushwaha, S Verma, Sanjay. *Bilateral Nodular Pulmonary Tuberculosis Simulating Metastatic Lung Cancer*. The Internet Journal of Pulmonary Medicine. 2006 Volume 8 Number 1.

Abstract

Pulmonary tuberculosis presenting as multiple nodular opacity is very infrequent. Hereby we reported such type of case in a 40 year old lady, who presented with us with the complaints of exertional dyspnoea.

INTRODUCTION

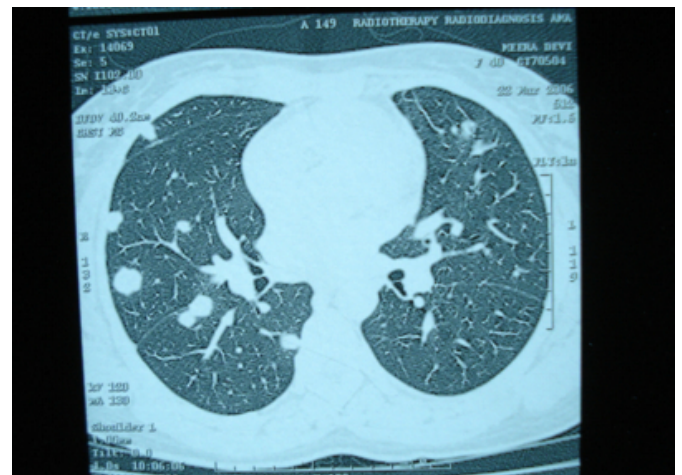Multiple pulmonary nodules on a chest radiograph present a challenge to the physician and secondaries in lung is supposed to be the commonest cause. The usual roentgenographic manifestations of pulmonary tuberculosis are parenchymal infiltrations in the apical and posterior segments of upper lobe. But multiple bilateral nodules in tuberculosis are unusual roentgenographic presentation. We hereby report such type of case in middle aged women.

CASE REPORT

A 40 year old female, house wife, was admitted to our department with complaints of exertional dyspnoea, low grade fever and decreased appetite for last six months. There was significant past history of three recurrent abortions ten years back. On general physical and respiratory system examination, there was no significant abnormality detected. Her haemogram, renal function and liver function tests were normal. Chest radiograph taken at the time of admission showed multiple large nodules in both lungs field. Her Computed Tomography thorax revealed the nodular shadows each measuring about 2cm in size suggestive of metastatic nodules (Fig:1).

Figure 1

Figure 1: Computed Tomography thorax revealed the nodular shadows each measuring about 2cm in size suggestive of metastatic nodules.

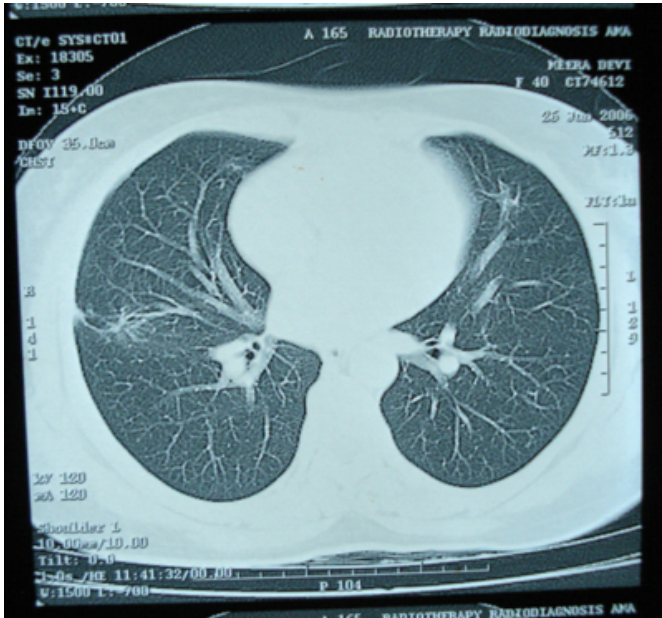


As thyroid, breast and genitourinary tract malignancies can very commonly present initially as lung metastasis, ultrasound neck for thyroid, mammography for breast nodule, ultrasound abdomen and gynaecological evaluation were done. But all investigations came out to be normal. Montoux test was negative. Bronchoscopy was done and bronchoalveolar lavage was negative for acid fast bacilli as well as malignant cells. Finally, Video assisted thorascopic guided lung biopsy was taken and the histopathology showed caseating granulomas suggestive of tubercular infection. Patient was put on four drugs anti tubercular therapy (Rifampicin, Isoniazid, Ethambutol and Pyrazinamide). After two and a half months of therapy, patient was asymptomatic and Computed Tomograph thorax

were absolutely normal (Fig:2)

Figure 2

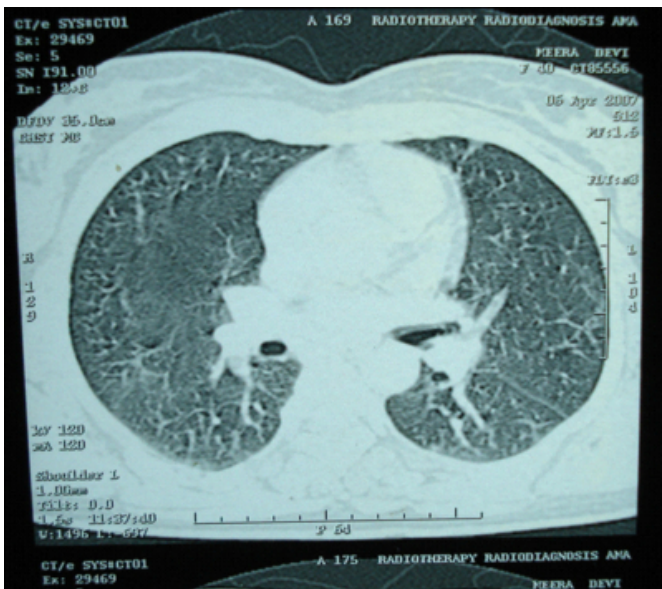
Figure 2: Computed Tomography thorax after three months of anti tubercular treatment revealed complete disappearance of nodular shadows.



Anti tubercular therapy was continued for further 7 months. Her Computed Tomograph thorax after five months of treatment completion revealed normal (Fig:3).

Figure 3

Figure 3: Computed Tomography thorax during follow-up after 5 months of anti tubercular treatment completion revealed no abnormality.



DISCUSSION

In case of multiple nodular shadows in lungs, it is common to suspect metastatic lung cancer at the outset. But the other causes in the differential diagnosis are lymphoma, benign tumours, septic emboli, inflammatory granulomas (tuberculosis, nocardiosis, fungal infection) or non-infectious granulomas (sarcoidosis, rheumatoid nodules, wegener's granulomatosis)^{3,4,5,6,7}. The presence of calcification may be diagnostic of a benign granuloma, but this does not prove that other nodules are also benign. Multiple pulmonary nodules are distinguished from multifocal patchy opacities in the same way as a solitary nodule is distinguished from a regional consolidation. They have a homogeneous appearance and sharply defined borders. Wide and even distribution throughout both lungs of discrete pinpoint nodules (sometimes referred to as micronodules) is the classic pattern of disseminated (miliary) tuberculosis. The frequency of this pattern in disseminated tuberculosis has varied in different series from 37.5%¹³ to 92.7%. The interval between hematogenous dissemination and the development of roentgenographic evidence of nodules may be several weeks. A tuberculoma of the lung is a round or oval lesion situated commonly in an upper lobe, the right more often than the left. Typically it is sharply circumscribed and has a diameter ranging from 0.5 to 4 cm or more. Multiple tuberculomas (two to four nodules) have also been reported. Most tuberculomas remain stable for many years, and many calcify. Sputum smears and cultures for tubercle bacilli usually give negative results. The diagnostic yield of bronchoscopy, bronchial brushings and transbronchial biopsy varies with the size and location of the tuberculoma, and in many cases a definitive diagnosis can be made only after Video-assisted thoracoscopic surgery (as in present case). In contrast to miliary nodules and tuberculomas, the pattern of multiple bilateral discrete pulmonary nodules (as seen in present case) is not generally recognized as a roentgenographic presentation of pulmonary tuberculosis. Rarely, as in our case, tuberculosis may present with this roentgenographic pattern.

In last we can conclude that whenever multiple nodular shadows are observed, it is common to suspect metastatic lung cancer at the outset but the differential diagnosis of pulmonary tuberculosis also should be kept in mind.

References

1. Khan MA, Kovnat DM, BACHUS B. Clinical and roentgenographic spectrum of pulmonary tuberculosis in the adult. *Ann J Med*, 1977;62: 31-34.
2. Singla R, Chokhani R, Jaiswal A, Menon MPS. Pulmonary tuberculosis mimicking metastatic nodules. *Ind J Tub*, 1991;38:33-36.

3. Felson B. The interstitium. In: Chest Roentgenology. Philadelphia: W.B. Saunders and Co.; 1992: 314-49.
4. Viggiano RW, Swensen SJ, Rosenow EC. Evaluation and management of solitary and multiple pulmonary nodules. Clin Chest Med 1992; 13: 83-95.
5. Fraser RG, Pare JA, Fraser RS. Multiple pulmonary nodules with or without cavitation. In: Diagnosis of Diseases of the Chest, 3rd edn. Philadelphia: W.B. Saunders and Co.; 1991: 3074-9.
6. Choi YH, Im JG, Han BK, Kim JH, Lee KY, Myoung NH. Thoracic manifestation of Churg- Strauss syndrome: radiologic and clinical findings. Chest 2000; 117: 117-24.
7. Saxena S, Joshi JM. Multiple Pulmonary Nodules. Indian J Chest Dis Allied Sci 2005; 47: 193-195
8. Suzuki A, Hujita A, Yamamoto H, Ohtsuka T, Tokuda H, Suyama T. Pulmonary tuberculosis presenting multiple nodular shadows in 4 patients. Nihon Kokyuki Gakkai Zassi, 1999; 37:538-42.

Author Information

Surya Kant

Professor, Department of Pulmonary Medicine, C.S.M. Medical University

RAS Kushwaha

Assistant Professor, Department of Pulmonary Medicine, C.S.M. Medical University

Sanjay Kumar Verma

Senior Resident, Department of Pulmonary Medicine, C.S.M. Medical University

Sanjay

Senior Resident, Department of Pulmonary Medicine, C.S.M. Medical University