

Biliary stenting of an iatrogenic esophageal perforation following corrosive esophagitis in a 5-year-old child

Most esophageal perforations are iatrogenic in origin (0.01%–55%) [1–3], and traumatic defects are still associated with high mortality, ranging between 12% and 50% [4]. Clinically, early identification and treatment of the problem is necessary, but guidelines for effective management have not been established.

A 5-year-old girl developed high-grade corrosive esophagitis after ingesting a caustic solution (● Fig. 1). This resulted in the formation of a long esophageal stricture, which was causing severe dysphagia. Three and a half months after the incident, the stricture, which could not be passed with a 5.9-mm gastroscop (GIF-XP 160, Olympus, Tokyo, Japan) (● Fig. 2) was dilated with a balloon to 6 mm; 48 hours later the patient developed septic mediastinitis because of a perforation. A computed tomography (CT) scan showed leakage of contrast in the right pleural cavity, approximately 4 cm above the cardia (● Fig. 3). Owing to a lack of pediatric treatment options for severe sepsis in combination with a pronounced esophageal stricture, the perforation was sealed with a partially covered biliary stent (Niti-S biliary stent, size 10 × 80 × 70 mm, Taewoong Medical Co. Ltd., Gyeonggi-go, South Korea) (● Fig. 4). Two and a half months later, the patient underwent esophageal resection and reconstruction with colon interposition, and the stent was removed intraoperatively. The post-operative complication of an anastomotic stricture at 14 cm was successfully treated with balloon dilatation.

Corrosive esophagitis with stricture formation is a severe complication of caustic solution ingestion [5]. The state-of-the-art treatment is endoscopic dilatation or bougienation, which itself is associated with a high risk of perforation. In our case, the complication led us to consider an unusual treatment, since a long stenosis in a small child cannot be treated with conventional stenting. We were able to seal

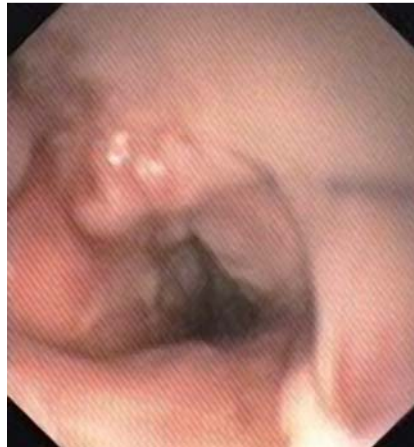

Fig. 1 Third-degree burn: esophagitis after ingestion of a caustic solution.

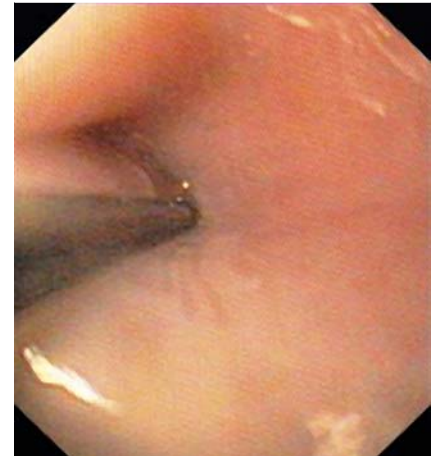


Fig. 2 The stricture with an endoscopically placed guide wire before balloon dilatation.

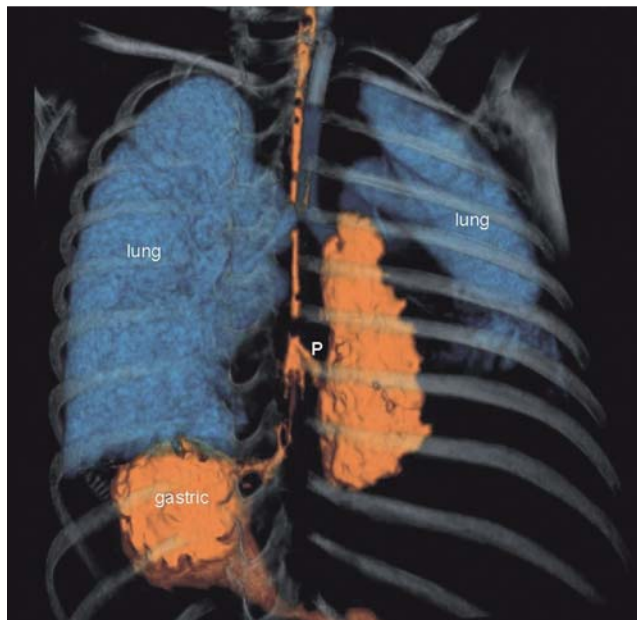


Fig. 3 Chest computed tomography three-dimensional reconstruction showing the esophageal perforation (P).

the perforation with a biliary stent, which allowed the esophagus to function until definitive repair could be attempted as primary repair was not possible.

Endoscopy_UCTN_Code_TTT_1AO_2AZ

O. Ruthmann, S. Richter, A. Fischer, K. D. Rückauer, U. T. Hopt, H. J. Schrag
Department of General and Visceral Surgery, Albert-Ludwigs-University, Freiburg, Germany

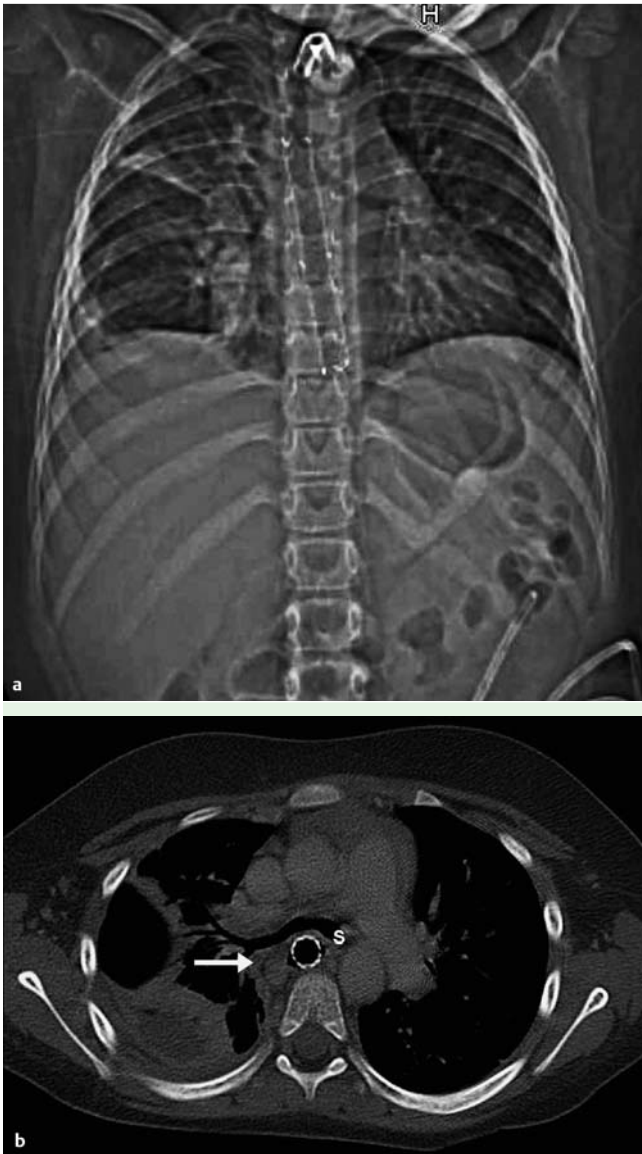


Fig. 4 a Chest radiograph showing the final position of the stent. b Computed tomographic scan of the esophagus showing the final position of the stent (S); fluid is visible in the paraesophageal space (arrow).

References

- 1 Tytgat GNJ. Endoskopisch geführte Dilatation und Prothesenimplantation. In: Ottenjann R, Classen M (eds). Gastroenterologische Endoskopie. Stuttgart: Enke, 1991: 519–526
- 2 Silvis SE, Nebel O, Rogers G et al. Endoscopic complications. Results of the 1974 American Society for Gastrointestinal Endoscopy Survey. 1976; 1: 928–930
- 3 Huber-Lang M, Henne-Bruns D, Schmitz B, Wuerl P. Esophageal perforation: principles of diagnosis and surgical management. 2006; 36: 332–340
- 4 Fischer A, Thomusch O, Benz S et al. Non-operative treatment of 15 benign esophageal perforations with self-expandable covered metal stents. Ann Thorac Surg 2006; 81: 467–472
- 5 Huang YC, Ni YH, Lai HS, Chang MH. Corrosive esophagitis in children. Pediatr Surg Int 2004; 20: 207–210

Bibliography

DOI 10.1055/s-0029-1214939

Endoscopy 2009; 41: E325–E326

© Georg Thieme Verlag KG Stuttgart · New York ·

ISSN 0013-726X

Corresponding author

Assistant Professor Dr. H. J. Schrag

Department of General and Visceral Surgery

Albert-Ludwigs-University

Hugstetter Str. 55

D-79106 Freiburg im Breisgau

Germany

Fax: +49-0761-2702543

hans-juergen.schrag@uniklinik-freiburg.de