

Biology of *Trypanosoma (Trypanozoon) evansi* in experimental heterologous mammalian hosts

K. K. Misra · S. Roy · A. Choudhury

Received: 16 July 2014 / Accepted: 9 December 2014 / Published online: 20 January 2015
© Indian Society for Parasitology 2015

Abstract *Trypanosoma (Trypanozoon) evansi* is a causative agent of the dreadful mammalian disease trypanosomiasis or ‘Surra’ and carried as a latent parasite in domestic cattle but occasionally proves fatal when transmitted to horses and camel. Sporadic outbreak of ‘Surra’ to different animals (beside their natural hosts) reminds that *T. evansi* may be zoonotic, as their close relative cause sleeping sickness to human being. This haemoflagellate is mechanically transmitted by horse fly and its effect on different host varies depending on certain factors including the effectiveness of transmission by mechanical vector, the suitability and susceptibility of the host as well as most importantly the ability of the disease establishment of parasite to adapt itself to the host’s resistance, etc. The course of the disease caused by *T. evansi* is similar to that of human sleeping sickness caused by *T. (T.) brucei gambiense*. The target organs and symptoms show close similarity. *T. evansi* can successfully be transmitted among unnatural hosts i.e., other classes of vertebrates, like chicken. In transmission experiments, the unnatural hosts may sometimes induce profound changes in the biology of trypanosomes. Hence, in present study the observations are the biology of different morphological changes of *T. evansi* as well as its ability of disease formation

within some heterologous mammal viz., albino rat, guinea-pig, bandicoot, mongoose, domestic cat and common monkey. Blood smears of infected albino rats, bandicoot, and mongoose revealed only monomorphic form. Interestingly, blood smears of infected cat and monkey, *T. evansi* shows slender trypomastigote form and short intermediate form whereas organ smears shows other two forms of haemoflagellate viz., sphaeromastigote and amastigote form. The haemoflagellate maintains a common reproductive cycle in all the experimental heterologous hosts whereas disease symptoms differ. *T. evansi* infected cat and monkey shows nervous symptoms. Infected monkey expresses some symptoms similar to that of human sleeping sickness disease. Thus the paper highlights zoonotic potentialities of *T. evansi*.

Keywords Bandicoot rat · Cat · Monkey · Pleomorphic forms · Surra · *Trypanosoma evansi* · Zoonosis

Introduction

Trypanosoma (Trypanozoon) evansi Steel 1885 is world wide in distribution. It was the first pathogenic trypanosome discovered, causing the dreadful mammalian disease ‘Surra’, which is known in India since time immemorial. Morphologically *T. (T.) evansi* (commonly termed as *T. evansi*) is typically represented almost exclusively by thin trypomastigotes comprising slender and intermediate forms corresponding to those in *T. (T.) brucei* (Hoare 1956, 1972). Hoare’s standard measurement of *T. evansi* is 15–34 µm in length with a mean of 24 µm. The principal hosts of *T. evansi* are domestic animals viz., dromedaries, cattle, equines and dogs. In addition to domesticated animals, the presence of *T. evansi* was recorded from diverse wild mammals, some of

K. K. Misra
Department of Zoology, R. B. C. College, Naihati, India

Present Address:
K. K. Misra (✉)
Department of Zoology, Asutosh College, Kolkata, India
e-mail: misrakk@vsnl.com

S. Roy
City College, Kolkata, India

A. Choudhury
University of Calcutta, Kolkata, India

which were regarded as reservoir hosts of Surra. The disease is mechanically transmitted by horse fly.

Sporadic out break of ‘Surra’ to different animals (beside their natural hosts) reminds that *T. evansi* may be zoonotic, as their close relative cause sleeping sickness to human being. Moreover, *T. evansi* proved itself as euryxenous parasite.

Trypanosoma evansi is morphologically monomorphic, represented by its trypomastigote stage comprising of the predominant long slender forms. Some intermediate and short stumpy forms corresponding to those of *T. brucei* (Hoare 1956) are found. Thus pleomorphic forms are not uncommon (Ormerod and Venkatesan 1971a, b; Choudhury and Misra 1973). *T. evansi* is pathogenic to most domestic animals but its effect on different host varies depending on certain factors.

The course of the disease caused by *T. evansi* is similar to that of human sleeping sickness caused by *T. (T.) brucei gambiense*. The target organs and symptoms show close similarity. Morales and Carreno (1976) reported that *T. evansi* and *T. brucei* could produce similar disease manifestation in laboratory animals.

Trypanosoma evansi is the causative germ for cattle trypanosomiasis in India, and are carried as a latent parasite in domestic cattle but occasionally proves fatal when transmitted to horses and camel (Hoare 1972). Surra is more chronic in camels than in horses. Although cattle, water buffalo and pigs are found to be infected in most enzootic areas, the infection in these animals is usually devoid of clinical symptoms and is seldom fatal. Consequently these animals serve as good reservoirs for *T. evansi* in enzootic areas, especially in India, the Far East, and in Central and South America. In Bengal (India and Bangladesh combined) *T. evansi* found in cattle usually produces symptom but sometimes breaks out in epidemic form producing acute trypanosomiasis which takes a heavy toll of cattle population. *T. evansi* also occasionally infects zoo tiger and in dogs (Manohar et al. 2003; Varshney et al. 2003).

The *T. brucei* group is one of the most important groups of trypanosomes. *T. evansi* is considered to be a distinct species of the *brucei* group (subgenus *Trypanozoon*) (Hoare 1972). Morales and Carreno (1976) reported that *T. evansi* and *T. brucei* species could produce similar clinical and pathological lesions in laboratory animals. However both species seem to produce intravascular and extravascular lesions in their hosts (Losos and Ikede 1972; Biswas et al. 2001, 2010; Rodrigues et al. 2009; Bal et al. 2012). Prasad et al. (2013) studied the prevalence of trypanosomiasis in certain areas of Andhra Pradesh.

The establishment of trypanosome infection in mammals depends on various factors including the effectiveness of transmission by mechanical vector, the suitability and susceptibility of the host, the ability of the established

parasite to adapt itself to the host’s resistance, etc. *T. evansi* can successfully be transmitted among unnatural hosts i.e. other classes of vertebrates, like chicken (Misra et al. 1976) and in various other mammals. In transmission experiments, the unnatural hosts may sometimes induce profound changes in the biology of trypanosomes including the development of dyskinetoplasty and subsequent growth pattern of normal and dyskinetoplastic forms leading to competitive exclusion of the later mutant morph (Misra 1986). The zoonotic potentiality of *T. evansi* in India was previously argued (Misra 1981). These were noted after they had been maintained for sometime in unnatural hosts. These include (1) changes in morphology and physiology of the parasite and (2) changes in virulence. All these contribute to the pathology of the host.

The present study aims to investigate the biology of *Trypanosoma (Trypanozoon) evansi* in experimental heterologous hosts, viz., albino rat, guineapig, bandicoot rat, Indian mongoose, domestic cat and common monkey to authenticate the virulence and zoonotic potentiality of the haemoflagellate.

Materials and methods

For the experiment, BB24 strain of *Trypanosoma (Trypanozoon) evansi* was isolated from a cow and maintained in albino rats and guineapig. These strains were obtained from Bengal Veterinary College, Kolkata. The experiment was repeated thrice. The experimental mammals (albino rat, guineapig, bandicoot rat, Indian mongoose, domestic cat and common monkey) were purchased from the local dealers. The animals were kept in moderately large cages and fed with proper diet. Only the common monkeys were kept in iron cage. They were supplied with prepared food such as: boiled rice with fish for cats; fish and meat for mongoose; gram and rice with vegetables for white rats and guineapig; apple snails for bandicoot and bread, banana, wet gram and guava (ad libitum) for monkeys.

Animal cages were cleaned thrice a week and disinfected with Lyzol. Blood films were drawn from the suitable parts of the host body:

White rat	Tail tip
Guineapig	Ear
Bandicoot	Tail tip
Mongoose	Tail tip
Domestic cat	Ear
Common monkey	Ear

Blood/tissue smears were air dried, fixed in absolute methanol (acetone free) for 5 min and stained in Giemsa/Leishman stain for 3 h (1:1 dilution in glass distilled water at 7.0–7.2 pH). After staining the smears were washed with glass distilled water (pH 7.0–7.2) and then air dried. Light

microscopy was employed for examination of the smears. The fresh blood films containing living materials were examined immediately after preparation. The inoculum was usually prepared from the peripheral or heart blood of the donor host mixed with enough physiological saline (1:1 dilution with citrated saline) solution to prevent clotting. The inoculum was injected in the experimental hosts with a top tuberculin syringe intraperitoneally or intramuscularly. The amount of inoculum was determined in accordance with the body weight and type of the recipient hosts. Appearance of trypanosomes in circulation and intensity of parasitaemia during and in between peaks were studied by means of in vivo preparation with citrated saline. Rectal temperature and general health conditions were recorded daily, clinical thermometer was used placing through the anus in case of experimental cats and monkeys only and general health conditions were checked by examining the pulse rate, eye lid, eye ball and cornea for oedematous swelling.

[Studies on mongoose, cat, and monkey were done during 1972–1975. After that the experiments were could not be continued due to legislative restriction for the use of animals in biological research. However, work on bandicoot rat was continued as this animal is considered as pest.]

The measurements of trypanosomes were followed after Davis (1952) with a slight modification in the procedure. Midline of the trypanosomes were drawn directly on the paper using camera lucida, marking the position of kinetoplast, nucleus, free flagellum and breadth of the body length was correctly measured. Camera lucida drawings of the trypanosomes were also made using prism. The black and white photomicrographs were taken.

Observations

Experiment-I

On rodents

Albino rat *Trypanosoma evansi* inoculated to white rats does not appear in their blood till the fourth day of inoculation. On the fifth day after introduction, trypanosomes were found in the peripheral blood. Population density of trypanosomes in the blood reaches its peak on the sixth day. Animals succumbed to infection in between sixth and eighth day of inoculation. Out of 40 albino rats inoculated with *T. evansi* only one survived till tenth day of inoculation.

Stained preparations of blood smears of infected albino rats revealed that all the trypanosomes found in the blood were monomorphic (Figs. 1–3) coinciding *T. evansi* mensurally. No sporadic occurrence of the stumpy forms was found among 108 trypanosomes measured by the author.

Reproductive cycle On intraperitoneal inoculation by syringe, parasite readily invade the internal organs, namely none marrow, spleen, liver, kidney, etc. and start multiplication by usual process. Fifth day after inoculation parasites increase in number and appear in the peripheral blood. Few trypanosomes were found to multiply in the peripheral blood.

Guineapig (Cavia porcellus) No details study of pathogenicity or site of infection was studied in guineapigs. Mainly they were used in maintaining the *T. evansi* strain. It has been observed that unlike the other rodents employed in this study *T. evansi* infection in guineapig runs a mixed course. After the intraperitoneal inoculation of *T. evansi*, the parasites show some regular peaks but later parasitaemia becomes irregular. There is no hard and fast rule of number of peaks that guineapigs can tolerate. Sometimes they died after the first peak of infection and sometimes survived till 4 months. The course of infection or the reproductive cycle more or less follows the similar patten as shown by the previous rodents. But the population density is lower than the foregoing experimental rodents. In all the peaks the parasites maintain their monomorphic state.

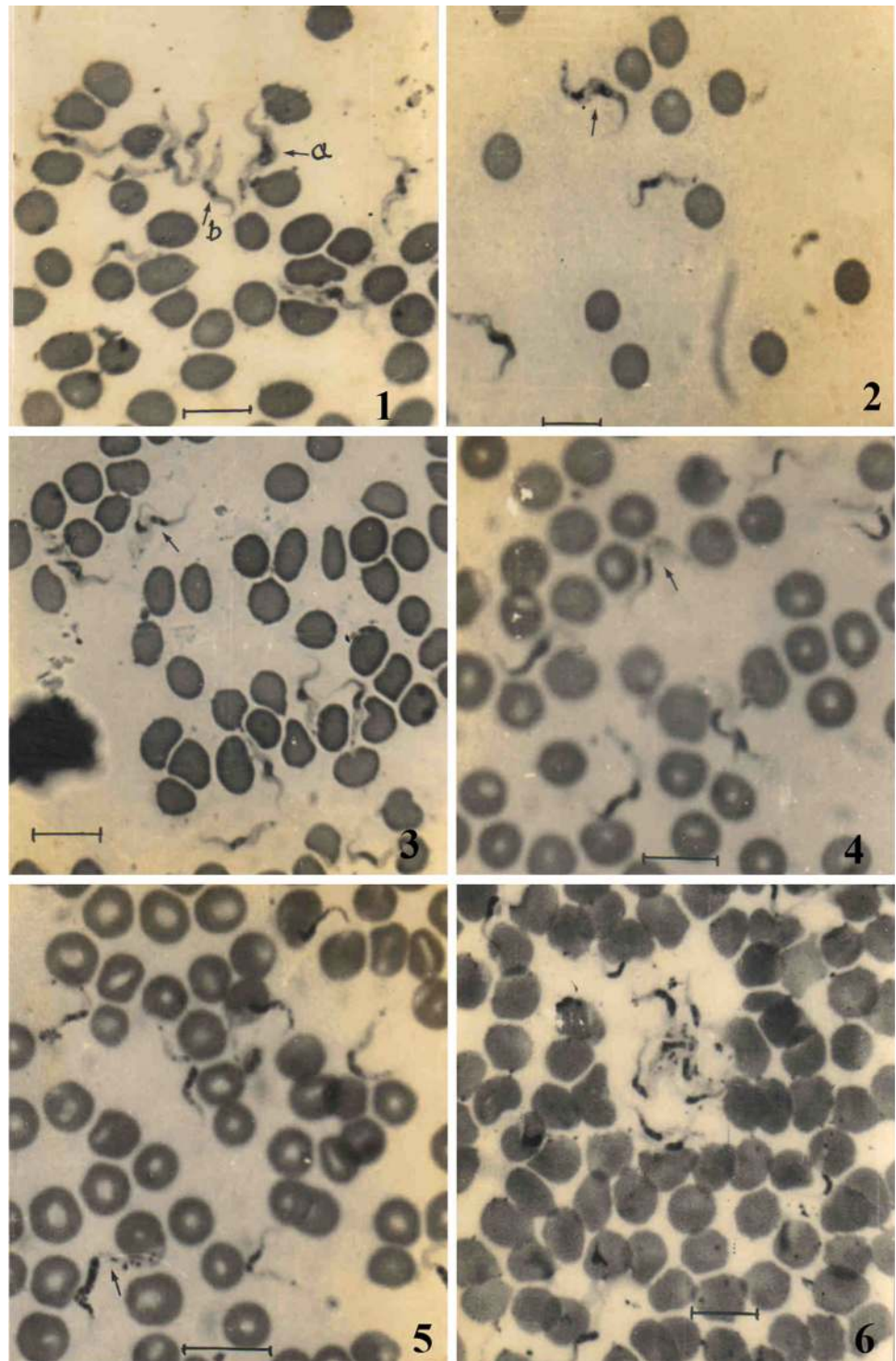
Bandicoot (Bandicota indica) All the bandicoots used in this experiment were trapped by the author from Sagar Island, in the Ganges estuary of West Bengal, as well as from the University campus. The bandicoots were given intraperitoneal inoculation of *T. evansi* placing them in a squeeze cage. The infection proved fatal for all the bandicoots except these sacrificed prior to death to detect the site of multiplication.

The trypanosomes were first observed in the peripheral blood on the fifth day in citrated saline blood preparation. Parasite population soon reaches its peak on the sixth or seventh day of infection. Trypanosomes disappeared from the peripheral blood in between eighth to ninth day and reappeared on eleventh to twelfth day. The animals succumbed to infection in between twelfth and fourteenth day and after second peak of infection. None survived beyond the fourteenth day.

Blood films of both the peaks showed monomorphic forms (Figs. 4–6, 7) of *T. evansi*. So far no short stumpy form was detected in the blood films of all the bandicoots, blood films drawn during the peak of infection show 40–45 trypanosomes in a 10 × 100 (oil immersion) microscopic field. It is revealed that among all the rodent species used in this experiment population density of *T. evansi* is the highest in these bandicoots.

Reproductive cycle To study the site of multiplication of *T. evansi* in bandicoot, animals were sacrificed on the first, third, fifth, tenth, eleventh and thirteenth day after inoculation. Animals sacrificed prior to the first peak show high

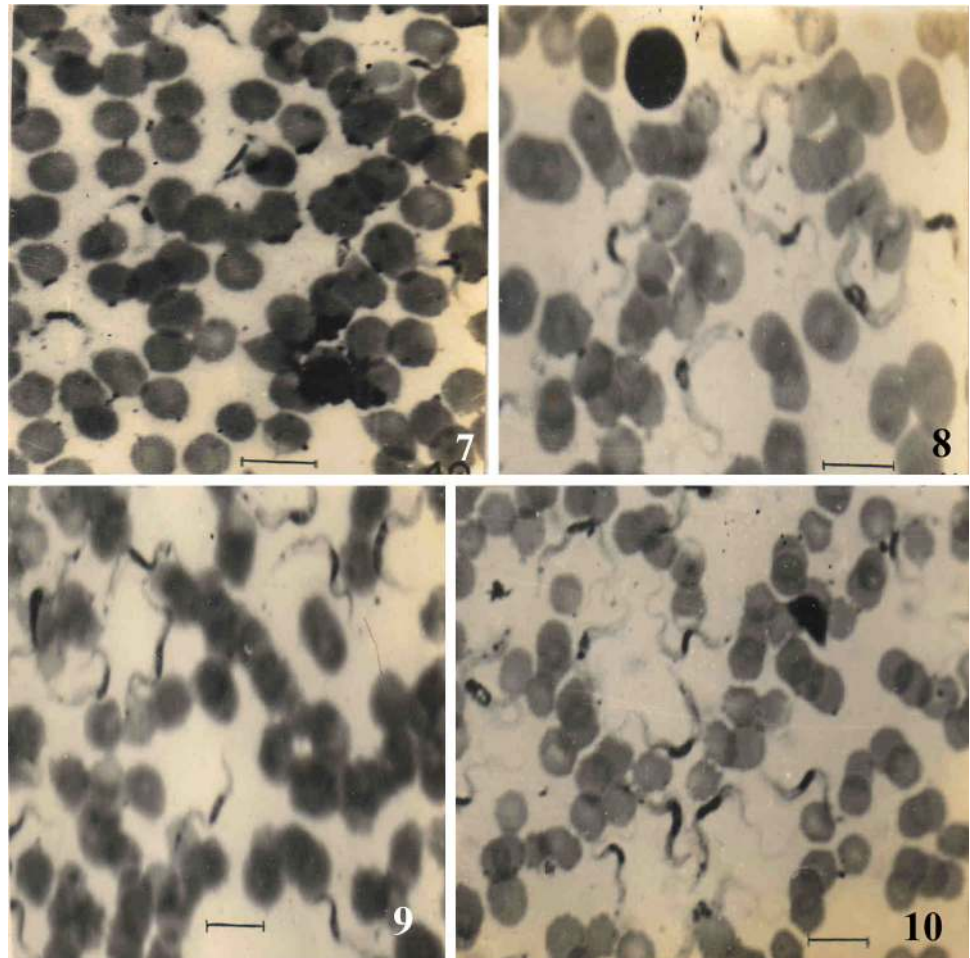
Figs. 1–6 Photographs of *Trypanosoma evansi*. **1** *T. evansi*, slender form, in the blood of albino rat; *a* indicates the division of kinetoplast of *T. evansi* and *b* indicates nucleus divided but kinetoplast remain undivided. **2** The slender form of *T. evansi* indicates two kinetoplast and two nuclei of dividing stage. **3** Divisional stages of *T. evansi*. Arrow shows trypanosome already divided at the anterior end. **4** Slender form (arrow) along with the divisional forms of *T. evansi* in bandicoot. **5, 6** Unnatural division of *T. evansi* in the peripheral blood of bandicoot. Arrow indicates the nuclear fragmentation as well as division of kinetoplast into five pieces. Scale represents 10 μm



parasitaemia and prolific multiplication in the bone marrow as was observed in the case of other rodents. Fall of the first peak was noted from the seventh day evening and parasites disappears completely on the eighth day evening; it was found that the trypanosomes appeared for the second time on the eleventh day and reached its peak between twelfth and fourteenth day. Animals sacrificed on tenth and

eleventh day showed random multiplication of *T. evansi* in bone marrow, spleen, kidney, liver and even in lung. Maximum multiplication was recorded in bone marrow. No trypanosome was detected in brain. Animals sacrificed on thirteenth day showed minimum parasites as well as minimum divisional stages in their internal organs. They were frequent in the peripheral blood and sinusoidal blood of

Figs. 7–10 7 The unnatural division of *T. evansi* in the blood of bandicoot. Scale represents 10 μm 8–10 Photographs of *T. evansi* artificially infected to mongoose. Normal and dividing trypanosomes are seen in the figures. Shape of the nucleus is notable. Scale represents 10 μm



liver. In most of the cases it was found that trypanosomes undergo binary fission in the peripheral blood. Sometimes irregular nuclear division was also observed.

Symptoms: The animals become sluggish. No other symptom was observed.

Experiment-II

On carnivores

Indian mongoose (*Herpestes palustris* and *H. auropunctatus*) To study the effect of *T. evansi* in carnivore hosts, the wild mongoose (*Herpestes palustris* and *H. auropunctatus*) were employed in the experiment. The choice of the material was solely based on the easy availability of these wild carnivores.

All the animals received *T. evansi* intraperitoneally and peripheral circulation showed presence of trypanosomes from the sixth day after inoculum and onwards. Infection reached its first peak on 12 and 13 days. The parasite disappears from the circulation on the fifteenth day and

reappears on twentieth day and the 2nd peak on 23rd to 24th day. Thus the infection always reaches a peak after 12–13 days of infection. Animals succumb to infection after 4–5 of such peaks.

Examination of blood films reveals that in all the peaks the trypanosomes remain monomorphic (Figs. 8–10). No short stumpy or intermediate forms were observed in the films prepared from infected mongoose blood.

Reproductive cycle Some of the *Herpestes* spp. were sacrificed for the detection of the site of multiplication of *T. evansi*. They were sacrificed on and in-between the peaks. Post mortem examination revealed that bone marrow, spleen, liver, kidney and lung were the main sites of multiplication. They were abundant in blood films with ample divisional stages. Actually in case of high parasitaemia they were found to multiply in almost all the internal organs as well as in the blood vessels, but they were not found in the brain or cerebrospinal fluid.

External symptom The mongoose infected with *T. evansi* showed some external symptoms. The notable features are: loss of appetite, drowsiness and becomes less ferocious i.e.

more docile. Anaemia with gradual loss of body weight was also the marked features. Ultimately they become so weak that they could not even move and ultimately died.

Domestic cat (Felis sp.) As a close member of the tiger groups and being easy to handle, cats were employed as the second experimental carnivore hosts. Large cats when caged become ferocious. To avoid such situation, young and juvenile cats were collected so that they become acclimated in course of time.

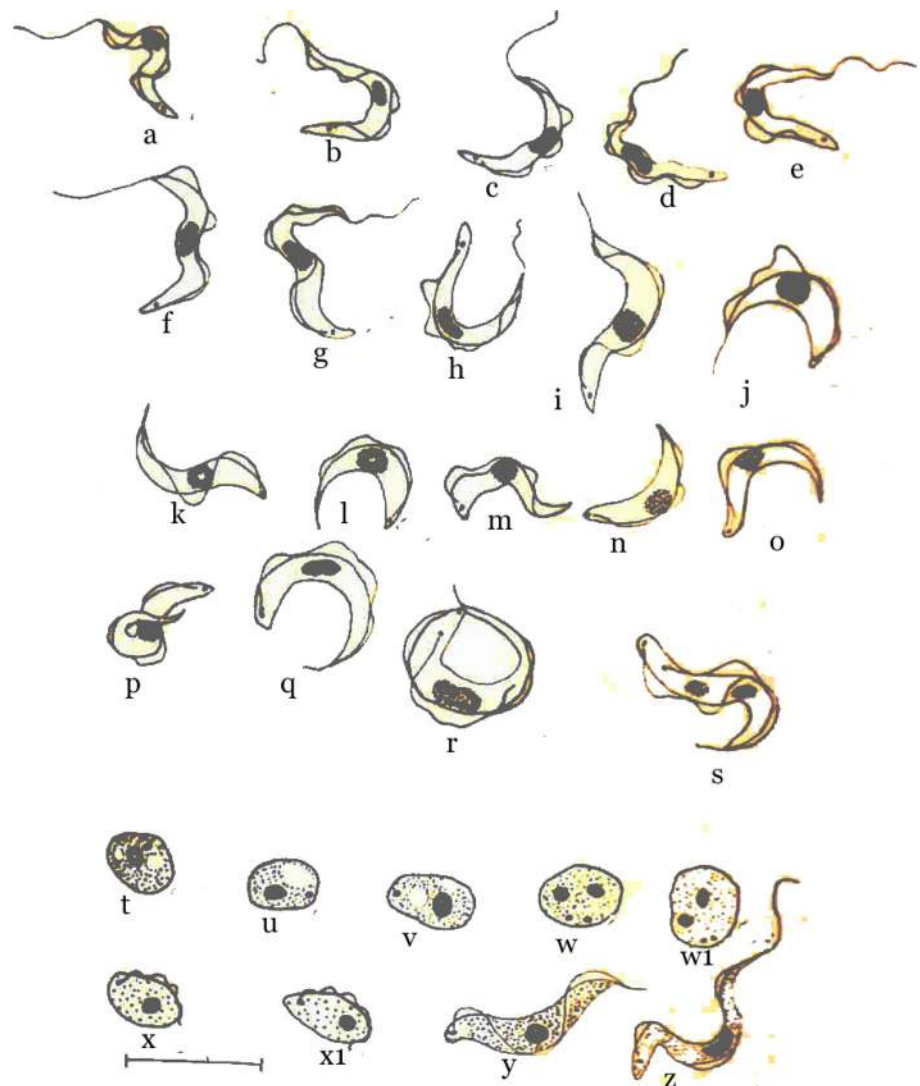
Four cats were inoculated with *T. evansi* and 5 days later trypanosomes found to appear in the circulation reaching a peak on the seventh day. The cat stopped feeding. One of the eyes (left) was showing oedematous condition and drops of tears were trickling down. The cat stopped feeding. Trypanosomes started disappearing from the eighth day evening. Likewise such peaks appeared after every 7 days. During the alternative eye (right) became swollen with drops of tear and the stained blood film

showed ‘pleomorphic’ trypanosomes (Figs. 11a–p). Animals succumbed to infection after 2–3 months after inoculation. Some times earlier deaths occur after first or second peak of infection.

Examination of the blood films of all the peaks revealed that from the second peak onwards *T. evansi* in cat becomes pleomorphic showing three distinct forms. However, the intermediate forms were abundant in comparison (Fig. 12) to shorter intermediate form and stumpy forms. Blood films prepared from the first peak have been found to contain only slender forms. Trypanosomes in the peripheral circulation have been found to divide during peak hours. Slender forms undergo binary fission in the peripheral blood. It is to be mentioned that after the third/fourth peak in cat *T. evansi* falls back to monomorphic. It has also been observed that the acuteness of the disease in cat depends on the pleomorphism of the parasite.

Reproductive cycle To detect the site of infection of *T. evansi* in cat, animals were sacrificed on and in between the

Fig. 11 a–z The photographs showing camera lucida drawings of different forms of *T. evansi* from infected cat: a–s Photographs of blood smears. a–h Slender forms of *T. evansi*. These forms representing the monomorphic forms of *T. evansi*. i, j Intermediate forms of *T. evansi*. k, l Short intermediate forms of *T. evansi* having a small free flagellum. m–p Stumpy forms of *T. evansi*. q–s Divisional stages of intermediate form of *T. evansi*. t–y Photographs of optic lobe impression smear. t–v Amastigote forms of *T. evansi*. Note the vacuole (s) present in the cytoplasm. w, w₁ Divisional stage of amastigote form of *T. evansi*. x, x₁ Sphaeromastigote stage of *T. evansi*. y Short intermediate form of *T. evansi*. z Slender form of *T. evansi* from cerebellum of infected cat. Scale represents 10 μm



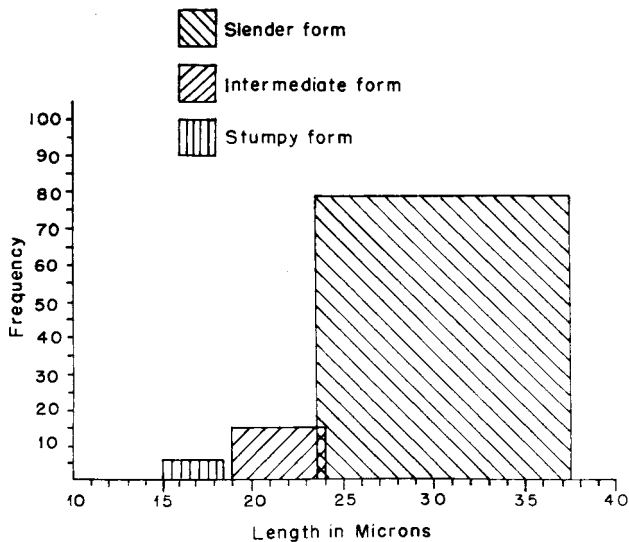
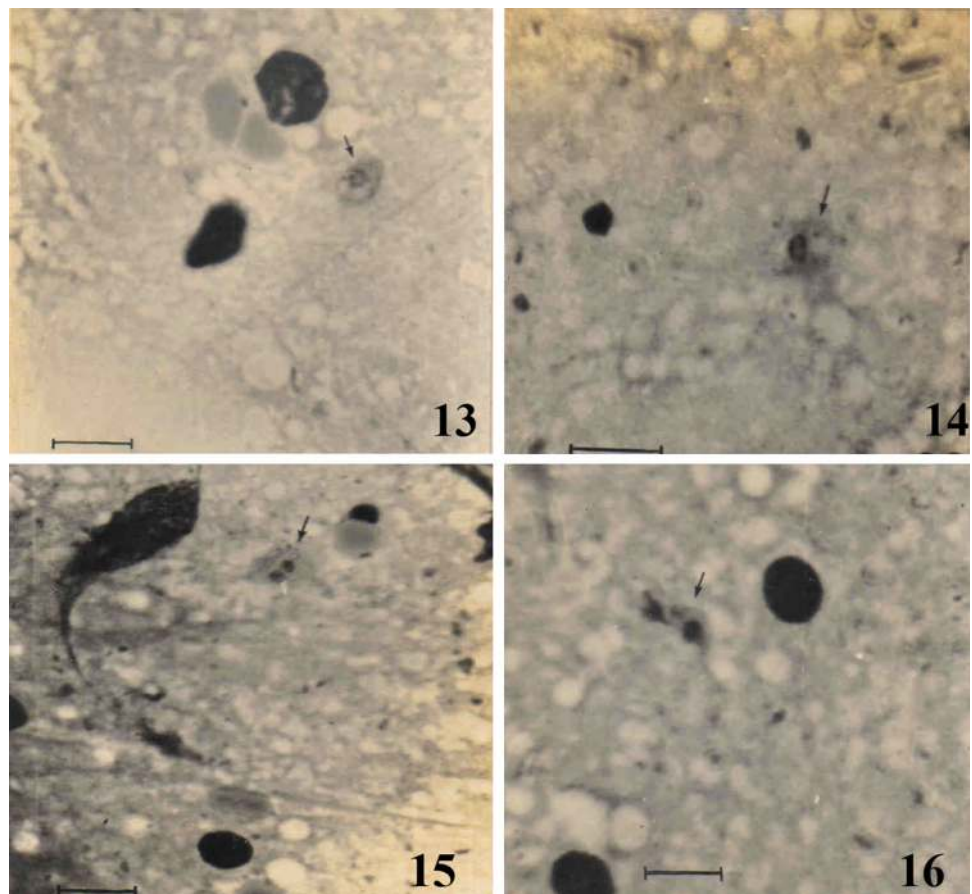


Fig. 12 The frequency of pleomorphic forms of *T. evansi* obtained from cat. The frequency of stumpy form shown in figure represents both the ‘short intermediate’ and stumpy forms combined

peak periods. Organ impression smears of bone marrow, spleen, lung, kidney and liver showed the presence of parasite in profuse numbers. They have been found to

divide in these organs. Cerebrospinal fluid taken from brain showed presence of trypanosomes. Selective organ impressions of optic lobe and cerebrum revealed motile flagellates. Trypanosomes found in the organs were mostly slender forms (Fig. 11z) with lone exception of stumpy forms. Beside the trypomastigote form in brain of infected cat, some amastigote and sphaeromastigote stages also were found in optic lobe smear. Amastigote form is more or less round with a round nucleus and a kinetoplast (Fig. 11t–v). Sometimes one to two vacuoles may be observed in this form. Cytoplasm stain faint (Figs. 13–14). In optic lobe smear amastigote form showing their divisional stage which composed of two nuclei and two kinetoplasts (Figs. 11w, w₁, 15). Besides amastigote stages, 2–3 sphaeromastigote stages (Figs. 11x, x₁, 16) were almost found in the same preparation of optic lobe but the forms were not very distinct enough. Sphaeromastigotes are oval in shape with a nucleus and kinetoplast. The later lies behind the nucleus and a flagellum arising from the kinetoplast wraps around the cell body with a small free flagellum. No vacuole was seen on the faintly stained cytoplasm. During peak period a fall in the trypanosome population was noted as observed in organ impression smears. Interestingly enough, in case of high parasitaemia,

Figs. 13–16 13, 14 Amastigote stages (arrow) of *T. evansi* in the smear of optic lobe of infected cat. The vacuoles in the cytoplasm are notable. 15 Amastigote stage undergoing division (arrow), showing two nuclei and two kinetoplasts from optic lobe smear of infected cat. 16 Sphaeromastigote stage of *T. evansi* (arrow) from optic lobe smear of infected cat. Scale represents 10 μm



even the ‘shorter intermediate forms’ have been found undergoing division (Fig. 11q–s) in the peripheral circulation and this form also found in the smear of optic lobe of infected cat (Fig. 11y).

External symptom In the first peak of infection, cats looked normal (Fig. 17) though less active. This may be due to high fever. From the second peak onwards, along with fever, oedematous swelling in the eye lid and its surroundings is observed. It has been noted that during every peak alternate eyes have been found to be affected. Later, the corneal opacity (Figs. 18–20) and the oedema in eyelids (Fig. 19) become a common feature. At the fall of each peak affected cornea becomes clear. After 7–8 peaks both the eyes become infected and the corneal opacity leads to permanent blindness (Fig. 20). When both the eyes become infected normal optical test proved negative for vision and corneal opacity persists for a long time. Cats become drowsy and less active at the peak periods with less of appetite. Voice becomes considerably low. They do not

respond to the presence of visitors. Sometimes oedematous swelling has been found under the abdomen. There are gradual paroxysm and emaciation till death. An infected cat can easily be identified by its ruffled hair and facial inflammation. At the time of high fever they can not even stand. All these symptoms may be compared with the normal cat.

Pathogenicity Simultaneously with the other symptoms cats developed high fever during infection. The temperature starts rising when the trypanosomes are first encountered in the blood. Temperature rises to its peak which coincides with the peak of parasitemia in circulation. Fall of body temperature was recorded when intensity of parasitaemia declined. Thus the temperature in infected cats always shows a peak which is directly proportional to the parasitaemia in peripheral circulation. After two to three such peaks the gap period between the successive peaks may be shortened. Table 1 represents detail of measurements of *T. evansi* in all the heterologous hosts. The

Figs. 17–20 Photograph showing the differences of physical expressions of same cat between before and after infection of *T. evansi*. **17** Cat showing normal appearance and normal eyes. **18** Oedema in the eye lids. The left eye of the cat is almost closed. Opaque corneal can be seen. Note that tears trickling down the infected eye. **19** *T. evansi* infected cat at the height of second peak. Note the affected right eye of the cat, which is almost closed due to oedematous swelling in eyelids. Facial inflammations are notable features. **20** Same cat after six peaks. Both the eyes became infected and corneal opacity led to complete blindness


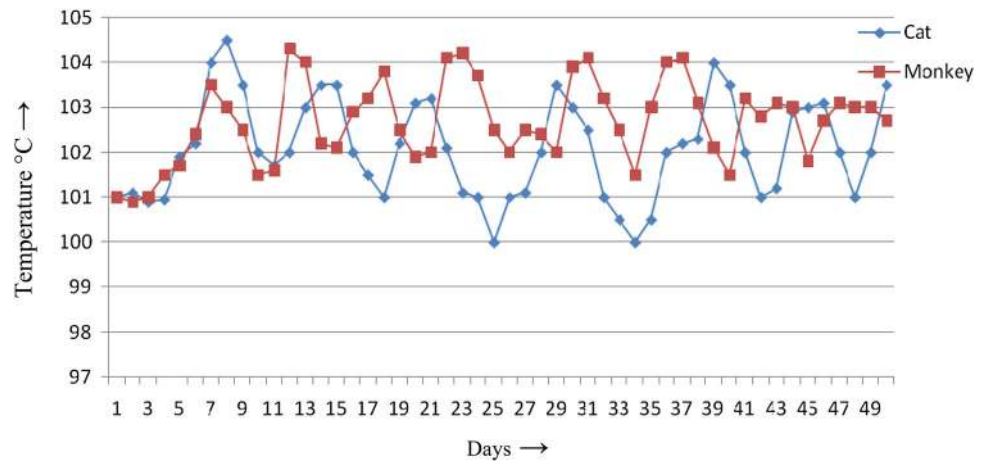


Table 1 The measurement (microns) of *T. evansi* from heterologous hosts (monomorphic forms only)

Hosts	TL	PK	KN	N	NA	FF	CB	B
White rat	20.78 ± 2.848	1.36 ± 0.724	6.55 ± 1.146	3.07 ± 0.809	5.72 ± 1.673	4.1 ± 1.074	16.7 ± 2.538	2.1 ± 0.408
Mongoose	24.82 ± 4.41	1.4 ± 0.609	6.87 ± 1.778	3.15 ± 0.98	6.34 ± 2.833	7.07 ± 2.114	17.74 ± 3.11	2.1 ± 0.287
Bandicoot	20.55 ± 3.61	1.2 ± 0.7	7.05 ± 1.21	2.92 ± 0.999	4.71 ± 1.526	4.58 ± 2.44	16.0 ± 2.48	2.27 ± 0.67
Guineapig	26.48 ± 4.14	1.67 ± 0.87	7.25 ± 1.72	3.7 ± 1.027	4.71 ± 2.03	9.13 ± 2.77	17.63 ± 3.76	1.92 ± 0.43
Cat	28.80 ± 3.062	1.4 ± 0.6	7.3 ± 2.34	2.5 ± 0.75	8.1 ± 2.55	9.4 ± 1.87	19.55 ± 2.96	3.35 ± 0.65
Monkey	28.88 ± 0.33	1.65 ± 0.14	7.45 ± 0.22	2.75 ± 0.15	6.75 ± 0.31	9.35 ± 0.47	19.25 ± 0.42	2.35 ± 0.25

Fig. 21 The graph showing the temperature variation in cat and monkey



temperature record in three experimental cats shows general conformity at the initial stage of infection but deviates significantly at the later part of parasitaemia (Fig. 21).

Anaemia, as evident from the total blood count, is the other major factor which developed in cat after *T. evansi* infection. Mucous membranes, eye membranes, and gum showed pale reddish colour confirming the anaemic condition of the animal. Total erythrocytes and leucocytes count in normal cat is 7.2 million/cm respectively. The total erythrocytes were 6.4 million/cm and 12.6 thousand/cm respectively. The total erythrocytic count was found to decline gradually during the successive peaks. Post mortem of the infected cats showed that there was slight enlargement of the liver and spleen. Spleen becomes pale in colour. Amount of bone marrow in femur was less than that of a normal cat. However, no haemorrhage was seen in the internal organs.

Haemoglobin content of the infected cats shows depletion. The haemoglobin percentage in normal cats is in between 12.2 and 13.2. It drops down to 11, 10, 9.2 and 9 (%) successively on the fifth, sixth, seventh and eighth day of inoculation. Again the haemoglobin percentage starts increasing until reaching 10 % on the twelfth day and on the sixteenth day haemoglobin content showed lowest record i.e. 8.0 %. As the infection becomes chronic a constant deficiency in haemoglobin content is observed.

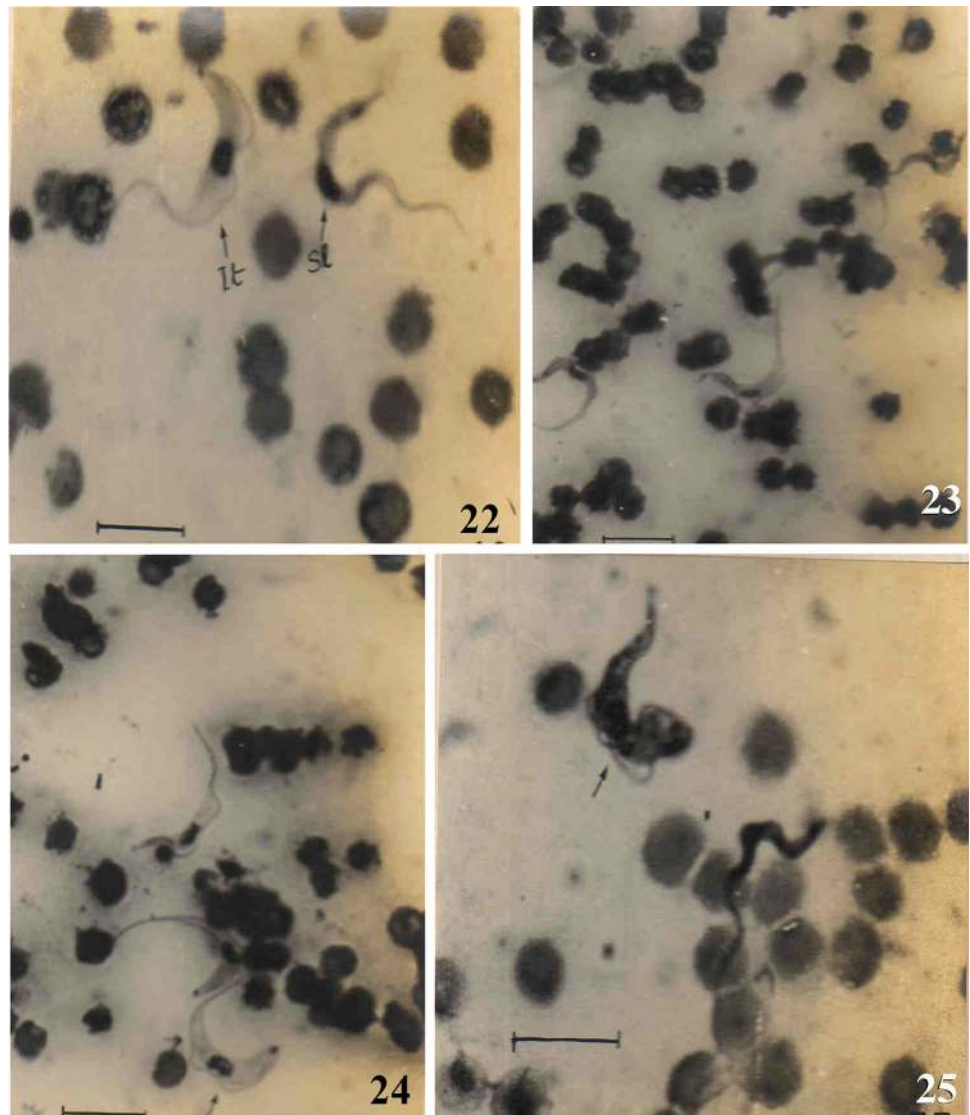
Experiment-III

On primate

Common monkey (Macaca mullata) All the monkeys received *T. evansi* intraperitoneally. The parasites were first observed in the circulation of the monkey on the 4th day after the inoculation of trypanosomes. It soon reached its peak on the 7th day after the infection. Peak of the parasitaemia developed at every seventh day. Animals survived up to 5–7 of such peaks. Examination of the blood films of all the peaks revealed that from the second peak onwards *T. evansi* in monkeys become pleomorphic showing three distinct forms (Figs. 22–25). Blood films prepared from the onset of infection have been found to contain only slender forms. Percentages of the pleomorphic forms were very low. However it was very difficult to find out the pleomorphic forms after 3 to 4 peaks. Trypanosomes in the peripheral circulation have been found to divide during peak hours.

Reproductive cycle Trypanosoma evansi in monkey follows the similar reproductive cycle as it follows in other mammals. Trypomastigotes (Fig. 26) dominate in the peripheral circulation, as well as in the visceral organs. Amastigote and sphaeromastigote stages were found in the smears of lung and heart after 144 h of infection.

Figs. 22–25 Photographs showing blood smear of *T. evansi* infected monkey. **22** Slender and intermediate forms; Sl- slender form, It- intermediate form. **23, 24** Slender and intermediate forms (arrow) of *T. evansi*. **25** Slender and stumpy form (arrow). Scale represents 10 μ m



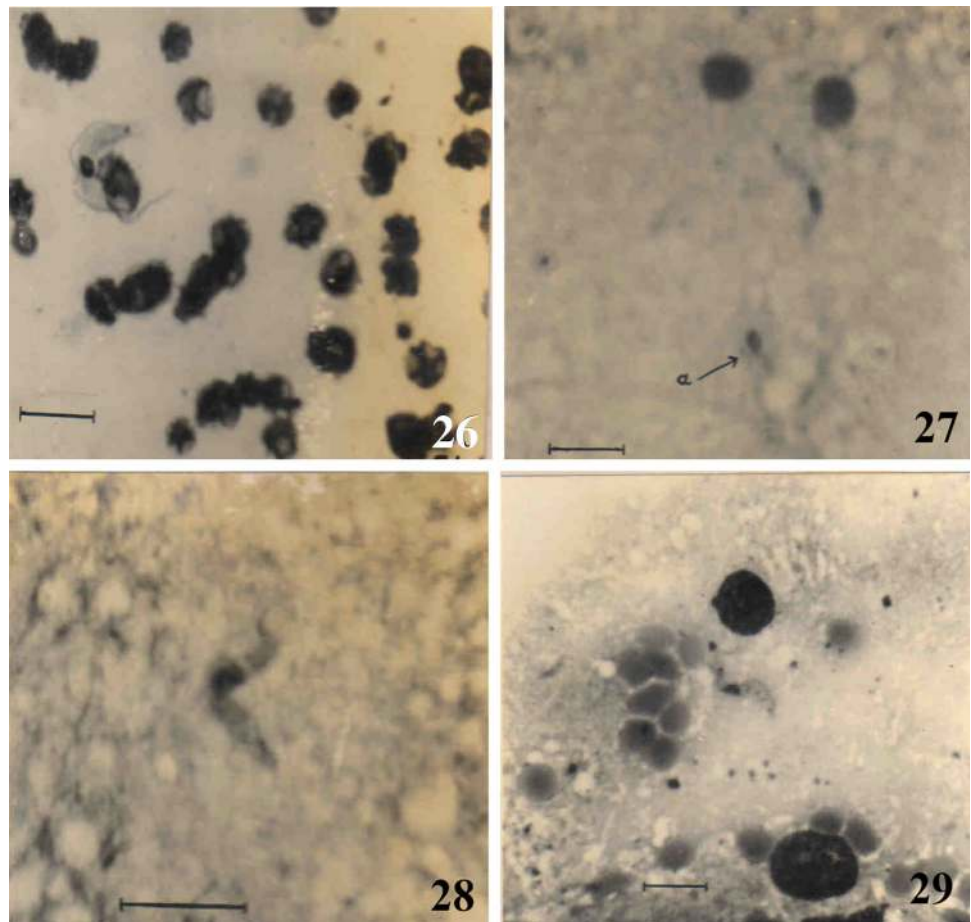
Amastigote form is more or less a round with a round nucleus and a kinetoplast. Sometimes one to two vacuoles may be observed. Cytoplasm stains faint in Giemsa. Besides amastigote stage, sphaeromastigote stages are also found in the same preparation. Sphaeromastigote are oval in shape with a nucleus and kinetoplast. The latter lies behind the nucleus and a flagellum arising from the kinetoplast wraps around the cell body with a small free flagellum. No vacuole is seen on the faintly stained cytoplasm. Amastigote and sphaeromastigote stages are also observed in choroid plexus and in the smears of optic lobes (Figs. 27–28) and cerebrum (Fig. 29) of infected monkeys after 5 peaks. Choroid plexus show maximum number of these forms along with trypomastigotes. After 5 peaks trypomastigotes were observed in CSF. Equal binary fission as well as multiple fissions is observed in the trypomastigote forms. Amastigotes and sphaeromastigote are found to divide by binary fission. No multiple fission is

observed in amastigote and sphaeromastigote stages. Morphology and division of these two stages in monkeys are essentially similar to those previously found from the infected cats.

Pathogenicity External symptoms due to *T. evansi* infection of the rhesus monkey, are found quite similar to that found in Gambian Sleeping sickness patients in Africa. Rise in body temperature in accordance with the parasitaemia is one of the main features of the disease. Interesting enough after 3–4 peaks, the parasitaemia gradually found to decline and the successive peaks become lower. Irregularity in rise of temperature is also recorded at the late phase of the infection.

Mucous membranes, eye membranes and gum showed pale reddish colour confirming the anaemic condition of the animals. Oedematous swellings are also observed in eye and eye lids, face, all the joints, hands and feet. Animals become thin and weak. At the late phase of the

Figs. 26–29 26 Intermediate forms in the blood smear of infected monkey. Blunt posterior end with kinetoplast is visible 27–29 Photomicrographs of *T. evansi* from the brain smear of infected monkey. 27 Slender form of *T. evansi* from optic lobe; a- degenerating amastigote form. 28. Intermediate form of *T. evansi* in optic lobe. 29. Dividing intermediate form from cerebellum. Scale represents 10 μ m



infection, the nervous symptoms become pronounced. The animals become lethargic. They paid less attention to the visitors or food. Monkeys became seriously ill and found sleeping always. They found to lie on the cage with sleepy eyes. Ultimately the monkeys lose all strength and stop feeding and eventually die. Monkeys usually survive 6–7 weeks.

Animals scarified before death show oedematous nature of the visceral organs. Accumulation of water is found in the peritoneal cavity and between the durometer and arachnoid mater of the brain.

Discussion

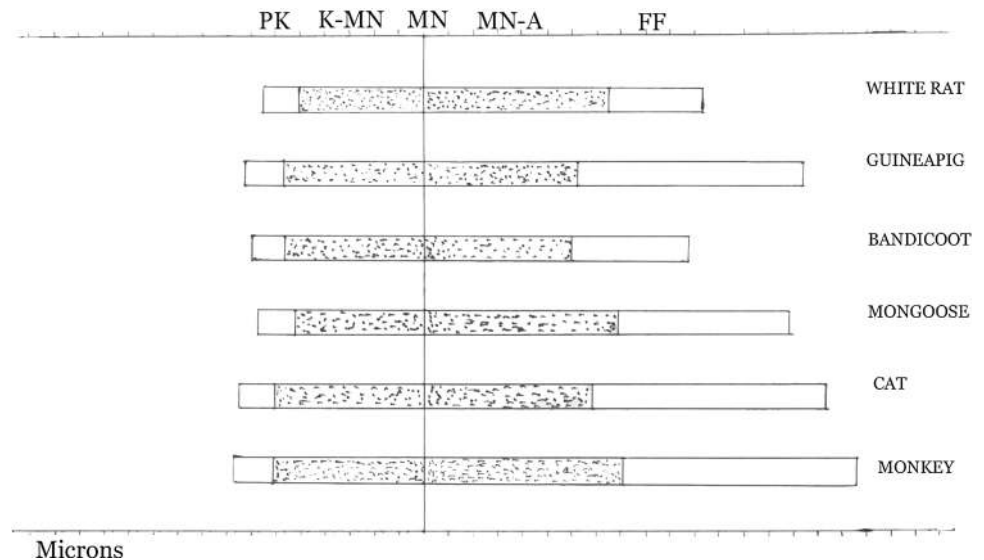
Trypanosoma (Trypanozoon) evansi comprises geographical strains differing in the degree of host restriction in different parts of the world and is therefore, represented by equine, bovine and cameline hostal strains or xenodemes (Hoare 1976). *T. evansi* can infect a very large range of hosts including camelids, equines, cattle, buffaloes, sheep, goats, pigs, dogs and other carnivores, deer, gazelles, horses and elephants. The disease is also recorded in new

large range of wild and domestic hosts in Latin America, including reservoirs (capybaras) (Desquesnes et al. 2013a). In the present investigation a laboratory strain of *T. evansi*, isolated from Indian buffalo, was maintained in guineapig, white rats and cats. A wide range of interesting observations have been made on the heterospecific interaction between the laboratory strain of *T. evansi* and various heterologous hosts, herbivores and carnivores, by cross transmission experiments (passage infection).

In the cross transmission experiments, the unusual and unnatural hosts may sometimes induce to support the growth of the haemoflagellate. Profound changes in the biology of trypanosomes were noted after they had been maintained for some time in an unusual host. These include (a) morphological changes and (b) changes in virulence.

The biometric study of the abundant collection of blood films at author's disposal conformed to the monomorphic pattern of *T. evansi* in almost all the heterologous hosts except cat and monkey. The discrepancy in the mensural data obtained from the readings in different hosts are assumed to be under the impact of different environments (blood and other tissue microhabitats) offered by the respective hosts (Fig. 30). In herbivorous hosts, rodents in

Fig. 30 The graph elucidating the mensural detail of the monomorphic form of *T. evansi* populations maintained in heterologous hosts. PK - Distance between posterior end and kinetoplast, K-MN - Distance between kinetoplast and middle of the nucleus, MN - Middle of the nucleus, MN-A - Distance between middle of the nucleus and anterior end, FF - Free flagellum



particular, fluctuation in population density on different areas of the host body, during and in between the peak periods, and during the later part of infection before host's death, were very much pronounced in different hosts. Measurements of the monomorphic form of *T. evansi* displayed a wide range of variation within the same host genus and in different host genera as well, are evident from the table and figures. Cause of observed variations in morphology and measurements of *T. evansi* may be due to heterogeneity of hosts produced by some physiological factors. This part of the observations carried by the author correlates with the biometrical study of 22 populations from cases of Surra in 6 species of mammalian hosts (other than those chosen by the present author) by Hoare (1976). He wanted to ascertain whether the populations measured showed any variation in dimensions and, if so, to determine the statistical and taxonomic significance of this variation. The author is in corroboration with Hoare (1972) in that the variations in the mean length of diverse strains of *T. evansi* infected to heterologous hosts afford no criterion for regarding them as independent taxa, but it indicates that in spite of the wide mensural discrepancies, they present one group belonging to a single species, *T. evansi*. Tejero et al. (2008) studied the morphometric characteristics of three Venezuelan isolates of *T. evansi* in murine hosts and they found morphometric differences of isolates and suggested that it is due to the association between trypomastigote morphometry, and host haematology as well as body weight.

Pleomorphism in *Trypanosoma evansi* in cat passage and pathogenicity in cat and monkey

The most outstanding part of the present investigation is the development of pleomorphism in *T. evansi* in carnivore

and primate host, after syringe passage. Perhaps this observation is one of the rarest records on pleomorphism developing naturally in any carnivore animal like cat (Choudhury and Misra 1972a, b) which is an unnatural host for *T. evansi*.

It was generally believed in the past that *T. evansi* was monomorphic, since the stumpy forms characteristic of the pleomorphic species of *Trypanozoon* are usually absent, though there are published records of their occurrence in some strains of this species (after Hoare 1972). It is now confirmed (Hoare 1972) that in *T. evansi* a variable, but mostly insignificant proportion of stumpy forms does occur from time to time (Choudhury and Misra 1972a, b). Since in many cases the strains examined had been maintained in laboratory animals (mainly by passage), it was thought that like *T. brucei* under similar conditions they might have lost some of the pleomorphism present in their natural hosts. To justify the validity of this question Hoare (1976) reinvestigated and studied blood films from 19 naturally infected animals (Surra positive camels, horses, mules, cattle, buffalo and dogs). The examination revealed no stumpy forms in 11 animals including the canine host and 0.05–0.4 percent in 8, the average percentage for 31,000 trypanosomes examined being 0.05. Hoare (1972) concludes that “since these results were based on the examination of single random samples, there was no evidence that the extreme rareness of stumpy forms was a constant characteristic of *Trypanosoma evansi*”. Ravindran et al. (2008) are of the opinion that the examination of blood smears has a limited value in diagnosis of sub-acute or chronic cases in *T. evansi* infection. The authors therefore employed PCR techniques for documenting the infection in camels, donkeys and dogs. This is important for epidemiological studies.

In the present investigation, all the experimental hosts inoculated with *T. evansi* by syringe passage were

susceptible to the trypanosome with different amounts of virulence and in all cases transmitted *T. evansi* showed monomorphic forms only. It is in the experimentally infected cat and monkey only, the syringe passage of *T. evansi* exhibit pronounced pleomorphism with considerable amount of virulence and expressed pathogenicity (Choudhury and Misra 1972b).

In structure and mensural data the pleomorphic forms of *T. evansi* in experimental cats corroborate to that of Hoare (1976) obtained from the naturally infected various domestic herbivores. The expressed pathogenic symptoms and acute parasitaemia showed a rhythmical coincidence with the successive peaks. During the interval of two successive peaks the expressed symptoms of infected cats and monkeys also disappear. In all the experimental cats, periodic corneal opacity led to blindness that became permanent only in two cases. In two cats, the hosts get immuned of *T. evansi* after few months, ceased to exhibit expressed pathogenic symptom and trypanosomes losing pleomorphism changed back to monomorphic form. That pleomorphism in *T. evansi* is not constant is also evident from the fact that when pleomorphic strain is syringe passage to rodent hosts, *T. evansi* reversed to monomorphic form. Low level of pleomorphism was also recorded from monkey where it disappears after 3–4 peaks. Pleomorphism in *Trypanozoon* trypanosomes is the expression of their metabolic adaptation against host immune reaction where the mitochondrial enzymes become active (use of TCA cycle) to minimize uptake of glucose. In the present investigation, initially some degree of pleomorphism is observed in cat and monkey. This may be due to the host reaction. Disappearance of pleomorphic forms in chronic infection is supposed to be the result of host's inability to combat against parasitic load, thus the parasite returned to slender form where mitochondrial enzymes are not required.

In the later part of the present investigation, impression smear of optic lobe and cerebellum of experimentally infected cats revealed the presence of amastigote and sphaeromastigote stages of *T. evansi* (Choudhury and Misra 1973; Misra and Choudhury 1974, 1975). Obviously this invention is a novel addition to the pattern of development of the parasite and is destined to cast a long impact on the probable origin and phylogeny of *T. evansi*. It was reported that the amastigote form from choroid plexus of white rat was observed in a strain of *T. brucei* isolated from man in Botswana by Ormerod and Venkatesan (1970, 1971a, b). However, Soltys et al. (1969); Soltys and Woo (1969, 1970) also observed amastigote stages in *T. brucei*. These observations led the scientists “to believe that the life cycle of these trypanosomes including a tissue phase comparable to that in *Stercoraria*” (Hoare 1972). Histopathology of choroid plexus of *T. evansi* infected bandicoot

rat also confirmed the presence of amastigote stage (Biswas et al. 2010). Occurrence of amastigote and sphaeromastigote stages of *T. evansi* in the organ impression smear preparation as well as in tissue section in cat and monkey indicates the evolutionary relationships among the members of the subgenus *Trypanozoon*.

Biologically *T. evansi* is very similar to *T. equiperdum*, the causative agent of dourine (Brun et al. 1998; Claes et al. 2003). They are morphologically resembles the slender forms of the tsetse-transmitted species, *T. brucei brucei*, *T. b. gambiense* and *T. b. rhodesiense*. *T. evansi* is however difficult to distinguish morphologically from the other members of the subgenus *Trypanozoon*. The diagnosis in this disease was uniquely based on the microscopic detection of trypomastigote and by the response to therapy (Tarello 2005). Depending on the molecular characterizations it is indicated that various strains of *T. evansi* isolated from Asia, Africa and South America are very homogeneous and may have a single origin (Ventura et al. 2002), but other works suggest that *T. evansi* could have emerged from *T. brucei* in several instances (Jensen et al. 2008; Lai et al. 2008). The difficulties in differentiating *T. equiperdum* from the other *Trypanozoon* spp. have been stressed (Zablotskij et al. 2003; Claes et al. 2005), and the existence of *T. equiperdum* was even questioned.

Lai et al. (2008) studied kDNA of both *T. equiperdum* and *T. evansi* and commented that both the species are actually strains of *T. brucei*, which lost part (Dk) or all (Ak) of their kDNA. The authors further opined that these two species are not monophyletic clades thus should be considered as two subspecies of *T. brucei*, i.e. *T. brucei equiperdum* and *T. brucei evansi* respectively. *T. evansi* and *T. equiperdum* are different from *T. b. brucei* since they suffer from a mutation leading to the homogenization of their kinetoplastic minicircles, which make them unable to properly edit their mitochondrial RNA, hence they are unable to transform into procyclic stage.

The outcome of the present investigation is interesting in that the haemoflagellate maintains a common reproductive cycle in all the experimental heterologous hosts, however, exhibit pleomorphic stages, including amastigote and sphaeromastigote, in carnivore and primate. This may be interpreted that host-parasite interaction is intense and acute as the parasite invades higher group of mammals. This might be the basis of the zoonotic potentiality of *T. evansi* (Misra 1981). In recent years, cases of human infection due to *T. evansi* are reported (Joshi et al. 2005; Powar et al. 2006; Nijjar and Del Bigio 2007). Zoonotic potentiality of this disease might be related with the socioeconomic and environmental factors, because of the close association of man and domestic cattle where mechanical vector of the disease is present (i.e. in endemic areas).

Contraction of foreign trypanosome species (*T. vivax*, and *T. lewisi*-like), besides salivarian trypanosomes, to human being is not new (Hoare 1976). It was shown that some trypanolytic factors in normal human serum (NHS) are responsible in preventing *T. evansi* infection to human (Vanhollebeke and Pays 2010). The authors explained that primate-specific apolipoprotein L-1 (apoL1) and haemoglobin-related protein (Hpr) in association with sub fractions of HDLs and IgM/apolipoprotein A-1 (apoA1) form trypanosome lytic factor (TLF1) and TLF2 which bind to trypanosome haptoglobin (Hp-Hb) receptor and undergo subsequent trypanosome lysis. This is considered for resistance to *T. evansi* by human. Prompt molecular analysis on this aspect of incidence of *T. evansi* infection to human (references mentioned earlier) showed that frame shift mutation in the patient is the cause for the unusual contraction of the haemoflagellate (Vanhollebeke et al. 2006). Interestingly, serological screening of 1,806 villagers, where first incidence was recorded, was tested with CATT/*T. evansi* and 22.7 % were found positive. However, trypanosome remains undetected from the positive samples (Shegokar et al. 2006). Desquesnes et al. (2013b) reviewed the zoonotic aspects of *T. evansi* and commented that despite no reports on the existence of mutated Apo L1 alleles in the population “people are still at risk particularly immunosuppressed individuals living in the regions where *T. evansi* is endemic”. The present work was conducted on rhesus monkey, a primate species, where severe pathogenic symptoms were observed very similar to those of human sleeping sickness. Thus, it is logical to arrive at an inference that *T. evansi* has the potentiality to become zoonotic.

Acknowledgments The authors are thankful to the Head of the Department of Zoology, University of Calcutta for necessary laboratory facilities. The author (KKM) pays his gratefulness to the Principal, R. B. C. College, Naihati for this work.

References

- Bal MS, Singla LD, Kumar H, Vasudev A, Gupta K, Juyal PD (2012) Pathological studies on experimental *Trypanosoma evansi* infection in Swiss albino mice. *J Parasit Dis* 36(2):260–264. doi: [10.1007/s12639-012-0120-5](https://doi.org/10.1007/s12639-012-0120-5)
- Biswas D, Choudhury A, Misra KK (2001) Histopathology of *Trypanosoma (Trypanozoon) evansi* infection in bandicoot rat. I Visceral organs. *Exp Parasitol* 99:148–159
- Biswas D, Choudhury A, Misra KK (2010) Histopathology of *Trypanosoma (Trypanozoon) evansi* infection in bandicoot rat. II Brain and choroid plexus. *Proc Zool Soc* 63:27–37. doi: [10.1007/s12595-010-0004-6](https://doi.org/10.1007/s12595-010-0004-6)
- Brun R, Hecker H, Lun ZR (1998) *Trypanosoma evansi* and *T. equiperdum*: distribution, biology, treatment and phylogenetic relationship (a review). *Vet Parasitol* 79:95–107
- Choudhury A, Misra KK (1972a) Experimental infection of *Trypanosoma evansi* in the carnivore host. *Trans R Soc Trop Med Hyg* 66:365
- Choudhury A, Misra KK (1972b) Experimental infection of *Trypanosoma evansi* in the cat. *Trans R Soc Trop Med Hyg* 67:672
- Choudhury A, Misra KK (1973) Occurrence of amastigote and sphaeromastigote stages of *T. evansi* in the brain tissue of cat. *Trans R Soc Trop Med Hyg* 67:609
- Claes F, Agbo EC, Radwanska M, Tepas MFW, Baltz T, Dewaal DT, Goddeeris BM, Classen E, Busher P (2003) How does *Trypanosoma equiperdum* fit into the *Trypanozoon* group? A cluster analysis by RAPD and multiplex-endonuclease genotyping approach. *Parasitology* 26:425–431
- Claes F, Buscher P, Touratier L, Goddeeris BM (2005) *Trypanosoma equiperdum*: master of disguise or historical mistake? *Trends Parasitol* 21(7):316–321
- Davis BS (1952) Studies on the trypanosomes of some Californian mammals. *Univ California Pub Zool* 57:145
- Desquesnes M, Holzmuller P, De-Hua Lai, Dargantes A, Zhao-Rong Lun, Jittaplaong S (2013a) *Trypanosoma evansi* and surra: a review and perspectives on origin, history, distribution, taxonomy, morphology, hosts, and pathogenic effects. *Biomed Res Int*. doi:[10.1155/2013/194176](https://doi.org/10.1155/2013/194176)
- Desquesnes M, Dargantes A, Holzmuller P, De-Hua Lai, Zhao-Rong Lun, Jittaplaong S (2013b) *Trypanosoma evansi* and surra: a review and perspectives on transmission epidemiology and control impact, and zoonotic aspects. *Biomed Res Int*. doi:[10.1155/2013/321237](https://doi.org/10.1155/2013/321237)
- Hoare CA (1956) Morphological and taxonomic studies on mammalian trypanosomes. Revision of *Trypanosoma evansi*. *Parasitology* 46:130–172
- Hoare CA (1972) The trypanosomes of mammals. Blackwell, London
- Hoare CA (1976) Accidental infection of man with foreign mammalian trypanosomes. *Proc Zool Soc Calcutta* 39:1–7
- Jensen RE, Simpson L, Englund PT (2008) What happens when *Trypanosoma brucei* leaves Africa. *Trends Parasitol* 24:428–431
- Joshi PP, Shegokar VR, Power RM, Herder S, Katti R, Salkar HR, Dani VS, Bhaegava A, Jannin J, Truc P (2005) Human trypanosomiasis caused by *Trypanosoma evansi* in India: the first case report. *Am J Trop Med Hyg* 73:491–495
- Lai DH, Hashimi H, Lun ZR, Ayala FJ, Lukes J (2008) Adaptations of *Trypanosoma brucei* to gradual loss of kinetoplast DNA: *Trypanosoma equiperdum* and *Trypanosoma evansi* are petite mutants of *T. brucei*. *Proc Natl Acad Sci USA* 105(6):1999–2004
- Losos GJ, Ikede BO (1972) Review of pathology of diseases in domestic and laboratory animals caused by *T. congolense*, *T. brucei*, *T. rhodesiense*, *T. gambiense*. *Vet Pathol* 9 (Suppl):1–71
- Manohar BM, Selvaraj J, Jayathangaraj MG, Khan PN (2003) Pathology of *Trypanosoma evansi* infection in a tiger. *Indian Vet J* 80:505–507
- Misra KK (1981) Zoonotic potentiality of *Trypanosoma evansi* in India. *Proc 6th Intern Cong Protozool Warsaw* 225
- Misra KK (1986) Incompatibility of mutated population of *Trypanosoma evansi* in sympatric condition. *Arch Protistenkd* 131:159–164
- Misra KK, Choudhury A (1974) Multiplication of visceral forms of *T. evansi* in cat. *Proceedings of the III International Congress of Parasitology München* 1 : 204
- Misra KK, Choudhury A (1975) Experimental infection of *Trypanosoma evansi* (Steel) in rhesus monkey. *Proc 62nd Ind Sci Congr Assoc* 99:167
- Misra KK, Ghosh M, Choudhury A (1976) Experimental transmission of *Trypanosoma evansi* to chicken. *Acta Protozool* 15:381–386
- Morales GA, Carreno F (1976) The prochemys rat, a potential laboratory host and model for the study of *Trypanosoma evansi*. *Trop Anim Health Prod* 8:122–124
- Nijjar SS, Del Bigio MR (2007) Cerebral trypanosomiasis in an incarcerated man. *Can Med Assoc J* 176:448

- Ormered WE, Venkatesan S (1970) The choroid plexus in African sleeping sickness. *Lancet* 2:777
- Ormered WE, Venkatesan S (1971a) The occult visceral phase of mammalian trypanosomes with special reference to the life cycle of *Trypanosoma (Trypanosoon) brucei*. *Trans R Soc Trop Med Hyg* 65:722
- Ormered WE, Venkatesan S (1971b) An amastigote phase of the sleeping sickness trypanosome. *Trans R Soc Trop Med Hyg* 65:736
- Powar RM, Shegokar VR, Joshi PP, Dani VS, Tankhiwale NS, Truc P, Jannin J, Bhargava A (2006) A rare case of human trypanosomiasis caused by *Trypanosoma evansi*. *Indian J Med Microbiol* 24:72–74
- Prasad KL, Kondaiah PM, Rayulu VC, Srilatha Ch (2013) Prevalence of canine trypanosomiasis in certain areas of Andhra Pradesh. *J Parasit Dis*. doi:10.1007/s12639-013-0326-1
- Ravindran R, Rao JR, Mishra AK, Pathak KML, Babu N, Sathesh CC, Rahul S (2008) *Trypanosoma evansi* in camels, donkeys and dogs in India: comparison of PCR and light microscopy for detection—short communication. *Vet Arhiv* 78(1):89–94
- Rodrigues A, Açhera RA, Souza TM, Schild AL, Barros CSL (2009) Neuropathology of naturally occurring *Trypanosoma evansi* infection of horses. *Vet Pathol* 46:251. doi:10.1354/vp.46-2-251
- Shegokar VR, Powar RM, Joshi PP, Bhargava A, Dani V, Katti R, Zare V, Khanande VD, Jannin J, Truc P (2006) Short report: human trypanosomiasis caused by *Trypanosoma evansi* in a village in India: preliminary serological survey of the local population. *Am J Trop Med Hyg* 75:869–870
- Soltys MA, Woo P (1969) Multiplication of *Trypanosoma brucei* and *Trypanosoma congolense* in vertebrate hosts. *Trans R Soc Trop Med Hyg* 63:490
- Soltys MA, Woo P (1970) Further studies on tissue forms of *Trypanosoma brucei* in a vertebrate host. *Trans R Soc Trop Med Hyg* 64:492
- Soltys MA, Woo P, Gillick AC (1969) A preliminary note on the separation and infectivity of tissue forms of *Trypanosoma brucei*. *Trans R Soc Trop Med Hyg* 63:495
- Tarello W (2005) *Trypanosoma evansi* infection in three cats. *Revue Méd Vét* 156(3):133–134
- Tejero F, Roschman G, Carmona A, Mercedes T, Aso P (2008) *Trypanosoma evansi*: a quantitative approach to the understanding of the morphometry-hematology relationship throughout experimental murine infections. *Protozool Res* 18:34–47
- Vanhollebeke B, Pays E (2010) The trypanolytic factor of human serum: many ways to enter the parasite, a single way to kill. *Mol Microbiol* 76:806–814
- Vanhollebeke B, Truc P, Poelvoorde P, Pays A, Joshi PP, Katti R, Jannin JG, Pays E (2006) Human *Trypanosoma evansi* infection linked to a lack of apolipoprotein L-1. *N Eng J Med* 355:2752–2756
- Varshney JP, Bandyopadhyay S, Raina R, Saghar SS (2003) Diagnosis and treatment of *Trypanosoma evansi* associated corneal opacity in dogs. *J Vet Parasitol* 17(1):53–55
- Ventura RM, Takeda GF, Silva RA, Nune VL, Buck GA, Teixeira MM (2002) Genetic relatedness among *Trypanosoma evansi* stocks by random amplification of polymorphic DNA and evaluation of a synapomorphic DNA fragment for species-specific diagnosis. *Int J Parasitol* 32:53–63
- Zablotskij VT, Georgiu C, Dewaal T, Clausen PH, Claes F, Tourateir L (2003) The current challenges of dourine: difficulties in differentiating *Trypanosoma equiperdum* within the subgenus *Trypanozoon*. *Rev Sci Tech* 22(3):1087–1096