

# Black fungi: clinical and pathogenic approaches

G. S. DE HOOG\*, F. QUEIROZ-TELLES<sup>2</sup>, G. HAASE<sup>3</sup>, G. FERNANDEZ-ZEPPENFELDT§, D. ATTILI ANGELIS\$, A. H. G. GERRITS VAN DEN ENDE\*, T. MATOS¶, H. PELTROCHE-LLACSAHUANGA<sup>3</sup>, #, A. A. PIZZIRANI-KLEINER\$, J. RAINER<sup>+</sup>, N. RICHARD-YEGRES§, V. VICENTE\*\* & F. YEGRES§

\*Centraalbureau voor Schimmelcultures, Baarn, the Netherlands; <sup>2</sup>Hospital de Clínicas, Federal University of Paraná, Paraná, Brazil; <sup>3</sup>Institute for Medical Microbiology, University Hospital, RWTH Aachen, Germany; §Universidad Nacional Experimental 'Francisco de Miranda', Coro, Venezuela; #Institute of Medical Immunology, University Hospital, RWTH Aachen, Germany; \$ESALQ – USP, Dept. de Genética, Piracicaba, Sao Paulo, Brazil; ¶Institute of Immunology and Microbiology, Medical Faculty, Ljubljana, Slovenia; <sup>+</sup>Institute of Microbiology, Leopold Franzens University, Innsbruck, Austria; \*\*Escola Superior de Agricultura 'Luiz de Queiroz', Piracicaba, Brazil

Data are presented on the clinically relevant black yeasts and their relatives, i.e., members of the Ascomycete order Chaetothyriales. In order to understand the pathology of these fungi it is essential to know their natural ecological niche. From a relatively low degree of molecular variability of the black yeast *Exophiala dermatitidis*, potential agent of brain infections in patients from East Asia, it is concluded that this species is an emerging pathogen, currently going through a process of active speciation. It is found to be an oligotrophic fungus in hot, moist environments, such as steambaths. *Cladophialophora*-, *Fonsecaea*- and *Ramichloridium*-like strains, known in humans as agents of chromoblastomycosis, are frequently found on rotten plant material, but the fungal molecular diversity in the environment is much higher than that on the human patient, so that it is difficult to trace the etiological agents of the disease with precision. This approach has been successful with *Cladophialophora carrionii*, of which cells resembling muriform cells, the tissue form of chromoblastomycosis, were found to occur in drying spines of cacti. Phagocytosis assays provide a method to distinguish between pathogens and non-pathogens, as the killing rates of strict saprobes proved to be consistently higher than of those species frequently known as agents of disease. The therapeutic possibilities for patients with chromoblastomycosis are reviewed.

**Keywords** antifungal therapy, black yeasts, chromoblastomycosis, phagocytosis

## Introduction

Black yeasts have been known since the end of the 19th century, but they still are among the most difficult fungal groups to identify and therefore the knowledge on this group is still only fragmentary. The diagnostic confusion in the past is not surprising, since the taxonomy of black

yeasts is now known to be much more complicated than was anticipated. With the application of molecular criteria a great number of undescribed species is encountered. This number is expected to increase even more when detailed studies in biodiversity are performed. Apparently undescribed taxa from the environment and even from human patients are regularly found, and their number is likely to augment exponentially when less commonly explored sources are sampled. It seems probable that within a few years from now the number of taxa known in black yeasts and their relatives will multiply tenfold.

Correspondence: G. S. De Hoog, Centraalbureau voor Schimmelcultures, PO Box 273, NL-3740 AG Baarn, the Netherlands. Tel.: +31 35 5481253; fax: +31 35 5416142; e-mail: de.Hoog@cbs.knaw.nl

Revealing further teleomorph/anamorph relationships will be key issues in the study of these organisms.

Molecular phylogeny has enabled the attribution of black yeast species to main groups in the fungal kingdom. One of the most interesting findings made in recent years has been the consistent relation of human pathogenic taxa (black yeasts as well as their filamentous counterparts) to a small, clearly delimited group, the order *Chaetothyriales*, and the family *Herpotrichiellaceae* in particular. This family is phylogenetically remote from the remaining bitunicate ascomycetes. It has been suggested that the fungi went through a process of rapid diversification, probably after having entered a new substratum. It is tempting to speculate that this substratum is the human body.

A reliable taxonomic system that reflects natural relationships has predictive value. It provides a clue towards understanding the ecology of species, as species appear to display a surprising ecological consistency. Species can be retrieved from their expected habitat after using enrichment techniques. Major evolutionary trends in the black yeasts and their allies not only concern human pathogenicity, but also hyperparasitism and osmophily. Each study on virulence factors should begin with detailed consideration of the phylogeny of the organism.

### Tracing the source and route of infection of neurotropic black yeasts

The black yeast *Exophiala dermatitidis* is known from the environment, but also from systemic mycoses in humans. In Southeast Asia fatal cerebral infections are noted in patients which are otherwise in good health. However, the preponderant clinical picture in Europe is subclinical colonization of the lungs of patients with cystic fibrosis (CF); the rare systemic cases in this part of the world are mild and occur in immunocompromised patients only. The two clinical pictures are partly caused by members of a single population, as has been determined by random amplified polymorphic DNA (RAPD). The question is whether *E. dermatitidis* is a contaminant/opportunistic fungus only, as might be concluded from its European occurrence, or whether it should be regarded as a systemic pathogen, as seems apparent from its behaviour in Southeast Asia.

To address this question, *E. dermatitidis* was compared with *Pseudallescheria boydii*, an environmental species showing neurotropism after temporary coma and aspiration of contaminated water. The taxon displays a remarkable degree of variability in ribosomal DNA (rDNA) internal transcribed spacer (ITS) sequences and polymerase chain reaction (PCR)-fingerprint data.

Within the species, several nuclear DNA homology groups are known, but identical strains (i.e., with >80% homology) vary by >10% in their ITS sequences. *P. boydii* easily forms a teleomorph in culture and thus it is likely to show abundant meiotic recombination. These data indicate that the taxon inhabits a permissive ecological niche (namely polluted, nitrogen-rich, water), where many genotypes that emerge in the course of evolution are able to survive and can occur next to each other. Due to its high degree of recombination the tree shows poor resolution.

*E. dermatitidis* is much less variable; no sexuality is known. This may indicate that the species is in an active process of adaptation to a new niche. The species was proven to be oligotrophic and thermophilic. These conditions are met, for example, in steambaths, which are hot and moist, and have slightly osmotic wall surfaces. This ecology explains the prevalence of the species in the lungs of CF patients. Bathing facilities in Europe were proven to contain several more *Exophiala* species, each inhabiting slightly different microniches determined by temperature relationships. Apparently, oligotrophism is an ecological mainstay. Neurotropism is also a plesiomorph characteristic in relatives of *Exophiala*, such as *Cladophialophora bantiana* and *Ramichloridium mackenziei*. Hence, combining the two ecological tendencies, *E. dermatitidis* is likely to be predisposed to adapt as a neurotropic pathogen. Its molecular structure seems to indicate that this event has happened only recently.

### Comparison of phagocytosis, oxidative burst and killing of black yeasts

Phylogenetic analysis of black yeasts and their relatives revealed that all type strains of the genus *Exophiala* clustered as a monophyletic group together with members of the *Herpotrichiellaceae* (order *Chaetothyriales*), indicating a close relationship [1]. Therefore, it may be expected that they share virulence factors resulting in comparable pathogenicity. The presence of melanin has been considered as an important virulence factor and it was recently shown that this leads to lower killing rates in *E. dermatitidis* when comparing melanized strains with a respective albino mutant in a bioassay using whole human blood [2]. Surprisingly, melanized species considered virulent were found at a phylogenetically short distance to melanized, but virtually non-virulent species, e.g. *E. spinifera* and *Phaeococcomyces exophialae* [3]. Since the most important defense system of the human organism against fungal infections are professional phagocytes (i.e., macrophages and neutrophils releasing reactive oxidative

intermediates [ROI] that have been described to be able to kill yeasts and filamentous fungi), the present study addressed this discrepancy assessing phagocytosis, evoked oxidative burst, and killing by human neutrophils of black yeast species ( $n = 9$ ) exhibiting different pathogenic potential. A recently developed method for testing phagocytosis of *E. dermatitidis* and its albino mutants by human neutrophils was applied using flow cytometry in combination with a killing bioassay comprising six independent assays [2].

Whereas phagocytosis and the evoked oxidative burst were increasing nearly synchronously during the test period, surprisingly, the degree of killing differed significantly after 5 h of co-incubation in whole blood of healthy human donors. Two groups of fungi could be identified that were found to be killed to a high (range 96.4–80.5%; group 1) or low (range 65.7–50.2%; group 2) degree. Group one comprised (data presented as per cent killed after 5 h incubation in whole blood): *Candida albicans* DSM 11943 (95.3%), *Saccharomyces cerevisiae* DSM 1333 (94.6%), *Hortaea werneckii* CBS 107.67<sup>NT</sup> (80.5%), *E. castellanii* CBS 158.58<sup>NT</sup> (96.4%), *Phaeoanellomyces elegans* UTMB 1286<sup>T</sup> (93.2%), *P. exophialae* CBS 668.76<sup>T</sup> (86.6%), and the white mutant strains of *Exophiala dermatitidis* mel<sup>3-</sup> ATCC 44504 (95.0%). Group two comprised: *E. dermatitidis* ATCC 34100 (61.0%), *E. dermatitidis* CBS 207.35<sup>T</sup> (65.7%), *E. jeanselmei* ATCC 34123<sup>T</sup> (50.2%), *E. mesophila* CBS 402.95<sup>T</sup> (63.1%), *E. bergeri* CBS 526.76<sup>T</sup> (62.8%), and *E. spinifera* CBS 107.67<sup>T</sup> (57.1%).

The killing of the non-pigmented yeasts *C. albicans* and *S. cerevisiae* was comparable in degree to that seen with the non-melanized *E. dermatitidis* strain. The deposited melanin in the cell wall of black fungi is known to absorb light and heat energy due to numerous free carboxyl groups. This accounts for many of the protective, as well as the photosensitizing, properties of melanin [4]. In the case of plant pathogens, it is well known that melanin increases cell wall rigidity and thus it might render killing more difficult [5]. In the case of ascomycetous black yeasts, dihydroxynaphthalene (DHN) melanin is formed by oxidative polymerization of phenolic compounds [6]. It can be speculated that the presence of melanin confers a higher capacity to neutralize oxidants, resulting in survival during the evoked oxidative burst in the phagolysosome of neutrophils. Thus, for all melanized yeasts analyzed in the present study a comparable survival rate would be expected, especially since the degree of phagocytosis and evoked oxidative burst was comparable in all strains studied. Intracellular location of the yeast cells associ-

ated with the neutrophils was ensured by microscopic evaluation of the phagocytosis process [2].

Despite our working hypothesis that due to their close phylogenetic relationship the same type of melanin should be present in all the black yeasts studied, the degree of killing after 5 h differed significantly between the melanized strains studied. The black yeasts that were killed to a degree comparable to that seen in non-melanized strains (i.e., *C. albicans*, *E. dermatitidis* mel<sup>3-</sup>, *S. cerevisiae*) are mainly isolated from mild human infections, whereas strains killed to a lesser extent are well-known for their potential to cause severe infections, with the exception of *E. mesophila*. In the latter species its reduced growth at 37 °C might prevent invasion of the human host [7].

Invasiveness of fungal pathogens has often been linked to defects in cell-mediated immunity, but the results of the present study clearly show that neutrophils of healthy donors killed pathogenic melanized species to a lesser extent than other species. Since neutrophils are still considered to be the most important effector cells, low killing rates of the respective species most probably reflect their high virulence. Therefore, the striking differences in killing rates of melanized species strongly indicate that melanization of the cell wall alone is insufficient to confer the killing resistance.

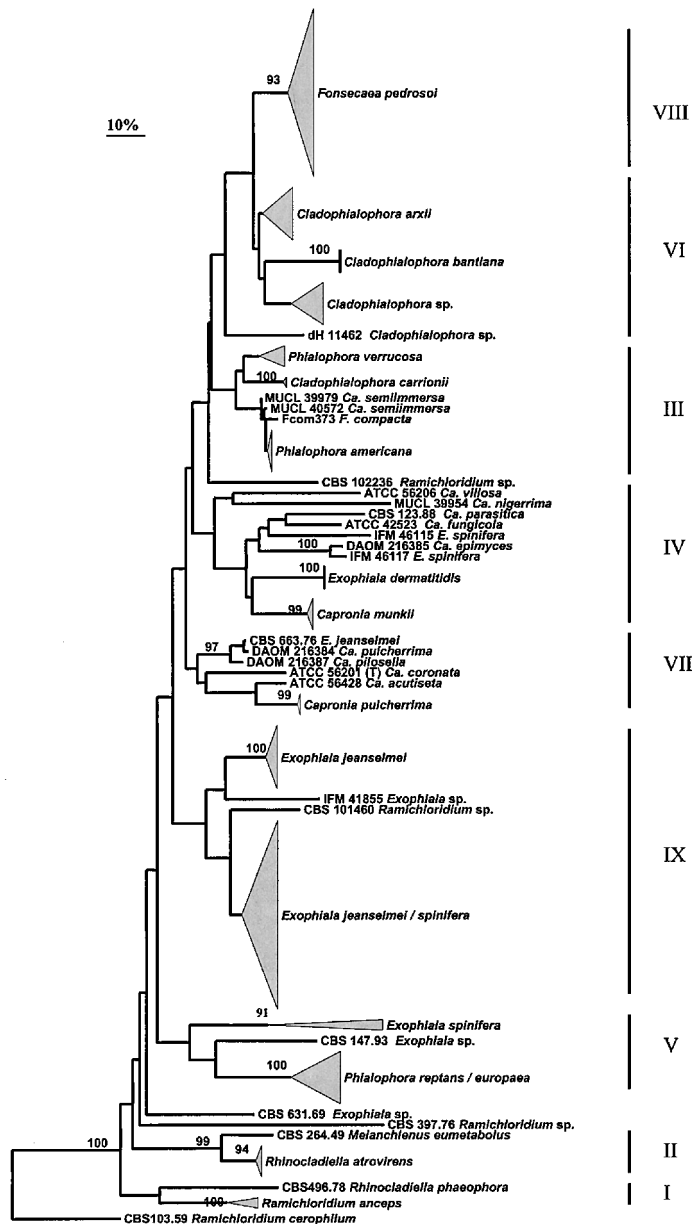
If all black yeasts tested possess the same type and structure of melanin the difference in killing might be attributable to the expression of an additional virulence factor. Due to the close phylogenetic relationship of *Exophiala* species [1], acquisition of novel virulence factors is unlikely. Therefore, one can speculate whether expression of such a plesiomorphic virulence factor depends upon ecological stress factors. Another explanation is that due to the complex composition of melanin, i.e., monomers usually complexed with proteins and carbohydrates [4], differences in final polymerization could result in different linkage patterns of monomers with different a capacity for scavenging radicals which may contribute to the observed differences. Survival in the phagolysosome might subsequently result in its penetration and invasion of the surrounding tissue, since melanized hyphae exert larger turgor-derived forces at their apices than non-melanized cells [8]. Definitive proof of the involvement of melanin in the virulence of black yeasts awaits further experiments by specifically altering DHN-melanin biosynthesis pathway by, for example, gene disruption. Due to the establishment of genetic transformation, gene disruption protocols and a gene expression system [9], such experiments could be feasible for *E. dermatitidis* in the near future.

## Molecular identification of dematiaceous environmental versus patient strains

An attempt was made to find agents of human chromoblastomycosis in the environment, on the assumption that the infection is initiated by traumatic inoculation and thus that the aetiological agents are likely to be saprobes. In a phylogenetic tree (Fig. 1) derived from sequences of ITS1, ITS2 and 5-8S rDNA we included all known agents of chromoblastomycosis, supplemented with morphologically similar environmental strains and

other potentially pathogenic members of the *Herpotrichiellaceae*. Approximately 10 groups can be recognized. Reference strains of *Ramichloridium*, *Rhinochlaidiella* and *Fonsecaea* formed distinct groups (I, II and VIII).

A group designated as *Fonsecaea* contained, except for reference strains of *F. pedrosoi*, a number of clinical isolates from patients with chromoblastomycosis but also some saprobes (VIII). The reference strains of *F. pedrosoi* and *F. compacta* comprised a subgroup at some distance



**Fig. 1** Phylogenetic tree of agents of chromoblastomycosis and their relatives, based on the ITS1, ITS2 and 5-8S rDNA sequences, using the neighbor joining algorithm.

from the Brazilian isolates. This may indicate a close kinship between saprobic and pathogenic strains from the same geographic region.

Species of *Phialophora* are in a subgroup exclusively comprising agents of subcutaneous mycoses. The monophyletic character of this group is underlined by the presence of phialides with collarettes in all strains. Strains of *Phialophora verrucosa*, one of the classical agents of chromoblastomycosis, formed a distinct clade with representatives able to form muriform cells, as observed in *Fonsecaea*. This fact supports the suggestion that the muriform cells may indeed be a main virulence factor in the development of the disease, representing an adaptation to the conditions prevailing in host tissue.

A complex containing the type strain of *Cladophialophora arxii* comprised a number of environmental strains, and *C. devriesii* (CBS 834.96). Gerrits van den Ende & De Hoog [10] found a relatively close kinship between *C. bantiana* and non-neurotropic *Cladophialophora* species. In *Cladophialophora*, the presence of introns in the 18S rDNA subunit may be strictly related to the specialization of the neurotropism of *C. bantiana* [10].

Saprobic species with *Ramichloridium*-like morphology were found all over the tree. Strain F11PLA was found in group III with species of *Cladophialophora* that are agents of chromoblastomycosis. The same holds true for *Exophiala*-like anamorphs. Different levels of adaptation seem to occur in these groups. Group IV was the only group with teleomorph relationships, confirming earlier reports [11–14]. The species *E. spinifera* and *E. jeanselmei* formed a well-defined monophyletic branch [15]. Based on ITS sequences, the same studies found close affinity between *E. spinifera* and *Capronia munkii*. Haase *et al.* [16] observed *Capronia* teleomorphs all along an SSU phylogenetic tree of the *Herpotrichiellaceae*.

Using RAPD, the majority of *F. pedrosoi* strains were located in group I, with specific subgroups presenting bootstrap values above 85%, which was partly explained by saprobic and pathogenic strains being isolated from the same geographic region. Similar results were obtained with ITS rDNA sequence analysis and with nutritional physiology. Isolate FP8D, which is morphologically *Cladosporium*-like, was found to cluster with isolates from clinical cases, based on RAPD marker analysis. In the recent phylogeny-based taxonomy, *Cladosporium* contains only saprobes which are classified in the order *Dothideales*, family *Mycosphaerellaceae*, whereas the pathogenic genus *Cladophialophora* belongs to the *Herpotrichiellaceae*, order *Chaetothyriales*. Apparently the two genera with very different clinical significance are sometimes morphologically difficult to distinguish from each other.

### **C. carrionii in cacti at the chromomycosis semi-arid endemic zone in Venezuela**

Chromomycosis is a chronic subcutaneous granulomatous disease caused by several melanized dimorphic fungi reported predominantly from tropical countries. In Venezuela, the first case was described by O'Daly in 1938; in 1943 he also reported for the first time an aetiological agent now known as *C. carrionii*. The endemic area is in the Northwest of Venezuela. Since 1959, Borelli noted that patients infected by *Fonsecaea pedrosoi* came mainly from humid climates, whereas *C. carrionii* seemed to occur in semi-arid zones. Keeping goats is one of the main agricultural activities in the latter area and over the years labourers repeatedly traumatize themselves with cacti thorns. An increase in persons susceptible to the development of chromoblastomycosis is thus observed. Chromoblastomycosis is considered to be a multifactorial disease, involving genetic as well as environmental factors. A prevalence of 16/1000 cases of chromoblastomycosis should be explained by the coincidence in the same geographical area of a homogeneous genetically susceptible population and facility of exposure to the natural source of infection. Since 1983, several studies were carried out at Francisco de Miranda University in order to confirm the presence of *C. carrionii* in the endemic zone [17–20].

Samples were collected in the vicinity close to the patients' houses: fragments of cacti, spines, decaying wood and fence bark fragments. Brown erosive lesions in cactus stems were studied. Thin sections of vegetative tissue, spines and wood were carefully examined to search for brown muriform cells. Positive samples were covered with a thin layer of glycerin/yeast, peptone and glucose liquid medium ( $\frac{1}{2}$  volume), placed on a slide upon a bent glass rod into a Petri dish with 5 ml of sterile water to maintain humidity and incubated at room temperature with daily examination. Proteolytic activity and thermotolerance tests were carried out to confirm strain identification.

Several isolates of *C. carrionii*, one of *Sporothrix schenckii*, and a number of unidentified fungal species, were repeatedly observed to produce similar spherical, thick-walled cells growing by isotropic enlargement. *C. carrionii* was detected in 11 localities in association with common xerophytes: *Prosopis juliflora*, *Aloe vera*, and the *Cactaceae* *Opuntia caribaea*, *O. caracasana*, *Stenocereus griseus* and *Cereus lanuginosus*. Brown muriform cells were observed in the stems of living *Cactaceae*, in the medullar tissue, and in the spines.

It is postulated that the fungi survive in a very dry, hostile tropical environment inside living cactus tissues. The saprobic filamentous form rapidly expands under

favorable conditions on the decaying wood surface, or *in vitro*. After accidental implantation of the pathogen into the human skin, a localized subcutaneous chronic granulomatous lesion may then occur.

*C. carrionii* is ubiquitous in the semi-arid part of the endemic area, where decaying wood and spines of xerophytes, predominantly *Cactaceae*, have been implicated as a source of infection by the rural population and could be considered as the natural reservoir of the fungus. It is important to clarify the mechanisms of infection and pathogenicity of this fungus in humans and in *Cactaceae*.

### Chromoblastomycosis: a therapeutic challenge

Chromoblastomycosis (CBM) is a chronic, subcutaneous fungal infection, caused by the transcutaneous implantation of several species of dematiaceous fungi. The disease is more frequent in tropical and subtropical regions among rural workers. After traumatic implantation, the initial lesion can evolve into pleomorphic lesions, leading to dense dermal fibrosis and oedema [21,22]. CBM lesions are recalcitrant and extremely difficult to eradicate. In this manner, patients with CBM are a true therapeutic challenge for clinicians. During the last few decades, several treatment regimens have been employed [23–28]. In the early stages, the lesions respond to surgical resection but later, as the severity increases, better results are achieved with chemotherapy. Therapeutic success can be related to the aetiological agent (*C. carrionii* is more sensitive than *F. pedrosoi* [29]), to the severity of the disease (oedema and dermal fibrosis can reduce antifungal tissue levels) and obviously, to the choice of the antifungal drug [30]. There are no comparative trials in CBM. In most of the clinical trials, the lesions are not graded according to severity and standardized criteria of cure are not used by the different authors dealing with this mycosis. Currently, itraconazole (ITZ) alone or combined with flucytosine or topical liquid nitrogen (cryotherapy) appears to be the best treatment for CBM [28–32].

The study of 71 patients with chromoblastomycosis in the State of Paraná, South Region of Brazil, between 1985 and 1996, accumulated information relating to the aetiology, epidemiology, clinical course and treatment of the disease. *F. pedrosoi* was the primary aetiological agent, and was isolated in 94.3% of the cases. However, unusual agents such as *F. compacta*, *E. jeanselmei* and *E. castellanii* were detected in the lesions of three patients that presented with typically muriform cells upon histopathological examination. The research of the epidemiological pathways of autochthonous cases revealed that in

the State of Paraná, transmission of the disease is mainly occupational, affecting the inhabitants of the State's uplands. In 48 patients, a non-comparative clinical trial with itraconazole was carried out to evaluate its efficacy and toxicity. Eighteen patients were considered unevaluable because they failed to return for their control visits or because of non-continuous therapy. The CBM lesions were classified according to morphology and severity. A mild form was defined as a solitary plaque or nodule measuring less than 5 cm in diameter. A moderate form was taken to be solitary or multiple lesions (nodular, verruciform or plaque types), existing alone or in combination, covering one or two adjacent cutaneous regions, and measuring less than 15 cm in diameter. The severe form consisted of any type of lesion, alone or in combination, covering extensive cutaneous regions, whether adjacent or non-adjacent [30]. All subjects received itraconazole at 200–400 mg day<sup>-1</sup> until the established criteria of cure were achieved. Clinical criteria included: disappearance of pain and itching, and complete healing of all lesions with scarring. Mycological criteria were the absence of pathogens on direct microscopic examination and no fungal isolation on culture. Histological criteria included absence of pathogens, atrophy of the epidermis, disappearance of microabscesses and granulomas, replacement of granulomatous infiltrate by chronic inflammation and fibrosis. The persistence of all these findings had to continue for three consecutive monthly biopsies [33]. Clinical, mycological, histopathological and laboratory evaluations were performed before, during and after therapy. In order to establish whether the chronic itraconazole therapy could interfere in human steroidogenesis and androgenesis, the adrenal response to corticotropin and testosterone was evaluated in 15 patients by radioimmunoassay.

This report presents the results obtained with 30 CBM patients treated with itraconazole (Table 1). Nine patients (30%) presented mild CBM lesions with a median of 7.5 (range 1–19) years of duration. Four patients (44%) in this group had been treated previously. In 12 patients (40%), the lesions were moderate and had been present for a median time of 20 (range 6–50) years. In this group, five patients (42%) referred earlier treatments with antifungal drugs. Finally, lesions were typed as severe in nine patients (30%) and were of long duration, median 24 (range 18–40) years. Sixteen patients (53%) had been treated previously. Final assessment showed that eight patients (89%) with mild forms achieved clinical and mycological cure after 10.9 (range 7–17.6) months of therapy. No relapses were observed in this group after the mean time of 31.2 (range 12–72) months. Similar responses were observed in 11 of the 12 patients (91%)

**Table 1** Clinical and demographic characteristics of 30 patients with chromoblastomycosis treated with itraconazole

Clinical form	Clinical and mycological cure <i>n</i> (%)	Duration of treatment (months (median))	Improvement <i>n</i> (%)
Mild	8 (89%)	10.9 (7–17.6)	1 (11%)
Moderate	11 (91%)	12.9 (5–31)	1 (9%)
Severe	4 (44%)	30 (10–51)	5 (56%)
Total	23 (76%)	18	7 (24%)

with moderate forms, after an average of 12.9 (range 5–31) months of continuous treatment. In this group, one patient relapsed after 6.3 months of follow-up while the remaining patients did not relapse (12–60 months follow-up). Among the nine patients with severe CBM lesions, four (44%) had clinical and mycological response after a mean of 30 (range 10–51) months of treatment, and the remaining patients had improved significantly. One relapse was observed during the follow-up (after 35 months), but the patient improved again after a new course of therapy. No significant changes in the values of hematological and biochemical tests were observed.

Mean cortisol and testosterone concentrations at baseline were  $12.4 \mu\text{g dl}^{-1}$  and  $454 \text{ ng dl}^{-1}$ , respectively, and after  $12.4 \pm 5.2$  months of treatment with itraconazole were  $15.4 \mu\text{g dl}^{-1}$  and  $480 \text{ ng dl}^{-1}$ , respectively. There was no clinical or laboratory evidence of steroidogenic or androgenic impairment [34].

These results show that the therapy with itraconazole can achieve long lasting clinical and mycological cures in most of the patients having mild to moderate forms of CBM, after prolonged periods of treatment. On the other hand, only 44% of the severe cases were cured clinically and mycologically. The clinical outcome observed in those patients presenting severe lesions of CBM, could be related to decreased itraconazole tissue concentrations. Local fibrosis, oedema and bacterial co-infection are common associated factors that can decrease local itraconazole concentration, especially in the subcutaneous tissues, which in severe lesions are replaced by dense fibrosis.

Other therapeutic strategies available include the combination of itraconazole with flucytosine and/or the association of local liquid nitrogen [31,32]. Both methods may reduce the duration of itraconazole treatment. According to preliminary data, terbinafine at a daily dose of 500 mg for 6–12 months also seems to be effective in CBM (efficacy 85%). However, the results presented by Esterre *et al.* [35] cannot be compared with our results because different assessment criteria were employed in both trials [30,35].

In the future, the new antifungal drugs under development may play an important role in the treatment of CBM. *In vitro* dematiaceous fungi are very sensitive to

the new triazoles voriconazole and posaconazole and also to MK-0991, an echinocandin [36,37]. The results published to date suggest that these new agents have broad-spectrum activities *in vitro*; however, their effectiveness in the treatment of human mycoses remains to be determined.

### Contributors

The contributors to this symposium were: **G. S. de Hoog**, **D. Attili Angelis**, **A. H. G. Gerrits van den Ende**, **T. Matos**, **A. A. Pizzirani-Kleiner**, **J. Rainer** & **V. Vicente**, *Tracing the source and route of infection of neurotropic black yeasts*; **G. Haase** & **H. Peltroche-Llacsahuanga**, *Comparison of phagocytosis, oxidative burst and killing of black yeasts with different pathogenic potential*; **V. Vicente**, *Molecular identification of dematiaceous environmental vs. patient strains*; **G. Zeppenfeldt-Fernandez**, **N. Richard-Yegres** & **F. Yegres**, *Cladophialophora carrionii in cacti at the chromomycosis semi-arid endemic zone in Venezuela*; **F. Queiroz-Telles**, *Chromoblastomycosis: a therapeutic challenge*. The co-convenors were **G. S. de Hoog** and **F. Queiroz-Telles**.

### References

- Haase G, Sonntag L, Melzer-Krick B, De Hoog GS. Phylogenetic inference by SSU-gene analysis of members of the *Herpotrichiellaceae* with special reference to human pathogenic species. *Stud Mycol* 1999; **43**: 80–97.
- Schnitzler N, Peltroche-Llacsahuanga H, Bestier N, Zündorf J, Lütticken J, Haase G. Effect of melanin and carotenoids of *Exophiala (Wangiella) dermatitidis* on phagocytosis, oxidative burst, and killing by human neutrophils. *Infect Immun* 1999; **67**: 94–101.
- Fader RC, McGinnis MR. Infections caused by dematiaceous fungi: Chromoblastomycosis and phaeoerythromycosis. *Infect Dis Clin North Am* 1988; **2**: 925–938.
- Butler MJ, Day AW. Fungal melanins: a review. *Can J Microbiol* 1998; **44**: 1115–1136.
- Money NP, Howard RJ. Confirmation of a link between fungal pigmentation, turgor pressure, and pathogenicity using a new method of turgor measurement. *Fungal Genet Biol* 1996; **20**: 217–227.
- Wheeler MH, Bell AA. Melanins and their importance in pathogenic fungi. *Curr Top Med Mycol* 1988; **2**: 338–387.
- Listemann H, Freiesleben H. *Exophiala mesophila* spec. nov. *Mycoses* 1996; **39**: 1–3.

- 8 Brush L, Money NP. Invasive hyphal growth in *Wangiella dermatitidis* is induced by stab inoculation and shows dependence upon melanin biosynthesis. *Fungal Gen Biol* 1999; **28**: 190–200.
- 9 Ye X, Feng B, Szanislo PJ. A color-selectable and site-specific integrative transformation system for gene expression studies in the dematiaceous fungus *Wangiella (Exophiala) dermatitidis*. *Curr Genet* 1999; **36**: 241–247.
- 10 Gerrits van den Ende AHG, De Hoog GS. Variability and molecular diagnostics of the neurotropic species *Cladophialophora bantiana*. *Stud Mycol* 1999; **43**: 151–162.
- 11 Untereiner WA. Fruiting studies in species of *Capronia (Herpotrichiellaceae)*. *Ant van Leeuwenhoek* 1995; **68**: 3–17.
- 12 Untereiner WA. Taxonomy of selected members of the ascomycete genus *Capronia* with notes on anamorph-teleomorph connections. *Mycologia* 1997; **89**: 120–131.
- 13 Untereiner WA, Straus NA, Malloch D. A molecular-morpho-taxonomic approach to the systematics of the *Herpotrichiellaceae* and allied black yeasts. *Mycol Res* 1995; **99**: 897–913.
- 14 Untereiner WA, Naveau F. Molecular systematics of the *Herpotrichiellaceae* with an assessment of the phylogenetic positions of *Exophiala dermatitidis* and *Phialophora americana*. *Mycologia* 1999; **91**: 67–83.
- 15 De Hoog GS, Poonwan N, Gerrits van den Ende AHG. Taxonomy of *Exophiala spinifera* and its relationship to *E. jeanselmei*. *Stud Mycol* 1999; **43**: 133–142.
- 16 Haase G, Sonntag L, Melzer-Krick B, De Hoog GS. Phylogenetic inference by SSU-gene analysis of members of the *Herpotrichiellaceae* with special reference to human pathogenic species. *Stud Mycol* 1999; **43**: 80–97.
- 17 Richard-Yegres N, Yegres F. *Cladosporium carrionii* en vegetación xerófila. Aislamiento en una zona endémica para la cromomycosis, 1987. *Dermatol Venez* 1989; **25**: 15–18.
- 18 Richard-Yegres N, Yegres F, Nishimura K, Makoto M. Virulence and pathogenicity of human and environmental isolates of *Cladosporium carrionii* in new born ddY mice. *Mycopathologia* 1991; **114**: 71–76.
- 19 Richard-Yegres N, Yegres F, Zeppenfeldt G. Cromomycosis: epidemia rural, laboral y familiar en Venezuela. *Rev Iberoam Micol* 1992; **9**: 38–41.
- 20 Zeppenfeldt G, Richard-Yegres N, Yegres F, Hernandez R. *Cladosporium carrionii*: hongo dimórfico en cactáceas de la zona endémica para la cromomycosis en Venezuela. *Rev Iberoam Micol* 1994; **11**: 61–63.
- 21 Carrión AL. Chromoblastomycosis. *Ann NY Acad Sci* 1950; **50**: 1255–1282.
- 22 McGinnis MR. Chromoblastomycosis and phaeohyphomycosis: new concepts, diagnosis and mycology. *J Am Acad Dermatol* 1983; **8**: 1–16.
- 23 Bayles MAH. Chromomycosis: treatment with thiabendazole. *Arch Dermatol* 1971; **104**: 476–485.
- 24 Polak AM. Determination de la synergie entre la 5-fluocytosine et l'amphotericin B au moyen de differents modèles *in vitro* et *in vivo*. *Bull Soc Fr Mycol Méd* 1974; **3**: 175–178.
- 25 Bopp C. Therapy of chromoblastomycosis with a new method. *Med Cutan Ibero Lat Am* 1976; **4**: 285–292.
- 26 Lubritz RR, Spence JE. Chromoblastomycosis. Cure by cryosurgery. *Int J Derm* 1978; **17**: 830–832.
- 27 McBurney EI. Chromoblastomycosis treatment with ketoconazole. *Cutis* 1982; **30**: 746–748.
- 28 Restrepo A, Gonzales A, Gomez I, Arango M, De Bedout C. Treatment of chromoblastomycosis with itraconazole. *Ann NY Acad Sci* 1988; **544**: 504–516.
- 29 Borelli D. A clinical trial of itraconazole in the treatment of deep mycoses and leishmaniasis. *Rev Infect Dis* 1987; **9** (Suppl. 1): S57–S63.
- 30 Queiroz-Telles FF, Purim KS, Fillus JN, et al. Itraconazole in the treatment of chromoblastomycosis due to *Fonsecaea pedrosoi*. *Int J Dermatol* 1992; **31**: 805–812.
- 31 Bolzinger T, Pradinaud R, Sainte-Marie D, Dupont B, Chwet-zoff E. Traitement de quatre cas de chromomycose à *Fonsecaea pedrosoi* par l'association 5-fluorocytosine-itraconazole. *Nouv Derm* 1991; **10**: 462–466.
- 32 Kullavanijaya P, Rojanavanich V. Successful treatment of chromoblastomycosis due to *Fonsecaea pedrosoi* by combination of itraconazole and cryotherapy. *Int J Dermatol* 1995; **34**: 804–807.
- 33 Bayles MAH. Chromomycosis. *Bailliere Clin Trop Med Commun Dis* 1989; 45–70.
- 34 Queiroz-Telles F, Purim KS, Boguszewski CL, Afonso FC, Graf H. Adrenal response to corticotrophin and testosterone during long-term therapy with itraconazole in patients with chromoblastomycosis. *J Antimicrob Agents Chemother* 1997; **40**: 899–902.
- 35 Esterre P, Inzan CK, Ramarcel ER, et al. Treatment of chromomycosis with terbinafine: preliminary results of an open pilot study. *Br J Dermatol* 1996; **134** (Suppl. 46): 33–36.
- 36 Marco F, Pfaller MA, Messer AS, Jones RN. Antifungal activity of a new triazole, voriconazole (UK-109,496), compared with three other antifungal agents tested against clinical isolates of filamentous fungi. *Med Mycol* 1998; **36**: 433–461.
- 37 Espinel-Ingroff A. Comparison of *in vitro* activities of the new triazole SCH56592 and the echinocandins MK-0991 (L-743,872) and LY303366 against opportunistic filamentous and dimorphic fungi and yeasts. *J Clin Microbiol* 1998; **36**: 2950–2961.