

Bochdalek hernia with concomitant partial situs inversus in an adult

E. Gedik¹, S. Girgin¹, M.C. Tuncer², S. Onat³, A. Avci³, Ö. Karabulut²

¹Department of General Surgery, Dicle University, Faculty of Medicine, Diyarbakir, Turkey

²Department of Anatomy, Dicle University, Faculty of Medicine, Diyarbakir, Turkey

³Department of Thoracic Surgery, Dicle University, Faculty of Medicine, Diyarbakir, Turkey

[Received 15 March 2010; Accepted 13 April 2010]

We report the case of 44-year-old woman with a left-sided Bochdalek hernia (BH) with concomitant partial situs inversus. The patient was presented from the outpatient clinic with lower chest discomfort. She had suffered from abdominal pain for one year, with no history of trauma, previous surgery, or extreme physical exertion. Chest radiograph revealed a large left-sided BH. The patient underwent thoracotomy. Intestinal organs, containing bowel, small intestine, caecum, and appendix were seen in the left hemithorax. Because of the failure to reduce the intestinal organs into the peritoneal cavity, laparotomy was performed. The right side of the abdominal cavity was empty. In conclusion, partial situs inversus was diagnosed. The diaphragmatic defect was repaired with non-absorbable sutures via laparotomy, and with a prolene mesh via thoracotomy. Bochdalek hernia with partial situs inversus is a rare clinical entity with none reported in medical literature. (Folia Morphol 2010; 69, 2: 119–122)

Key words: Bochdalek hernia, adult, hernia repair, situs inversus, surgery

INTRODUCTION

Congenital diaphragmatic hernia occurs in 1 in every 2000–3000 live births and accounts for 8% of all major congenital anomalies. The risk of recurrence of isolated congenital diaphragmatic hernia in future siblings is approximately 2%. Familial congenital diaphragmatic hernia is rare (< 2% of all cases), and both autosomal recessive and autosomal dominant patterns of inheritance have been reported. Congenital diaphragmatic hernia is a recognized finding in Cornelia de Lange syndrome and also occurs as a prominent feature of Fryns syndrome, an autosomal recessive disorder with variable features, including diaphragmatic hernia, cleft lip or palate, and distal digital hypoplasia [4, 16].

Congenital hernias resulting from a developmental failure of posterolateral diaphragmatic foramina to fuse properly were first described by Vincent Alexander Bochdalek in 1848 [12], although the origins of descriptions of diaphragmatic hernia can be dated to writings of 1690 [2]. Diaphragmatic hernias through the posterolateral foramen of Bochdalek represent the commonest type of congenital diaphragmatic hernia [1]. The majority present during neonatal life and have a poor prognosis, being associated with congenital pulmonary abnormalities [10, 13, 17]. Left-sided Bochdalek hernia (BH) occurs in approximately 85% of cases. Left-sided hernias allow herniation of both the small and large bowel and intra-abdominal solid organs into the thoracic

cavity. In right-sided hernias (13% of cases), only the liver and a portion of the large bowel tend to herniate. Bilateral hernias are uncommon and are usually fatal [6, 9]. Presentation of a Bochdalek hernia in an adult is exceptionally rare — Kirkland published the first review of 34 cases of adult BH in 1959, and as of 1992 only 100 cases of symptomatic adult BH have been reported in world literature [8]; however, with the growing use of abdominal computed tomography (CT) this abnormality is being increasingly detected in asymptomatic individuals. A Medline search of the literature revealed only 100 cases of BH in adults [11]. BH with concomitant partial situs inversus has not been reported before. The aim of this report is to present rare cases of adult presentation of BH with concomitant partial situs inversus, and to discuss the clinical presentation and management

CASE PRESENTATION

A 44-year-old woman was admitted to the outpatient clinic with left-sided lower chest discomfort and shortness of breath on physical exertion. She had suffered from abdominal pain for one year. There was no significant past medical history or trauma. Auscultation revealed no audible breath sounds in the left side of the chest. Physical examinations revealed stable vital signs. The laboratory results were within normal limits. Chest radiography showed bowel loops in the left hemithorax (Fig. 1). In addition, computed chest tomography was performed. It revealed a left-sided Bochdalek hernia, localization of intestinal organs in the left hemithorax, compressed left lung parenchyma, and mediastinal shifting (Fig. 2). It was thought that the diaphragmatic hernia had existed for a long time. For this reason, left side thoracotomy was planned to separate severe adhesions between the thoracic and intestinal organs. On the other hand, because of defect wideness, we were obliged to perform a laparotomy because organ locations were more certain (avoiding torsion) in the abdomen. The omentum, ascending and transverse colon, small intestine, caecum, and appendix were observed in the left hemithorax. A hernial sac was not revealed. The left lung was in hypoplasia. Intestinal organs were viable. Signs of strangulation and necrosis were not seen. A posterolateral diaphragmatic defect was measured at 6 × 3 cm. The adhesions between the intestinal and thoracic organs (pericardium and thoracic wall) were separated carefully. Reduction of the intestinal organs into the peritoneal cavity was attempt-

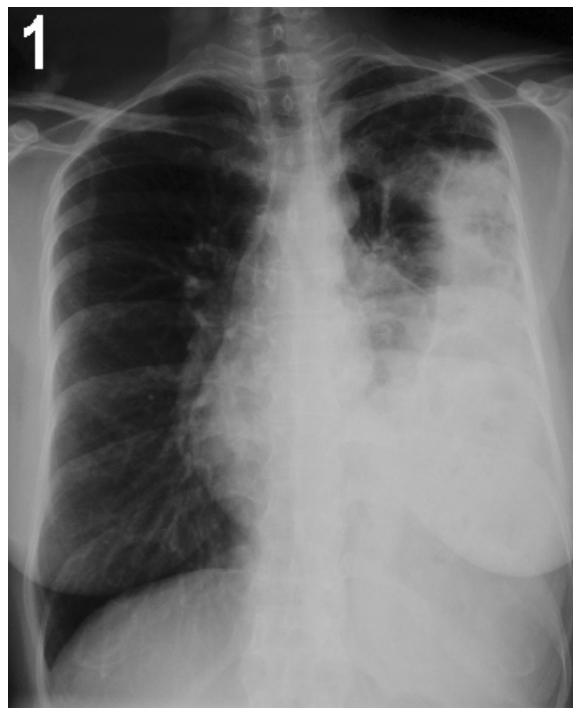

Figure 1. Chest radiograph PA view showing raised left hemidiaphragm and presence of air filled bowel loops in the left thoracic cavity.

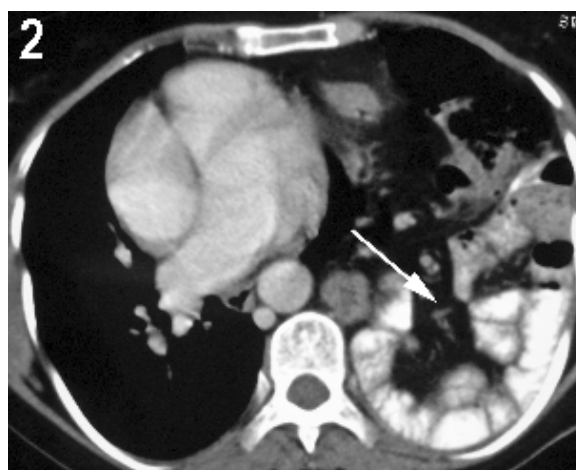


Figure 2. Computed tomography of the abdomen, showing herniation of intra-abdominal contents into left chest in a patient with Bochdalek hernia.

ed, but it failed. Thus, the thoracotomy incision was closed temporarily. For this reason, a laparotomy with median incision was performed. The right lower part of the abdominal cavity was empty. The spleen was localized midline. Mesocolon ascendens and transversalis were localized in the midline, and radix mesenterii was localized to the left of the centre. Consequentially, partial situs inversus was observed. Furthermore, the diaphragmatic defect was

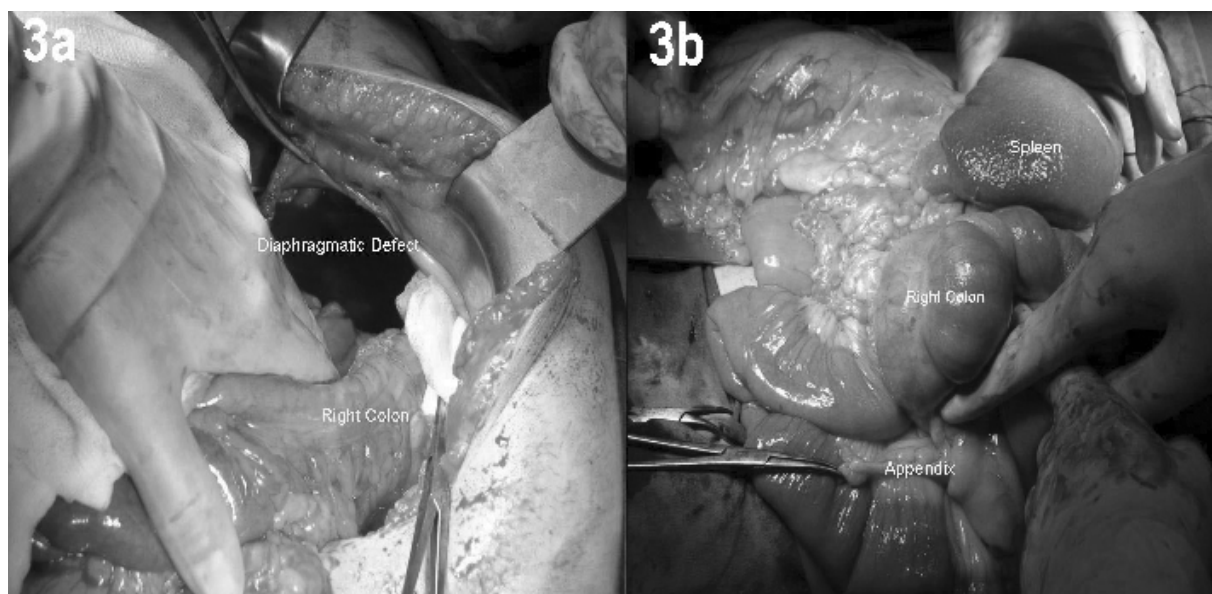


Figure 3. Partial situs inversus and contents of hernia sac.

enlarged to 8 cm to reduce intestinal organs. Visceral complications of BH such as obstruction or strangulation were not revealed (Fig. 3A, B). Closure and repair of the diaphragmatic defect were applied in two steps. First, the diaphragmatic defect was repaired with non-absorbable sutures via laparotomy. Later, the laparotomy incision was closed and the patient was repositioned lateral decubitus for thoracotomy. A prolene mesh was used for propping the diaphragmatic restoration via thoracotomy (Fig. 4) then the thoracotomy incision was closed. The patient made an uneventful recovery and was discharged from the hospital on day 27.

DISCUSSION

Vincent Alexander Bochdalek first described a congenital hernia resulting from the developmental failure of the posterolateral foramina to fuse properly in 1848 [5]. Most BH are diagnosed in children because of pulmonary insufficiency symptoms. BH in adulthood is unusual. The right hemidiaphragm is fully formed before the left, hence most BH are found on the left side as in our presented case.

Clinical presentation of BH in adults may vary from an incidental finding on radiological investigation to strangulation of the contents. Our patient was admitted with nonspecific symptoms such as chest discomfort and abdominal pain. The physical examination of BH patients is typically misleading, as was ours. Chest X-rays show gas-fluid levels and bowel loops in the chest and thus suggest the diagnosis in more than 70% of cases; however, a normal

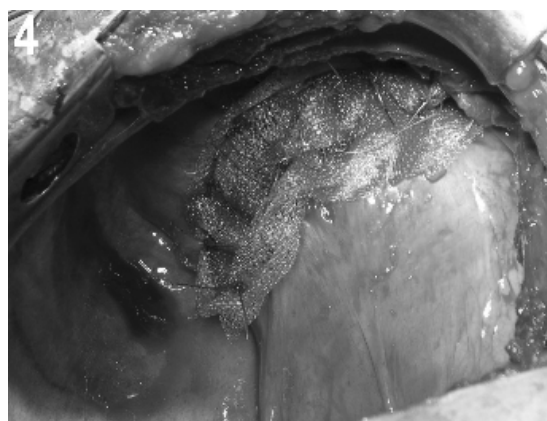


Figure 4. Diaphragmatic restoration via thoracotomy.

chest X-ray does not rule out a BH [15]. Thin-section computed tomography scanning is highly accurate and should be regarded as a standard method to diagnose a BH that presents either electively or as an emergency [7]. The presented case was evaluated electively after thin-section CT scanning.

The treatment of a BH is surgical and includes reducing the abdominal contents and repairing the diaphragmatic defect. The best approach for management of left-sided hernias is controversial. Those who advocate a thoracotomy claim improved ability to separate severe adhesions between thoracic viscera and the hernia sack [14]. Those in favour of laparotomy believe it to be superior for the recognition and management of malrotation and for dealing with visceral complications such as obstruction

or strangulation[3]. In our case report, both thoracotomy and laparotomy were performed. Separation of severe adhesions, repair of diaphragmatic defects, and diagnosis of hypoplastic lung were achieved via thoracotomy. Moreover, reducing intestinal organs into the peritoneal cavity, diagnosis of partial situs inversus, and repairing diaphragmatic defects were achieved via laparotomy. Laparoscopic or thoracoscopic methods may be useful in selected BH patients. However, the amount of intestinal herniated organs into the thoracic cavity and the considered adhesions prompted us to perform open surgery.

The size of BH ranges widely from less than 1 cm to almost complete agenesis of the hemidiaphragm. It was 6 cm in the presented case. Extensive defects may not be repaired with primary suturation. Non-absorbable or absorbable prosthetic materials may be needed to achieve durable repair. We used prolene mesh for propping the diaphragmatic repair of sutures into the thoracic side of the diaphragm. We did not use prolene mesh propping for the abdominal side of the diaphragm to avoid causing intestinal adhesions and bridges.

Situs inversus viscerum is a rare autosomal recessive congenital defect in which the position of abdominal and/or thoracic organs is a mirror image of the normal position, in the sagittal plain.

If undetected, this condition can create a diagnostic puzzle. Situs inversus viscerum can be either total or partial. Situs inversus usually remains undiagnosed, as in our case, unless it is diagnosed accidentally while investigating another associated ailment. There are no previous reports about relationships between partial situs inversus and BH. It might be a protective condition for visceral complications such as strangulation and obstruction.

Adult presentation of a BH with concomitant partial situs inversus is a rare clinical entity. The current treatment of a BH is surgical repair, even in asymptomatic cases, because of the risk of visceral herniation and strangulation. Thoracotomy is the preferred technique for separating severe adhesions between abdominal and thoracic organs. On the other hand, laparotomy is the preferred technique for reduction and for dealing with visceral complications. Diaphragmatic defect repairing can be achieved by thoracotomy or laparotomy. In conclu-

sion, we believe that the presence of partial situs inversus protects herniated contents from strangulations and intestinal obstructions, and the possibility of its presence should be recognized by surgeons and anatomists.

REFERENCES

- Ahrend TR, Thompson BW (1971) Hernia of the foramen of Bochdalek in the adult. *Am J Surg*, 122: 612–615.
- Fine R, Borrero E, Stone A (1987) Bochdalek hernia in adulthood. *NY State J Med*, 87: 516–518.
- Fingerhut A, Baillet P, Oberlin P, Ronat R (1984) More on congenital diaphragmatic hernia in the adult (letter). *Int Surg*, 69: 182–183.
- Fisher JC, Haley MJ, Ruiz-Elizalde A, Stolar CJ, Arkovitz MS (2009) Multivariate model for predicting recurrence in congenital diaphragmatic hernia. *J Pediatr Surg*, 44: 1173–1179.
- Haller JA (1986) Professor Bochdalek and his hernia: then and now. *Prog Pediatr Surg*, 20: 252–255.
- Jandus P, Savioz D, Purek L, Frey JG, Schnyder JM, Tschopp JM (2009) Bochdalek hernia: a rare cause of dyspnea and abdominal pain in adults. *Rev Med Suisse*, 5:1061–1064.
- Losanoff JE, Sauter ER (2004) Congenital posterolateral diaphragmatic hernia in an adult. *Hernia*, 8: 83–85.
- MarFan MJ, Coulson ML, Siu SK (1999) Adult incarcerated right-sided Bochdalek hernia. *Aust NZ J Surg*, 69: 239–241.
- Mullins ME, Saini S (2005) Imaging of incidental Bochdalek hernia. *Semin Ultrasound CT MR*, 26: 28–36.
- Nouheim KS (1998) Adult presentation of unusual diaphragmatic hernias. *Chest Surg Clin N Am*, 8: 359–369.
- Rout S, Foo FJ, Hayden JD, Guthrie A, Smith AM (2007) Right-sided Bochdalek hernia obstructing in an adult: case report and review of the literature. *Hernia*, 11: 359–362.
- Salacin S, Alper B, Cekin N, Gulmen MK (1994) Bochdalek hernia in adulthood: a review and an autopsy case report. *J Forensic Sci*, 39: 1112–1116.
- Shields TW, MD (2005) *General Thoracic Surgery*. 6th ed. Lippincott Williams and Wilkins, Philadelphia, pp. 761–762.
- Sugg WL, Roper CL, Carlsson E (1964) Incarcerated Bochdalek hernias in the adult. *Ann Surg*, 160: 847–851.
- Swain JM, Klaus A, Achem SR, Hinder RA (2001) Congenital diaphragmatic hernia in adults. *Semin Laparosc Surg*, 8: 246–255.
- Yamaguchi M, Kuwano H, Hashizume M, Sugio K, Sugimachi K, Hyoudou Y (2002) Thorascopic treatment of Bochdalek hernia in the adult: report of a case. *Ann Thorac Cardiovasc Surg*, 8: 106–108.
- Wiseman NE, MacPherson RI (1997) “Acquired” congenital diaphragmatic hernia. *J Pediatr Surg*, 12: 657.