



## Bone cement implantation syndrome

A. J. Donaldson<sup>1</sup>, H. E. Thomson<sup>1</sup>, N. J. Harper<sup>2\*</sup> and N. W. Kenny<sup>3</sup>

<sup>1</sup>Department of Anaesthesia, University Hospital of South Manchester, Southmoor Road, Manchester M23 9LT, UK. <sup>2</sup>Department of Anaesthesia and <sup>3</sup>Department of Orthopaedic Surgery, Manchester Royal Infirmary, Oxford Rd, Manchester M13 9WL, UK

\*Corresponding author. E-mail: nigel.harper@manchester.ac.uk

Bone cement implantation syndrome (BCIS) is poorly understood. It is an important cause of intraoperative mortality and morbidity in patients undergoing cemented hip arthroplasty and may also be seen in the postoperative period in a milder form causing hypoxia and confusion. Hip arthroplasty is becoming more common in an ageing population. The older patient may have co-existing pathologies which can increase the likelihood of developing BCIS. This article reviews the definition, incidence, clinical features, risk factors, aetiology, pathophysiology, risk reduction, and management of BCIS. It is possible to identify high risk groups of patients in which avoidable morbidity and mortality may be minimized by surgical selection for uncemented arthroplasty. Invasive anaesthetic monitoring should be considered during cemented arthroplasty in high risk patients.

*Br J Anaesth* 2009; **102**: 12–22

**Keywords:** complications, death; complications, embolism; complications, hypotension; complications, hypoxia; surgery, orthopaedic

There is no peer-reviewed summary of bone cement implantation syndrome (BCIS) in the current anaesthetic literature. There is no widely accepted definition and there is a paucity of recommendations for the avoidance and management of this syndrome. This article draws together all the published literature. The authors propose a definition of BCIS and a classification according to clinical severity. We explore the putative mechanisms and highlight the groups of patients who are at particularly high risk of developing the syndrome, allowing for risk-stratification and appropriate modification of the anaesthetic technique.

### Background

BCIS is a significant cause of morbidity and mortality in patients undergoing cemented hip arthroplasty. According to the 2007 Annual Report of the National Joint Registry for England and Wales, more than 60 000 hip replacements are performed each year in England and Wales; approximately 65% occur in NHS hospitals.<sup>44</sup> The most common indication for total hip replacement (THR) is disabling arthritis. THR and hemiarthroplasty are also performed for femoral fracture, either as a primary procedure (1%) or in the management of failed internal fixation (1%).<sup>44</sup> More than two-thirds of THR operations are performed in patients >65 years old and women outnumber men two to

one.<sup>43 44</sup> There has been an increase in the number of ASA II and III patients undergoing a THR in recent years.<sup>44</sup>

Hip arthroplasties may be cemented, uncemented or hybrid. In England and Wales ~30% of THRs are currently uncemented.<sup>44</sup> Although the proportion of uncemented procedures appears to have increased in recent years,<sup>44 57</sup> cemented THR is unlikely to be completely supplanted by uncemented arthroplasty. Between April 2006 and March 2007, the average reported length of stay was 9.8 days for a cemented primary THR, and 8.6 days for an uncemented procedure.<sup>44</sup> The mortality after cemented and uncemented primary THR was 2.3% and 1.6%, respectively.<sup>44</sup> The greater mean age of patients receiving a cemented THR may contribute to the longer hospital stay and the greater mortality rate. Data from the National Joint Registry indicate that the requirement for revision in the first 3 years is higher in uncemented procedures (1.9% and 0.9%, respectively).<sup>44</sup>

The average cost of a THR to the NHS was £3686 in 2000.<sup>43</sup> The 2007–8 NHS payment by results tariff was £5305 for an elective cemented primary hip replacement, and £5901 for an uncemented procedure.<sup>12</sup>

The 2000–3 National Institute for Health and Clinical Excellence (NICE) guidelines on primary total hip replacement recommended that cemented prostheses should be used for THR. The guidelines noted that cemented prosthesis have better long-term viability, that there are no cost effective data to support the use of generally more costly

uncemented and hybrid hip prosthesis and that there was no reliable evidence to support the proposition that potential ease of revision (for uncemented or hybrid devices) would outweigh the poorer revision rate.<sup>43</sup> In 2003 it was estimated that a potential saving to the NHS of £8 million could be achieved if cemented prostheses were used in place of uncemented prostheses at the time of the NICE guidelines.<sup>43</sup> Increasing uptake of uncemented or hybrid prostheses would suggest this figure may now be higher. NICE makes no comment on the relative safety of cemented vs uncemented prostheses.

## Search strategy

In the preparation of this review, articles were identified using a Medline search for the phrases; bone cement, bone cement implantation syndrome, arthroplasty, hip replacement, complications, methyl methacrylate (MMA), and monomer. Further relevant references were identified from found articles. All original articles were read, and full text was obtained for all articles. All randomized controlled trials, observational studies, and case series found in the search were included.

## Definition

BCIS has no agreed definition; it is characterized by a number of clinical features that may include hypoxia,<sup>26 39 69</sup> hypotension,<sup>39 69 70</sup> cardiac arrhythmias,<sup>50</sup> increased pulmonary vascular resistance (PVR),<sup>5 34 50 67 70</sup> and cardiac arrest.<sup>5 13 45 50 53 59 61</sup> It is most commonly associated with, but is not restricted to, hip arthroplasty. It usually occurs at one of the five stages in the surgical procedure; femoral reaming, acetabular or femoral cement implantation, insertion of the prosthesis<sup>26 39 50 53 56 70</sup> or joint reduction.<sup>50</sup>

## Proposed definition of bone cement implantation syndrome

BCIS is characterized by hypoxia, hypotension or both and/or unexpected loss of consciousness occurring around the time of cementation, prosthesis insertion, reduction of the joint or, occasionally, limb tourniquet deflation in a patient undergoing cemented bone surgery.

## Proposed severity classification of bone cement implantation syndrome

- Grade 1: moderate hypoxia ( $Sp_{O_2} < 94\%$ ) or hypotension [fall in systolic blood pressure (SBP)  $> 20\%$ ].
- Grade 2: severe hypoxia ( $Sp_{O_2} < 88\%$ ) or hypotension (fall in SBP  $> 40\%$ ) or unexpected loss of consciousness.
- Grade 3: cardiovascular collapse requiring CPR.

## Incidence

The descriptions of adverse clinical events attributed to BCIS vary so widely in the published literature that it is not possible to draw any meaningful conclusions concerning the true incidence of complications, such as hypotension and oxygen desaturation.

Case reports generally identify fatalities and lesser degrees of BCIS are probably under-reported in the literature. The lack of a standard definition for BCIS goes against accurate reporting. In a study of 48 patients undergoing elective cemented THR, one patient (2%) suffered significant hypotension ( $> 30\%$  reduction in SBP) and eight patients (17%) developed significant desaturation (reduction in oxygen saturation  $> 5\%$ ).<sup>31</sup> Long-stem hip arthroplasty appears to be associated with a higher incidence of BCIS (*vide infra*). A study of 55 patients undergoing cemented long-stem hip arthroplasty (the indication for the use of a long-stem component was metastatic disease in 40 patients, and a revision procedure in 15 patients) demonstrated cement-associated hypotension [mean arterial pressure (MAP)  $< 70$  mm Hg, or reduction in MAP  $> 15$  mm Hg] in 38% of patients and oxygen desaturation in 25%.<sup>23</sup>

The true incidence of cardiac arrest secondary to BCIS is unknown, and mortality data are not systematically collected or published. There are only three large case reviews of operative mortality during cemented THR (1684, 15 211, and 11 655 patients)<sup>10 15 50</sup> (Table 1). Data from these three studies suggest the incidence of intraoperative mortality during cemented THR is 0.11% (95% CI: 0.07–0.15). Two of these studies also looked at intraoperative mortality in uncemented THR or hemiarthroplasty. There were no intraoperative deaths during uncemented THR (6684 and 11 011 patients)<sup>15 50</sup> or uncemented hemiarthroplasty (4400 patients)<sup>50</sup> in these studies.

The largest study, which looked at 38 488 hip arthroplasties, was published in 1999 and reported 23 intraoperative deaths in 23 077 patients receiving a cemented arthroplasty. Eleven deaths were reported in 11 655 cemented total hip arthroplasties, and 12 occurred during 2814 cemented hemiarthroplasties. All the deaths were because of cardio-respiratory problems during cementation. There were no intraoperative deaths in 15 411 uncemented arthroplasties undertaken during the same period.<sup>50</sup>

Similar results were reported in a review of 21 895 patients undergoing a total hip arthroplasty. There were 19 intraoperative deaths from BCIS in 15 211 patients who underwent a cemented THR and none in 6684 patients who underwent an uncemented THR procedure. All the deaths occurred around the time of cementation.<sup>15</sup>

The intraoperative mortality for cemented hemiarthroplasty was 0.43% (95% CI: 0.19–0.67); this group includes patients with and without femoral fractures.<sup>50</sup> If the procedure is undertaken to repair a fracture, the type of fracture greatly affects the outcome; the reported

**Table 1** Intraoperative mortality during total hip replacement. Data expressed as percentage, (95% confidence interval) and (number of deaths/total number of patients). \*Authors do not specify if procedures were elective or emergency cases. †Authors do not specify if procedures were elective or emergency cases. Group includes patients with and without femoral fractures

	Coventry <i>et al.</i> <sup>10</sup> (1974)	Ereth <i>et al.</i> <sup>15</sup> (1992)	Parvizi <i>et al.</i> <sup>50</sup> (1999)
Uncemented THR		0%* (0/6684)	0%† (0/11 011)
Cemented THR	0.06%* (0.18) (1/1684)	0.12%* (0.06–0.18) (19/15 211)	0.09%† (0.04–0.14) (11/11 655)
Cemented THR (no fracture)*			0.06% (0.01–0.11) (5/8036)
Cemented THR (non-pathological fracture)*			0.14% (0.02–0.26) (5/3473)
Cemented THR (pathological fracture)*			0.68% (0–2.01) (1/146)

**Table 2** Intraoperative mortality during hemiarthroplasty. Data expressed as percentage, (95% confidence interval) and (number of deaths/total number of patients). \*Authors did not state whether the procedures were elective or emergency cases. †Authors do not specify if procedures were elective or emergency cases. Group includes patients with and without femoral fractures. ‡Authors stated that around 400 long-stem hip arthroplasties were performed in the study period

	Patterson <i>et al.</i> <sup>51</sup> (1991)	Parvizi <i>et al.</i> <sup>50</sup> (1999)
Uncemented hemiarthroplasty†		0% (0/4400)
Cemented hemiarthroplasty (no fracture)*		0% (0/466)
Cemented hemiarthroplasty for non-pathological fracture*		0.4% (0.14–0.66) (9/2278)
Cemented hemiarthroplasty for pathological fracture*		4.3% (0–9.05) (3/70)
Cemented arthroplasty (THR and hemiarthroplasty) for intracapsular fracture*		0.2% (0.05–0.35) (7/3458)
Cemented arthroplasty (THR and hemiarthroplasty) for intertrochanteric fracture*		1.6% (0.69–2.51) (11/706)
Cemented arthroplasty with a long-stem femoral component*	~1% (0.02–1.98) (4/~400‡)	
(Indications the use of a long-stem prosthesis were fractures in three and fracture non-union in one patient)		

intraoperative mortality rate is 0.2%, 1.6%, and 4.3% for intracapsular fracture, intertrochanteric fracture, and pathological fracture, respectively<sup>50</sup> (Table 2).

Although primarily a problem associated with hip replacement, BCIS has also been described during other cemented procedures including knee arthroplasty<sup>5 46</sup> and vertebroplasty.<sup>8 68</sup>

## Clinical features

BCIS has a wide spectrum of severity. Many patients undergoing cemented hip arthroplasty develop non-fulminant BCIS characterized by a significant, transient reduction in arterial oxygen saturation,<sup>19 26 39 50 59 70</sup> and systemic blood pressure<sup>13 34 39 50 59 67 70</sup> in the peri-mentation period. A smaller proportion of patients develop fulminant BCIS resulting in profound intraoperative cardiovascular changes, which may proceed to arrhythmias,<sup>50</sup> shock or cardiac arrest.<sup>5 13 45 50 53 59 61</sup>

BCIS invariably results in reduced arterial oxygenation.<sup>26 50 59 70</sup> The cardiovascular changes are more variable. The MAP may be reduced.<sup>39 50 59</sup> Reduction in stroke volume (SV)<sup>9 15 70</sup> and cardiac output (CO) have been widely described.<sup>9 15 50 70</sup> The systemic vascular resistance (SVR) may be reduced<sup>70</sup> or increased.<sup>15</sup> The PVR<sup>5 34 50 67 70</sup> and pulmonary artery pressure (PAP) may be increased<sup>15 59 67 70</sup> and the right-ventricular ejection fraction may be impaired.<sup>67</sup> The effects on the pulmonary vasculature are usually transient<sup>3 6</sup> but may persist for up to 48 h after operation.<sup>5</sup>

It is believed that the increased PVR causes a reduced right-ventricular ejection fraction, the compliant right ventricle (RV) distends and causes the interventricular septum

to bulge into the left ventricle (LV), further reducing LV filling, and therefore CO.<sup>67</sup>

It has been suggested that embolization of femoral canal contents to the cerebral circulation either through a patent foramen ovale or after transit through the pulmonary circulation<sup>63</sup> may cause postoperative delirium.<sup>3 6 63</sup> Transcranial Doppler ultrasonography demonstrated cerebral emboli in 40–60% of patients undergoing joint arthroplasty in two small studies but none of these patients developed delirium or a focal neurological deficit.<sup>14 63</sup>

A case report published in 2004 describes a patient who developed BCIS during hemiarthroplasty for a femoral fracture. She suffered an intraoperative cardiac arrest from which she was resuscitated. Unfortunately, she never regained consciousness and remained in a persistent vegetative state. Serial magnetic resonance imaging (MRI) scans were suggestive of multiple cerebral fat emboli.<sup>59</sup> A second case report describes a patient who underwent an uneventful elective total hip arthroplasty but developed marked obtundation postoperatively. MRI scans suggested cerebral fat emboli.<sup>47</sup> A small study of patients undergoing tibial surgery showed serum astroglial S-100B protein concentration (a marker of cerebral injury) was significantly increased in the group who underwent a cemented procedure compared with those who had an uncemented procedure although no neurological sequelae were detected on serial postoperative assessments.<sup>30</sup>

## Aetiology and pathophysiology

The aetiology and pathophysiology of BCIS are not fully understood. Several mechanisms have been proposed.

**Table 3** Mean and peak intramedullary pressures generated during cementation and prosthesis insertion in vented and unvented femurs

	Finger packing		Cement gun	
	Peak pressure (mean, mm Hg)	Mean pressure (mean, mm Hg)	Peak pressure (mean, mm Hg)	Mean pressure (mean, mm Hg)
Unvented femur Cementation <sup>35</sup>	608	127	1177	322
Unvented femur (cadaveric studies) Cementation <sup>35</sup>	881	229	2051	374
Prosthesis insertion <sup>35</sup>	4931	3140	5003	3008
Vented femur Cementation <sup>65</sup>	>117			
Prosthesis insertion <sup>65</sup>	>190			

Initial theories focused on the release into the circulation of MMA cement monomer during cementation. More recent research has investigated the role of emboli formed during cementing and prosthesis insertion. Several mechanisms such as histamine release,<sup>66</sup> complement activation,<sup>34</sup> and endogenous cannabinoid-mediated vasodilatation have also been proposed.<sup>41</sup>

#### Monomer-mediated model

It has been demonstrated that circulating MMA monomers cause vasodilatation *in vitro*.<sup>28 52</sup> This hypothesis is not supported *in vivo* in a number of animal studies that have shown that the plasma MMA concentration after cemented hip arthroplasty is considerably lower than the concentration required to cause pulmonary<sup>36</sup> or cardiovascular effects.<sup>39 40 45</sup> Consequently, it has been suggested that the haemodynamic changes observed in BCIS are the result of an increase in intramedullary pressure at cementation leading to embolization, rather than a direct action of the monomer on the cardiovascular system.<sup>45</sup>

#### Embolic model

Recent research has focused on the role of embolization in BCIS. Embolic showers have been detected using echocardiography in the right atrium,<sup>8 15 31</sup> RV,<sup>8 31 42</sup> and pulmonary artery<sup>32</sup> during surgery. Post-mortem studies have demonstrated pulmonary embolization in animals<sup>27 45</sup> and man.<sup>29 50 53</sup> The physiological consequences of embolization are considered to be the result of both a mechanical effect<sup>3 45</sup> and mediator release,<sup>3 70</sup> which provokes increased pulmonary vascular tone.<sup>3 32</sup> It has been demonstrated that this debris includes fat,<sup>5 22 39 45 50 53</sup> marrow,<sup>5 39 45 50 53</sup> cement particles,<sup>50</sup> air,<sup>24 37</sup> bone particles,<sup>21</sup> and aggregates of platelets and fibrin.<sup>39</sup>

#### Mechanism of emboli formation

Embolization occurs as a result of high intramedullary pressures developing during cementation and prosthesis insertion.<sup>45</sup> The cement undergoes an exothermic reaction<sup>18</sup> and expands in the space between the prosthesis and bone, trapping air and medullary contents under pressure

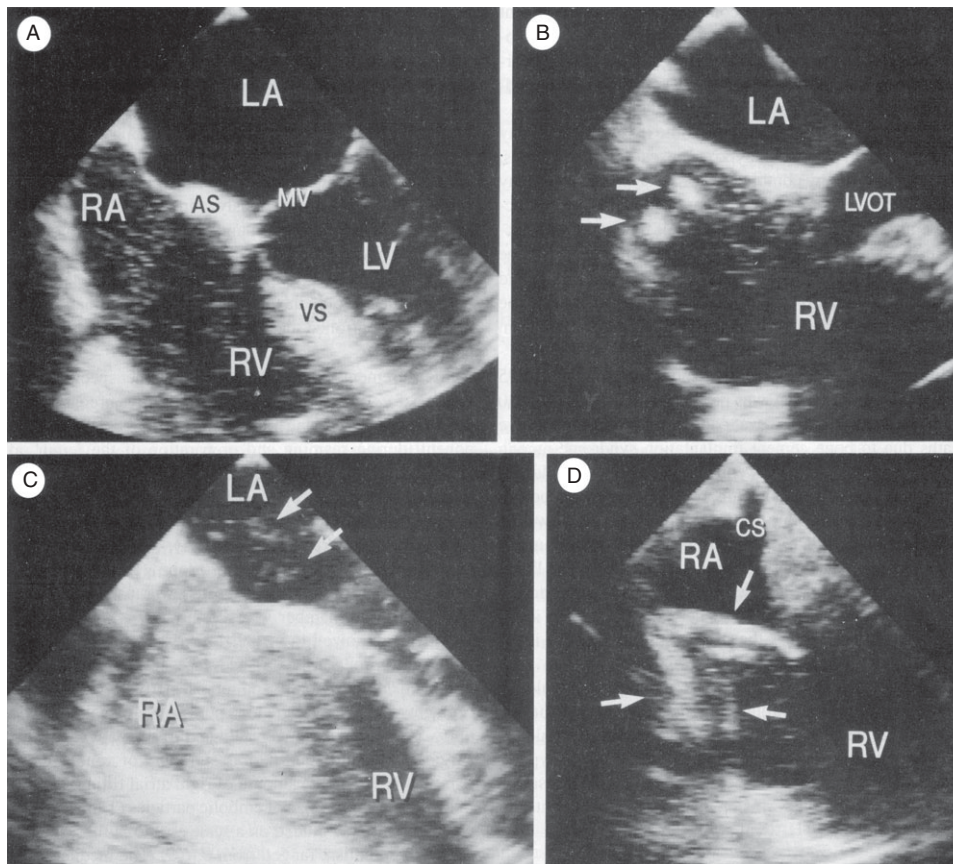
so that they are forced into the circulation.<sup>37 45</sup> The temperature of the cement can increase as high as 96°C 6 min after mixing the components.<sup>18</sup>

Cementation is achieved either with a cement gun or by manually packing the femoral canal. Regardless of the method of cementation, prosthesis insertion into the cemented femur is associated with a considerably greater pressure than cementation alone. When cement is inserted into the femur using a cement gun, the pressures generated are almost double those seen when manual packing is used (Table 3). Unfortunately, the single study in patients where a hole was drilled into the femur as a vent was flawed because some of the pressures generated exceeded the calibration range of their measuring equipment.<sup>65</sup>

#### Transoesophageal echocardiography

Several workers have demonstrated emboli in the heart using transoesophageal echocardiography (TOE) and these vary greatly in size and number (Fig. 1). In one patient, these were reported to be up to 5 cm in length.<sup>32</sup> A study of patients undergoing cemented arthroplasty demonstrated emboli in 47 out of the 48 patients. The authors described the appearance of multiple small emboli as a 'snow flurry'. Emboli greater than 10 mm were demonstrable in approximately one-third of patients in the study.<sup>31</sup>

TOE has demonstrated that the embolic load is greater in cemented compared with uncemented hip arthroplasty.<sup>15</sup> These findings were confirmed in a small study that observed emboli on TOE in all seven patients undergoing cemented and uncemented total hip arthroplasties. 'Snow flurries' were visible on TOE intermittently from the start of reaming until the end of the surgical procedure in both cemented and uncemented arthroplasty. In the cemented group, these were most marked during reaming of both the femur and acetabulum, and during insertion of the femoral component and reduction of the hip joint. In the group undergoing uncemented arthroplasty, the incidence and duration of the flurries did not increase at any specific point during the procedure. Cardio-respiratory variables were minimally changed during these episodes.<sup>21</sup>



**Fig 1** Four chamber TOE views showing embolism during total hip arthroplasty. (A) Small emboli (<5 mm) filling less than half of the right atrium. (B) Medium-sized emboli (5–10 mm, arrowed) and small emboli filling more than half of the right atrium. (C) Small emboli (<5 mm) completely filling the right atrium, multiple paradoxical emboli in left atrium. (D) Large emboli (>10 mm) in the right atrium with delayed passage at the tricuspid valve. AS, atrial septum; CS, coronary sinus; LA, left atrium; LV, left ventricle; LVOT, left ventricular outflow tract; MV, mitral valve; RA, right atrium; RV, right ventricle; VS, ventricular septum. Reproduced from *Mayo Clinic Proc*<sup>15</sup> with permission.

#### *Evidence of emboli at autopsy*

A study in dogs demonstrated the presence of fat and marrow in the pulmonary microvasculature at post-mortem after both cemented and uncemented arthroplasty. The dogs with a cemented procedure had a more than 10-fold increase in the number of emboli seen at autopsy compared with those in the uncemented group.<sup>45</sup> A more recent animal study demonstrated that medullary lavage before cemented arthroplasty significantly reduced the number of emboli seen post-mortem in dogs ( $P < 0.0005$ ).<sup>70</sup>

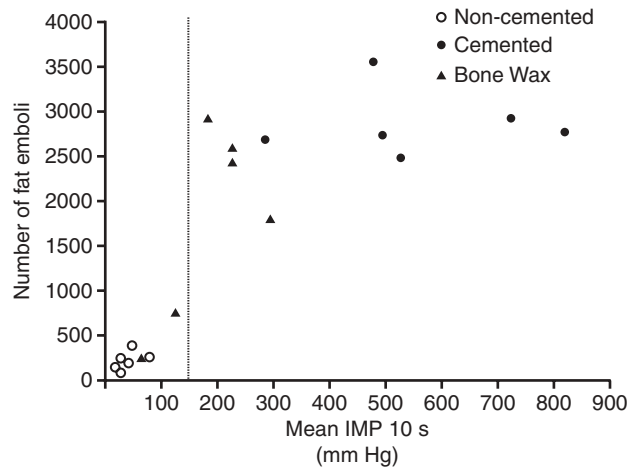
Post-mortem examinations performed after intraoperative deaths during cemented arthroplasty also confirm the presence of marrow,<sup>5 29 50 53 61</sup> fat,<sup>5 50 53 61</sup> bone emboli,<sup>61</sup> and MMA microparticles<sup>50</sup> in the lungs. Fat emboli have also been demonstrated post-mortem in the brain, kidneys, and myocardium of a patient who had a cardiac arrest during insertion of the femoral prosthesis.<sup>61</sup>

#### *The link between intramedullary pressure and embolization*

When a cemented prosthesis is being used, the cement is pressurized intentionally to force it into the interstices of

the bone. This achieves improved bonding between the cement and bone by increasing the contact surface area. Uncemented arthroplasty is associated with lower intramedullary pressure, fewer emboli, and less severe haemodynamic changes.<sup>15 45</sup> The degree of embolization may be related to the peak pressure generated in the femoral canal.<sup>45</sup> The mechanics of emboli formation were investigated in a study in which cemented and uncemented surrogate femoral prostheses were implanted into anaesthetized dogs. The peak intramedullary pressure and the number of pulmonary emboli found at post-mortem examination were significantly greater in the cemented group. When bone wax was inserted into the femur instead of cement to generate raised intramedullary pressures with a non-volatile substance, the observed embolic load and the cardiovascular changes remained significantly higher than those observed in the uncemented group.<sup>45</sup>

The dogs in the cemented and bone wax groups showed an increase in pulmonary shunt fraction, an increased mean pulmonary arterial pressure and a significant reduction in arterial partial pressure of oxygen ( $Pa_{O_2}$ ) compared with the control value during the 60 min observation



**Fig 2** Number of fat emboli in the lungs (area of 1200 mm<sup>2</sup>) and the maximum mean intramedullary pressure (IMP) over a 10-s interval. Reproduced with permission from Waddell and Byrick.<sup>45</sup>

period. No significant changes in  $Pa_{O_2}$  were seen in the group undergoing a non-cemented procedure.<sup>45</sup>

These observations suggest that high intramedullary pressure *per se* is an important factor in the genesis of BCIS.<sup>45</sup> Although the extent of embolization was proportional to the intramedullary pressure, there appeared to be a ceiling effect; this phenomenon has been attributed to a finite amount of debris being present in the femoral canal (Fig. 2).

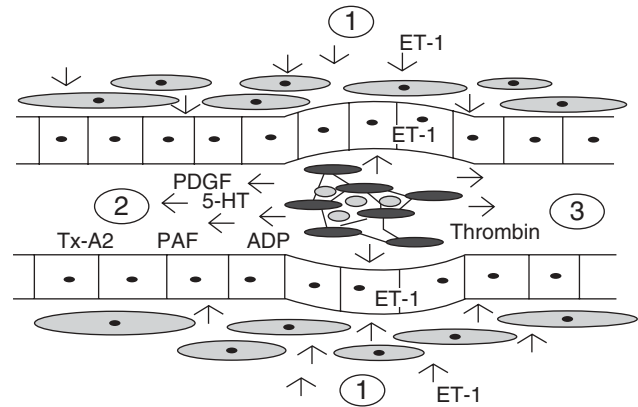
#### The haemodynamic effects of embolization

The debris from the medulla can embolize to the lungs, heart<sup>15</sup> or paradoxically to the cerebral<sup>6 15</sup> and coronary circulations.<sup>6</sup> It is thought that showers of pulmonary emboli result in the characteristic hypoxia and right ventricular dysfunction leading to hypotension.<sup>70</sup> Studies show that the degree of cardiovascular compromise is not necessarily proportional to the degree of the embolic load.<sup>15 32</sup>

#### Mediator release from emboli

In addition to simple mechanical obstruction of the pulmonary circulation, there are several possible mechanisms by which emboli may result in an increase in PVR (Fig. 3). First, mechanical stimulation or damage of endothelium may result in reflex vasoconstriction or release of endothelial mediators. Second, it has been suggested that the embolic material may release vasoactive or pro-inflammatory substances that directly increase PVR, such as thrombin and tissue thromboplastin,<sup>39 40</sup> or act indirectly by promoting release of further mediators which increase PVR.<sup>15</sup>

Other mediators cause a reduction in SVR such as 6-keto PGF  $1\alpha$ <sup>7 70</sup> and tissue thromboplastin through release of secondary mediators such as adenine nucleotides.<sup>39</sup> Medullary lavage before insertion of the cement



**Fig 3** Pulmonary vessel with embolus comprising fat, platelets, fibrin, and marrow debris. (1) Reflex vasoconstriction and endothelial production of endothelin 1. (2) Release of vasoconstriction mediators; platelet derived growth factor (PDGF), serotonin (5-HT), thromboxane A2 (Tx-A2), platelet activating factor (PAF), adenosine diphosphate (ADP). (3) Vasoconstriction attributable to non-cellular components of embolus including thrombin.

significantly reduces the release of some of these mediators.<sup>70</sup> Mediator-induced vasoconstriction, in combination with the mechanical obstruction from emboli, causes shunting of blood that is the most likely cause of the hypoxaemia.

#### Problems with the embolic model

The embolic model has become the dominant hypothesis as the causative process in BCIS. However, embolization does not explain all of the observed phenomena. Embolization is not always associated with haemodynamic changes,<sup>15 21 31</sup> and the degree of embolism correlates poorly with the extent of hypotension or hypoxaemia.<sup>31 39</sup> Studies using TOE show that embolic events are common and most patients tolerate them well. One study found the emboli to be smaller than the diameter of the functional pulmonary gas exchange vessels (75  $\mu$ m compared with 150  $\mu$ m). The authors surmised that the small emboli would lodge in the terminal pulmonary vessels. The larger vessels that supply the functional gas exchange units are likely to be spared, maintaining a normal ventilation perfusion (V/Q) relationship. They failed to demonstrate V/Q mismatching 30 min after the insertion of the femoral prosthesis.<sup>15</sup>

Hypotension has been noted in patients where MMA cement has been used in circumstances in which significant embolism is unlikely, for example, percutaneous vertebroplasty.<sup>68</sup> Although micro-embolism may be a contributing factor in BCIS, it is probable that other mechanisms co-exist.

#### Histamine release and hypersensitivity

Anaphylaxis (Type 1 hypersensitivity) was implicated as a potential cause for a fatal case of BCIS in 1972.<sup>2</sup>

Anaphylaxis and BCIS share many similar clinical features. A significant increase in plasma histamine concentration in hypotensive patients undergoing cementation has been demonstrated.<sup>66</sup> It is unclear whether the histamine release is attributable to a direct effect of the cement monomer or through an IgE-mediated process. In a single study, blockade of histamine receptors with clemastin and cimetidine (H1 and H2 antagonists) appeared to impart a protective effect,<sup>66</sup> but these findings have not been reproduced in more recent studies.<sup>33 38</sup>

Contact hypersensitivity (Type 4 hypersensitivity) to MMA has been demonstrated in surgeons<sup>17</sup> and experimental animals.<sup>25</sup>

### Complement activation

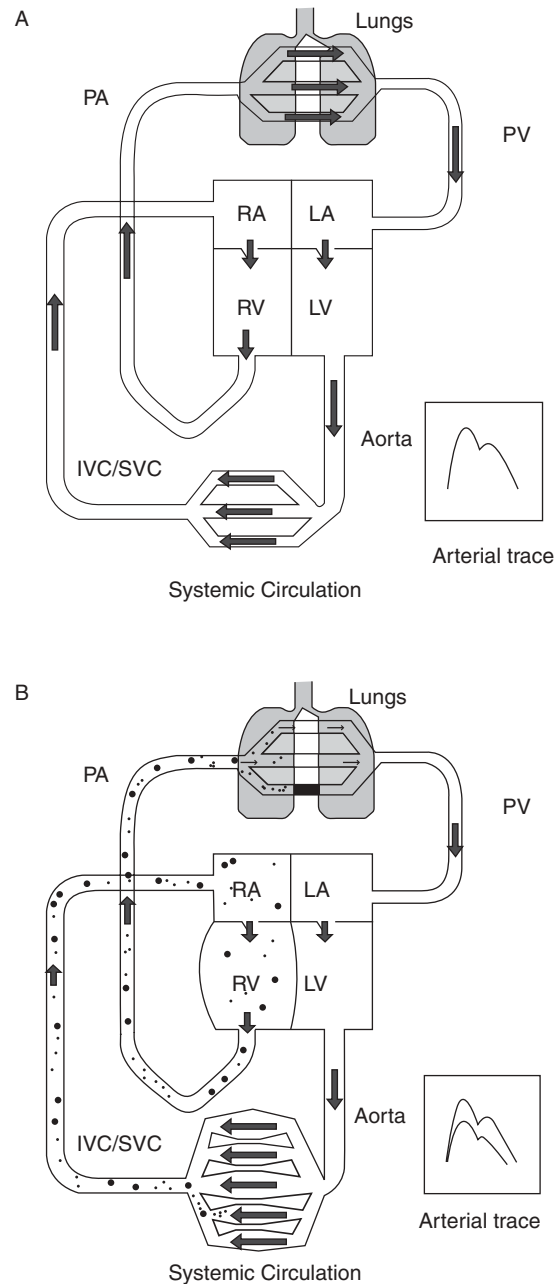
The anaphylatoxins C3a and C5a are potent mediators of vasoconstriction and bronchoconstriction.<sup>1</sup> An increase in C3a and C5a levels, suggesting activation of the complement pathway, has been demonstrated in cemented hemiarthroplasty but not in uncemented hemiarthroplasty.<sup>1</sup> High-dose methylprednisolone (2 g) was demonstrated to attenuate complement activation and hypoxia in a small randomized controlled, double-blinded study of patients undergoing a cemented arthroplasty. Methylprednisolone appeared to prevent the release of anaphylatoxins and the development of oxygen desaturation.<sup>19</sup> A more recent study failed to identify complement activation.<sup>34</sup>

### Multimodal model

It is likely that a combination of the above processes is present in any individual patient who develops BCIS. The extent to which each of these models contributes to the clinical features may depend upon the individual's physiological response. For example, there is significant inter-patient variability in the response to morphine-induced histamine release.<sup>58 71</sup> Several of the phenomena may have opposing actions and the combined effects of BCIS on haemodynamic variables will depend on the relative magnitude of the changes in PVR, SVR, and myocardial contractility. It is reasonable to assume that the patient's pre-existing co-morbidities may alter the clinical features of BCIS. It would be expected that a patient with pre-existing impaired right-ventricular function would be more susceptible to the effects of a sudden increase in PVR (Fig. 4).

### Patient risk factors

Numerous patient-related risk factors have been implicated in the genesis of BCIS including old age,<sup>50–52</sup> poor pre-existing physical reserve,<sup>23 51</sup> impaired cardiopulmonary function,<sup>23 50 52 53</sup> pre-existing pulmonary hypertension<sup>69</sup> osteoporosis,<sup>50 51</sup> bony metastases,<sup>3 23</sup> and concomitant hip fractures,<sup>50 51 53</sup> particularly pathological or intertrochanteric



**Fig 4** (A) Normal circulation, and (B) proposed combined model with peripheral vasodilatation, reduced venous return, increased pulmonary vascular resistance and pulmonary embolization, reduced cardiac output, reduced systemic vascular resistance (allowing some counter increase in cardiac output due to reduced afterload) and hypoxia from both the emboli and the pulmonary effects of histamine.

fractures.<sup>50</sup> These latter three factors are associated with increased<sup>3 23 50 51</sup> or abnormal<sup>23</sup> vascular channels through which marrow contents can migrate into the circulation. Patients with a patent foramen ovale or atrial-septal defect may be at increased risk of paradoxical emboli and neurological sequelae.

A retrospective analysis of the case notes of 55 consecutive patients undergoing cemented long-stem arthroplasty revealed that three patients suffered catastrophic

complications, two developed prolonged coma and one patient died. All three had metastatic disease and a previously un-instrumented femur.<sup>23</sup> Malignant tumours are associated with increased levels of pro-coagulants such as fibrinopeptide A that may also increase thromboembolism.<sup>54 55</sup>

The proportion of patients presenting for THR with co-morbidity has increased in recent years.<sup>44</sup> The National Joint Registry data for 2006 show that 14% of patients undergoing primary hip arthroplasty were ASA III, 1% were ASA IV, and 0.06% ( $n=32$ ) patients were ASA V.<sup>44</sup>

### Surgical risk factors

Patients with a previously un-instrumented femoral canal may be at higher risk of developing the syndrome than those undergoing revision surgery.<sup>23 51</sup> There are two possible mechanisms. First, there is more potentially embolic material present in an un-instrumented femur.<sup>23</sup> Second, once the canal has been instrumented and cemented, the inner surface of the femur becomes smooth and sclerotic and offers a less permeable surface.<sup>51</sup> The use of a long-stem femoral component increases the likelihood of developing BCIS.<sup>23 51</sup>

### Anaesthetic risk reduction

Joint arthroplasty is often carried out in patients with significant co-morbidity: 14% of patients undergoing primary hip arthroplasty in the NHS, and 26% of those undergoing a revision procedure have an ASA score of three or over.<sup>44</sup> The anaesthetic team should be fully involved in the pre-operative assessment of patients scheduled for joint arthroplasty, allowing for full investigation of co-morbidity and pre-optimization.<sup>2</sup> Particular attention should be paid to patients undergoing a cemented procedure with cardiac, respiratory or metastatic disease, patients with a femoral fracture and those having a long-stem prosthesis inserted.<sup>11 23 53</sup>

In high risk cases discussion should occur between the surgeon and anaesthetist regarding the most appropriate anaesthetic and surgical technique, including the potential risk-benefit of uncemented compared with cemented arthroplasty. A telephone survey of the 12 trauma centres in Wales in 2003 demonstrated that the decision concerning the choice of cemented or uncemented hemiarthroplasty was made after discussion between the anaesthetic and surgical team in only two centres. In a further two centres, the decision was influenced by the patient's age and mobility according to an agreed protocol.<sup>49</sup> In patients with a history of previous severe BCIS, avoidance of a further cemented procedure may be prudent.

The anaesthetic technique should be tailored to the individual patient and the type of prosthesis. Although there is no clear evidence regarding the impact of anaesthetic technique on the severity of BCIS, an animal study has

suggested that volatile anaesthetic agents may be associated with a greater haemodynamic change for the same embolic load.<sup>20</sup> In this study, isoflurane was compared with a high-dose fentanyl and diazepam technique that is unrepresentative of normal anaesthetic practice. The avoidance of nitrous oxide should be considered in high risk patients to avoid exacerbating air embolism.

Increasing the inspired oxygen concentration should be considered in all patients at the time of cementation,<sup>5 26</sup> especially in patients at increased risk of BCIS.<sup>23 51 53</sup> Avoiding intravascular volume depletion may reduce the extent of the haemodynamic changes in BCIS.<sup>23 26 34 50 52 53</sup>

A high level of haemodynamic monitoring should be considered in high risk patients.<sup>5 50 51 53</sup> Central venous pressure (CVP) monitoring will aid volume optimization and inotrope administration but changes in CVP may correlate especially poorly with changes in PAP in BCIS.<sup>4 45</sup> An oesophageal Doppler study in 20 patients undergoing hip arthroplasty demonstrated a significant reduction in CO and stroke volume, neither of which was detected by standard haemodynamic monitoring.<sup>9</sup> The use of an intraoperative pulmonary artery catheter<sup>3 50 51</sup> or trans-oesophageal echocardiography<sup>3 15</sup> has been suggested in high risk patients.

In one institution, the analysis of seven intraoperative cardiac arrests during hemiarthroplasty led to the routine use of low-dose epinephrine infusion during cementing.<sup>51</sup>

We recommend that, in addition to standard anaesthetic monitoring, patients with one or more significant risk factors for developing BCIS (Table 4) should have a high level of perioperative vital signs monitoring. This should include invasive arterial pressure monitoring and a central venous catheter. Hypotension in BCIS may be the result of decreased SVR, reduced CO, or a combination of the two, and the authors consider that CO monitoring with an assessment of cardiac filling, CO, and SVR should be given serious consideration in patients at high risk of BCIS. This would allow for management to be directed more appropriately should BCIS develop.

### Surgical risk reduction

A retrospective analysis of intraoperative mortality in patients undergoing hip arthroplasty over a 28 year period showed a three-fold reduction ( $P<0.05$ ) in the intraoperative

**Table 4** Significant risk factors for developing BCIS

Pre-existing disease
Pre-existing pulmonary hypertension
Significant cardiac disease
New York Heart Association class 3 or 4
Canadian Heart Association class 3 or 4
Surgical factors
Pathological fracture
Inter-trochanteric fracture
Long-stem arthroplasty



mortality in the latter 9 years of the study. This was attributed to several modifications in the surgical and anaesthetic technique.<sup>50</sup>

A number of surgical measures may be undertaken to reduce the risk of BCIS. These include medullary lavage,<sup>4 22 23 53 62 64 70</sup> good haemostasis before cement insertion,<sup>23</sup> minimizing the length of the prosthesis,<sup>51</sup> using non-cemented prosthesis<sup>3 13 50 53</sup> (especially if using a long-stem implant),<sup>51</sup> and venting the medulla.<sup>3 22 23 26 50 53</sup> Venting the bone permits the air to escape from the end of the cement plug and reduces the risk of an air embolus. Unfortunately, drilling a hole in the cortical bone to create a pressure-relieving vent can increase the risk of femoral fracture.<sup>3 26 27</sup> The risk of fracture is greater if the size of the drill hole is greater than a critical diameter.

If cement is used, insertion with a cement gun<sup>16</sup> and retrograde insertion<sup>35</sup> have been suggested as ways of reducing the incidence of BCIS. Cement guns are being increasingly used in clinical practice, and result in more even pressure distribution in the medullary cavity,<sup>60</sup> and less reduction in oxygen saturation ( $P < 0.006$ ).<sup>35</sup> Paradoxically, it has been demonstrated that intramedullary pressures are higher when cementation is performed with a cement gun rather than finger packing.<sup>35</sup>

The method of preparation of bone cement is also relevant to BCIS. A study of 72 patients undergoing repair of femoral fracture demonstrated a complication rate (significant decrease in oxygen saturation and arterial pressure) of 11% in the patients whose cement was mixed in a partial vacuum, compared with 53% in the group in which the cement was mixed at atmospheric pressure. Mortality in the two groups was 2.8% and 13.8%, respectively.<sup>69</sup> Working the cement to remove the volatile vasodilatory compounds has also been recommended.<sup>52 53</sup> The 2006 British Orthopaedic Association Guide to Good Practice recommends a number of the above measures.<sup>2</sup>

## Management

Communication between the surgeon and the anaesthetist is important. In addition to the hazards of cement implantation and prosthesis insertion,<sup>39 50</sup> reduction of the prosthetic femoral head is also a time of increased risk because previously occluded vessels are re-opened and accumulated debris may be allowed into the circulation.<sup>50</sup><sup>67</sup> During knee arthroplasty, significant venous emboli are released at the time of tourniquet deflation and this may also be a high risk period.<sup>48</sup>

A fall in end tidal carbon dioxide concentration may be the first indication of clinically significant BCIS in the anaesthetized patient and should alert the anaesthetist. Oesophageal Doppler measurements may detect impending BCIS at an earlier stage than standard haemodynamic monitoring.<sup>9</sup> Early signs of BCIS in the awake patient

undergoing regional anaesthesia include dyspnoea<sup>13 14</sup> and altered sensorium.<sup>14 59</sup>

In the absence of clinical trials comparing different management approaches to BCIS, current recommendations are empiric and guided by case reports and basic physiological principles.

If BCIS is suspected, the inspired oxygen concentration should be increased to 100% and supplementary oxygen should be continued into the postoperative period. It has been suggested that cardiovascular collapse in the context of BCIS be treated as RV failure.<sup>3 53</sup> Aggressive resuscitation with i.v. fluids has been recommended.<sup>51 53</sup> Although CVP monitoring does not accurately reflect PAP,<sup>53</sup> a central venous catheter may be indicated for the administration of inotropic drugs. Opinion is divided as to the relative merits of a pure alpha adrenergic agonist<sup>29 70</sup> or a mixed alpha and beta receptor agonist.<sup>29 51 53 67</sup> The choice of vasopressor is facilitated by the presence of non-invasive CO monitoring or a pulmonary artery flotation catheter.

Haemodynamic instability should be treated with the potential aetiology in mind. Sympathetic  $\alpha_1$  agonists should be first-line agent in the context of right heart dysfunction and vasodilatation. Fluid resuscitation should then be commenced if there is insufficient pre-load.

## Summary

We have discussed the incidence and clinical features of BCIS and proposed a formal definition and severity classification. Our proposed classification system provides a structure for reporting cases of BCIS and may permit more accurate assessment of the incidence of BCIS in the future.

We have explored a number of theories of the underlying pathophysiology of BCIS, including the monomer-mediated model, the embolic model, and the histamine and complement-mediated models. We have postulated that, rather than one discrete mechanism, the true aetiology may encompass a combination of mechanisms, partly modified by the patient's own physiological response and pre-existing pathology.

Although cemented procedures are generally very safe, we have highlighted specific groups of patients who are particularly at risk of developing BCIS and we have made a number of suggestions to minimize this risk, including liaison with the surgeon regarding the type of prosthesis, generous intra-vascular fluid repletion, increased vigilance at the periods of highest risk, and invasive vital-signs monitoring. We suggest that a cemented prosthesis should be avoided in patients who are at high risk of BCIS unless there are overriding orthopaedic considerations. In addition, we have discussed the clinical management of a patient who develops BCIS with an emphasis on the use of direct acting alpha agonist drugs.

## Acknowledgements

The authors wish to thank Dr Erath, Dr Byrick, Professor Waddell, and the *Mayo Clinic Proc* for their kind permission to reproduce Figures 1 and 2.

## References

- Bengtson A, Larsson M, Gammer W, Heideman M. Anaphylatoxin release in association with methylmethacrylate fixation of hip prostheses. *J Bone Joint Surg* 1987; **69**: 46–9
- British Orthopaedic Association. Primary total hip replacement: a guide to good practice. 2006. Available from [www.boa.ac.uk/site/showpublications.aspx?ID=59](http://www.boa.ac.uk/site/showpublications.aspx?ID=59)
- Byrick RJ. Cement implantation syndrome: a time limited embolic phenomenon. *Can J Anaesth* 1997; **44**: 107–11
- Byrick RJ, Bell RS, Kay JC, Waddell JP, Mullen JB. High-volume high-pressure pulsatile lavage during cemented arthroplasty. *J Bone Joint Surg Am* 1989; **71**: 1331–6
- Byrick RJ, Forbes D, Waddell JP. A monitored cardiovascular collapse during cemented total knee replacement. *Anesthesiology* 1986; **65**: 213–6
- Byrick RJ, Mullen JB, Mazer CD, Guest CB. Transpulmonary systemic fat embolism. Studies in mongrel dogs after cemented arthroplasty. *Am J Respir Crit Care Med* 1994; **150**: 1416–22
- Byrick RJ, Mullen JB, Wong PY, Kay JC, Wigglesworth D, Doran RJ. Prostanoid production and pulmonary hypertension after fat embolism are not modified by methylprednisolone. *Can J Anesth* 1991; **38**: 660–7
- Chen HL, Wong CS, Ho ST, Chang FL, Hsu CH, Wu CT. A lethal pulmonary embolism during percutaneous vertebroplasty. *Anesth Analg* 2002; **95**: 1060–2
- Clark DI, Ahmed AB, Baxendale BR, Moran CG. Cardiac output during hemiarthroplasty of the hip. A prospective, controlled trial of cemented and uncemented prostheses. *J Bone Joint Surg* 2001; **83**: 414–8
- Coventry MB, Beckenbaugh RD, Nolan DR, Ilstrup DM. 2,012 total hip arthroplasties: a study of postoperative course and early complications. *J Bone Joint Surg* 1974; **56**: 273–84
- Deburge A, Guepar T. Guepar hinge prosthesis: complications and results with two years follow-up. *Clin Orthop Rel Res* 1976; **120**: 47–53
- Department of health payment by results: Tariff information 2007–2008. Available from [www.dh.gov.uk/en/Policyandguidance/Organisationpolicy/Financeandplanning/NHSFinancialReforms/DH\\_077279](http://www.dh.gov.uk/en/Policyandguidance/Organisationpolicy/Financeandplanning/NHSFinancialReforms/DH_077279)
- Duncan JAT. Intra-operative collapse or death related to the use of acrylic cement in hip surgery. *Anaesthesia* 1989; **44**: 149–53
- Edmonds CR, Barbut D, Hager D, Sharrock NE. Intraoperative cerebral arterial embolisation during total hip arthroplasty. *Anesthesiology* 2000; **93**: 315–8
- Erath MH, Weber JG, Abel MD, et al. Cemented versus noncemented total hip arthroplasty-embolism, haemodynamics and intrapulmonary shunting. *Mayo Clinic Proc* 1992; **67**: 1066–74
- Evans RD, Palazzo MG, Ackers JW. Air embolism during total hip replacement: comparison of two surgical techniques. *Br J Anaesth* 1989; **62**: 243–7
- Fries IB, Fisher AA, Salvati EA. Contact dermatitis in surgeons from methylmethacrylate bone cement. *J Bone Joint Surg* 1975; **57**: 547–8
- Frost PM. Cardiac arrest and bone cement. *Br Med J* 1970; **3**: 524
- Gammer W, Bengtson A, Heideman M. Inhibition of complement activation by high-dose corticosteroids in total hip arthroplasty. *Clin Orthop Relat Res* 1998; **236**: 205–9
- Guest CB, Byrick RJ, Mazer CD, Wigglesworth DF, Mullen JB, Tong JH. Choice of anaesthetic regimen influences haemodynamic response to cemented arthroplasty. *Can J Anesth* 1995; **42**: 928–36
- Hayakawa M, Fujioka Y, Morimoto Y, Okamura A, Kemmotsu O. Pathological evaluation of venous emboli during total hip arthroplasty. *Anaesthesia* 2001; **56**: 571–5
- Herndon JH, Bechtol CO, Crickenberger DP. Fat embolism during total hip replacement: a prospective study. *J Bone Joint Surg Am* 1974; **56**: 1350–62
- Herrenbruck T, Erickson EW, Damron TA, Heiner J. Adverse clinical events during cemented long-stem femoral arthroplasty. *Clin Orthop Relat Res* 2002; **395**: 154–63
- Hyland J, Robins RH. Cardiac arrest and bone cement. *Br Med J* 1970; **4**: 176–7
- Jensen JS, Trap B, Skydsgaard K. Delayed contact hypersensitivity and surgical glove penetration with acrylic bone cements. *Acta Orthop Scand* 1991; **62**: 24–8
- Kallos T. Impaired oxygenation associated with use of bone cement in the femoral shaft. *Anesthesiology* 1975; **42**: 210–5
- Kallos T, Enis JE, Gollan F, Davis JH. Intramedullary pressure and pulmonary embolism of femoral medullary contents in dogs during insertion of bone cement and a prosthesis. *J Bone Joint Surg Am* 1974; **56**: 1363–7
- Karlsson J, Wendling W, Chen D, et al. Methylmethacrylate monomer produces direct relaxation of vascular smooth muscle in vitro. *Acta Anaesthesiol Scand* 1995; **39**: 685–9
- Kepes ER, Underwood PS, Becsey L. Intra-operative death associated with acrylic bone cement. Report of Two Cases. *J Am Med Assoc* 1972; **222**: 576–7
- Kinoshita H, Iranami H, Fujii K, et al. The use of bone cement induces an increase in serum astroglial S-100B protein in patients undergoing total knee arthroplasty. *Anesth Analg* 2003; **97**: 1657–60
- Lafont ND, Kalonji MK, Barre J, Guillaume C, Boogaerts JG. Clinical features and echocardiography of embolism during cemented hip arthroplasty. *Can J Anesth* 1997; **44**: 112–7
- Lafont ND, Kostucki WM, Marchand PH, Michaux MN, Boogaerts JG. Embolism detected by transoesophageal echocardiography during hip arthroplasty. *Can J Anaesth* 1994; **41**: 850–3
- Lamade WR, Friedl W, Schmid B, Meeder PJ. Bone Cement Implantation Syndrome. A prospective randomised trial for the use of antihistamine blockade. *Arch Orthop Trauma Surg* 1995; **114**: 335–9
- Lewis RN. Some studies of the complement system during total hip replacement using bone cement under general anaesthesia. *Eur J Anaesth* 1997; **14**: 35–9
- McCaskie AW, Barnes MR, Lin E, Harper WM, Gregg PJ. Cement pressurization during hip replacement. *J Bone Joint Surg (Br)* 1997; **79**: 379–84
- McLaughlin RE, DiFazio CA, Hakala M, et al. Blood clearance and acute pulmonary toxicity of methylmethacrylate in dogs after simulated arthroplasty and intravenous injection. *J Bone Joint Surg* 1973; **55**: 1621–8
- Michel R. Air embolism in hip surgery. *Anaesthesia* 1980; **35**: 858–62
- Mitsuhashi H, Saitoh J, Saitoh K. Methylmethacrylate bone cement does not release histamine in patients undergoing prosthetic replacement of femoral head. *Br J Anaesth* 1994; **73**: 779–81
- Modig J, Busch C, Olerud S, Saldeen T, Waernbaum G. Arterial hypotension and hypoxaemia during total hip replacement: the

- importance of thromboplastic products, fat embolism and acrylic monomers. *Acta Anaesthesiol Scand* 1975; **19**: 28–43
- 40 Modig J, Busch C, Waernbaum G. Effects of graded infusion of monomethylmethacrylate on coagulation, blood lipids, respiration and circulation. *Clin Orthop Relat Res* 1975; **113**: 187–95
- 41 Motobe T, Hashiguchi T, Uchimura T, *et al.* Endogenous cannabinoids are candidates for lipid mediators of bone cement implantation syndrome. *Shock* 2004; **21**: 8–12
- 42 Murphy P, Byrick R, Edelist G, Kay C. Transesophageal echocardiographic changes associated with cemented arthroplasty. *Anesthesiology* 1994; **81**: A753
- 43 National Institute for Health and Clinical Excellence. Guidance on the selection of prosthesis for primary total hip replacement 2000/2003. Available from: [www.nice.org.uk](http://www.nice.org.uk)
- 44 National Joint Registry for England and Wales 4th Annual Report. Available from [www.njrcentre.org.uk](http://www.njrcentre.org.uk)
- 45 Orsini EC, Byrick RJ, Mullen JBM, Kay JC, Waddell JP. Cardiopulmonary function and pulmonary microemboli during arthroplasty using cemented or non-cemented components the role of intramedullary pressure. *J Bone Joint Surg* 1987; **69**: 822–32
- 46 Orsini EC, Richards RR, Mullen JM. Fatal fat embolism during cemented total knee arthroplasty: a case report. *Can J Surg* 1986; **29**: 385–6
- 47 Ott MC, Meschia JF, Macket DC, *et al.* Cerebral embolisation presenting as delayed, severe obtundation in the postanesthesia care unit after total hip arthroplasty. *Mayo Clinic Proc* 2000; **75**: 1209–13
- 48 Parmet JL, Horrow JC, Pharo G, Collins L, Berman AT, Rosenberg H. The incidence of venous emboli during extramedullary guided total knee arthroplasty. *Anesth Analg* 1995; **81**: 757–62
- 49 Parry G. Sudden deaths during hip hemi-arthroplasty. *Anaesthesia* 2003; **58**: 922–3
- 50 Parvizi J, Holliday AD, Ereth MH, Lewallen DG. Sudden death during primary hip arthroplasty. *Clin Orthop Relat Res* 1999; **369**: 39–48
- 51 Patterson B, Healey J, Cornell C, Sharrock N. Cardiac arrest during hip arthroplasty with a cemented long-stem component. A report of seven cases. *J Bone Joint Surg* 1991; **73**: 271–7
- 52 Peebles DJ, Ellis RH, Stride SDK, Simpson BRJ. Cardiovascular effects of methylmethacrylate cement. *Br Med J* 1972; **1**: 349–51
- 53 Pietak S, Holmes J, Matthews R, Petrasek A, Porter B. Cardiovascular collapse after femoral prosthesis surgery for acute hip fracture. *Can J Anesth* 1997; **44**: 198–201
- 54 Rickles FR, Edwards RL. Activation of blood coagulation in cancer: Trousseau's syndrome revisited. *Blood* 1983; **62**: 14–31
- 55 Rickles FR, Edwards RL, Barb C, Cronlund M. Abnormalities of blood coagulation in patient with cancer. Fibrinopeptide A generation and tumor growth. *Cancer* 1983; **51**: 301–7
- 56 Rinecker H. New clinico-pathophysiological studies on the bone cement implantation syndrome. *Arch Orthop Trauma Surg* 1980; **97**: 263–74
- 57 Roberts VI, Elser CN, Harper WM. What impact have NICE guidelines had on the trends of hip arthroplasty since their publication? The results from the Trent Regional Arthroplasty Study between 1990 and 2005. *J Bone Joint Surg Br* 2007; **89**: 864–7
- 58 Rosow CE, Moss J, Philbin DM, Savarese JJ. Histamine release during morphine and fentanyl anaesthesia. *Anesthesiology* 1982; **56**: 93–6
- 59 Sasano N, Ishida S, Tetsu S, *et al.* Cerebral fat embolism diagnosed by magnetic resonance imaging at one, eight and 50 days after hip arthroplasty: a case report. *Can J Anaesth* 2004; **51**: 875–9
- 60 Scott S, McCaskie AW, Calder SJ, Wildin C, Gregg PJ. Current cementing techniques in hip hemi-arthroplasty. *Injury* 2001; **32**: 461–4
- 61 Sevitt S. Fat embolism in patients with fractured hips. *Br Med J* 1972; **2**: 257–62
- 62 Sherman RMP, Byrick RJ, Kay JC, Sullivan TR, Waddell JP. The role of lavage in preventing haemodynamic and blood gas changes during cemented arthroplasty. *J Bone Joint Surg* 1983; **65**: 500–6
- 63 Sulek CA, Davies LK, Enneking FK, Gearen PA, Lobato EB. Cerebral microembolism diagnosed by transcranial Doppler during total knee arthroplasty. Correlation with transoesophageal echocardiography. *Anesthesiology* 1999; **91**: 672–6
- 64 The Swedish Hip Arthroplasty Registry. 2005. Available from [www.jru.orthop.gu.se](http://www.jru.orthop.gu.se)
- 65 Tronzo RG, Kallos T, Wyche MQ. Elevation of intramedullary pressure when methylmethacrylate is inserted in total hip arthroplasty. *J Bone Joint Surg Am* 1974; **56**: 714–8
- 66 Tryba M, Linde I, Voshage G, Zenz M. Histamine release and cardiovascular reactions to implantation of bone cement during total hip replacement. *Anaesthetist* 1991; **40**: 25–32
- 67 Urban MK, Sheppard R, Gordon MA, Urquhart BL. Right ventricular function during revision total hip arthroplasty. *Anesth Analg* 1996; **82**: 1225–9
- 68 Vasconcelos C, Gailloud P, Martin J-B, Murphy KJ. Transient arterial hypotension induced by polymethylmethacrylate injection during percutaneous vertebroplasty. *J Vasc Interv Radiol* 2001; **12**: 1001–2
- 69 Werner L. A response to 'Sudden deaths during hip hemi-arthroplasty'. *Anaesthesia* 2003; **58**: 922–3 Parry G. *Anaesthesia* 2004 Feb; **59**: 200
- 70 Wheelwright EF, Byrick RJ, Wigglesworth DF, *et al.* Hypotension during cemented arthroplasty. Relationship to cardiac output and fat embolism. *J Bone Joint Surg* 1993; **75**: 715–23
- 71 Withington DE, Patrick JA, Reynolds F. Histamine release by morphine and diamorphine in man. *Anaesthesia* 1993; **48**: 26–9