

## Bone Marrow Aspirate and Biopsy: A Pathologist's Perspective. II. Interpretation of the Bone Marrow Aspirate and Biopsy

Roger S. Riley,<sup>1\*</sup> David Williams,<sup>1</sup> Micaela Ross,<sup>2</sup> Shawn Zhao,<sup>3</sup> Alden Chesney,<sup>4</sup>  
Bradly D. Clark,<sup>5</sup> and Jonathan M. Ben-Ezra<sup>1</sup>

<sup>1</sup>Medical College of Virginia Hospitals of Virginia Commonwealth University, Richmond, Virginia

<sup>2</sup>Jewish Hospital, Cincinnati, Ohio

<sup>3</sup>Columbus Regional HealthCare System, Columbus, Georgia

<sup>4</sup>Sunnybrook Health Sciences Centre, Toronto, Ontario, Canada

<sup>5</sup>Memorial Sloan-Kettering Cancer Center, New York, New York

---

Bone marrow examination has become increasingly important for the diagnosis and treatment of hematologic and other illnesses. Morphologic evaluation of the bone marrow aspirate and biopsy has recently been supplemented by increasingly sophisticated ancillary assays, including immunocytochemistry, cytogenetic analysis, flow cytometry, and molecular assays. With our rapidly expanding knowledge of the clinical and biologic diversity of leukemia and other hematologic neoplasms, and an increasing variety of therapeutic options, the bone marrow examination has become more critical for therapeutic monitoring and planning optimal therapy. Sensitive molecular

techniques, in vitro drug sensitivity testing, and a number of other special assays are available to provide valuable data to assist these endeavors. Fortunately, improvements in bone marrow aspirate and needle technology has made the procurement of adequate specimens more reliable and efficient, while the use of conscious sedation has improved patient comfort. The procurement of bone marrow specimens was reviewed in the first part of this series. This paper specifically addresses the diagnostic interpretation of bone marrow specimens and the use of ancillary techniques. *J. Clin. Lab. Anal.* 23:259–307, 2009.

© 2009 Wiley-Liss, Inc.

**Key words:** bone marrow pathology; bone marrow examination; hematological diagnosis; immunohistochemistry; flow cytometry; cytochemistry; monoclonal antibodies; in situ hybridization; karyotyping

---

### INTRODUCTION

Bone marrow examination has become increasingly important for the diagnosis and treatment of hematologic and other illnesses. Morphologic evaluation of the bone marrow aspirate and biopsy has recently been supplemented by increasingly sophisticated ancillary assays, including immunocytochemistry, cytogenetic analysis, flow cytometry, and molecular assays. With our rapidly expanding knowledge of the clinical and biologic diversity of leukemia and other hematologic neoplasms, and an increasing variety of therapeutic options, the bone marrow examination has become more critical for therapeutic monitoring and planning optimal therapy. Sensitive molecular techniques, in vitro drug sensitivity testing, and a number of other special

assays are available to provide valuable data to assist these endeavors. Fortunately, improvements in bone marrow aspirate and needle technology has made the procurement of adequate specimens more reliable and efficient, while the use of conscious sedation has improved patient comfort. The procurement of bone marrow specimens was reviewed in the first part of this series. This paper specifically addresses the diagnostic interpretation of bone marrow specimens, including the

---

\*Correspondence to: Roger S. Riley, Medical College of Virginia Hospitals of Virginia Commonwealth University, Richmond, Virginia. E-mail: rsriley@vcu.edu

Received 30 December 2008; Accepted 19 February 2009

DOI 10.1002/jcla.20305

Published online in Wiley InterScience (www.interscience.wiley.com).

practical use of ancillary techniques to supplement morphologic examination.

**NORMAL BONE MARROW**

The bone marrow occupies the cavities of about 85% of the skeletal system and weighs between 1,600 and 3,700 g in the normal adult (1). Functionally, the bone marrow is the major site of blood cell formation (hematopoiesis) in the body, and also serves as an important element of the reticuloendothelial system. The bone marrow normally produces approximately 2.5 billion red blood cells, 1.0 billion granulocytes, and 2.5 billion platelets daily per kilogram of body weight (2). However, the marrow has an enormous reserve capacity of 5–10 times normal in times of hematopoietic stress (2). The major components of the bone marrow, as classified by Brown and Gatter, are listed in Table 1 (3).

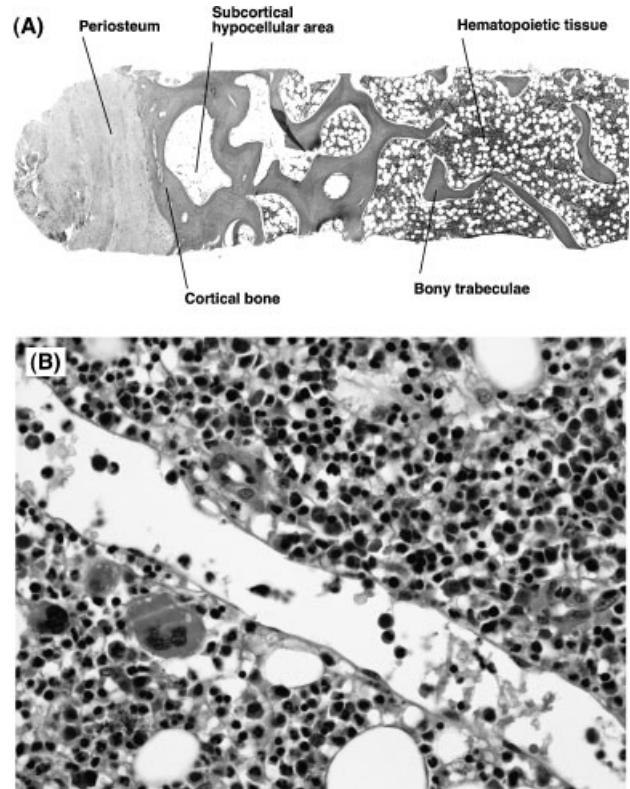
**Histomorphology of Bone Marrow**

Two types of bones are present in bone marrow biopsy specimens. The cortex is a dense layer of cortical

(compact) bone covered by a continuous outer layer of fibroelastic tissue (periosteum; periosteal membrane) and lined by a single layer of cells (endosteum) (Fig. 1) (4–6). The periosteum assists in the maintenance of bone shape and plays an important role in ion exchange (7). Cavities within the cortical bone contain a honeycomb network of trabecular (cancellous) bone lined by a layer of endosteal cells continuous with the cortical endosteum (4). The trabeculae are formed from parallel layers of bone (lamellae) held together by cement lines. The continuous process of bone formation and resorption (osseous remodeling) is most obvious in the subcortical portion of the biopsy of a child. In this region, bone-resorbing cells (osteoclasts) occupy small niches on the surface of the trabeculae (Howship’s lacunae, erosion cavities) interspersed by layers of bone matrix-forming cells (osteoblasts) and osteoid (unmineralized bone). The osteoclasts are typically large multinucleated cells, while the osteoblasts are small and cuboidal. Osseous remodeling is a highly complex process regulated by the interaction between a number of hormones, growth factors, and cytokines.

**TABLE 1. Components of the Normal Bone Marrow**

Component	Comment
Bone	Cortex of dense bone. Trabeculae of lamellar bone. Osteoblasts and osteoclasts along endosteal surface
Stroma	
Vessels	Small arteries, capillaries, and venous sinusoids. Sinusoids are normally thin-walled, collapsed, and inconspicuous
Reticulin and fibroblasts	Fine reticulin fibers form supporting network throughout marrow. Produced by fibroblasts. Most prominent around vessels
Adipose tissue	Increases with age, most prominent in subcortical region
Hematopoietic tissue	
Granulocytic series	Predominant marrow cell type except very early in life. Least mature forms normally along endosteal surface and around small arteries, most mature forms in intertrabecular region
Erythrocytic series	Normally organized into small groups (erythroid islands) associated with a macrophage
Megakaryocytic series	Mature forms are largest cells in body. Non-clustered, scattered, usually adjacent to venous sinusoids
Lymphocytes	Comprise up to 50% of marrow cells in infants and young children. Small, inconspicuous, may form small clusters
Plasma cells	Occur individually or in clusters of 2–3 cells. Most conspicuous around capillaries. Polyclonal
Mast cells	Few in normal bone marrow
Macrophages	Frequently occur in association with erythroid precursors



**Fig. 1.** Structure of the bone marrow. (A) Low-power photomicrograph of bone marrow biopsy, showing various bone structural components (H&E stain, 40 x), (B) Medium-power photomicrograph of bone marrow biopsy, showing microanatomy of the bone marrow. Including sinusoid (arrows) and hematopoietic elements (H&E stain, 400 x).

Hematopoiesis occurs in the cavities of certain bones that contain hematopoietically active marrow tissue (red marrow). Red marrow is widespread in the bones of children, but is restricted to the skull, sternum, scapulae, vertebrae, ribs, pelvic bone, and the proximal ends of the long bones of the extremities in adults (5,6,8). In these cavities, clusters of stem cells and their progeny lie in the extravascular spaces between a vast network of vascular channels (sinusoids) (Fig. 1) (2). Cytoplasmic processes extending from the fibroblastoid (reticular) cells covering the advential surface of the sinusoids form a support lattice for hematopoietic cells. The fibroblastoid cells, vascular endothelial cells, macrophages, extracellular matrix molecules, and adipocytes comprise the bone marrow stroma. This network of cells is important in directing many of the soluble chemical factors (cytokines) that regulate and control the process of hematopoiesis, in addition to providing an adhesive framework onto which the developing cells are bound (8–13). These factors are referred to collectively as the hematopoietic microenvironment. An analogy is to think of the stem cell as the seed and the microenvironment as the soil. Both must be present for the crop (mature bone marrow cells) to grow successfully. In addition to assuring that the production rate of blood cells is equal to the senescence rate, these substances are also important in responding to disease and environmental stimuli. For example, a bacterial infection leads to increased neutrophil production, but not to erythrocyte production, while erythrocytes, but not neutrophils, increase in response to hypoxia.

Hematopoietic cells are not arranged at random, but have a consistent spatial relationship to the other components in normal samples. Early myeloid precursors are found adjacent to the endosteal surface, while mature myeloid cells, erythroid cells, and megakaryocytes are found in the central intratrabecular region in association with the marrow sinusoids (Fig. 1) (3,5,6,8). However, this arrangement can be easily disrupted by pathologic states. The cellularity of the bone marrow is defined as the proportion of cellular elements relative to adipose tissue (3,14). The cellularity is variable and normally decreases with age. The cellularity for a given age can be approximated by subtracting the patient's age from 100. The term hypocellular is used for a bone marrow with decreased cellularity and increased adipose content, while a bone marrow with an increased proportion of hematopoietic cells, and decreased amount of fat, is referred to as hypercellular. There are other age-related changes in the bone marrow, including a reduction in the volume of trabecular bone and the number of endosteal cells, osteocytes, and paratrabecular sinusoids (8). In addition, the subcortical region of older individuals may contain a disproportio-

tionally large amount of adipose tissue (subcortical hypoplasia), possibly leading to errors in interpretation if an adequate sample is not available. The cellularity of the bone marrow is not static. Cellularity can rapidly increase in response to stress, infection, or other diseases, while decreased cellularity for age is usually the result of a pathologic disease.

### Cellular Components of the Bone Marrow

Blood cells (i.e., red cells, white cells, and platelets) are continuously renewed in the bone marrow from progenitors of primitive mesenchymal cells known as pluripotential hematopoietic stem cells (HSCs) (15). The essential properties of the stem cell are self-renewal and self-differentiation. Progenitor cells arising from the HSC are multipotent, but their progeny are committed to differentiation along the erythroid, granulocytic, monocytic, megakaryocytic, or lymphocytic pathways. Although HSCs form a very small proportion of the total hematopoietic cells, they are maintained throughout the life of the individual. Most HSCs are in a reserve, nondividing pool, while a small fraction continually divide but do not differentiate. HSC survival, self-renewal, proliferation, and differentiation require appropriate hormone-like chemical signals (hematopoietic cytokines) and the "microenvironment" provided by the stromal cells and extracellular matrix of the bone marrow. Hematopoietic cytokines are 20–50 kD glycoproteins that can be subdivided into two types based on whether they consist of four or six  $\alpha$ -helices (16,17). Type I hematopoietic cytokines include interleukins (IL) -2, -3, -4, -5, -6, -7, -9, -11, -12, -13, 15, -21, -23, erythropoietin (EPO), thrombopoietin (Tpo), leukemia inhibitory factor, neurotrophin-1/B-cell-stimulating factor-3, and colony-stimulating factors for granulocytes (G-CSF), and granulocyte-macrophages (GM-CSF). Interferons (IFN) and IL-10, -19, -20, -22, and -24 are members of the type II cytokine family (16). Hematopoietic cytokines are secreted by various cells and tissues throughout the body and regulate the production and function of hematopoietic cells (16,18). The therapeutic potential of cytokines makes them the focus of intense scientific and commercial interest. The properties of the major hematopoietic cytokines are summarized in Table 2.

The regulation of hematopoiesis is a complex process that is incompletely understood. The details of this process have been derived primarily from *in vitro* cell culture experiments that analyze the molecular, immunologic, biochemical, and morphologic effects of various cytokines on different populations of hematopoietic cells. The cytokines exert their biologic effects through interaction with specific receptors on hematopoietic cells

TABLE 2. Hematopoietic Cytokines

Factor	Source	Receptor/target cells	Alternative names	Major biologic function
Erythropoietin (EPO)	Largely renal tubular and juxtatubular cells. Some from hepatocytes and hepatic Kupffer cells	Pluripotent embryonic stem cells and early multipotent hematopoietic cells	Erythroid colony stimulating activity; Erythropoiesis stimulating factor	Differentiation factor for erythroid progenitor cells. Regulates proliferation of erythroid progenitors
G-CSF	Stromal cells, fibroblasts, endothelial cells, activated monocytes, macrophages and neutrophils	CD114; cells of neutrophil/granulocyte lineage, placenta cells, endothelial cells	Granulocyte colony-stimulating factor; Colony stimulating factor-2, Differentiation factor	Proliferation and differentiation of neutrophil/granulocyte progenitor cells
GM-CSF	Activated T cells, macrophages, stromal cells, endothelial cells, fibroblasts	Myeloid cells, endothelial cells, small cell lung carcinoma cells	Granulocyte-macrophage colony stimulating factor, hematopoietic cell growth factor	Growth and development of granulocyte and macrophage progenitor cells. Acts synergistically with Epo in proliferation of erythroid and megakaryocytic progenitor cells
IL-1 (IL1 $\alpha$ , IL-1 $\beta$ )	Monocytes, activated macrophages, dendritic cells, peripheral neutrophils	Type-1 receptor (CD121a): T cells, cells of mesenchymal origin; Type-2 receptor (CD121b): B cells, granulocytes, macrophages	Endogenous pyrogen, acute phase protein inducing factor, leukocytic endogenous mediator	Major mediator of inflammatory reactions, stimulation of T-helper cells, B-cell proliferation and immunoglobulin synthesis. Induces other growth factors
IL-2 (T-cell growth factor)	Activated CD4 <sup>+</sup> T cells	T-cell precursors	Lymphocyte mitogenic factor, blastogenic factor, lymphocyte proliferation factor	Stimulates growth and differentiation of T cells, activation of T cells
IL-3	Activated T cells, NK Cells	Macrophages, mast cells, eosinophils, megakaryocytes, basophils, bone marrow progenitor cells	Multi-colony stimulating factor, colony forming unit spleen, erythroid colony stimulating factor	Stimulates proliferation and differentiation of most hematopoietic progenitor cells, induces histamine release from mast cell
IL-4	Activated T cells, basophils, mast cells, stromal cells	Type 1 IL-4 Receptor (CD124/CD132): B cells, macrophages; Type 2 receptor	B-cell growth factor, B cell stimulating factor	Induces proliferation and differentiation of activated B cells, stimulation of B cell, mast cell, and basophil progenitors, enhanced expression of MHC class II, increased expression of adhesion molecules, modulation of pro-inflammatory cytokine/chemokine production
IL-5	T-helper cells, mast cells	II hematopoietic and lymphoid cells	Eosinophil differentiation factor, B-cell growth and differentiation factor	Enhances growth and differentiation of eosinophils, stimulation of B cell growth and immunoglobulin secretion
IL-6	Stimulated monocytes, fibroblasts, endothelial cells, stromal cells, T cells, macrophages	T cells, mitogen-activated B cells, peripheral monocytes	B-cell stimulating factor; hepatocyte stimulating factor	Major inflammatory mediator, induces B and T cell growth and differentiation; stimulates myeloid stem cell proliferation and differentiation, regulates thrombopoietin production

IL-7	BM stromal cells, thymic and intestinal epithelial cell	CD127, activated T cells, pre-B cells and their progenitors; bone marrow macrophages	Pre-B-cell growth factor; thymocyte growth factor	Stimulates proliferation of pre-B and pro-B cell, induces proliferation of early and mature activated T cells
IL-8	Stimulated monocytes, macrophages, fibroblasts, endothelial cells, other cells	CD128, neutrophils and many other cells	Neutrophil chemotactic factor, granulocyte chemotactic factor, neutrophil activating factor	Enhances chemotaxis and the enhanced expression of adhesion molecules, stimulates the myeloid cell production and differentiation
IL-9	Activated Th cells		T-cell growth factor-3; mast cell growth factor, megakaryocyte growth factor	Stimulates proliferation of T-helper cell clones, enhances proliferation of bone marrow mast cells, megakaryocytes and burst-forming units-erythrocytes
IL-10	Activated T cells, B cells, monocytes	Cdw210, Macrophages, B cells	B-cell-derived T-cell growth factor	Downregulates T-cell function and proliferation, inhibits the synthesis of IL-1, IL-6 and TNF- $\alpha$
IL-11	Bone marrow stromal cells, fibroblasts, mesenchymal cells	Fibroblasts	Adipogenesis inhibitory factor, megakaryocyte colony stimulating factor	Regulator of megakaryocytopoiesis, enhances the colony formation by primitive hematopoietic precursor cells, promotes primary and secondary immune responses and modulates antigen-specific antibody reactions of B cells
IL-12	Activated B cells, T cells	Peripheral blood mononuclear cells, activated T cells, NK cells	Cytotoxic lymphocyte maturation factor, NKSF (natural killer cell stimulatory factor)	Stimulates proliferation of lymphoblasts following cell activation, activates CD56 <sup>+</sup> NK cells, induces synthesis of IFN- $\gamma$ , IL-2, and TNF, stimulates natural-killer and cytotoxic T cells
M-CSF	Stromal cells	CD115/?	Monocyte-macrophage colony stimulating factor, macrophage growth factor CSF-1	Enhances growth, differentiation, and survival of monocytes; stimulates proliferation and differentiation of hematopoietic stem cells into macrophages
Stem cell factor	Fibroblasts and other cell types	Stem cell factor receptor (CD117); stem cells and early bone marrow progenitor cells	Multipotent growth factor, Steel factor, stem cell growth factor	Growth factor for primitive CD34 <sup>+</sup> lymphoid and myeloid hematopoietic bone marrow progenitor cells, stimulates proliferation of myeloid, erythroid, and lymphoid progenitors
Major regulator of	Thrombopoietin (TPO) megakaryopoiesis, stimulates megakaryocyte proliferation, maturation, and platelet production	Liver, kidney, striated muscle, bone marrow stromal cells	Megakaryocyte progenitors	TSF (thrombopoiesis stimulating factor)
Tumor necrosis factor (TNF)	Monocytes/macrophages, endothelial cells, many tissues	Widespread, most tissues	TNF- $\alpha$ (cachectin) and TNF- $\beta$ (lymphotoxin)	Multifunctional cytokine, promotes proinflammatory reaction in response to injury or infection, stimulates IL-1 and GM-CSF, many other effects

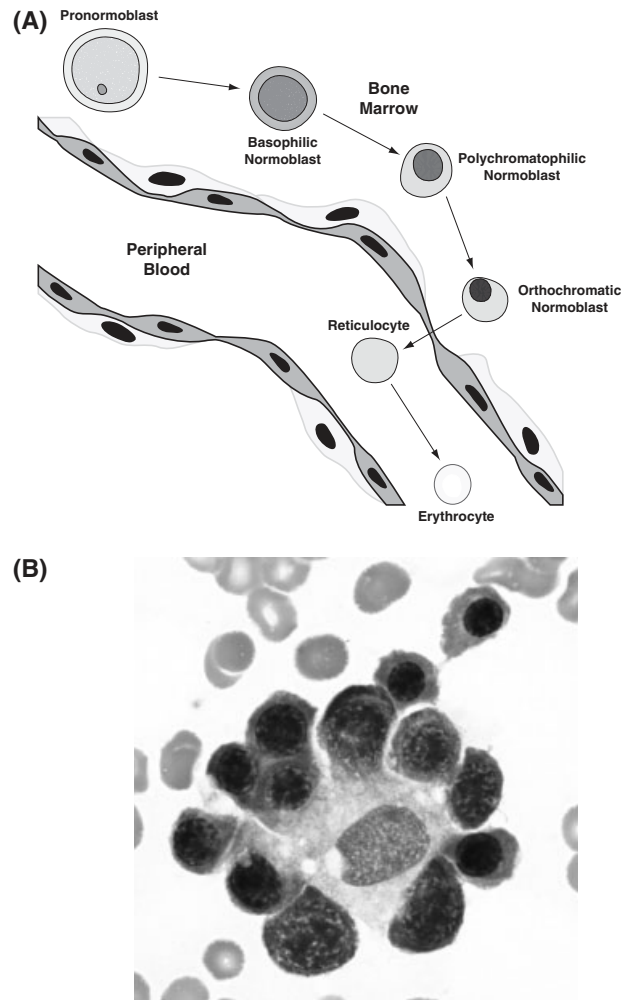
that form the hematopoietic receptor superfamily (16,19). Members of the hematopoietic receptor superfamily are membrane glycoproteins composed of structurally similar extracellular domains, single transmembrane domains, and intracellular domains that are constitutively associated with different signaling proteins, the most critical being members of the Jak and Btk/Tec nonreceptor tyrosine kinase families (i.e., Jak-1, Jak-2, Jak-3, and Tyk-2) (16). Ligand binding brings the associated Jaks into close proximity, leading to the activation of transcription factors, the most important being members of the signal transducers and activators of transcription (Stat) family (16). The genes for many of the hematopoietic receptors reside in a small region on the long arm of chromosome 5. Genetic alterations of the hematopoietic receptors or related signaling components result in immunologic and hematologic diseases, including immunodeficiency and leukemia.

### Erythroid precursors

Erythropoiesis is a complex, highly regulated process that results in the differentiation of hematopoietic stem cells into mature red blood cells (20). In the adult, this process normally results in the production of approximately  $10^{10}$  red blood cells per hour to maintain the red blood cell count within a narrow physiologic range. Primitive erythroid precursors arise from the pluripotent stem cell and subsequently undergo a progressive series of structural and biochemical changes driven by EPO and other hematopoietic cytokines (Fig. 2). The most important of these changes include the following:

- Synthesis and cytoplasmic accumulation of hemoglobin.
- Loss of protein-synthesizing apparatus and mitochondria.
- Chromatin condensation, contraction, and extrusion of the nucleus.
- Loss of cell-surface membrane receptor expression via exosome formation.
- Changes in membrane cholesterol and phospholipid levels.
- Changes in various intracellular enzyme levels, including glucose-6-phosphate dehydrogenase.

The erythroid burst-forming unit is the first lineage committed erythroid cell detectable by cell culture studies. Erythroid colony forming units (CFU-E) arise under the influence of EPO. The pronormoblast results from cell division of the CFU-E, and is the first morphologically identifiable red blood cell. Subsequent cellular stages in erythropoiesis include the basophilic normoblast, polychromatophilic normoblast, ortho-



**Fig. 2.** Erythropoiesis. (A) Illustration of stages of erythroid development, (B) Bone marrow aspirate showing erythroid island (Wright-Giemsa stain, 1000x).

chromatic normoblast, reticulocyte, and mature red blood cell (Fig. 2) (21,22). Together, the red blood cells and the various morphologically identifiable red blood cell precursors comprise the erythron.

The progression from a pronormoblast to a non-nucleated red blood cell requires 3–5 days but can be accelerated if biologically needed. The erythroid precursors are described below. The term “normoblast” should only be used in reference to normal erythropoiesis. The more general term, “erythroblast,” refers to both normal and abnormal erythropoiesis.

- **Pronormoblast (rubriblast):** This is the largest of the erythroid precursors ( $\sim 20 \mu\text{m}$ ). The nucleus has a “ropy,” relatively coarse chromatin and may contain large nucleoli that are not prominent. There is a moderate amount of agranular basophilic cytoplasm,

a large Golgi zone, and a perinuclear halo of mitochondria. Two basophilic normoblasts are formed from the division of a pronormoblast.

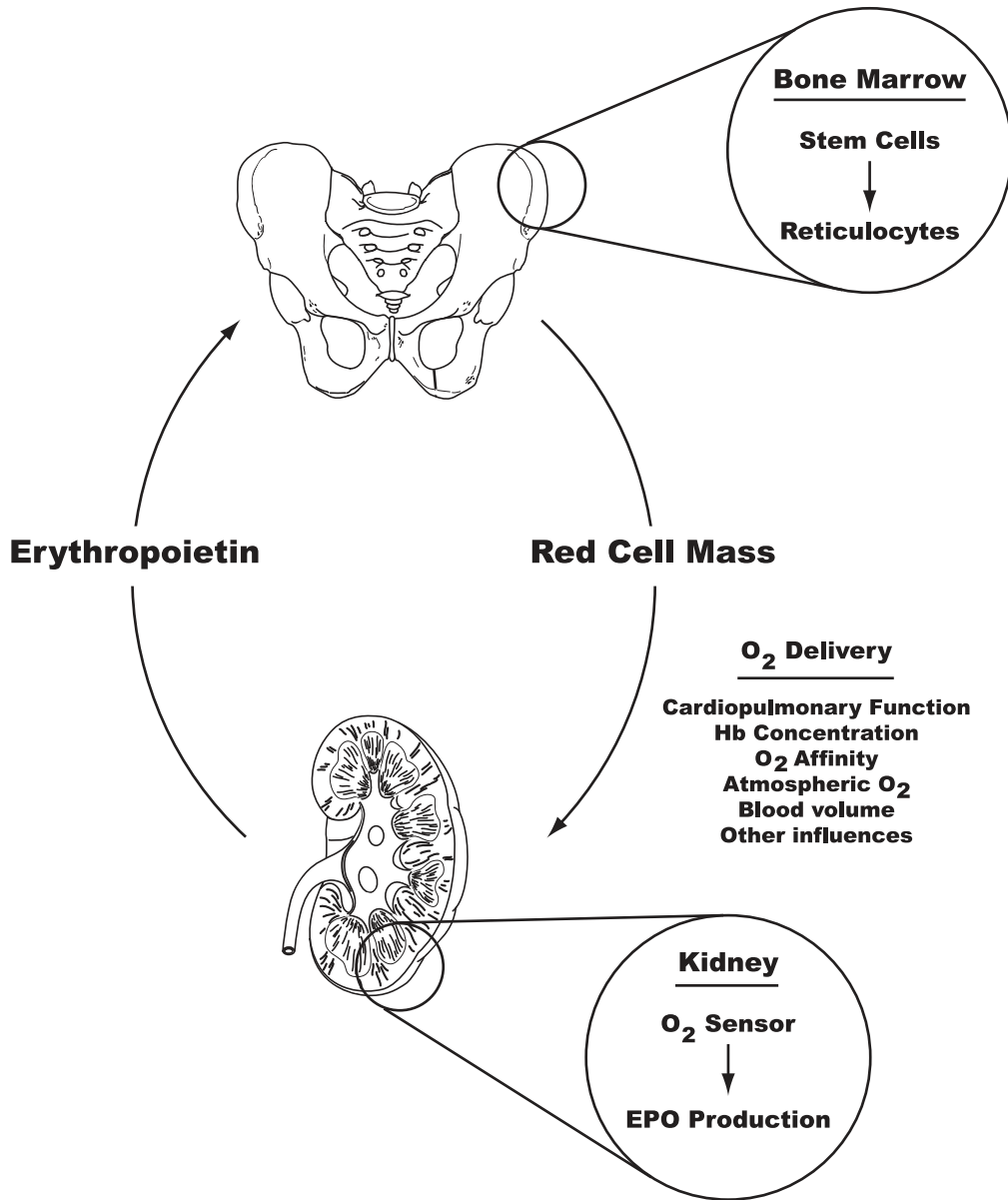
- **Basophilic normoblast (prorubricyte):** The basophilic normoblast I is slightly smaller than the pronormoblast (10–18  $\mu\text{m}$ ) and has intensely staining, slightly coarse nuclear chromatin. Nucleoli are not prominent. The cytoplasm is deeply basophilic because of the presence of large amounts of RNA. A Golgi zone may be present, as well as a perinuclear halo of mitochondria. Siderosomes may be seen with an iron stain. A second cell division produces the basophilic normoblast II, characterized by condensed nuclear chromatin arranged in spoke-like fashion.
- **Polychromatophilic normoblast (rubricyte):** The polychromatophilic normoblast I is slightly smaller than the basophilic normoblast (10–15  $\mu\text{m}$ ) and is characterized by intensely staining “checkerboard” or “tortoise shell” chromatin that is distinct from the lavender parachromatin. Nucleoli are not visible. Hemoglobin production in the cytoplasm produces polychromasia (varying shades of gray due to the mixture of red hemoglobin and blue-staining RNA). One or two mitotic divisions occur, with the formation of polychromatophilic normoblast II, which is usually classified as a separate stage of maturation, the orthochromatic normoblast.
- **Orthochromatic normoblast (acidophilic normoblast, metarubricyte):** This cell is smaller than the polychromatophilic normoblast and is incapable of cell division. It is characterized by a small and dense nucleus (pyknotic). The cytoplasm remains polychromatic, but contains more hemoglobin and fewer polyribosomes than the polychromatophilic normoblast. The reticulocyte results when the nucleus is extruded with a small rim of cytoplasm.
- **Reticulocyte (proerythrocyte):** This is an anucleate red blood cell, which is slightly larger than the mature red blood cell (10–15  $\mu\text{m}$  vs. 6–8  $\mu\text{m}$ ). The early reticulocyte contains mitochondria, a small number of ribosomes, the centriole, and remnants of Golgi bodies. Early reticulocytes continue to synthesize hemoglobin, and approximately 20–30% of the total hemoglobin of the red blood cell is synthesized at this stage of red blood cell development. However, hemoglobin synthesis gradually decreases as cellular organelles are progressively lost and the reticulocyte becomes a mature red blood cell. Changes in the surface membrane of the reticulocyte, including the loss of the transferrin receptor, also occur during differentiation. After about two days in the bone marrow, reticulocytes are normally released into the peripheral blood and undergo final maturation. The term “reticulocyte” was derived from the deep blue

precipitate seen in these cells after staining with new methylene blue and other tricyclic, heterochromatic, cationic dyes that bind and cross-link RNA and aggregate other organelles.

- **Normocyte (erythrocyte, discocyte):** The mature red blood cell is 7–7.5  $\mu\text{m}$  in diameter, similar to the nucleus of a small lymphocyte. The cytoplasm is pale red, with a central area of pallor approximately 1/3 the diameter of the cell. The central pallor is due to the biconcave shape of the cell.

EPO is one of the hematopoietic growth factors and the major chemical regulator of erythropoiesis. EPO is a glycoprotein (34,000–39,000 kDa) produced by the kidney in response to reduced renal oxygen tension. Although EPO accelerates the division of erythroblasts at all stages of development, its major effect is to stimulate resting committed erythroid progenitor cells to enter the cell cycle (Fig. 3) (18,23). The binding of EPO to the EPO receptor (EPO-R) induces a conformation change in the EPO molecule that results in the activation of the tyrosine kinase Janus kinase 2 and the subsequent tyrosine phosphorylation of the transcription factors signal transducer and activator of transcription 1 (STAT1), STAT3, and STAT5a/b (24). Optimal oxygen delivery to the tissues occurs at a hematocrit of 40–45% and thus the production of red blood cells is very tightly regulated. Cell death of unwanted erythroid precursors through apoptosis is one of the major mechanisms of regulation. Both the intrinsic and extrinsic apoptotic pathways may be activated by the withdrawal of EPO or the activation of death receptors (25). Recent evidence suggests that inappropriate activation of apoptosis is one of the major pathophysiologic mechanisms of anemia (25).

Clones of nucleated erythroid precursors with a macrophage (reticular cell and nursing cell) in the center are termed erythroblastic islets or islands (26). This “nursing cell arrangement” is critical for erythropoiesis, since the macrophage supplies iron and plays other critical supporting roles. Transferrin is used to carry stored iron released from hemosiderin in the macrophage to the erythroblast, where it is incorporated as a membrane-bound body called a siderosome. The siderosomes transfer their iron into the mitochondria, where the iron is integrated into the heme portion of the hemoglobin molecule. The macrophage also keeps the bone marrow in order by phagocytizing extruded erythroblast nuclei and elderly or apoptotic hematopoietic precursors. The microscopic structure of the erythropoietic islets is best appreciated in bone marrow aspirate smears and may not be apparent in bone marrow biopsy sections. Erythroid precursors normally comprise about 25–35% of total bone marrow cellularity (myeloid to erythroid ratio of 1.5:1 to 3:1). The more



**Fig. 3.** The biological effect of erythropoietin.

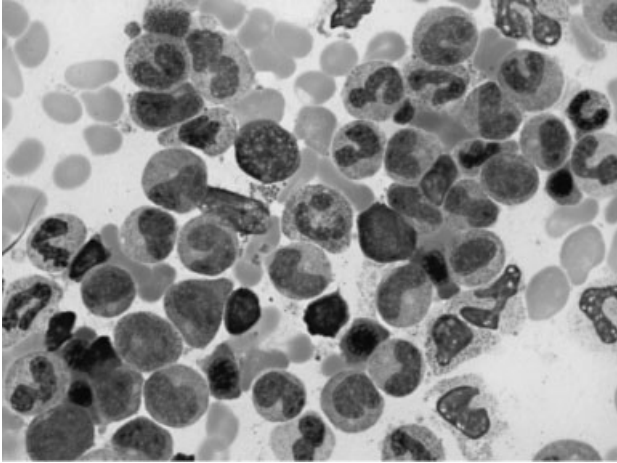
mature erythroid forms (polychromatophilic and orthochromatic normoblasts) normally comprise the majority of erythroid precursors, and are easily recognized in aspirate and biopsy specimens by their “peppercorn-like” appearance, with round nuclei and dark, condensed nuclei.

#### Granulocytic precursors

Granulocytes consist of neutrophils, eosinophils, and basophils. Although the term myeloid is used to distinguish cells derived from the bone marrow from cells derived from lymph tissue, it is also used in

reference to the neutrophil series. Neutrophils are the most abundant cell type in the normal bone marrow. The majority are neutrophilic myelocytes, metamyelocytes, bands, and segmented forms. Immature myeloid cells (myeloblasts) have round to irregularly shaped nuclei with one or more nucleoli and pale basophilic cytoplasm. Neutrophilic differentiation is reflected by the appearance of cytoplasmic granules, a change in the cytoplasm from light blue to clear, and a change in the shape of the nucleus from bean-shaped to banded to segmented. The early stages of granulopoiesis occur in the paratrabecular and periarteriolar areas, while more mature granulocyte precursors are found in the inter-





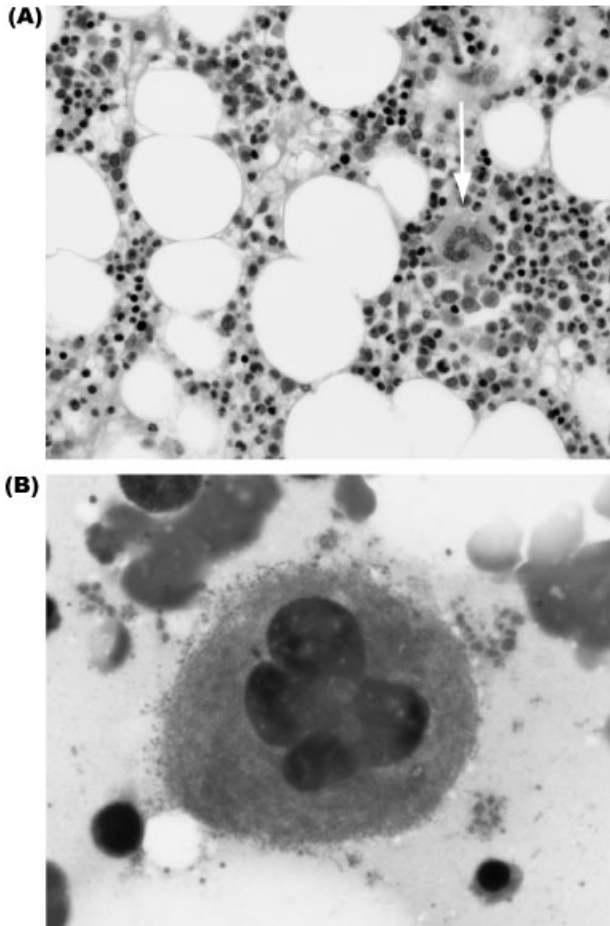
**Fig. 4.** Bone marrow aspirate showing myeloid precursors at different stages of maturation (Wright-Giemsa stain, 1000 x).

trabecular regions (Fig. 4). Normal neutrophilic granulocyte precursors are described below.

- **Myeloblast:** The myeloblast is the earliest morphologically distinct bone marrow precursor. The normal myeloblast is 15–20  $\mu\text{m}$  with a large, round nucleus, finely reticulated chromatin, and several small, distinct nucleoli. The cytoplasm is moderately basophilic and may contain a few azurophilic granules. Ultrastructural studies reveal the nucleus to primarily consist of euchromatin, while the cytoplasm contains abundant ribosomes and a few profiles of rough endoplasmic reticulum (27). Peroxidase activity may be present. The myeloblast is capable of cell division. Myeloblasts normally comprise approximately 1% of the nucleated bone marrow cells.
- **Promyelocyte (progranulocyte):** Promyelocytes are round to oval cells that are slightly larger than myeloblasts (15–25  $\mu\text{m}$ ). The promyelocyte nucleus is similar to that of the myeloblast, with fine chromatin and distinct nucleoli. However, the cytoplasm contains azurophilic (primary) granules that are formed during this stage of maturation. The primary granules bud from the inner, concave face of the Golgi apparatus, and contain many enzymes, including myeloperoxidase, lysozyme, elastase, cathepsin G, and acid hydrolases (27). Some hematopathologists classify promyelocytes as early or late, depending on the number of primary granules. The nucleus is slightly indented with one or two small nucleoli. A prominent Golgi zone is present. Promyelocytes retain proliferative capacity and comprise about 2% of normal nucleated bone marrow cells.
- **Myelocyte:** The myelocyte is 10–20  $\mu\text{m}$  in diameter. This stage of maturation is characterized by the formation of secondary granules that are not azurophilic. Secondary granules contain lactoferrin, lysozyme, vitamin B<sub>12</sub>-binding protein, phospholipase A<sub>2</sub>, histaminase, and other substances (28). Primary granules are no longer produced, and are diluted out as maturation continues. The nucleus is slightly eccentric, and round, “arrowhead”-shaped, or slightly indented with partially condensed chromatin. Nucleoli are not usually present. A small Golgi zone may be present. The earliest myelocyte forms are capable of cell division, but proliferative capacity is lost as maturation progresses. Myelocytes comprise approximately 10% of the nucleated marrow cells.
- **Metamyelocyte:** The metamyelocyte is 10–18  $\mu\text{m}$  in diameter, with abundant cytoplasm containing numerous small secondary granules and rare primary granules. Metamyelocytes have a “horseshoe”-shaped nucleus indented to less than one-half of the nuclear diameter. Dark-staining heterochromatin replaces some of the lighter-staining euchromatin of earlier myeloid stages (27). Metamyelocytes comprise 15–30% of nucleated marrow cells and are incapable of cell division.
- **Band forms:** Band neutrophils are 10–18  $\mu\text{m}$  in diameter and comprise 10–15% of nucleated marrow cells. Band neutrophils are also found in the peripheral blood. The nucleus is indented to more than one-half of the nuclear diameter but never restricted to a filament. The nucleus may be twisted or folded and often assumes a C, S, or U shape. There is a further loss of euchromatin, with a peripheral localization of the heterochromatin under the nuclear membrane. The cytoplasm is abundant and pinkish, with numerous small secondary granules.
- **Segmented forms:** Segmented neutrophils (polymorphonuclear leukocyte, PMN, 10–15  $\mu\text{m}$ ) are the most numerous leukocytes in the bone marrow and peripheral blood. The nucleus is segmented with 3–5 lobes connected by thin, narrow strands of dark nuclear material. The nucleus consists largely of heterochromatin, with only scattered patches of euchromatin. The pale cytoplasm contains numerous small secondary granules. The major function of the segmented neutrophil is the phagocytosis and killing of microbes (29,30).

### Megakaryocytes

Megakaryocyte colony-forming units (CFU-Meg) are derived from the pluripotent stem cell (31). The earliest megakaryocyte has a normal (diploid) DNA content, but the DNA content, as well as nuclear and cytoplasmic mass, rapidly increase as the cell undergoes a series of mitoses without cell division (endoreduplications) (Fig. 5).



**Fig. 5.** Megakaryocytes. (A) Megakaryocyte (arrow) in a bone marrow biopsy (H&E stain, 400x), (B) Megakaryocyte at high magnification, showing granular cytoplasm and platelet release (H&E stain, 1000x).

Megakaryocytes are found in the intratrabecular space adjacent to sinusoids and may be interposed between endothelial cells. The sinusoids are usually inconspicuous; however, and the megakaryocytes appear to be randomly dispersed. The following stages of megakaryocyte maturation are recognized (8).

- **Megakaryoblast:** Immature megakaryocytes are 15–20  $\mu\text{m}$ , with round to slightly lobulated nuclei and scant amounts of deeply basophilic cytoplasm.
- **Promegakaryocyte:** The promegakaryocyte is 20–80  $\mu\text{m}$  in diameter, with lightly basophilic, finely granulated cytoplasm.
- **Mature megakaryocyte:** Mature, polyploid (4N to 64N) megakaryocytes are the largest hematopoietic cell (80–150  $\mu\text{m}$ ), with a volume of approximately 15,000 femtoliter (fL). These cells are characterized by a multilobulated, cerebriform nucleus and eosinophilic

cytoplasm. As the megakaryocyte matures, cytoplasmic granules appear, followed by demarcation membranes. When maturation is complete, cytoplasm fragmentation occurs, with the production of 1,000 to 8,000 platelets, each with a volume of 7 to 9 fL (Fig. 5). Platelets are shed into the sinuses of the bone marrow on their way to the blood. Lymphocytes, granulocytes, and erythroblasts may also be found within the cytoplasm of the megakaryocyte, termed emperipoiesis. The purpose of this phenomenon is not understood.

The regulation of platelet production is poorly understood. Tpo is believed to be the major humoral regulatory substance. This substance stimulates CFU-Meg division, megakaryocyte production, and platelet production from the megakaryocyte (32,33). The peripheral blood is the normal reservoir for the majority (~66%) of platelets within the body. Most of the remaining platelets are stored in the spleen. The splenic pool greatly expands in patients with splenomegaly (enlargement of the spleen) or hypersplenism (a condition in which the spleen rapidly and prematurely destroys red blood cells).

### Lymphocytes

Small lymphocytes normally comprise 15–20% of the nucleated cell population of the bone marrow in adults, and a slightly larger proportion in children (8). There is normally a predominance of T lymphocytes in both the bone marrow and the peripheral blood. Lymphocytes are normally present singly in the intratrabecular spaces, but lymphoid clusters and aggregates of mature lymphocytes are common with increasing age.

### Monocytes and macrophages

Monocytes are produced in the bone marrow and normally comprise a small proportion of morphologically indistinct cells. They are probably under-recognized, since they are easily confused with granulocytic precursors (8). Macrophages (reticular cells and histiocytes) are large cells with oval or kidney-shaped nuclei, and variable amounts of cytoplasm that may contain granules, vacuoles, cellular debris, or hemosiderin. Macrophages are part of the reticuloendothelial (mononuclear phagocyte) system, and are essential for the removal of senescent cells and debris. They also serve as the major marrow site for storage of iron, and play a critical role as “nursing cells” for erythropoiesis. The derivation of the macrophage is less well understood than for other cells. They may represent a heterogeneous cell population derived not only from monocytes, but also from fixed reticulocyte cells, or a granulocyte-monocyte precursor (8).

### Plasma cells

Plasma cells are the final developmental stage of the B lymphocyte, responsible for the production of immunoglobulin. Plasma cells normally comprise about 1% of nucleated marrow cells in the adult, and are equally distributed throughout the active hematopoietic areas of the body. Frish has calculated that >100 million plasma cells in the bone marrow are responsible for >90% of the serum immunoglobulin synthesized in the body. Two histologic types of plasma cells can be identified in the bone marrow (8).

- Reticular plasma cells: These are the most common type of marrow plasma cell. They are 8–25 μm in diameter, with deeply basophilic cytoplasm, coarse chromatin arranged around the inner nuclear membrane in a “spoke-wheel” pattern, and a clear area adjacent to the nucleus representing the Golgi zone (“paranuclear hof”). These cells are usually found in close proximity to a blood vessel.
- “Lymphoplasmacytoid” plasma cells: These cells are smaller than the reticular plasma cell, with a less well-defined Golgi zone and a smaller amount of cytoplasm. Lymphoplasmacytoid plasma cells produce low-affinity IgM.

### Mast cells

Mast cells are derived from the basophil and constitute a very small proportion of normal bone marrow cellularity (34). Mast cells may resemble basophils, or may have an elongated, spindle-shaped appearance. They are most often found adjacent to endothelial cells or marrow sinusoids, at the endosteal surface of trabecular bone, in the walls of small vessels, or at the periphery of lymphoid aggregates (8). Mast cells are best visualized with special stains, including Giemsa and toluidine blue, or immunohistochemical stains (tryptase) (35).

### Stroma

The supporting framework of the bone marrow consists of a network of reticular fibers, blood vessels, and nerves. Fibroblasts, adipose cells, extracellular matrix proteins, and other components contribute to the microenvironment of the bone marrow.

## ROUTINE DIAGNOSTIC EVALUATION OF HEMATOLOGIC SPECIMENS

Bone marrow examination provides both qualitative and quantitative information about marrow cells and morphologic information about each cell line. Information is provided by the maturity and appearance of the cells of

each lineage. Immature cells are increased in hyperplastic and reactive conditions and in the acute leukemias. Atypical cells may be induced by reactive hyperplasia, vitamin B<sub>12</sub> and folate deficiency, the myelodysplastic diseases, drugs, toxins, or infectious agents. The amount of hemosiderin is an important clue to the cause of anemia. This information must be interpreted in the context of peripheral blood findings and other clinical and laboratory data. Therefore, diagnostic examination of the bone marrow is performed in a systemic fashion, evaluating the following components.

- Review of patient history, recent laboratory data, and past specimens.
- Examination of the peripheral blood smear, with determination of the absolute and relative proportion of each cell line and the presence of abnormal morphologic features.
- Examination of the bone marrow aspirate under low, intermediate, and high power, to assess cellularity, the relative proportion of each cell type, the morphology of each cell type, and the presence of metastatic cancer cells or other “foreign” cells.
- Examination of a Perl’s Prussian blue-stained bone marrow aspirate for storage iron (decalcification of the bone marrow biopsy leaches out the iron, making this specimen type less suitable).
- Examination of the bone marrow biopsy under low, intermediate, and high power to assess cellularity, the relative proportion of each cell type, morphology of each cell type, presence of fibrosis, granulomatous inflammation, lymphoid aggregates, metastatic tumors, or other focal lesions.
- Evaluation of flow cytometric data, immunohistochemical stains, special stains, or other ancillary tests.
- Assignment of a final histologic diagnosis.

Specimen quality is a major consideration in the interpretation of bone marrow specimens. Diagnostic interpretation is possible only if morphologically intact cells are present in sufficient number to be representative of the bone marrow. The bone marrow aspirate should contain several particles, each with a “trail” of well-stained, morphologically distinct bone marrow cells. A common problem is the dilution of the bone marrow aspirate with peripheral blood, leading to a paucity of particles and hematopoietic precursors. The aspirate may also be excessively thick, poorly stained, or prepared with excessive pressure, so that the majority of cells are crushed and morphologically unrecognizable. Smears from patients with acute leukemia often have an overabundance of cells and the thickness of the smear can hamper morphologic evaluation. Adequate areas may sometimes be found at the periphery of the smear; otherwise, additional smears should be stained. Additional smears may be prepared from

TABLE 3. Bone Marrow Artifacts

Specimen	Artifact	Cause
Bone marrow aspiration	Suboptimal staining	Old or contaminated staining solution, inadequate staining time
	Inadequate particles	Poor aspiration technique, "dry tap"
	Cell crushing and distortion	Inadequate training, improper procedure
	Thick smears	Clotted specimen, inadequate training, improper procedure
	Uneven cell distribution	Clotted specimen, inadequate training, improper procedure
	Clotted specimen	Poor technique, multiple aspiration attempts with local activation of coagulation system, hyperactive coagulation system
Bone marrow biopsy	Aspiration artifact	Biopsy of aspiration site, failure to obtain aspirate and biopsy specimens from different areas
	Suboptimal staining	Inadequate fixation of processing, expired or contaminated staining solution
	Biopsy of previous aspiration or biopsy site	Failure to reorient biopsy needle at a proper angle or to a proper site
	Crushed or fragmented specimen	Harsh handling during touch imprint preparation or processing, inadequate microtomy
	Inadequate fixation	Inadequate volume of fixative solution, inadequate fixation time
	Excessive decalcification	Poor tissue fixation, excessive time in decalcification solution
	Inadequate decalcification	Poor tissue fixation, insufficient time in decalcification solution, inadequate volume of decalcification solution
	Uneven section thickness, "thick and thin" sections, chatter, "Venetian blind effect"	Inadequate decalcification, inadequate microtomy (dull knife blade, improper handwheel tension, improper clearance angle, improper pressure plate or spring balance tension, loose cassette clamp, inadequate decalcification, worn equipment)
	Compressed or wrinkled sections	Inadequate microtomy (dull knife blade, warm specimen block, improper clear angle, loose cassette clamp, worn equipment)
	"Scratched" or "split" sections	Defective cutting blade, inadequate decalcification, worn or improperly adjusted microtome

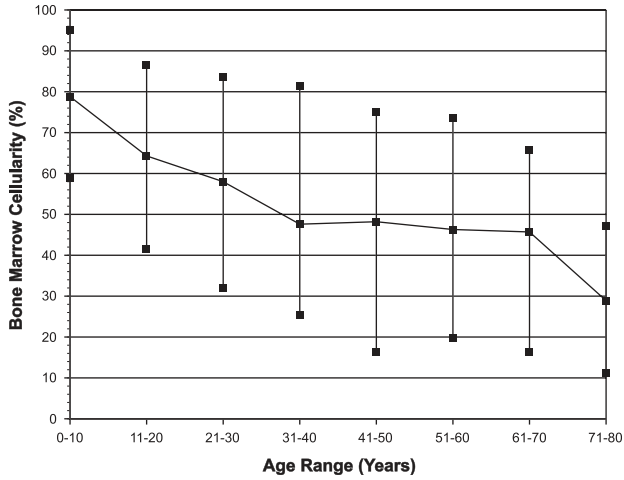
heparin-anticoagulated aliquots of bone marrow. Other options include smears prepared from diluted marrow, a buffy coat, or a specimen purified by density gradient centrifugation in Ficoll-Hypaque or other media. The bone marrow biopsy should be of adequate length, intact, and well-stained. Repeat biopsy must be recommended to the submitting physician if adequate specimens are not available. Common problems that compromise bone marrow specimen quality are summarized in Table 3.

### Bone Marrow Cellularity

Bone marrow cellularity is a measurement of the ratio of hematopoietic cells to fat. Cellularity provides important information about the activity of the bone marrow. At birth the marrow space is nearly entirely filled with active hematopoietic tissue. However, with aging, a loss of hematopoietic tissue, a reduction in the number of osteoblastic progenitors, and a reduction in the amount of bone causes a gradual decrease in the cellularity of the bone marrow (36). There is a corresponding increase in the amount of adipose tissue, which fills the nonhematopoietic marrow space. Several studies of normal individuals have demonstrated a relatively rapid decline in the cellularity of the iliac crest bone marrow over the first two decades of life, and a much more gradual decrease in middle-aged and older

individuals (Fig. 9) (37–39). Consequently, a normal middle-aged individual will have approximately 50% cells and 50% fat. However, because of the many variables affecting bone marrow cellularity, including location of the biopsy, 25–75% is usually considered normal in individuals 20–70 years of age (Figs. 6 and 7). Increased cellularity, termed hyperplasia (>75% cells), is a characteristic response to peripheral cytopenia due to extramedullary cell destruction (i.e., regenerative anemia, leukopenia, or thrombocytopenia) or an increased demand for hematopoietic elements (i.e., infection and hypoxia). Decreased bone marrow cellularity, termed hypoplasia or aplasia (<25% cellularity), is characteristic of marrow insult or injury to one or more of the hematopoietic cell lines due to infectious agents, drugs, toxins, and immune-mediated diseases. However, in many cases the cause of the insult cannot be determined, and the case is classified as idiopathic.

Bone marrow cellularity is most accurately determined from H&E-stained sections of the bone marrow biopsy, although a useful estimate can be obtained from the bone marrow aspirate if biopsy cores are not available (40–43). A subjective estimate of the relative amount of adipose tissue and hematopoietic tissue is usually made, although the cellularity can be precisely determined by point-counting, image analysis, and other techniques (44,45).

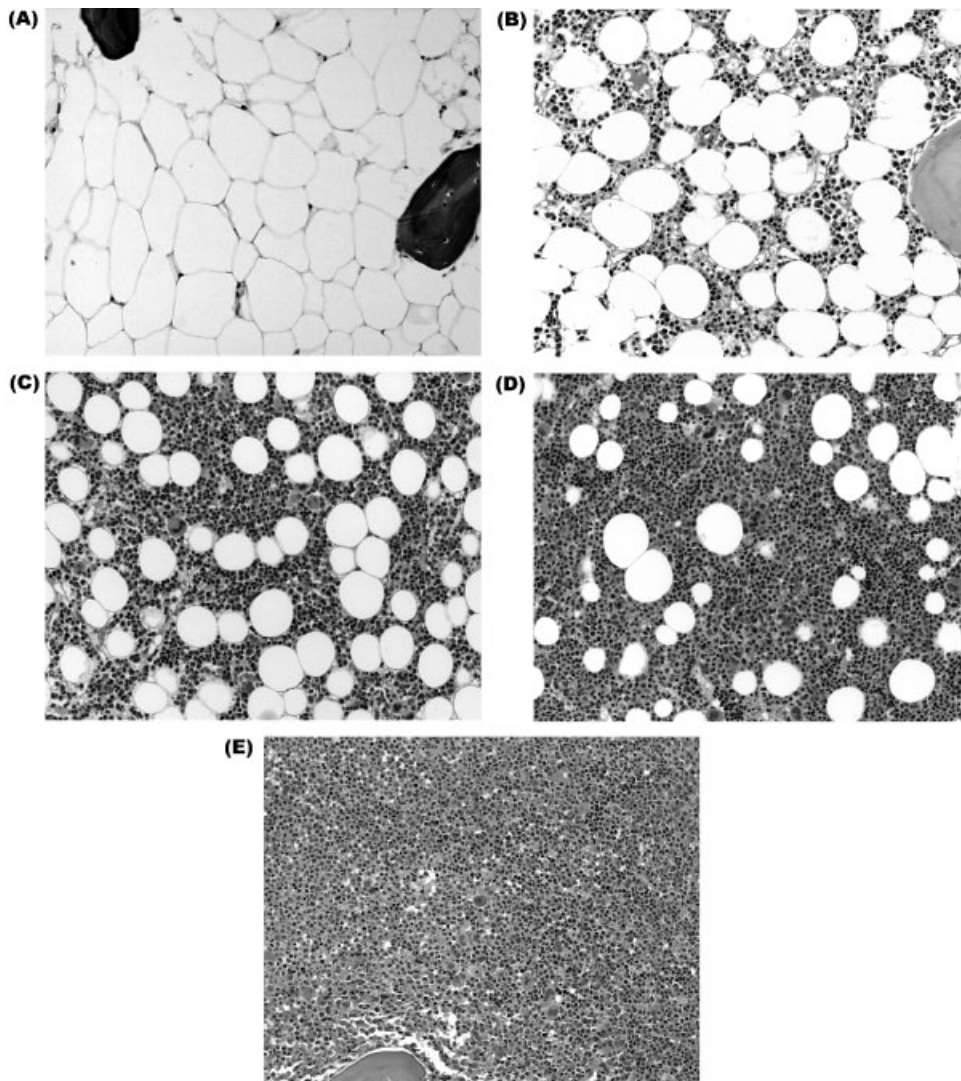


**Fig. 6.** Normal bone marrow cellularity relative to age. Data from (37).

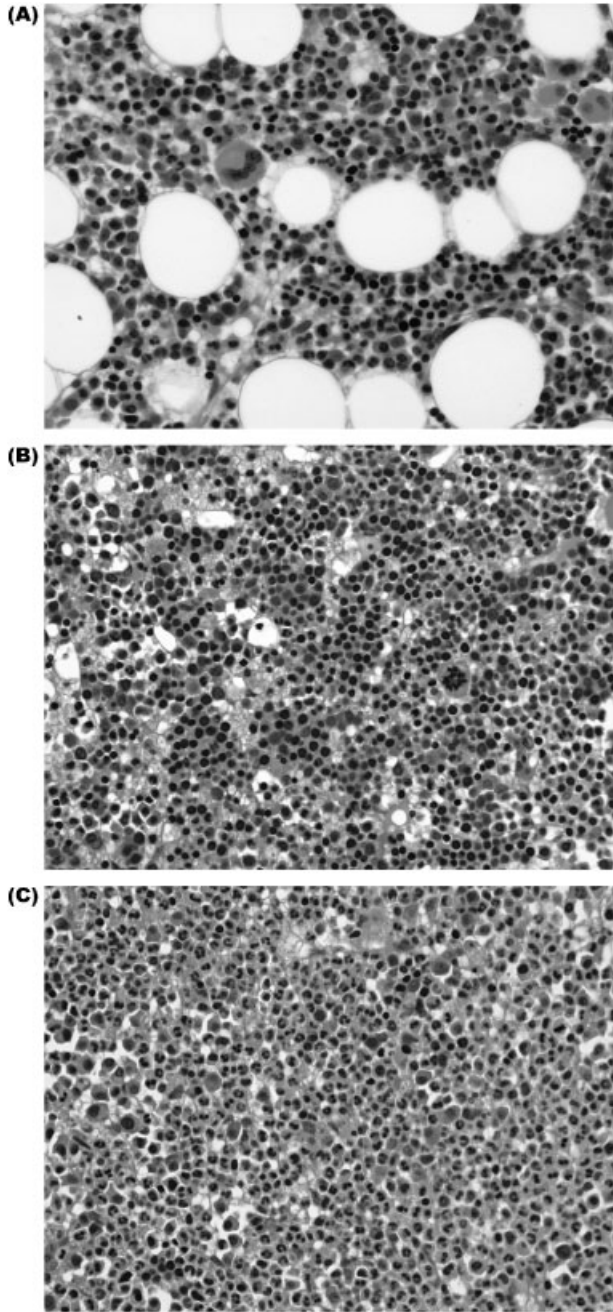
### Differential Count and Myeloid:Erythroid (M:E) Ratio

The differential count is performed by determining the percentage of various marrow cell types on a well-stained and technically adequate aspirate smear using a manual or electronic differential cell counter. Depending on the desired accuracy of the differential count, a total of 100, 200, 500, or 1,000 cells may be examined. The counts are compared with normal values and the total cellularity of the specimen to determine whether any cell line is increased (i.e., hyperplastic) or decreased (i.e., hypoplastic).

The M:E ratio is an important semi-quantitative measurement of red and white blood cell development. It is determined by dividing the proportion of cells in the myeloid series by the proportion of erythroblasts (46). A



**Fig. 7.** Photomicrographs of bone marrow biopsies with (A) <5% cellularity, (B) 25% cellularity, (C) 50% cellularity, (D) 100% cellularity (H&E stains, 400 x).



**Fig. 8.** Cellular composition of the bone marrow illustrating the M:E ratio. Photomicrographs of bone marrow biopsy specimens with (A) normal M:E ratio (approximately 3:1), (B) erythroid hyperplasia (M:E ratio 1:2), and (C) myeloid hyperplasia (M:E ratio > 10:1) (H&E stains, 400x).

subjective estimate of the M:E ratio can also be made on sections of the bone marrow cores if an aspirate is not available. The published values for the normal M:E ratio vary considerably, but values between 1.5:1 and 4:1 are usually considered normal (Fig. 8). An increased M:E ratio indicates granulocytic hyperplasia or decreased

erythropoiesis, while a decreased M:E ratio suggests decreased granulopoiesis or erythroid hyperplasia.

### Storage Iron

The bone marrow is a major storage site for body iron, so the amount of stainable iron in the bone marrow is an accurate indication of body iron stores. The evaluation of storage iron becomes extremely important in the evaluation of anemia in which measurements of serum iron do not reveal a definitive etiology.

Intracellular marrow iron is primarily in the form of hemosiderin granules localized in macrophages, with less in erythroblasts ("sideroblasts"). The structure of hemosiderin is poorly defined, but appears to consist of a complex of ferritin, ferritin degradation products, and other substances. Individuals with very large quantities of bone marrow iron show numerous irregular, yellow, granular deposits of hemosiderin in macrophages. However, smaller amounts of hemosiderin cannot be visualized by light microscopy, and must be detected by the Perl's Prussian blue reaction. The reaction of iron with potassium ferrocyanide [potassium hexacyanoferrate(III)] produces a deep blue precipitate that can be visualized by light microscopy. Prussian blue stains of bone marrow aspirate smears and bone marrow biopsy imprints provide the most sensitive measure of hemosiderin content. Decalcification of the clot section and bone marrow biopsy cores may decrease the amount of iron, but these specimens should be used if a bone marrow aspirate is not available (47).

The grading of the amount of storage iron is a routine part of the bone marrow examination. Several spicules on a Prussian-blue-stained bone marrow aspirate smear should be examined under medium (40x) and high (100x) magnification and the amount of hemosiderin estimated according to the scale of Bain (Table 4) (48). The grading should be based on the presence of intercellular storage iron, and both the macrophages and erythroblasts should be carefully examined. Most of the intracellular iron is in macrophages, but normally 20–50% of the erythroblasts contain one to four small granules of Prussian-blue positive material. The smear must also be carefully examined for the presence of ringed sideroblasts, which are abnormal

**TABLE 4. Bone Marrow Iron Content**

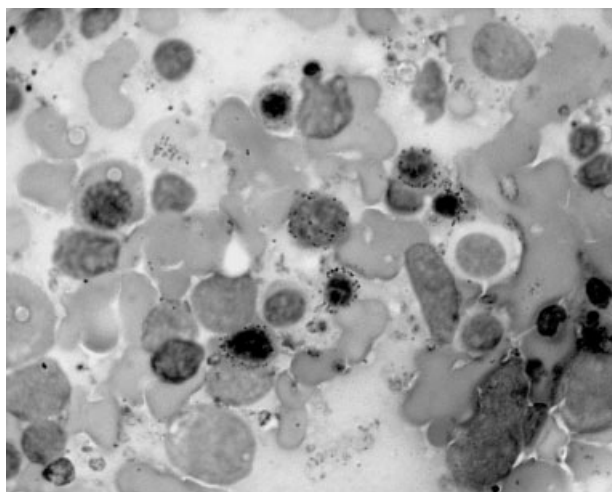
Grade	Features of Prussian blue stain
0	No stainable iron
1+	Small intracellular iron stores using oil objective
2+	Small, sparse intracellular iron particles at low power
3+	Numerous small intracellular iron particles
4+	Larger particles with a tendency to aggregate into clumps
5+	Dense, large clumps
6+	Very large clumps and extracellular iron

cells with granular iron deposits in mitochondria, forming a ring around the nucleus (Fig. 9).

Bone marrow iron stores are reduced or absent in iron-deficiency anemia, but increased in patients with anemia of chronic disease, iron overload, myelodysplastic syndromes, sideroblastic anemias, and thalassaemia. Ringed sideroblasts are characteristic of the myelodysplastic syndromes and sideroblastic anemias, and are only rarely found in other diseases.

### Reticulin and Collagen

Reticular fibers (i.e., reticulin) are formed by fibroblasts and comprise an important part of the stroma of the bone marrow. In the normal bone marrow, reticular fibers are few in number, and mainly concentrated around the blood vessels and endosteum. An increase in reticular fibers is characteristically associated with the myeloproliferative diseases but may occur in other conditions, including inflammatory diseases, lymphoproliferative disorders, and metastatic tumors. Collagen (bundles of reticular fibers) may also appear in these diseases. A nonspecific marrow response with increased reticular fibers and/or collagen is referred to as “fibrosis of the bone marrow” or “marrow fibrosis,” while “myelofibrosis” is used to refer to marrow fibrosis in patients with myeloproliferative diseases. Since fibrosis is a frequent cause of a “dry tap” or failure to acquire bone marrow particles during aspiration, the presence of fibrosis is often suspected during the procedure. In these cases, the Gordon–Sweet stain is used to confirm the presence of increased bone marrow reticulin, while the trichrome stain is employed to document the presence of collagen (Fig. 10). The Gordon–Sweet stain is a silver impregnation technique in which reticular fibers acquire



**Fig. 9.** Photomicrograph of a bone marrow from a patient with a myelodysplastic syndrome, showing numerous ringed sideroblasts (arrowed cells) (Prussian blue stain, 1000x).

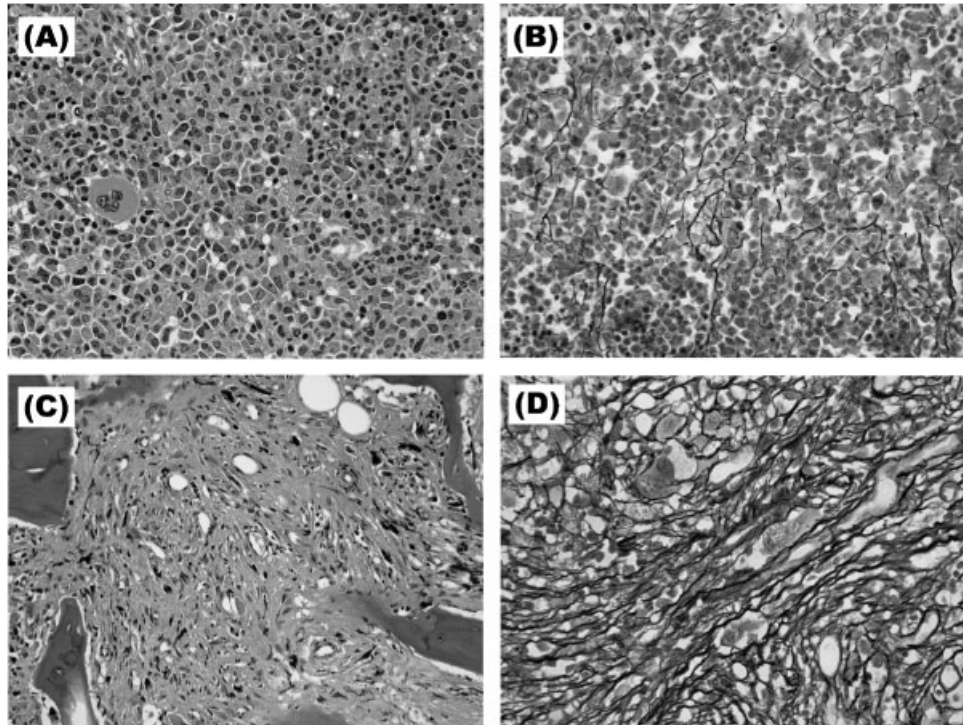
a dark gray or black color. Collagen has a blue color with the trichrome technique. In the interpretation of these stains, it is important to disregard areas with crush artifact, as well as the normal reticulin found immediately around blood vessels and bony trabeculae. Other factors that may affect the interpretation of reticulin stains include the thickness of the tissue section and cellularity of the tissue, as well as tissue fixation, decalcification, embedding, and shrinkage of the tissue during processing (39,49). The following grading scheme for marrow fibrosis was proposed by Bauermeister (Table 5) (50,51).

### Histopathologic Manifestations of Infection and Systemic Diseases

#### Acute inflammation and necrosis

The bone marrow of patients with septicemia may show vascular congestion with interstitial edema, focal hemorrhage, and fibrin deposition (52). Intravascular coagulation may be present. Large areas of hemorrhage may accompany hepatitis B infection with aplasia, hemophagocytic histiocytosis, or T-cell lymphoma (52).

Ischemic necrosis of the bone marrow most commonly occurs in patients with malignancies, either hematopoietic or nonhematopoietic, but has also been reported in various of nonmalignant diseases, including sickle cell disease, infection (fungal infections, typhoid fever, diphtheria, Q fever, tuberculosis, toxoplasmosis), septicemia, bacterial endocarditis, anorexia nervosa, anti-phospholipid antibody syndrome, hemolytic uremic syndrome, thrombotic thrombocytopenic purpura, disseminated intravascular coagulation, and hemophagocytic histiocytosis (52–54). In addition, bone marrow necrosis can be associated with various drugs, including G-CSF, interferon  $\alpha$ , ATRA, and fludarabine (54). Clinically, there are no pathognomonic symptoms of bone marrow necrosis, but severe necrosis may be accompanied by fever, bone pain, leukoerythroblastic peripheral blood features, pancytopenia, and elevated lactate dehydrogenase and alkaline phosphatase (53,55). H&E-stained trephine biopsy in a patient with bone marrow necrosis reveals intact cortical and trabecular bone, with focal or extensive loss of fat spaces and destruction of both hematopoietic stroma and hematopoietic cells (53,54,56,57). Stellate fibrin deposits may also be present (52). Bone marrow necrosis has generally been regarded as an uncommon lesion, but careful microscopic evaluation reportedly revealed necrosis in 37% of bone marrow biopsies (58). Suppurative necrosis of the bone marrow is characteristic of osteomyelitis. The necrosis destroys the bony trabeculae as well as hematopoietic and adipose tissue (52).



**Fig. 10.** Bone marrow reticulin fibers. Photomicrographs of a bone marrow biopsy of a patient with polycythemia vera in early spent phase showing a mild increase in reticulin fibers (**A**—H&E stain, 400 x, reticulin fibers; **B**—Gordon-Sweet reticulin stain, 400 x). Photomicrographs from a patient with primary myelofibrosis, showing a marked increase in reticulin fibers (**C**—H&E stain, 400 x, reticulin fibers; **D**—Gordon-Sweet reticulin stain, 400 x).

**TABLE 5. Reticulin Content**

Grade	Features of Gordon–Sweet and trichrome stains
0	No visible reticulin fibers
1+	Occasional fine individual fibers
2+	Fine fiber network throughout section, no coarse fibers
3+	Diffuse fiber network with scattered thick coarse fibers, no collagen
4+	Diffuse, often coarse fiber network with areas of collagenization

### Granulomatous chronic infection

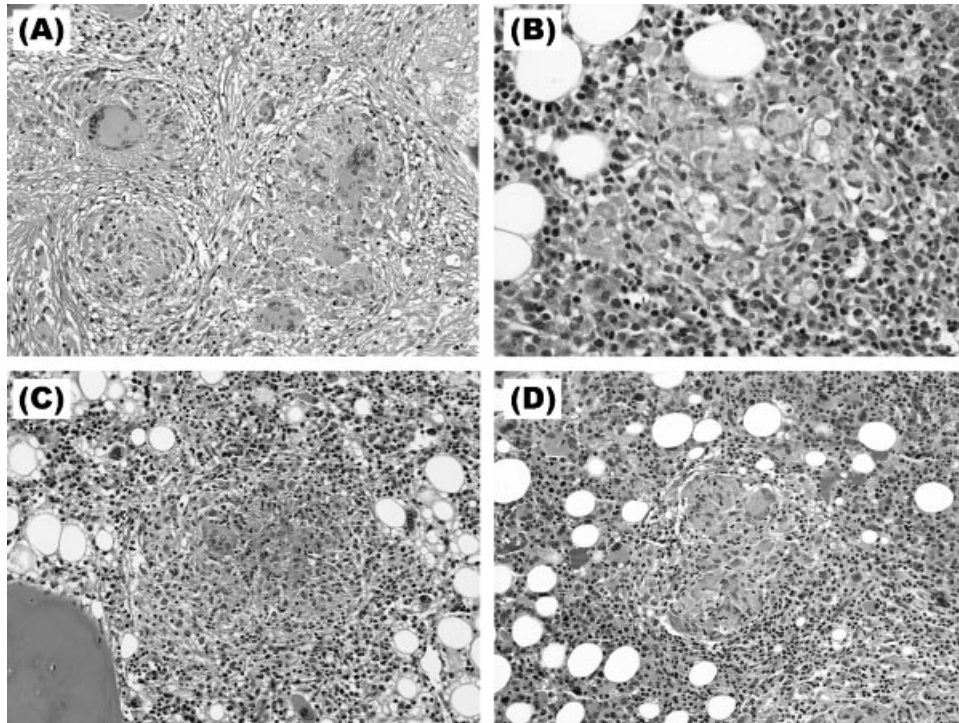
Granulomas are characterized by an “accumulation of histiocytes or epithelioid cells organized in a nodular pattern with sharp outlines (52).” Fibrinoid or caseous necrosis may occupy the central portion of the granuloma, while the periphery may contain a variable number of lymphocytes, plasma cells, and eosinophils (Fig. 11). Collagenous fibrosis may be found and multinucleated giant cells may be present. These lesions occur in association with chronic inflammatory conditions, including infection (fungal, viral, bacterial, rickettsial, and parasitic), autoimmune disease, drug hypersensitivity, sarcoidosis, and some malignancies (52). A fungal etiology must be excluded in all patients

with unexplained granulomas by special stains (Ziehl–Neelsen, GMS, or PAS Light Green) and microbiological culture. The exclusion of opportunistic agents such as atypical *Mycobacterium (avium intracellulare)*, *Histoplasma capsulatum*, *Toxoplasma gondii*, and *Cryptococcus neoformans* is especially important in immunosuppressed patients, including those with HIV infection (52). A careful search for small numbers of organisms is necessary, since patients with HIV/AIDS often have small areas of necrosis and clusters of macrophages without well-formed granulomas (Fig. 11). Recent studies have shown the highest diagnostic yield of bone marrow evaluation in HIV-infected patients receiving antiretroviral treatment when there is coexisting fever and cytopenia without localizing signs of infection (59).

### Lymphoid infiltrates and aggregates

Lymphocytes are a normal component of the bone marrow, constituting up to 25% of marrow cellularity. Normal lymphocytes are usually evenly interspersed throughout the interstitial tissue of the bone marrow, but may be clustered into lymphoid nodules or aggregates. The incidence of benign lymphoid aggregates increases with age, and may occur incidentally or in association





**Fig. 11.** Granulomatous inflammation in the bone marrow. Photomicrographs of bone marrow biopsies with (A) sarcoidosis, showing extensive replacement of the bone marrow tissue by granulomatous inflammation, (B) well delineated granuloma in an HIV-infected patient with disseminated cryptococcus, (C, D) unexpected granulomata occurring in bone marrow transplantation patients (H&E stains, 400x).

with nonhematologic diseases such as autoimmune disease, infection, or drug therapy. Since low-grade lymphoproliferative diseases commonly involve the bone marrow, and aggressive subtypes of non-Hodgkin lymphoma can, the bone marrow pathologist is often faced with determining the origin and clinical significance of a lymphoid infiltrate or aggregate(s). A detailed histopathologic evaluation will often discriminate the benign or malignant nature of lymphoid aggregate(s), but immunohistochemical examination is sometimes necessary and polymerase chain reaction (PCR) for T- and/or B-cell gene rearrangement studies is required in a few cases. In our experience, immunophenotypic analysis by flow cytometry is less useful for the evaluation of nodular lymphoid aggregates, since the neoplastic cells may not be present in the aspirated specimen.

According to Foucar, benign lymphoid aggregates are usually well-circumscribed, small (<4mm), few in number, randomly distributed in the bone marrow, and comprised of a predominance of T lymphocytes with variable numbers of plasma cells, eosinophils, mast cells, and histiocytes (60). On the contrary, the lymphoid aggregates from a malignant lymphoproliferative disease show more variability in morphology, but are often multiple, large, poorly circumscribed, and monomorphous in composition (Table 6) (Fig. 12). Certain

features of lymphoid aggregates may be useful in differentiating their origin. For example, germinal centers are most often present in benign lymphoid aggregates, especially those from patients with autoimmune disease, but may rarely be found in splenic marginal zone lymphoma and follicular lymphoma. Lymphoid aggregates in the bone marrow biopsies of patients with HIV/AIDS infection present special diagnostic problems. In these patients, benign lymphoid aggregates are easily misdiagnosed as malignant, since they are often large, poorly circumscribed, and show nuclear atypia (61).

Bone marrow involvement in non-Hodgkin lymphoma can be classified into several morphologic patterns of infiltration (Table 7) (62–65). According to a recent study of 450 bone marrow specimens with non-Hodgkin lymphoma, a mixed pattern of infiltration was most common, followed by the paratrabeular, nodular, diffuse, and intratrabeular/interstitial, and intrasinusoidal/intravascular patterns (66). The majority of patients with follicular lymphoma showed paratrabeular infiltrates, germinal centers, and/or follicular structures, while lymphoplasmacytic lymphoma usually showed an interstitial pattern of involvement (67). Discordance between the morphologic features of non-Hodgkin lymphoma in the bone marrow and that at other anatomic sites is another common problem in the

**TABLE 6. Characteristics of Benign and Malignant Lymphoid Aggregates**

Feature	Benign	Malignant
Number	Few, usually single	Variable, frequently multiple
Size	Usually < 1 mm	Variable frequently > 1 mm
Location	Usually intertrabecular/interstitial, frequently perivascular	Variable (paratrabecular, intertrabecular/interstitial, or intrasinusoidal/intravascular). Usually paratrabecular in non-Hodgkin lymphoma of follicular origin
Circumscription	Well defined (except HIV myelopathy)	Variable defined, frequent interstitial spread (“indian file pattern”)
Histomorphology	Polymorphous, predominance of small lymphocytes with uniform nuclear features, few admixed plasma cells, larger cells	Monomorphous, lymphocytes may show atypical morphology
Germinal centers	Occasionally present	Variable, may be present
Reticulin content	Minimal (except HIV myelopathy)	Moderate to marked
Immunohistochemistry	Polyclonal mixture of T and B lymphocytes, polyclonal immunoglobulin kappa and lambda light chain expression	Marked predominance of T or B lymphocytes, immunoglobulin light chain restriction in many B-cell lymphomas
Genotypic analysis by PCR	Lack clonality	Clonal T-cell or IgH gene rearrangements

interpretation of bone marrow biopsies (65,68). Morphologic discordance is particularly common in B-cell diffuse large cell lymphoma, where the bone marrow is “down graded,” or involved with lower grade lymphoma than the primary lesion (68,69). Discordant bone marrow involvement in DLCL is often paratrabecular, and may lead to incorrect diagnosis and treatment if correlation with lymph node histology is not available. A very careful inspection of the paratrabecular regions of every bone marrow biopsy is advised, since paratrabecular lymphoid infiltrates may be subtle or obscured by hypocellularity or fibrosis (68). Serial sectioning of the specimen may assist in difficult cases, as well as immunohistochemical staining with anti-CD20 and other B-cell markers.

### Nonhematopoietic tumors

The bone marrow is one of the most frequent sites of metastatic disease. In adults cancers of the lung, breast, and prostate most frequently metastasize to the bone marrow, while in children, neuroblastoma, rhabdomyosarcoma, medulloblastoma, and retinoblastoma are most frequently found in the bone marrow (70). In patients with cancer, bone marrow evaluation may be performed for staging or for the evaluation of anemia, thrombocytopenia, or other hematologic abnormalities. Occasionally, the tumor is initially identified from a bone marrow study. With the advent of immunohistochemistry and molecular assays such as the polymerase-chain reaction, there is increasing evidence in the identification of small numbers of isolated tumor cells in the bone marrow below the limit of detection by conventional histopathologic evaluation. Although these bone marrow “micrometastases” can be

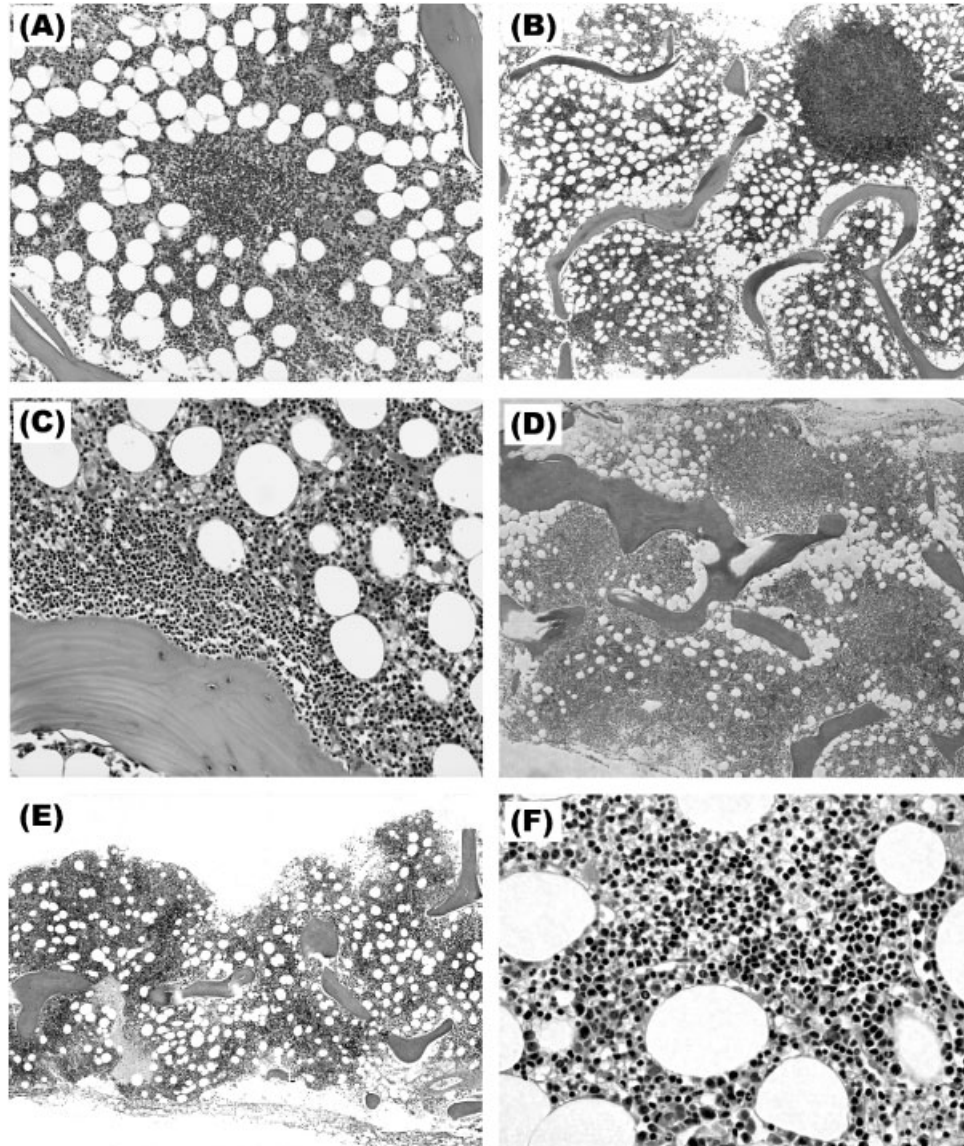
identified in 30–40% of patients with malignancy, their prognostic significance remains controversial (71–73).

Bone marrow specimen adequacy is an important practical factor in the detection of metastatic tumors, Hodgkin disease, and non-Hodgkin lymphoma. The trephine biopsy specimen should be at least 2 cm and mostly comprised of trabecular bone (70). Bilateral bone marrow samples should be obtained if possible, since many studies have indicated a high higher incidence of detection than with unilateral specimens (74–79). A bone marrow aspirate and biopsy touch imprint should be obtained if possible, since these specimens may preempt the biopsy findings and guide the use of special studies such as flow cytometry and fluorescence-in-situ hybridization (80). Rarely, a metastatic tumor may be present in the aspirated bone marrow and be absent from the biopsy core. Immunohistochemical staining of the bone marrow biopsy may be of great help in detecting small tumor foci not apparent in routine microscopic examination and confirming the diagnosis in suspicious cases.

### SPECIAL LABORATORY TECHNIQUES OF HEMATOLOGIC EVALUATION

There are many ancillary tests useful in hematopathology. The following are selected as special laboratory techniques that:

- Differentiate between benign and malignant processes.
- Determine the cell lineage (e.g., lymphocytes vs. myelocytes, T vs. B lymphocytes, myelocytes vs. monocytes, etc.).
- Provide some helpful prognostic parameters.



**Fig. 12.** Histopathology of bone marrow lymphoid aggregates. Photomicrographs of bone marrow biopsies of (A) Well defined intertrabecular lymphoid aggregate with benign histopathologic features (H&E stain, 100 x), (B) Discrete interstitial lymphoid aggregate in a patient with chronic lymphocytic leukemia (H&E stain, 40 x), (C) paratrabecular lymphoid aggregate in a patient with follicular lymphoma (H&E stain, 100 x), (D) Extensive diffuse and nodular involvement of the bone marrow by marginal zone lymphoma (H&E stain, 40 x), (E, F) Extensive interstitial involvement of the bone marrow by mantle cell lymphoma (H&E stains, 4 x, 400 x).

These techniques are not diagnostic by themselves, and should always be interpreted in light of the patient's clinical history and the morphological findings. They should be considered complementary to other investigations rather than "stand-alone" tests.

The bone marrow aspirate and biopsy, peripheral blood, and lymph node biopsies can be evaluated by techniques such as cytochemical stains, immunophenotypic analysis by flow cytometry or immunohistochemical staining, DNA ploidy and cell cycle analysis, cytogenetic analysis, and molecular techniques. Since these techniques are time consuming and expensive to

perform, selective use of these resources is necessary. Routine specimens should be examined and the clinical circumstances reviewed in order to determine the need for additional studies.

### Cytochemical Stains

Cytochemical stains, such as Sudan Black B, myeloperoxidase (MPO), specific and nonspecific esterases, periodic acid-Schiff (PAS), and acid phosphatase (AcP) were essential for the lineage determination of acute leukemia in the past. Recently, cytochemical stains have

TABLE 7. Applications of Common Techniques for Bone Marrow Analysis

Procedure	Specimen requirements <sup>a</sup>	Principal significance
Light microscopy	Wright–Giemsa-stained biopsy imprints and bone marrow aspirate smears H&E-stained sections of bone marrow biopsy and clot sections	Cell lineage, individual cell morphology, relative abundance of each cell type Marrow cellularity, megakaryocyte number, focal lesions
Special histologic stains (Prussian blue, Zeihl–Neelsen, Periodic-acid Schiff (PAS), Gordon–Sweet reticulin, trichrome, Congo red, Toluidine blue)	Unstained biopsy imprints and bone marrow aspirate smears, unstained sections of bone marrow biopsy and clot sections	Prussian blue: iron stores, ringed sideroblasts; Zeihl–Neelsen: acid-fast bacteria; GMS: fungi; PAS: erythroblasts, plasma cells, granulocytes; reticulin: reticulin fibers; trichrome: collagen fibrosis; Congo red: amyloid; Toluidine blue: mast cells
Cytochemical stains [PAS, Myeloperoxidase, Sudan Black B, Acid phosphatase, Acid phosphatase, tartarate resistant (TRAP), Naphthol AS-D chloroacetate esterase (NCAE), $\alpha$ -naphthyl butyrate esterase (ANBE)]	Unstained biopsy imprints and bone marrow aspirate smears	PAS: erythroblasts, plasma cells, granulocytes; myeloperoxidase: granulocytic precursors and mast cells; Sudan Black B: granulocytic precursors and mast cells; acid phosphatase: immature T lymphocytes (focal staining); TRAP: hairy cell leukemia; NCAE: granulocytic precursors and mast cells; ANBE: monocytes
Immunophenotypic analysis (flow cytometry, immunohistochemistry)	Flow cytometry: heparin-anticoagulated bone marrow aspirate; Immunohistochemistry: unstained biopsy imprints and bone marrow aspirate smears, unstained sections of bone marrow biopsy and clot sections	Cell surface or internal antigen detection with labeled antibodies for the diagnosis and classification of malignant hematopoietic diseases and detection of minimal residual disease
Karyotypic analysis	Heparin-anticoagulated peripheral blood or bone marrow aspirate	Chromosomal numerical and structural abnormality detection in cultured metaphase cells for diagnosis and prognosis
Molecular studies [Fluorescence in situ hybridization (FISH); Polymerase chain reaction (PCR)]	EDTA-anticoagulated peripheral blood or bone marrow aspirate	FISH: detection of chromosomal numerical and structural abnormalities in interphase or metaphase cells; PCR: sensitive detection of antigen receptor rearrangements or translocations specific to hematologic or lymphoid diseases
Microbiologic analysis	Sterile collection tubes	Detection of bacterial, viral, and fungal organisms through culture and other techniques
Chimerism	EDTA-anticoagulated bone marrow aspirate	Engraftment and minimal disease detection by analysis of donor and/or disease-specific molecular markers

<sup>a</sup>Specimen requirements vary at different laboratories, these are general guidelines only.

been superseded by flow cytometry and immunohistochemical staining.

Cytochemical stains detect enzymes or other intracellular substances. When the appropriate reagents are added to bone marrow aspirate smears, a color change is produced in the cells. The need for cytochemical analysis in individual bone marrow specimens is determined only after a Wright–Giemsa-stained marrow aspirate is reviewed by a pathologist. Extra smears are usually prepared from every bone marrow aspirate for this possibility. If marrow aspirate is unavailable and the peripheral blood is involved, cytochemical analysis can be performed on peripheral blood smears or cytopspins of body fluids. A summary of cytochemical stains and the

expected reactions with various cell types is shown in Table 8.

### Enzymatic cytochemical stains

#### *Myeloperoxidase*

MPO is an enzyme present in the azurophilic (nonspecific) granules of mature neutrophils and their granulated precursors (bands, metamyelocytes, myelocytes, and progranulocytes). Functionally, MPO plays an important role in cell activation (81). The assay is performed by incubating smears fixed in a glutaraldehyde/acetone solution with 3-amino-9-ethylcarbazole and hydrogen peroxide (H<sub>2</sub>O<sub>2</sub>). Neutrophilic granules

TABLE 8. Expected Reactions of Cytochemical Stains

Cell type	Sudan Black B	Peroxidase	Specific esterase	Nonspecific esterase	PAS	Acid phosphatase
Immature neutrophils	Faintly +	Strongly +	Strongly +	- To faintly +	+	+
Mature neutrophils	Strongly +	Strongly +	Strongly +	- To faintly +	+ (>Immature)	+
Eosinophils	+	Strongly +	Strongly +	- To faintly +	+	+
Monocytes	- To faintly +	Faintly +	- To faintly +	Strongly +	Faintly +	Strongly +
Lymphocytes	-	-	-	-	- To faintly +	B - T +
Erythroid cells	-	-	-	-	-	-

exhibit a dark brown color that increases with the maturity of the cell (Fig. 14). Eosinophilic granules show a yellowish color (MPO-e), monocytes exhibit a weak, diffuse cytoplasmic reaction with a few brown cytoplasmic granules, and cells of the lymphoid and megakaryocytic lineages are negative. Since MPO is a labile enzyme, staining activity decreases with aging of the smears. Optimal enzyme activity is obtained with smears that are immediately air-dried and stained within three days after preparation. The enzyme reaction is dependent on the optimal  $H_2O_2$  concentration; artifactual nuclear staining indicates a suboptimal  $H_2O_2$  concentration, while brown staining of erythrocytes and weak staining of neutrophils indicates excess  $H_2O_2$  (82).

The primary use of the MPO stain is to differentiate myeloblasts from lymphoblasts. A dual staining technique for MPO-e and Naphthol AS-D chloroacetate esterase (NACE) is available to detect the abnormal, NACE-positive eosinophils of the AML-M4Eo subtype subtype of acute myelomonocytic leukemia and the doubly positive cytoplasmic granules of the abnormal progranulocytes of AML-M3. Cytochemical stains for MPO are rarely used today, with the recent availability of an immunoperoxidase stain that can be used in deparaffinized tissue sections as well as smear preparations.

#### *Specific and nonspecific esterases*

Leukocyte esterases are enzymes that hydrolyze esters. Cytochemical stains for esterases use ester derivatives of naphthalene that liberate brightly colored naphthol (or naphthyl) compounds at the site of enzyme reactivity. Nonspecific esterases are characteristic of cells of monocytic lineage, while specific esterases are found in granulocytes.

The cytochemical assay for specific esterase uses NACE as the substrate. An intense brick red color is characteristic of mature neutrophils and their granulated precursors, as well as Auer rods and tissue mast cells. Eosinophils are negative, with the exception of the NACE-positive eosinophils in AML-M4-Eo. Circulating basophils are negative, while monocytes may exhibit a delicate weak granular pattern. Specific esterase is

more specific but less sensitive than MPO and Sudan Black B for myeloid cell, but can be useful in differentiating cells of the granulocytic lineage from those of monocytic lineage. In addition, since neutrophil esterase is resistant to decalcification, tissue fixation, and paraffin embedding, the cytochemical stain can be performed on deparaffinized bone marrow biopsy or tissue sections (82).

Cytochemical assays for nonspecific esterases detect various esterase and lipase enzymes that differ in cell and organelle specificity, substrate requirements, and resistance to inhibitors. Two different substrates,  $\alpha$ -naphthyl acetate esterase (ANAE) and  $\alpha$ -naphthyl butyrate esterase (ANBE), are commonly used as substrates in the clinical laboratory. Cytochemical stains for nonspecific esterases can be performed on both fixed smears and cytopins, as well as deparaffinized tissue sections. Generally, the ANAE and ANBE substrates produce similar results, with the exception that the esterase of platelets and megakaryocytes can only be detected with ANAE (82). Monocyte esterase is selectively inhibited by the addition of sodium fluoride. Some lymphocytes, mostly mature T-helper lymphocytes and Sezary cells, show focal esterase activity that is optimally visualized at an acid pH. Lymphocyte esterase is generally limited to the Gall bodies, lysosomes that hydrolyze esterified cholesterol taken up by receptor-mediated endocytosis of low-density lipoproteins (82).

The nonspecific esterase stains were commonly used in the past for the diagnosis of acute myelogenous leukemias with monocytic differentiation (FAB types M4 and M5). This has largely been replaced by the use of flow cytometry.

#### *Acid phosphatase*

AcP is an ubiquitous enzyme that exists in five isoenzyme forms. The cytochemical assay for AcP is based on the reaction of AcP with a naphthol derivative, resulting in the generation of naphthol that then reacts with an aniline dye to produce a colored reddish or reddish-purple product at the site of AcP reactivity.

AcP is present in most leukocytes, with the highest activity in monocytes, macrophages, plasma cells, megakaryocytes, and platelets. However, in contrast to

the diffuse cytoplasmic activity of these cells, AcP activity in the erythroblast and immature T lymphocyte is confined to the Golgi zone, resulting in a prominent paranuclear staining focus. Therefore, AcP activity is helpful in the differentiation between precursor T-cell and precursor B-cell acute lymphoblastic leukemia, where T cells are positive and B cells are negative for AcP reactivity.

Among hematopoietic cells, AcP isoenzyme 5 is restricted to the cells of hairy cell leukemia (HCL) and is unique in its inability to be inhibited by tartaric acid (tartrate-resistant acid phosphatase, TRAP). Therefore, the "TRAP" stain is helpful if the diagnostic confirmation of HCL, although a small proportion of cases are negative.

#### *Leukocyte alkaline phosphatase (LAP)*

LAP (neutrophil alkaline phosphatase, NAP) activity increases with maturation of the neutrophil. Further increases in activity occur during infections and inflammatory states, pregnancy, following treatment with hematopoietic growth factors, such as G-CSF and GM-CSF, and in some disease states, such as Hodgkin disease, myelofibrosis, and essential thrombocythemia. LAP activity is significantly decreased in a few disease states, including chronic myelogenous leukemia (CML), acute myelogenous leukemia, paroxysmal nocturnal hemoglobinuria, hereditary hypophosphatasia, and the myelodysplastic syndromes (83,84). Until the recent advent of the rapid RT-PCR assay for bcr-abl, LAP was performed to differentiate CML from a benign leukemoid reaction. The assay is usually performed on smears prepared from heparin-anticoagulated peripheral blood, using  $\alpha$ -naphthyl phosphate disodium salt as the substrate (85,86). The assay is subjectively graded by assigning a score between 0 (no staining) and 4 (heavy staining) to one hundred neutrophils and totaling the individual scores. A score between 50 and 150 is characteristic of normal peripheral blood, while peripheral blood from patients with CML usually have a score of less than 10. Because of the subjective and labor-intensive nature of the assay, it is justifiably no longer available from many hematology laboratories. Quantitative measurement of LAP by flow cytometry has been described, but has not achieved routine clinical use due to the more sensitive and specific molecular technique of t(9;22) analysis (87).

#### Nonenzymatic cytochemical stains

##### *Sudan Black B*

Sudan Black B stains certain phospholipids and sterols. Both the azurophilic (nonspecific) and specific granules of the granulocytic cell line produce a positive

black reaction. Since Sudan Black B produces a negative result in cells of lymphoid lineage, the assay is primarily used to differentiate acute myelogenous leukemia from acute leukemia of lymphoid origin. The reactivity and sensitivity of Sudan Black B is similar to MPO, but it is often preferred by many hematology laboratories, since it is much easier and faster to perform and does not fade with time. It is more sensitive but less specific than MPO for identifying acute myelogenous leukemia.

##### *Periodic acid-Schiff*

The PAS stain is based on the reaction of periodic acid with carbohydrates (i.e., polysaccharides and mucopolysaccharides) and glycoproteins to produce a reddish product. The stain is performed by incubating smears or deparaffinized tissue sections sequentially in a periodic acid solution and then Schiff's reagent (a solution of *p*-rosaniline, hydrochloric acid, and sodium metabisulphite in distilled water), followed by rinsing in sulphurous acid (82).

In blood cells, a positive PAS reaction usually indicates the presence of glycogen. Glycogen is present in mature neutrophils and monocytes, mature megakaryocytes, and platelets. An intense PAS reaction may result from the abnormal glycogen stores in the erythroblasts of acute erythroleukemia (AML-M6) and in the lymphoid cells of some patients with chronic lymphocytic leukemia (CLL), Sezary cell leukemia, and acute lymphoblastic leukemia. The PAS reaction in erythroleukemia cells is often described as "chunky," while abnormal lymphocytes contain a coarse, granular "string of pearls" around the nucleus.

A positive PAS reaction may result from abnormal stores of glycosylated immunoglobulins in plasmacytoid diseases, including intracytoplasmic Russell bodies and the intranuclear Dutcher-Fahey bodies of Waldenstrom's macroglobulinemia. Mucoproteins are responsible for a positive PAS reaction in progranulocytes and the abnormal eosinophils of AML-M4-Eo (82).

##### *Toluidine blue O*

Toluidine blue O is a dye used for the identification of basophils and mast cells on smears or in deparaffinized tissue sections. These cells are unique for their cytoplasmic granules containing high concentrations of heparin and histamine. Toluidine blue stains these cells metachromatically, meaning that the tissue components stain a different color than the dye, depending on the dye concentration, pH, and temperature. Mast cells usually exhibit reddish-purple granules (metachromatic staining), while the background stains blue (orthochromatic staining).

## Immunophenotypic Analysis of Hematologic Diseases

The identification and quantitation of cellular antigens with fluorochrome-labeled antibodies (e.g., immunophenotypic analysis) is one of the most important medical developments of the past two decades (88–90). Immunophenotypic analysis is critical to the initial diagnosis and classification of the acute leukemias, chronic lymphoproliferative diseases, and malignant lymphomas since treatment strategy often depends upon antigenic parameters. In addition, immunophenotypic analysis provides prognostic information not available by other techniques, provides a sensitive means to monitor the progress of patients after chemotherapy or bone marrow transplantation, and often permits the detection of minimal residual disease (MRD) (91). The analysis of apoptosis, multidrug resistance, leukemia-specific chimeric proteins, cytokine receptors, and other parameters may provide additional diagnostic or prognostic information in the near future.

### Basic principles of immunophenotypic analysis

In the late 1970s, the rapid development of monoclonal antibodies and the multiple commercial sources providing these antibodies led to similar antibodies marketed under a multitude of trade names and designations. The confusion prompted a series of International Workshops on Human Leukocyte Differentiation Antigens (HLDA Workshops), sponsored by the World Health Organization. At the first six workshops, the reactivity of different monoclonal antibody preparations was compared. Antibodies with similar antigenic reactivity were assigned to “clusters,” and a “cluster designation (CD)” was assigned to each group. The most recent workshop was held in Adelaide, Australia in December 2004, where “Human Leukocyte Differentiation Antigens” was succeeded by “Human Cell Differentiation Molecules” or “HCDM.” At these workshops, consensus was reached on 339 clusters of reactivity (“CD1–CD339”). Classification of the CD antigens is difficult, since most are not lineage specific, and several are widely expressed on various cell types. The antibodies most commonly used in diagnostic hematopathology are briefly described below. Additional information about each cluster of differentiation can be found at “Protein Reviews on the Web,” a web site maintained by the National Cancer Institute, and in numerous books and literature reviews (92–98).

Immunophenotypic analysis by flow cytometry or immunohistochemical staining is capable of determining the lineage of neoplastic cells in most hematologic malignancies (99,100). However, a thorough under-

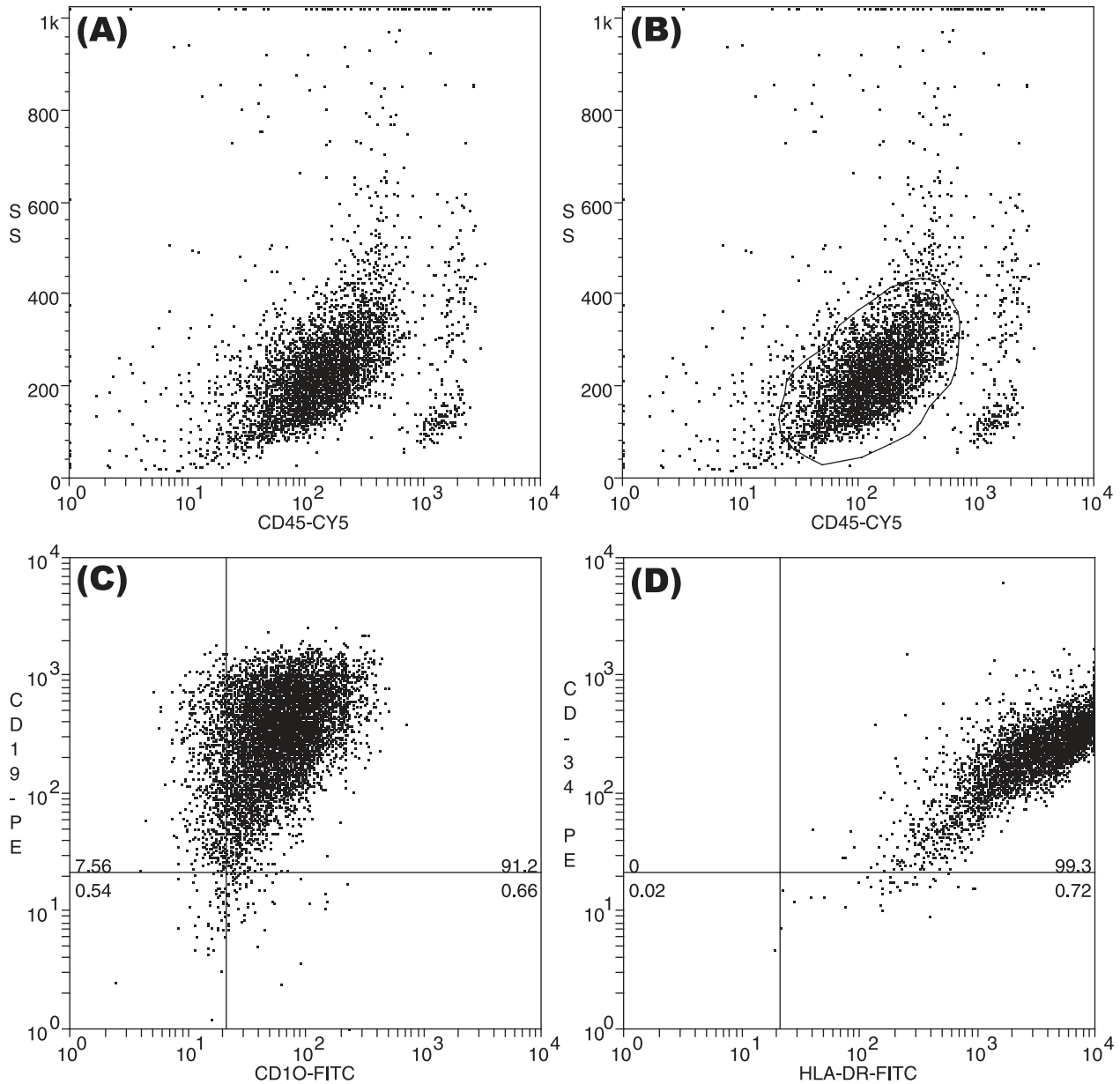
standing of the advantages and disadvantages of each technique is necessary for the optimal application of this technology and the proper interpretation of the results. Immunohistochemistry is a slide-based technique preferred when cellular antigen expression must be interpreted in the context of cell morphology and/or tissue architecture. Although the single-cell suspension required for flow cytometric analysis disrupts tissue architecture, the flow cytometer permits the rapid analysis of large numbers of cells for multiple cell properties, including cell size, granularity, surface and intracellular antigens, and DNA content (101,102).

Immunophenotypic data must only be interpreted in the context of morphologic findings and other clinical and laboratory data. A panel of antibodies is usually required for the analysis of most hematologic specimens, since each HCDM antigen has a unique pattern of cell expression that is rarely used alone. For example, to establish monoclonality, a pan-B-cell panel usually includes CD19, CD20, and CD22, while a pan-T-cell panel incorporates CD2, CD3, CD4, and/or CD7. Additional antibody panels may become necessary to establish a specific diagnosis. To provide rapid, cost-effective analysis, the antibody panel must be carefully selected. Most hematology laboratories have “panels” of chosen antibodies for different purposes, such as leukemia, lymphoma, or myeloma diagnosis, or the detection of MRD.

### Flow cytometric immunophenotypic analysis

Flow cytometry is a technique of quantitative single-cell analysis. The flow cytometer was developed in the 1970s and rapidly became an essential instrument for the biologic sciences. Spurred by the HIV pandemic and a plethora of discoveries in hematology, special flow cytometers for the clinical laboratory were developed by several manufacturers. The major clinical application for the flow cytometer is the diagnosis of hematologic malignancy, but the instrument has found various other applications in various laboratories. A recent trend is to develop specialized flow cytometers for specific purposes, such as reticulocyte enumeration, and to incorporate flow cytometric technology into other forms of laboratory instrumentation. This brief review of the principles and major clinical applications of flow cytometry may be supplemented by several recent review articles and books (103–107).

The flow cytometer is an instrument for the “... bringing of suspended cells one by one to a detector by means of a flow channel (108).” Prepared single-cell suspensions labeled with three to five monoclonal antibodies tagged with different fluorescent dyes are necessary for flow cytometric analysis. The flow



**Fig. 13.** Flow cytometric data analysis. Data analysis requires selection of the cell population(s) or interest, followed by determination of the proportion of positive cells for each antigen studied in each population. Typically, forward vs. side scatter or CD45 vs. side scatter are used to identify the cell population(s) of interest. **(A)** “Dot plot” two-dimensional histogram of a bone marrow aspirate from a child with precursor B-cell lymphoblastic leukemia/lymphoma, showing a discrete cell population with decreased CD45 expression and variable side scatter. The bone marrow predominately consists of blast cells and lymphocytes. This type histogram is usually used for leukemia analysis, since leukemic blast cell usually show decreased CD45 expression, and appear in a region of the histogram where few other cells are present. **(B)** A “gate” has been drawn around the blast cells, to restrict analysis to this cell population. **(C)** The gated blast cells have been analyzed for CD10 (x-axis) and CD19 (y-axis). The blasts show bright expression of CD10 and CD19, typical of childhood ALL, **(A)** The blast cells have been analyzed for HLA-DR (x-axis) and CD34 (y-axis).

cytometer uses a narrow, confined fluid stream to transport individual cells into a focused light beam of high intensity. A series of optico-electronic detectors pick up and amplify the signal produced during the interaction of the light beam with the cell. The resulting electrical pulses are digitized, and the data is stored,

analyzed, and displayed through a computer system (107,109). The end result is quantitative information about every cell that was analyzed (Fig. 13). Since large numbers of cells can be analyzed in a short period of time (>1,000/sec), statistically valid information about cell populations can be quickly obtained. The present



“state-of-the art” flow cytometers are capable of analyzing up to 13 parameters (forward scatter, side scatter, and 11 colors of immunofluorescence) per cell at rates up to 100,000 cells per second. Automation and robotics is increasingly being applied to flow cytometry to reduce analytic cost and improve efficiency.

### *Immunohistochemistry*

Immunohistochemistry (immunocytochemistry and immunostaining) is a slide-based technique of antibody analysis used for the demonstration of antigens in cells or tissues. This technique can be performed on smears, cytospins, tissue imprints, frozen, or fixed tissue sections (110). Although quantitative single-cell analysis cannot be obtained by routine immunostaining techniques, morphologic examination can be performed and the structural integrity of the cells and tissues is retained. In addition, nuclear and cytoplasmic antigens are easily evaluated by immunostaining, in contrast to flow cytometry, which is best suited to the analysis of cell surface antigens. However, a major drawback of immunohistochemical detection of monoclonality, especially in B-cell lymphoproliferative disorders is the lack of contrast between surface immunoglobulin staining and extracellular immunoglobulin staining (101).

An indirect avidin–biotin staining technique has been widely used for diagnostic immunohistochemistry, although more advanced detection systems using a streptavidin–biotin complex, alkaline phosphatase anti-alkaline phosphatase, or biotinylated tyramine complex are becoming more widely used. Since tissue fixation may “mask” antigenic recognition, antigen retrieval using heat and/or proteolytic enzymes may be necessary to demonstrate the presence of some substances (67).

### Cellular antigens in diagnostic hematopathology

Various monoclonal antibodies against cellular antigens are available for the immunophenotypic analysis of hematologic diseases (Table 7). Monoclonal antibodies against leukocyte common antigen (CD45) help to differentiate hematologic malignancies from other neoplasms. CD45 also differentiates populations of blast cells for further analysis, since almost all leukemias show decreased (dim) CD45 expression compared with normal leukocytes. The CD34 and HLA-DR antigens are markers for hematopoietic stem cells used for the diagnosis of acute leukemia and quality assurance in bone marrow transplantation. Since most of the remaining leukocyte surface antigens are lineage associated, but not specific to a single lineage or stage of cellular maturation, a panel of monoclonal antibodies is commonly used in clinical diagnosis. Several antigens

expressed in the cell cytoplasm, such as cytoplasmic CD3 (cyCD3), cytoplasmic CD22 (cyCD22), and MPO are lineage specific, but the analysis of cytoplasmic antigens by flow cytometry is technically difficult and not routinely used at this time in the clinical laboratory (Table 9).

At the HLDA Workshops antigenic molecules were assigned to major subgroups (i.e., T-cell, B-cell, NK-cell, myeloid, erythroid, platelet, endothelial cell, adhesion structure, cytokine receptor, and nonlineage) based on their principal pattern of expression (111). However, the major diagnostic application of the corresponding monoclonal antibodies in hematology does not follow this categorization, and a more practical classification by primary application is followed below.

### *Antigens with multi-lineage diagnostic applications*

**CD45:** The leukocyte common antigens (LCA, T-200, HLe-1, T29/33, BMAC1) comprise a family of at least six antigens that are strongly expressed by nucleated cells of hematopoietic origin, but are absent from most other tissues (112,113). Functionally, CD45 plays a central role in classical antigen receptor signal transduction, including both positive and negative regulation of signalling through the activation of the Src family of tyrosine kinases (114,115). CD45 also functions as a Janus kinase PTPase to modulates signals originating from integrin and cytokine receptors and plays a role in lymphocyte development (113,116).

CD45 is expressed on all nucleated leukocytes in the peripheral blood, peripheral and central lymphoid organs, and bone marrow (117,118). CD45 is present very early in erythroid development, but it is subsequently lost during development. CD45 is not present on circulating erythrocytes or platelets.

Since antigens in the CD45 family are among the few membrane components uniquely expressed on hematopoietic cells, anti-CD45 antibodies have been useful in studies of hematopoiesis, and in the clinical differentiation of poorly differentiated hematopoietic neoplasms from carcinomas and sarcomas. In flow cytometry, anti-CD45 monoclonal antibodies are routinely used in quality control, and in the differentiation of functional T-lymphocyte helper subsets (119–123).

**TdT:** Terminal deoxynucleotidyltransferase (TdT) is a primer-dependent DNA polymerase found in the nuclei of T- and B-cell progenitor cells. TdT can be detected by cytochemical staining, immunofluorescent microscopy, flow cytometry, immunohistochemistry, or by more sensitive molecular techniques such as RT-PCR (124). Since the expression of TdT is restricted to immature T and B cells, it is critical for the diagnosis of precursor T and precursor B acute lymphoblastic leukemia/lymphoma.

TABLE 9. Characteristics of Human Cell Differentiation Antigens for Hematologic Diagnosis

Antigen	Normal cellular expression	Major diagnostic application	Biological function	Other names
Anaplastic lymphoma-associated kinase protein	Epithelial cells, some plasma cells, HD, ALCL	Anaplastic large cell lymphoma		ALK, Ki-1
Bcl-2 protein	T and B lymphocytes	B-cell malignancies with t(14;18)(q32;q21) translocation; most follicular lymphomas, some diffuse large cell lymphomas	Integral protein in endoplasmic reticulum, mitochondrial membrane and nuclear envelope; suppresses apoptosis by caspase inhibition	B-cell leukemia/lymphoma 2
Bcl-6 protein	normal germinal center T and B cells, skeletal muscle cells, keratinocytes	B-cell malignancies with 3q27 rearrangements/aberrations (follicular lymphomas, diffuse large B cell lymphomas, Burkitt's lymphomas and in nodular, lymphocyte predominant Hodgkin's disease Precursor T cell ALL and some lymphoblastic lymphomas	Zinc finger transcription factor, modulate the transcription of START-dependent IL-4 responses of B cells, regulation of the Th2 inflammatory response	B-cell leukemia/lymphoma 6, Zinc Finger Protein 51
CD1a	Cortical thymocytes, dendritic reticular cells, Langerhans cells		MHC class I-like molecule, associated with $\beta$ -2-microglobulin. May have specialized role in antigen presentation, including delivery of signals for lymphocyte activation. Postulated role in thymic T-cell development	T6, Leu6
CD2	T cells, thymocytes, NK cells	Hematopoietic neoplasms of T-cell lineage	Sheep erythrocyte rosette receptor. LFA-3 (CD58) ligand. Adhesion molecule, can activate T cells	T11, Leu5b, 9.6
CD3	T cells, thymocytes	Hematopoietic neoplasms of T-cell lineage	Associated with the T cell antigen receptor. Required for cell surface expression of and signal transduction by TCR	T3, Leu4
CD4	Thymocyte subsets, helper and inflammatory T cells, monocytes, macrophages	Sezary cell leukemia and some hematopoietic neoplasms of T cell lineage	Coreceptor for MHC class II molecules. Binds Ick on cytoplasmic face of membrane. Receptor for HIV-1 and HIV-2 gp120	T4, Leu-3a
CD5	T cells, thymocytes, B-cell subset	B-CLL and most hematopoietic neoplasms of T cell lineage	CD72 ligand Signal transduction through antigen-specific receptor complex. T cell activation, T- and NK-cell activation	T1, Leu1, TI01, 10.2
CD7	Pluripotential hematopoietic cells, thymocytes, major T-cell subset, NK cells, early myeloid cells,	Hematopoietic neoplasms of T-cell lineage		Leu9, 3A1, WT 1
CD8	Cytotoxic T cells, thymocyte subsets, NK cells			
CD10	Early B lymphocytes, PMNs B- and T-cell precursors, bone marrow stromal cells	Precursor B cell ALL and non-Hodgkin lymphomas of follicular cell center origin	Coreceptor for MHC class I molecules. Binds Ick on cytoplasmic face of membrane. Regulates function of CD3/TCR complex	T8, Leu2a
CD11b	Monocytes, granulocytes, NK cells	Myelomonocytic leukemias, particularly of FAB M4 and M5 subclasses	CALLA. Zinc metalloproteinase. Neutral endopeptidase	CALLA, J5
CD11c	Myeloid cells, monocytes	Hairy cell leukemia and related hematopoietic neoplasms	Mac-1. Cell adhesion molecule. Subunit of integrin CR3 (associated with CD18). Binds CD54, complement component iC3b and extracellular matrix proteins	MAC-1, CR1, Mo1, OKM1
CD13	Myelomonocytic cells	Leukemias of myeloid lineage	Cell adhesion molecule. Subunit of integrin CR3 (associated with CD18). Binds fibrinogen Zinc metalloproteinase. Aminopeptidase N,	Leu-M5 My7, LeuM7

CD14	Myelomonocytic cells	Myelomonocytic leukemias, particularly of FAB M4 and M5 subclasses	Receptor for complex of LPS and LPS binding protein (LBP)	LeuM3, Mo2, My4
CD15	Granulocytes, monocytes, endothelial cells	Hodgkin's lymphoma, other hematopoietic neoplasms	Lewis-x (Lex) antigen. Branched pentasaccharide, expressed on glycolipids and many cell surface glycoproteins. Sialylated form is a ligand for CD62E (ELAM)	Leu M1, My1
CD16	NK cells, granulocytes, macrophages	Hematopoietic neoplasms of NK-cell lineage	FcγRIII. Component of low affinity Fc receptor (FcγRIII). Mediates phagocytosis and ADCC	OKNK, Leu-11a,b,c
CD19	Pan B-cell antigen	Precursor B cell ALL and non-Hodgkin lymphoma of B-cell lineage	Forms complex with CD21 (CR2) and CD81 (TAPA-1). Coreceptor for B cells. Regulation of B-cell activation	B4, Leu12
CD20	B-cell antigen	Precursor B-cell ALL and non-Hodgkin lymphoma of B-cell lineage	Ca <sup>++</sup> channel, B cell activation?	B1, Leu16
CD21	Mature B cells, follicular dendritic cell	Leukemia and lymphoma diagnosis	C3d/EBV-receptor (CR2). Coreceptor for B cells (with CD19 and CD81)	B2, CR2
CD22	Mature B cells	Leukemia and lymphoma diagnosis. Cytoplasmic CD22 is B cell lineage-specific antigen	Cell adhesion molecule. Ig-mediated adhesion of B cells to monocytes, T cells	B3, Leu14, SHC11
CD23	Activated B cells, activated macrophages, eosinophils, follicular dendritic cells, platelets	Leukemia and lymphoma diagnosis	Low affinity receptor for IgE (FcεRII). Ligand for CD19;CD21;CD81 coreceptor	Leu-20, B6
CD24	B cells, granulocytes	Leukemia and lymphoma diagnosis	Possible human homologue of mouse Heat Stable Antigen (HSA) or J11d	BA-1
CD25	Activated T cells, activated B cells, monocytes	Hairy cell leukemia, ATL/L, other hematopoietic neoplasms	Tac. Interleukin 2 receptor α chain	TAC
CD30	Activated B and T cells	Hodgkin's lymphoma, anaplastic large cell lymphoma	Ki-1. Growth factor receptor	Ki-1, Ber-H2
CD33	Myeloid cells myeloid progenitor cells, monocytes	Leukemias of myeloid lineage	Sialic acid adhesion molecule	My9, LeuM9, L4F3
CD34	Hematopoietic precursors, capillary endothelium	Leukemias of early myeloid lineage, lymphoblastic lymphoma	Ligand for CD62 (L-selectin)	HPCA-2, My10
CD36	Platelets, mature monocytes and endothelial cells, mammary endothelial cells, during stages of erythroid cell development and on some macrophage derived dendritic cells	Erythroleukemia (AML, FAB-M6). Reticulocyte pathophysiology	Glycoprotein IV. Cell adhesion molecule in platelet adhesion and aggregation, platelet-monocyte and platelet-tumor cell interaction. Scavenger receptor for oxidized LDL and shed photoreceptor outer segments. Recognition and phagocytosis of apoptotic cells. Cytoadherence of Plasmodium falciparum-infected erythrocytes	FA6-152
CD38	Early B and T cells, activated T cells, germinal center B cells, plasma cells	Plasma cell dyscrasias, some non-Hodgkin's lymphomas	Leukocyte activation	Leu17, T10
CD41	Megakaryocytes, platelets	Acute leukemia of megakaryocytic lineage (AML, FAB-M7)	aIIb integrin. Associates with CD61 to form GPIIb. Binds fibrinogen, fibronectin, von Willebrand factor and thrombospondin	GpIIb/IIIa, PL-273

TABLE 9. Continued.

CD42b	Megakaryocytes, platelets	Acute leukemia of megakaryocytic origin (AML, FAB-M7)	gpIb, vWF receptor. Binds von Willebrand factor and thrombin Essential for platelet adhesion	GpIb, FMC-25
CD43	T cells, myeloid cells, some B cell lymphomas	Some T-cell lymphoproliferative diseases	Leukosialin, sialophorin. binds CD54 (ICAM-1)	Leu22
CD45	Panhematopoietic	All hematopoietic neoplasms	Leukocyte common antigen. Tyrosine phosphatase, augments signalling through antigen receptor of B and T cells	T200, LCA
CD45RA	B cells, T cell subsets (naive T cells), monocytes, plasmacytoid dendritic cells	Leukemia and lymphoma diagnosis	220 kDa isoform of CD45 antigen	2H4
CD45RO	T cell subsets, B cell subsets, monocytes, macrophages	Leukemia and lymphoma diagnosis	isoform of CD45 containing none of the A, B and C exons	UCHL-1
CD55	Widespread cellular distribution, hematopoietic and non-hematopoietic cells	Paroxysmal nocturnal hemoglobinuria (PNH)	Decay Accelerating Factor (DAF). Complement activation inhibitor. Binds C3b, disassembles C3/C5 convertase	DAF
CD56	NK cells	Hematopoietic neoplasms of NK-cell lineage	NKH-1. Cell adhesion molecule. Isoform of Neural Cell Adhesion Molecule (NCAM)	NKH-1, Leu19, N-CAM
CD57	NK cells NK cells subsets of T cells, B cells and monocytes	Hematopoietic neoplasms of NK-cell and T-cell lineage	HNK-1. Oligosaccharide, found on many cell surface glycoproteins	HNK-1, Leu7
CD59	Many hematopoietic cells	Paroxysmal nocturnal hemoglobinuria (PNH)	Protectin, Mac inhibitor. Complement inhibitor.	MIRL
CD61	Megakaryocyte platelets, megakaryocytes, macrophages	Acute leukemia of megakaryocytic origin (AML, FAB-M7)	Binds complement components C8 and C9 to block assembly of membrane attack complex	Pt GPIIIa, 10-P61, Y2/51
CD79a	B cells (lineage specific)	Hematopoietic neoplasms of B-cell lineage	Components of B cell antigen receptor, required for cell surface expression and signal transduction	Mb-1
CD95	Widespread distribution	Hodgkin lymphoma (Reed-Sternberg cells), low-grade B-cell lymphomas (follicle center lymphomas, extranodal marginal zone lymphomas, and immunocytomas)	Apo-1, Fas, TNF-like ligand. Transmits apoptosis signal	APO-1, Fas
CD103	Intestinal epithelial lymphocytes Intraepithelial lymphocytes, 2-6% of peripheral blood lymphocytes	Enteropathy-associated T-cell lymphoma, hairy cell leukemia, HTLV-1 associated adult T-cell leukemias	Epithelial cell-specific integrin, $\alpha$ human mucosal lymphocyte antigen, E integrin	HML-1
CD117	Blast cells of myeloid lineage, mast cells	Acute myeloid leukemias	c-kit. Stem Cell Factor (SCF) receptor. Critical for stem cell survival and progenitor cell replication/differentiation	17F11, 95C3, YB5.BB
CD138	Plasma cells, pre-B cells, endothelial cells, some epithelial cells	Plasma cell dyscrasias	Cell adhesion, extracellular matrix receptor	Syndecan
CD235	Erythrocytes, erythroid precursors	Erythroleukemia (AML, FAB-M6), identification of erythroid progenitors	Component of erythrocyte membrane	Glycophorin A, 10F7
Cyclin D1	Proliferating cells	Mantle cell lymphoma diagnosis (bcl-1 rearrangement)	Proto-oncogene, regulator of G1 to S-phase transition	PRAD1 oncogene, BCL-1 oncogene
DBA-44	B-cell subset, mantle zone cells, immunoblasts, erythrocyte membranes, macrophages	Hairy cell leukemia diagnosis	B-cell membrane antigen, unknown function	Hairy cell leukemia antigen

Epithelial membrane antigen	Glandular epithelial cells, monocytes, monoblasts, plasma cells, anaplastic large cell lymphoma, malignant histiocytosis and erythroleukaemia	Anaplastic large cell lymphoma, diagnosis of metastatic tumors	Unknown	EMA, CA15-3, Polymorphic Epithelial Mucin, PEM, Sialomucin or Episialin and MUC-1
Fascin	Dendritic cells, Reed-Sternberg cells and variants	Classic Hodgkin lymphoma	Actin cross-linking	Fascin homolog 1, actin-bundling protein, singed-like protein, 55 kDa actin-bundling protein, p55
FM7	Differentiated B-cell subset	Chronic B-cell lymphoproliferative diseases	Possible cell membrane calcium channel	None
HLA-DR	B cells, monocytes, activated T cells, myeloid precursors	Hematopoietic neoplasms	HLA Class II receptor	HLA-DR. Ia
Ki-67 protein	Proliferating cells	Marker of cell proliferation, tumor growth and prognostic marker in some malignancies	Nuclear antigen expressed in cycling cells	Ki-67, MIB-1
Myeloperoxidase	Neutrophilic myeloid cells	Acute leukemia classification, diagnosis of extramedullary leukemia (chloroma)	Peroxidase enzyme component of lysozyme	MPO
PAX-5 Protein	B lymphocytes, pro-B, pre-B and mature B lymphocytes, some neural cells, testicular epithelial cells	B-lymphocyte marker	Cell differentiation, signal transduction; gene deregulation and overexpression in small lymphocytic lymphomas with plasmacytoid differentiation, a t(9;14)(p13;q32) translocation	B-cell lineage specific activator protein (BSAP)
Spectrin	Erythrocytes, erythroid precursors	Erythroleukemia (AML, FAB-M6), identification of erythroid progenitors	Component of erythrocyte membrane	Calspectin; brain actin-binding protein (BABP)
Tartrate-resistant acid phosphatase	Hairy cells, mast cells, Langerhan cells, osteoclasts, macrophages, neurons	Hairy cell leukemia diagnosis	Metalloenzyme, precise function unknown	TRAP
TdT	Lymphoblasts, thymocytes, myeloblast subset	Acute leukemia and lymphoblastic lymphoma	DNA polymerase	Terminal Deoxynucleotidyl Transferase, terminal transferase
Tryptase	Mast cells, basophils	Mast cell disease	Serine proteinase, mast cell antigen	mast cell tryptase 2, mmcp-7, human mast cell tryptase, mast cell protease 7, mast cell tryptase, granzyme k

Data from Protein Reviews on the Web. CD MOLECULES. Human cell surface molecules recognized by the International Workshops on Human Leukocyte Differentiation Antigens. <http://www.ncbi.nlm.nih.gov/PROW/guide/45277084.htm>

TdT expression is found in more than >90% of cases of acute lymphoblastic leukemia, and in fewer than 5% of acute leukemias classified as AML by the expression of other markers (125). However, TdT is expressed in a small proportion of normal bone marrow lymphoid precursors (“hematogones”) in pediatric bone marrow and during bone marrow reconstitution following chemotherapy or bone marrow transplantation. Therefore, other morphologic, immunophenotypic, and molecular parameters must be used for the diagnosis of residual and relapse leukemia (126). In precursor B-cell ALL the lack of TdT expression has been correlated with a high white blood cell count, the mixed lineage leukemia gene rearrangement, and a lack of expression of CD10 and CD34 (127).

**CD43:** The CD43 molecule (leukocyte sialoglycoprotein, leukosialin, sialophorin, LSGP, gp115) is a highly sialylated glycoprotein with a molecular weight of 95 kDa (128). The CD43 molecule is expressed on most leukocytes, excluding resting peripheral blood B cells and myeloid cells. In fixed, paraffin-embedded tissue, CD43 is expressed most strongly on T lymphocytes. The use of anti-CD43 monoclonal antibodies for the diagnosis and classification of lymphoproliferative diseases is limited by their broad immunoreactivity (129–131).

#### *Antibodies specific for T-lineage differentiation antigens*

**CD1:** Monoclonal antibodies in the CD1 cluster define four distinct isoforms (CD1a, CD1b, CD1c, CD1d) (132–135). CD1 antigens mediate a novel, non-MHC form of innate and adaptive immune recognition specific for nonprotein antigens, including lipids and glycolipids (136,137). Expression of the CD1 molecule by early T lymphocytes defines the common thymocyte stage of differentiation (Stage II). CD1 isoforms are expressed by approximately 80% of thymocytes (essentially restricted to the cortex), Langerhan’s and dendritic cells in the skin, and specific cells in lymph nodes, and other tissues. In addition, CD1 is expressed on approximately 50% of splenic B cells, a minor population of circulating adult B-lymphocytes. Anti-CD1a antibodies are usually included in panels for the differentiation of T-cell leukemias and lymphomas, since the CD1 antigens are expressed on neoplastic T cells in many cases of precursor T-cell lymphoblastic leukemia/lymphoma, Sezary syndrome, and cutaneous T-cell lymphoma (138–140).

**CD2:** CD2 is a 50-kDa single chain transmembrane glycoprotein and member of the immunoglobulin gene superfamily also known as the sheep red blood cell (SRBC) receptor, T11, and the LFA-3 (CD58) receptor. Functionally, the CD2 antigen is one of several cell

surface glycoproteins involved in T-cell and NK-cell adhesion and activation, recently termed adhesion-receptor-messenger systems (141–143).

CD2 is a “pan-T-cell” antigen, which is one of the earliest T-specific antigens yet discovered. It is present on thymocytes (cortical and medullary), mature circulating T lymphocytes, as well as on activated T cells, T-cell lines, and NK cells. The CD2 antigen is expressed on tumor cells from patients with precursor T-cell acute lymphoblastic leukemia/lymphoma, T-cell CLL, and the Sezary syndrome. Anti-CD2 antibodies have been extensively used for the clinical quantitation of pan T lymphocytes (“total T lymphocytes”) in the evaluation of patients with hematologic neoplasms of T-cell origin, congenital and acquired immunodeficiency diseases, autoimmune diseases, infectious diseases, and organ transplantation (144). In acute promyelocytic leukemia, CD2 expression is associated with the short form of PML-RAR  $\alpha$  transcripts and a poor clinical prognosis (145,146).

**CD3:** The CD3 molecule (T-cell receptor, CD3 complex, TiT3 complex) consists of a complex of six polypeptide chains associated with either disulfide-linked  $\alpha$  or  $\beta$  chains ( $\alpha/\beta$ -TcR) or a  $\gamma/\delta$  dimer ( $\gamma/\delta$ -TcR) that functionally serve as the primary recognition site of the T lymphocyte (147,148). The CD3 complex is present as a surface membrane component (mCD3) on virtually all mature T lymphocytes in the peripheral circulation, and shows bright surface expression on 20–30% of human thymocytes (mature cortical thymocytes, medullary thymocytes). On the contrary, the cytoplasmic CD3 antigen (cCD3) appears early in T-cell ontogeny.

Anti-CD3 antibodies are widely used in the clinical laboratory for the quantitation of total T lymphocytes in immunodeficiency diseases and the characterization of hematopoietic neoplasms (144,149,150).

**CD4:** The CD4 antigen is a 59 kDa monomeric transmembrane glycoprotein with four Ig-like domains (151). The presence of CD4 functionally defines the helper/inducer T-cell subset for T-T, T-B, and T-macrophage interactions. In these interactions the CD4 molecule of the T-helper cell serves as the recognition structure for the HLA Class II molecules of antigen-presenting cells or target cells, and may also play a direct signaling role in T-cell activation (152).

CD4 is expressed by approximately 80% of cortical thymocytes, 60% of circulating peripheral blood T lymphocytes, by microglial and dendritic cells, and very weakly by monocytes. Lymphocyte subtyping with anti-CD4 monoclonal antibodies has been widely employed in the diagnosis of HIV infection and in the clinical monitoring of patients with this disease (144,150). In addition, these antibodies have been helpful in the phenotypic differentiation of hematopoietic neoplasms, and in the diagnosis and monitoring of

autoimmune and infectious diseases (144). A minority of tumor cells from patients with precursor T-cell ALL and the majority of cells from patients with peripheral T-cell acute lymphoblastic leukemia/lymphoma express CD4 (153,154).

**CD5:** The CD5 molecule (T1, Leu-1, Tp67, and OKT1) is a 67 kDa monomeric glycoprotein that is a member of the scavenger receptor superfamily (155). The CD5 molecule is strongly expressed on a major subset of peripheral blood T lymphocytes, where its density increases with maturation of the T lymphocyte. However, CD5 is also present on thymocytes (high density on medullary thymocytes and in low density on cortical thymocytes), and is weakly expressed by a minor subset of mantle zone B lymphocytes, and by a very small percentage of normal circulating B lymphocytes (CD5<sup>+</sup> B cells, B1a cells, Leu-1 B cells) (156).

Monoclonal antibodies directed against the CD5 antigen are used in the quantitation of T lymphocytes in immunodeficiency states and other diseases and for the immunophenotypic analysis of lymphoreticular neoplasms. The CD5 antigen is expressed on most neoplastic T cells in patients with precursor T-cell acute lymphoblastic leukemia/lymphoma or T-cell lymphoproliferative diseases. In addition, most cases of B-cell CLL and mantle cell lymphoma (MCL) are neoplasms of the CD5<sup>+</sup> B cell, which shows a predilection for malignant transformation with age (156).

**CD7:** The CD7 antigen (gp40) is a single chain, 40-kDa polypeptide and member of the Ig superfamily that appears early in T-cell differentiation and is involved in T-cell adhesion, signal transduction, and the regulation of peripheral T- and NK-cell cytokine production (157,158). The CD7 antigen is present on T progenitor cells from the thymus and bone marrow. It has classically been recognized as the earliest T-cell-specific molecule, although some studies do not support this assumption (159). CD7 remains throughout T-cell maturation and is present on the majority of peripheral T lymphocytes.

Monoclonal antibodies in the CD7 cluster have been used with other T-cell antigens in the characterization of hematopoietic neoplasms of T-cell and NK-cell origin (160,161). Reduced or absent expression of this antigen has been observed in some T-cell neoplasms, and this phenomenon of aberrant CD7 expression has been helpful in the differentiation of early cases of cutaneous T-cell lymphoma from benign T-cell infiltrates, although there is evidence for the presence of CD7<sup>-</sup> T cells in some benign dermatologic diseases as well (162). Anomalous expression of the CD7 molecule is found in approximately one-third of patients with acute myelogenous leukemia, and may be associated with a more aggressive clinical course (161,163).

**CD8:** The CD8 molecule (T8) is a 32 kDa transmembrane glycoprotein that consists of two chains ( $\alpha$  and  $\beta$ ). The CD8 antigen is expressed by approximately 80% of human cortical thymocytes and 35% of peripheral blood T lymphocytes (164). Functionally, the CD8 antigen is the membrane receptor for MHC Class I molecules. Antigenic recognition by the cytotoxic T lymphocyte occurs via the T-cell antigen receptor, in association with Class I MHC products (165,166).

The enumeration and monitoring of T suppressor subsets has been useful in patients with immunodeficiency, infectious, autoimmune, and lymphoproliferative diseases (167). Anti-CD8 monoclonal antibodies are also used in the differentiation of chronic lymphocytosis. The quantitation of soluble CD8 by enzyme immunoassay may offer an alternative to immunophenotypic analysis for the detection and monitoring of lymphocyte activation.

**CD16:** Leukocyte Fc  $\gamma$  receptors (Fc $\gamma$ R) include three subclasses: Fc $\gamma$ RIIa (CD32a), Fc $\gamma$ RIIIa (CD16a), and Fc $\gamma$ RIIIb (CD16b) (168,169). The CD16 molecule is a complex polymorphic 50–65 kDa sialoglycoprotein. CD16 functions as an important activation receptor on NK cells, and is the functional receptor for antibody-dependent cellular cytotoxicity (ADCC). On neutrophils, CD16 functions as the low-affinity receptor for complexed IgG (i.e., immune complexes). Fc $\gamma$  receptors polymorphisms are associated with infectious, inflammatory, allergic, and autoimmune diseases (168).

The CD16 molecule is expressed on cytotoxic large granular lymphocytes (NK cells), neutrophils, macrophages, eosinophils, and basophils (170–172). In addition, a small subset of CD16<sup>+</sup> T lymphocytes has been defined that includes lymphocytes expressing both  $\alpha/\beta$  and  $\delta/\gamma$  T-cell antigen receptors (173). Anti-CD16 monoclonal antibodies have been widely used in the quantitation and characterization of NK cells.

**CD56:** The CD56 antigen (NKH-1, neural adhesion antigen) is a heavily glycosylated isoform of the human cell adhesion molecule (N-CAM) (174). CD56 is a pan-NK-cell antigen that is also expressed on 7–10% of peripheral blood mononuclear cells and tumor cells derived from the neuroectoderm, including small-cell carcinomas, neuroblastoma, medulloblastoma, retinoblastoma, pheochromocytoma, and some melanomas (174–176).

Anti-CD56 monoclonal antibodies are widely used in the clinical quantitation of NK cells. CD56 is expressed in some cases of acute myelogenous leukemia, where it is associated with an adverse clinical prognosis (177–179). The expression of CD56 assists in the differentiation of multiple myeloma from a monoclonal gammopathy of

undetermined significance and non-Hodgkin lymphomas with plasmacytoid differentiation (180).

**CD57:** The CD57 antigen (HNK-1) is a 220 kDa chondroitin sulphate proteoglycan structurally similar to a punitive natural ligand for cytotoxic T-lymphocyte (181). CD57 is expressed by 60% of NK cells, a T-cell subset without NK-activity, some B-cell lines, and the white matter tissue of the brain and central nervous system (181,182). Anti-CD57 monoclonal antibodies have been used in the clinical and clinical research enumeration of NK cells and in the characterization of NK subsets. Clonal expansion of CD8<sup>+</sup> CD57<sup>+</sup> cells has been reported in viral infection and in matched unrelated T-cell-depleted bone marrow transplant recipients (183–185).

**CD246:** CD246 (Anaplastic Lymphoma Kinase, ALK, Ki-1) is a 200 kDa glycosylated, single chain transmembrane tyrosine kinase and member of the insulin receptor subfamily encoded by a gene at 2p23 (186). Overexpression of CD246 is characteristic of neuroblastoma, some rhabdomyosarcomas, and rare cases of B-cell lymphoma (186). In addition, mutations involving the ALK gene lead to the expression of oncogenic ALK fusion proteins in some human malignancies, including anaplastic large cell lymphoma (ALCL) and inflammatory myofibroblastic tumor (186–188). In the hematopathology laboratory, anti-CD246 monoclonal antibodies are routinely used for the immunohistochemical evaluation of lymphomas with large cell morphology (189–191).

#### *Antigens characteristic of B lymphocytes*

The B-cell associated antigens defined by the Eighth International Workshop are described below and in Table 8.

**CD10:** CD10 (Common Acute Lymphoblastic Leukemia Antigen, CALLA) is a 95- to 100,000 Da glycoprotein (gp100) that functions as an enzyme (human membrane-associated enzyme-neutral endopeptidase, NEP, metalloendopeptidase, enkephalinase, membrane metalloendopeptidase) (192,193). The CD10 molecule is present on the pre-pre-B and pre-B stages of B lymphocyte development but disappears with subsequent maturation of the B cell. CD10 has also been identified on mature neutrophils, a small percentage of cells in the normal bone marrow and fetal liver, and various normal and malignant nonhematopoietic cells.

CD10 is expressed in more than 80% of cases of non-T-cell ALL, in 40–50% of patients with CML in lymphoid blast crisis, and in some B-cell and T-cell lymphomas (PDLL, Burkitt's lymphoma, T-cell lymphoblastic lymphoma). Anti-CD10 monoclonal antibodies are essential for the diagnosis of B-ALL and other B-cell neoplasms (194–197). In childhood ALL, CD10 expression is associated with a favorable clinical

prognosis, while negativity for CD10 is characteristic of mixed lineage leukemia (198).

**CD19:** The CD19 molecule is a 90 kDa Type I integral membrane glycoprotein and member of the immunoglobulin supergene family. The CD19 antigen is expressed very early in B-cell differentiation (199). From its appearance at the “pre-pre-B” stage of B-cell differentiation, it remains until terminal differentiation of the B lymphocyte into a plasma cell. The CD19 molecule is present on all B lymphocytes in the periphery and on approximately 5% of bone marrow cells. Almost all tumors of B-cell deviation express this antigen, whereas tumors of T-cell origin do not, making this antibody critical for B-cell enumeration and characterization of B-cell neoplasms (160,200,201).

**CD20 (L26):** The CD20 antigen (Bp35) is an unusual membrane-embedded nonglycosylated phosphoprotein that functions as a substrate for protein kinase C. CD20 is encoded by a gene on chromosome #11 and appears to regulate calcium flux in the B lymphocyte (202).

The CD20 molecule is expressed by all mature B cells from the peripheral blood, lymph nodes, spleen, tonsil, and bone marrow. CD20 is expressed in about 50% of cases of precursor B-cell lymphoblastic leukemia/lymphoma, but not in tumors of T-cell, myeloid, or monocytic origin. Anti-CD20 monoclonal antibodies are widely employed for B-cell enumeration and the diagnosis and treatment of B-cell neoplasms (203,204).

**CD21:** The CD21 molecule (C3d/EBV-Receptor, CR2 complement receptor) is a 113 kDa Type I integral membrane glycoprotein originally described by Nadler et al. (205,206). CD21 is the membrane receptor for Epstein Barr virus (EBV) and C3d (207). The CD21 antigen appears on the B cell at approximately the same time as surface Ig, and disappears in the early stages of terminal B-cell differentiation (208). The CD21 antigen is present on a fraction of mature B lymphocytes from the peripheral blood, lymph nodes, spleen, and tonsil, as well as follicular dendritic reticulum cells and pharyngeal epithelial cells (209). CD21 is expressed on tumor cells from patients with B-cell lymphomas (diffuse and nodular PDLL), B-CLL, and some cases of non-T ALL. It is absent from normal circulating T lymphocytes, tumor cells of T cell or myeloid origin, or diffuse or nodular histiocytic lymphomas. Monoclonal antibodies in the CD21 cluster are used in conjunction with other anti-B-cell monoclonal antibodies for typing mature lymphomas and leukemias of B-cell origin (210–212). CD21 expression is associated with a relatively good clinical prognosis in diffuse large B-cell lymphoma (213).

**CD38:** The CD38 antigen (T10) is a 45 kDa integral membrane glycoprotein signaling molecule that plays an



important role in B-cell growth and survival (214,215). The CD38 antigen is expressed on hematopoietic stem cells and blasts, prethymic cells, early thymic lymphocytes, and early B cells. As an activation marker, CD38 is expressed in high density on plasma cells and activated T cells. CD38 antigen expression is characteristic in ALL (both T- and B-cell lineage), multiple myeloma, a subtype of T-lymphoblastic lymphoma, follicular center cell lymphomas, and some cases of AML. Anti-CD38 antibodies are most commonly used in the evaluation of plasma cell disorders (216) and CLL, where CD38 expression correlates with aggressive disease (217–219).

**CD138:** CD138 (Syndecan-1, heparan sulfate proteoglycan) is a 30.5 kDa integral transmembrane proteoglycan produced by gene SDC1 on chromosome 2p24.1. In the bone marrow, CD138 expression is restricted to pre-B lymphocytes and plasma cells. Anti-CD138 antibodies can be detected by flow cytometry or immunohistochemistry, and are useful for the quantitation of plasma cells in patients with plasma cell dyscrasias (220,221).

**Cyclin D1:** Cyclin D1 (*bcl-1*, *PRAD-1*) is a key regulatory subunit of cyclin-dependent kinase-4, which promotes cells from the G1 phase of the cell cycle into the S phase. (222–224). Cyclin D1 is overexpressed in B-cell malignancies (e.g., mantle cell lymphoma and some cases of prolymphocytic leukaemia, plasma cell leukaemia, splenic lymphoma with villous lymphocytes, chronic lymphocytic leukaemia, and multiple myeloma), invasive breast cancer, and other malignancies (225–227). In the hematopathology laboratory, cyclin D1 detection is mainly used in the diagnosis of mantle cell lymphoma (MCL), that results from chromosomal translocation  $t(11; 14)(q13; q32)$ . In addition to cyclin D1 expression, MCL is also characterized by the expression of CD5, CD23, and B-cell antigens (CD19, CD20) (228,229).

**Bcl-2:** Bcl-2 is a member of a small but important family of apoptosis regulators controlling the level of B and T lymphocytes (230,231). Bcl-2 protein is an important diagnostic marker for follicular lymphomas, the majority of which possess the  $t(14:18)(q32;q21)$  translocation. Bcl-2 protein is usually detected by immunohistochemical staining or flow cytometry, while the  $t(14:18)(q32;q21)$  translocation can be detected by conventional karyotypic analysis or PCR. Since some normal T and B cells express *bcl-2*, immunostains or flow cytometric data must be interpreted in the context of other findings (232). Pitfalls in the interpretation of *bcl-2* immunostains include tangentially cut primary follicles or mantle zones and follicles colonized by non-FCC lymphomas that may be *bcl-2* positive (232).

**Bcl-6:** Bcl-6 is a nuclear transcriptional repressor that is functionally important in germinal center B-cell differ-

entiation and inflammation (233,234). Bcl-6 is expressed in normal germinal center B cells, non-Hodgkin lymphomas of follicular center cell origin, Burkitt lymphoma, nodular, lymphocyte predominant Hodgkin disease, and rare T-cell lymphomas. It is not expressed in other lymphomas of B-cell origin, including mantle cell lymphoma, marginal zone lymphoma, and HCL.

**PAX-5:** Pax-5 is a very specific B-cell lineage-specific protein (B-cell-specific activator protein, BSAP) encoded by a gene on chromosome 9p13. Pax-5 appears very early in B-cell differentiation but is also present on mature B lymphocytes. Neither normal T lymphocytes nor plasma cells nor T lymphocytes express PAX-5. During B lymphoid cell development, BSAP is involved in the regulation of other B-cell-specific genes, including CD19 and CD20.

Commercial anti-Pax-5 monoclonal antibodies were only recently introduced into the immunohistochemistry laboratory, but appear to surpass the sensitivity and specificity of CD20 for B cells, since they are expressed on very early, as well as committed B cells (235). In this regard, strong Pax-5 expression has been reported in the majority of B-cell lymphomas, many cases of classical Hodgkin disease, and rarely among T-cell lymphomas (236–238). Unfortunately, Pax-5 appears less useful as a diagnostic marker for the evaluation of acute leukemia, since it is expressed in a substantial proportion of cases of myeloid and T-cell origin (237).

#### *Myeloid antigens*

The myeloid-associated antigens classified by the Eighth International Workshop are described below.

**CD11b:** Anti-CD11b monoclonal antibodies are specific for an epitope on the 165 kDa  $\alpha$  chain of the LFA-1 complex (Mac-1 $\alpha$ ). CD11b/CD18 (CR3, C3bi Receptor, Mac-1, Mo1) is a noncovalently linked,  $\alpha/\beta$  heterodimeric glycoprotein belonging to the LFA-1 family of cell adhesion molecules (239,240). CD11b is expressed on monocytes, neutrophils, the suppressor subpopulation of CD8<sup>+</sup> cells, NK cells, and “null cells” from the bone marrow and peripheral blood (240). CD11b is frequently present on blast cells in acute monocytic (AML FAB-M5) and acute myelomonocytic leukemia (AML, FAB-M4) but is rarely expressed in acute granulocytic leukemia (AML, FAB M1, FAB-M2). CD11b monoclonal antibodies are widely used for the detection and quantitation of granulocytes and monocytes, and for the characterization of myelomonocytic neoplasms. Since CD11b is present on the suppressor subpopulation of CD8<sup>+</sup> cells, but not on the cytotoxic subpopulation, anti-CD11b monoclonal antibodies have also been used to differentiate these populations. In AML, CD11b expression has been reported as an unfavorable prognostic indicator (241).

**CD11c:** Monoclonal antibodies in the CD11c cluster react with an epitope on the 150 kDa  $\alpha$  (p150,95  $\alpha$ ) chain of the LFA-1 complex (240). CD11c/CD18 is a member of the LFA-1 family and functions in cell-cell interactions. CD11c/CD18 (gp150/95) is expressed on NK cells, granulocytes, monocytes, and a B-cell subset (weakly) (240). It is expressed in HCL, dependent upon the activation of the proto-oncogenes ras and junD (242,243). Anti-CD11c monoclonal antibodies are used in the characterization of myelogenous leukemias and HCL.

**CD13:** Monoclonal antibodies in the CD13 cluster react with an integral single-chain, heavily glycosylated membrane protein (gp150) with a molecular weight of 150–170 kDa identical to aminopeptidase N. CD13 functions in cell adhesion and angiogenesis has been proposed as a signal transduction molecule on the myeloid cell (244–246)

CD13 is expressed on human myeloid cells, including peripheral blood monocytes, basophils, neutrophils, and eosinophils. In the normal bone marrow it is weakly present on 5–40% of cells, including a subset of colony-forming cells (CFU-C). It is not expressed on erythrocytes, platelets, or lymphocytes. CD13 is expressed in approximately 75% of cases of AML but not by acute lymphoblastic or CLL cells (247). Anti-CD13 MoAbs are extensively used in the phenotyping of neoplasms of myeloid origin (248–250).

**CD14:** The CD14 molecule (gp55) is a 55 kDa phosphoinositol-linked single-chain surface membrane glycoprotein encoded by a gene on chromosome 5 (251–253). CD14 is a component of the LPS receptor complex (CD14, toll-like receptor 4, myeloid differentiation protein-2) (254,255).

Anti-CD14 monoclonal antibodies are excellent markers for monocytes and macrophages, and are widely used in the characterization of leukemias of monocytic origin (acute monocytic and acute myelomonocytic leukemia). In the peripheral blood, the CD14 molecule is strongly expressed by more than 90% of monocytes, and is weakly expressed by granulocytes (256). The expression of CD14 on cells of B lineage has also been reported (257). In the normal bone marrow, CD14<sup>+</sup> cells constitute approximately 5–10% of the total cell population, which includes most cells of the monocyte series. The CD14 molecule is expressed in approximately 40% of cases of AML, especially those of monocytic and myelomonocytic origin (FAB classes M4 and M5).

**CD15:** CD15 (Lewis x, 3-FAL, X-Hapten, SSEA, Lacto-N-fucopentaose III, LNF-III) is a human myelomonocytic antigen that is identical to a sugar sequence found in lacto-N-fucopentaose III (Gal 1-4 (Fuc 1-3) G1cNac) (258–260). CD15 is an adhesion molecule involved in leukocyte adhesion to endothelial cells and

may be involved in structural stabilization of the cell membrane (261).

Monoclonal antibodies in the CD15 cluster are widely used in the phenotypic analysis of hematopoietic neoplasms, and along with CD30, they are critical for the diagnosis of Hodgkin lymphoma. CD15 is expressed by the Reed–Sternberg cells of Hodgkin's disease and by granulocytes, but rarely by tissue macrophages or histiocytes. In the peripheral blood, anti-CD15 reacts with mature cells of myeloid and monocytic origin, including >95% of neutrophils, eosinophils, and basophils, and with 70–95% of circulating monocytes. It is present on some erythroid and T-cell lines, and on activated T cells, but not normal T and B lymphocytes, B-cell lines, erythrocytes, or platelets. Finally, CD15 is expressed in acute and CMLs and some CD10<sup>+</sup> precursor B-cell acute lymphoblastic leukemias.

**CD33:** Anti-CD33 monoclonal antibodies recognize a 67 kDa single-chain transmembrane glycoprotein (gp67) and member of the immunoglobulin supergene family encoded by a gene on chromosome 19 (262–264). CD33 is an inhibitory receptor that may function in myeloid cell development and proliferation (265–267).

Monoclonal antibodies in the CD33 cluster (CMA-676, Mylotarg) are used in the phenotypic analysis of leukemias, and in purging bone marrow for autologous transplantation (268). CD33 expression is largely restricted to normal and neoplastic cells of myeloid origin. In the peripheral blood, some monocytes express CD33, but not granulocytes, lymphocytes, erythrocytes, or platelets. Approximately 30% of the cells in the normal bone marrow are positive, including myeloid colony forming cells, myeloblasts, promyelocytes, monocytes, and a subset of erythroid burst forming cells. Approximately 80% of cases of acute myelogenous leukemia (AML) are positive for CD33. It is rarely expressed on neoplastic lymphoid cells, especially in cases undifferentiated acute lymphoblastic leukemia and mature B-cell lymphoproliferative disease (269).

**CD34:** The CD34 antigen is a highly acidic, highly glycosylated single-chain transmembrane with a molecular weight of 105–120 kDa, encoded by a gene localized to chromosome 1 (270–272). Functionally, the CD34 molecule serves as a phosphorylation target for activated protein kinase C and may be involved in signal transduction during early lymphohematopoiesis (273,274).

The CD34 molecule is expressed on hematopoietic precursor cells and capillary endothelial cells (275–277). As a marker of hematopoietic precursor cells, CD34 is “stage-specific,” rather than lineage specific (278). It is expressed in the greatest density on the earliest lymphohematopoietic cells, and progressively decreases

with cell maturation (279). Neoplasms of more mature hematopoietic cells (lymphomas, CLL) are almost uniformly negative for CD34. Anti-CD34 monoclonal antibodies are used in the identification and separation of bone marrow hematopoietic cells, and for the phenotypic analysis of hematopoietic neoplasms (280). CD34 expression has been reported as an adverse prognostic factor in AML, and a good prognostic factor in ALL (281,282).

**CD64:** The CD64 molecule is a single-chain glycoprotein with a molecular weight of 75 kDa (283). CD64 is the receptor for monomeric IgG (high-affinity Fc-IgG receptor, FcγR) and functions as a signal transducer (169,283). CD64 is expressed on monocytes, but is absent from blood lymphocytes (283). Monoclonal antibodies in the CD64 cluster are primarily used in the diagnosis of acute myelogenous leukemia of the FAB M4 and M5 subtypes (284).

**CD68:** The CD68 molecule (KP1) is an intracellular, 110 kDa protein of undefined biological function that is highly expressed on monocytes and tissue macrophages (285). Anti-CD68 monoclonal antibodies react with various other tissue cells (histiocytes, mast cells, synoviocytes, osteoclasts, giant cells, and kidney spindle cells) (285). Anti-CD68 monoclonal antibodies are primarily used as immunohistochemical reagents for the identification of tissue macrophages and related cells (286–288).

**CD117:** CD117 (c-KIT, stem cell factor receptor, SCFR) is a 145 kDa member of the immunoglobulin supergene family expressed on hemopoietic stem and progenitor cells, tissue mast cells, melanocytes, reproductive system, and embryonic brain cells (289). CD117 has been recently used in the diagnostic evaluation of acute leukemia, although its prognostic significance is not fully understood (290–293). Since C-Kit is a molecular target for imatinib mesylate (Gleevec; Novartis Pharma, Basel, Switzerland), the diagnostic and prognostic significance of CD117 expression is under evaluation in a number of human tumors, including uterine carcinosarcoma, renal oncocytomas and chromophobe renal cell carcinomas, and small-cell carcinoma of the urinary bladder.

#### *Antigens characteristic of megakaryocytes and platelets*

**CD41:** Monoclonal antibodies in the CD41 cluster are specific for an epitope on the calcium-dependent GPIIb/IIIa complex. Functionally, the CD41 antigen is a receptor for fibrinogen, fibronectin, and von Willebrand factor that is essential for platelet aggregation (294). CD41 is strongly expressed by platelets, megakaryoblasts, megakaryocytes, erythromegakaryoblastoid cell lines, splenic red pulp, and Kupffer cells

(295,296). Immature myeloid and lymphoid precursors may also express CD41 at low levels. (297) Clinically, CD41 monoclonal antibodies have been used in the diagnosis of acute megakaryocytic leukemia (AML, FAB-M7), congenital CD41 deficiency (Glanzmann thrombasthenia), and in the detection of antiplatelet alloantibodies (anti-Zw<sup>a,b</sup>, anti-Yuk<sup>a,b</sup>, anti-Bak<sup>a,b</sup>) (298,299).

**CD42a:** The CD42a molecule (platelet GPIX) is a 23 kDa single-chain glycoprotein that forms a noncovalent complex with GPIb (GPIb/IX complex) (300). The GPIb/IX complex functions as the von Willebrand factor-dependent adhesion receptor and as the receptor for the ristocetin-induced binding of von Willebrand factor (301).

CD42a is expressed on platelets, megakaryocytes, splenic red pulp, and Kupffer cells. CD42a monoclonal antibodies (FMC25) have been used in the diagnosis of acute megakaryocytic leukemia (AML, FAB-M7) and congenital CD42 deficiency (Bernard–Soulier syndrome) (298,299).

**CD61:** The CD61 antigen is a 110 kDa glycoprotein (integrin β<sub>3</sub>, GPIIIα chain) that can associate with either GPIIb or the VNR α-chain (302). CD61 is expressed on platelets and platelet precursors, weakly on B cells, some leukemic and EBV-cell lines, and on various nonhematopoietic cells. Monoclonal antibodies in the CD61 cluster are used for the diagnosis of megakaryoblastic neoplasms, idiopathic thrombocytopenia, and in the detection of antiplatelet alloantibodies (anti-Zw<sup>a,b</sup>, anti-Yuk<sup>a,b</sup>, anti-Bak<sup>a,b</sup>) (303,304).

#### *Antigens characteristic of erythroid cells*

**CD235a:** CD235 (glycophorin A) and band 3 are the most abundant proteins of the erythrocyte cell membrane (305–308). Owing to its very high content of sialic acid, CD235 contributes most of the negative charge to the erythrocyte membrane. This is essential for maintaining structural integrity and preventing red cell aggregation. CD235 also carries the MN blood group (305). During erythropoiesis, CD235 first appears after the erythroid CFU-E stage, reaches maximal expression in the early normoblast stage and maintains its expression for the life of the erythrocyte (309,310). The detection of CD235 expression by immunohistochemical staining or flow cytometry can be helpful in the differentiation of erythroid precursors from other bone marrow cells.

**Spectrin:** Spectrin is the major structural component of the red blood cell membrane (311–313). Spectrin mutations are one cause of hereditary elliptocytosis and spherocytosis (314). Since spectrin is brightly expressed on erythroblasts throughout erythroid maturation, while glycophorin A is only weakly expressed on mature

erythroblasts, antispectrin antibodies have been reported as superior to antiglycophorin antibodies in the immunohistochemical identification of erythroid precursors (311).

#### *Antigens expressed by proliferating cells*

Tumor stage and grade have been used for several decades as the primary parameters for the prognostication of patients with malignant tumors, and as a guide for the type and extend of therapy. Since these parameters are entirely subjective in most cases and semi-quantitative at best, and it is not surprising that quantitative indicators of tumor biological behavior have been evaluated. Quantitative analysis of the cell cycle has accompanied other major scientific discoveries and technological innovations of the past four decades. Thus, the use of light microscopy (mitosis counting, argyrophilic staining for nucleolar organizer regions), autoradiography, and radiotracers in the 1950s and 1960s was followed by the use of DNA-specific fluorochromes, flow cytometry, and image analysis in the 1970s and 1980s. More recently, monoclonal antibodies specific for antigens that appear during specific phases of the cell cycle have been quantitated by flow cytometry, image analysis, or immunohistochemistry. The next era in cell cycle analysis will involve the use of recombinant DNA technology.

Of the various proliferating cell antigens, Ki-67 and PCNA/cyclin are currently receiving the most attention. Since Ki-67 protein is expressed on the cell surface during active phases of the cell cycle, but only in the nucleus of resting cells, the proportion of surface-positive Ki-67 cells (the Ki-67 labeling index) is a specific measure of growth fraction (315). In lymphoproliferative disease, Ki-67 expression has a prognostic significance similar to that of proliferative activity and [3H]-TdR uptake (316). MIB-1 is a monoclonal antibody specific for the Ki-67 antigen that can be used in formalin-fixed paraffin-embedded tissue. Proliferating cell nuclear antigen (PCNA, cyclin) is a 36 kDa, DNA polymerase cofactor found in the nuclei of actively proliferating cells (317).

#### **Detection of MRD**

MRD is the persistence of malignant cells in the bone marrow or other tissues after remission has been achieved by conventional morphologic assessment (318,319). It is believed that these residual cells are the source of relapse in many patients who achieve "complete" morphologic remission from acute leukemia or other malignant hematologic diseases, although additional therapy to eradicate very small numbers of

residual cells does not improve survival in all patients. Researchers are actively evaluating the clinical and prognostic significance of MDR.

MRD detection by molecular techniques, especially quantitative real-time PCR, is presently the "state-of-the-art" for monitoring the response to treatment in most hematologic neoplasms because of its high sensitivity and specificity (320). Flow cytometric analysis is less sensitive than the polymerase chain technique for MRD, but it is simple and rapid, and provides quantitative data. In many cases, flow cytometry has adequate sensitivity. The detection of MRD by flow cytometric analysis is based on the presence of cell populations with aberrant immunophenotypic features. For example, the discovery of CD10<sup>+</sup>, TdT<sup>+</sup>, or CD34<sup>+</sup> cells in the cerebrospinal fluid is diagnostic of MRD, since immature leukocytes with these markers are not normally present in the CSF. The expression of TdT, cytoplasmic CD3, CD1a, or the dual phenotype CD4<sup>+</sup>/CD8<sup>+</sup> is diagnostic of residual MRD in T-ALL, since cells with this phenotype are normally confined to the thymus. The detection of B-ALL MRD is more difficult, since small numbers of immature B-cells are normally present in the bone marrow. The majority of B-ALL cases have aberrant antigenic features, however, including cross-lineage antigen expression (i.e., TdT, T-cell, or myeloid antigens), asynchronous antigen expression, or changes in the level of antigen expression (i.e., "dropped" or overexpressed antigens). The search for new markers and techniques of immunophenotypic analysis for MRD is underway by several investigators. The vast scope of this subject precludes further review in this publication.

#### **Cytogenetic Analysis**

Cytogenetics (chromosome analysis) is conventionally performed on metaphase preparations of cells grown in culture (321,322). In hematologic disease, two types of samples can be used for cell culture: bone marrow cells and peripheral blood. In the traditional tissue culture, metaphase preparation requires dividing cells. In the bone marrow, cells are in different stages of proliferation and differentiation and there are many dividing cells that can be captured for metaphase after a short-term culture. For a peripheral blood sample, metaphases are obtained after stimulation of T lymphocytes by PHA, which activates the cells into the cell cycle. After three days in culture medium, the cells are harvested, fixed with acetic acid and methanol, and fixed onto slides. The most commonly used technique to visualize the chromosome is G banding, which is viewed by light microscopy after pretreatment with trypsin and staining with Giemsa dye (323). Each chromosome and chromosome segment has

a unique "banding" pattern that can be identified by an experienced observer. Chromosomal deletions, translocations, and other abnormalities can also be identified by this procedure. The preparations can be stained with fluorescent dyes, which intercalate into the grooves of the DNA helix and viewed by fluorescence microscopy ("Q banding") (324). Q banding can be used as an adjunct to G banding and is especially useful in identifying translocations on the Y chromosome. Other staining techniques are also available to specifically identify chromosomal abnormalities in the centromeric or telomeric regions. The innovative technique of multi-color spectral karyotyping (SKY) uses 24 different fluorescent-labeled chromosome-painting probes to permit the simultaneous visualization of all human chromosomes (325,326). SKY is particularly sensitive for the detection of complex chromosomal translocations, rearrangements, and other abnormalities that cannot be resolved by conventional banding techniques.

In hematology, cytogenetic studies have provided information for diagnosis, treatment, prognosis and disease follow-up. Investigations of chromosome translocations in acute myeloid leukemia (AML), acute lymphoblastic leukemia (ALL), B and T-cell lymphomas, multiple myeloma, CML and myelodysplastic syndrome (MDS) have demonstrated various chromosomal abnormalities. The nonrandom translocations seen in the hematologic malignancies seem to involve genes that regulate cell proliferation, differentiation, and apoptosis. Some of those genes are proto-oncogenes, while others have specific protein kinase activities. In addition, the nonrandom chromosomal deletions in other malignancies has contributed to our

understanding of tumor suppressor genes, which appear to have a significant role in inherited malignancies and are now being actively sought in many common cancers. Finally, chromosome studies have helped to demonstrate the clonal nature of most hematopoietic neoplasms and the importance in tumor progression of sequential somatic genetic changes within the neoplastic clone. This latter phenomenon appears to depend primarily on acquired genetic liability in the tumor cell population. Karyotypic data are providing leads to the basis of this phenomenon, as well as to the significance of constitutional chromosomal fragility and of specific fragile sites within the genome of different individuals. Detection and quantification of those changes are significant for diagnosis, treatment, and disease follow-up. Specific examples of cytogenetic abnormalities are shown in Tables 8 and 10.

The use of conventional chromosome banding for monitoring patient response to treatment and the early detection of disease relapse has been supplemented in recent years by molecular analysis of bone marrow specimens. Fluorescence in situ hybridization (FISH) is an alternative to chromosome banding that uses fluorochrome-labeled DNA probes specific for structural and numeric chromosomal abnormalities. There are many types of probes used for FISH techniques. For example, some of the specific repetitive sequences located in the centromeres in compact clusters are used for the detection of numerical changes of certain chromosomes. Specific large DNA fragments, which were cloned in to phage, cosmid, or yeast artificial chromosome (YAC) vectors, are used for the detection of specific translocations and deletions. Somatic hybrids

**TABLE 10. Frequent Chromosomal Abnormalities in Hematologic Disease**

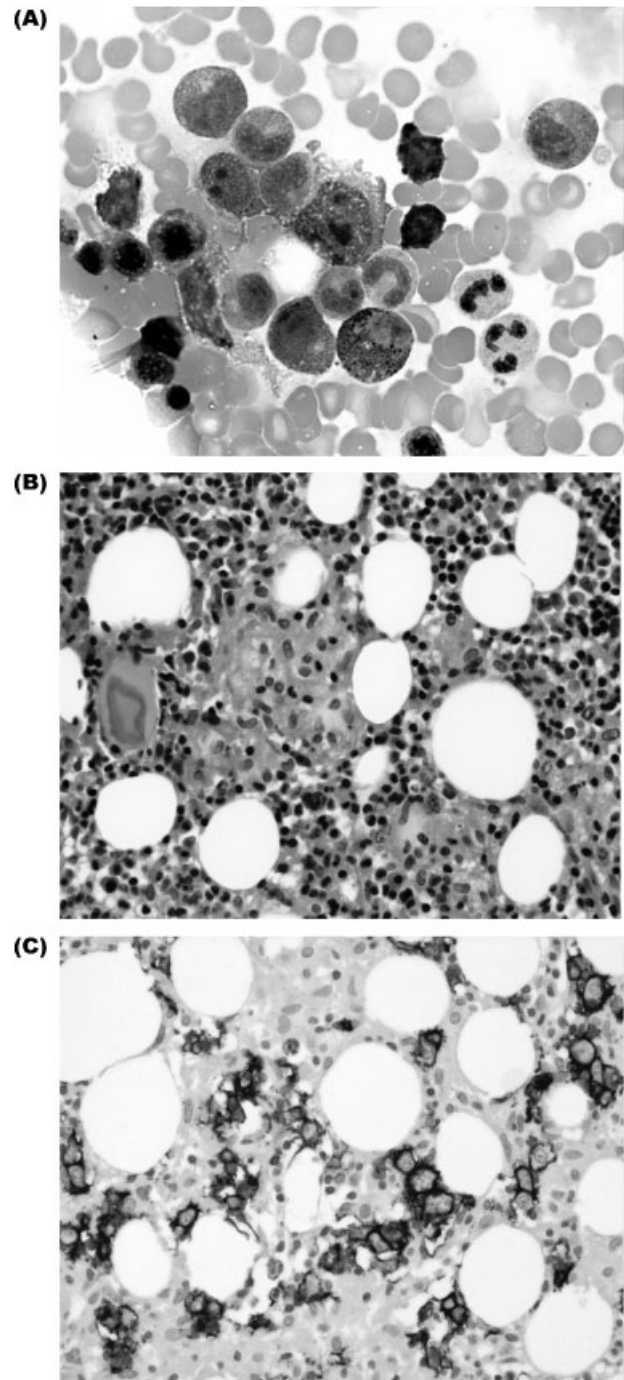
Disease	Subtypes	Genetic abnormality	Involved gene(s)
AML	M0	t(9;22)	BCR/ABL
	M2	t(8;21)	ETO/AML1
	M3	t(15;17)	PML/RARa
	M4	inv(16)	CBFB/MYH11
	M5b	11q23	MLL rearranged
ALL		t(12;21)	TEL/AML1
		t(1;19)	PBX/E2A
		t(v;11q23)	MLL rearranged
		t(9;22)	BCR/ABL
MDS		5q-, del(7q), del(20)	
CML		t(9;22)	BCR/ABL
Non-Hodgkin lymphomas	Mantle cell	t(11;14)	Cyclin-D1/IgH
	Burkitt	t(8;14), t(2;8), t(8;22)	C-MYC rearranged
	Follicular	t(14;18)	BCL-2/IgH
	Anaplastic	t(2;5)	NAM/ALK-1
Multiple myeloma		del(13q14), t(11;14), t(4;14), t(14;16)	RB1, Cyclin-D1, FGFR3, C-MAF

DNA were also labeled as chromosomal painting probes. Those probes are all commercially available.

FISH is technically rapid and easy to perform. DNA is denatured, hybridized, and washed (327–329). The hybridized signal can be recognized under the fluorescent microscope. If there are numerical changes such as trisomy or monosomy, three or one single signal will be scored, while translocation between chromosomes is recognized by fusion of two signals of different colors creating a third color. The DNA probes can hybridize to the metaphase as well as interphase (330). The advantage of hybridization to the interphase is that it does not require dividing cells. This is very useful because it is very difficult to obtain adequate metaphase in some malignancies (331). Multiple myeloma is an example of a disease that has greatly benefited from FISH and other modern techniques of analysis (332–334). Not only have new drugs with novel mechanisms of action (thalidomide, arsenic trioxide, and the proteasome inhibitor PS-341) been introduced, but the unraveling of the genetics of the disease has led to more accurate prognostic markers. Since plasma cells are difficult to assay with conventional cytogenetics, interphase FISH for immunoglobulin gene translocations [i.e., deletion of 13q14, t(11;14)(p16;q32), t(11;14)(q13;q32), t(14;16)(q32;q23), etc.] has been used for prognostic stratification and MRD detection after bone marrow transplantation. In the future, these discoveries may lead to targeted chemotherapy, such as the use of tyrosine kinase inhibitors to target the ectopic expression of receptor tyrosine kinase fibroblast growth factor receptor 3 associated with the t(4;14) translocation (335). Since FISH is a very sensitive technique for the detection of chromosome abnormalities, it is widely used both for diagnosis and for follow-up of MRD post chemotherapy and bone marrow transplant (336–339).

## Molecular Analysis

Besides FISH and cytogenetics, many molecular assays have been developed for clinical use, such as DNA Southern blot, mRNA Northern blot, and protein Western blot. However, these techniques require large quantities of sample DNA, RNA, or protein and are time consuming. Since the advent of the PCR, a unique DNA or complementary DNA sequence can be

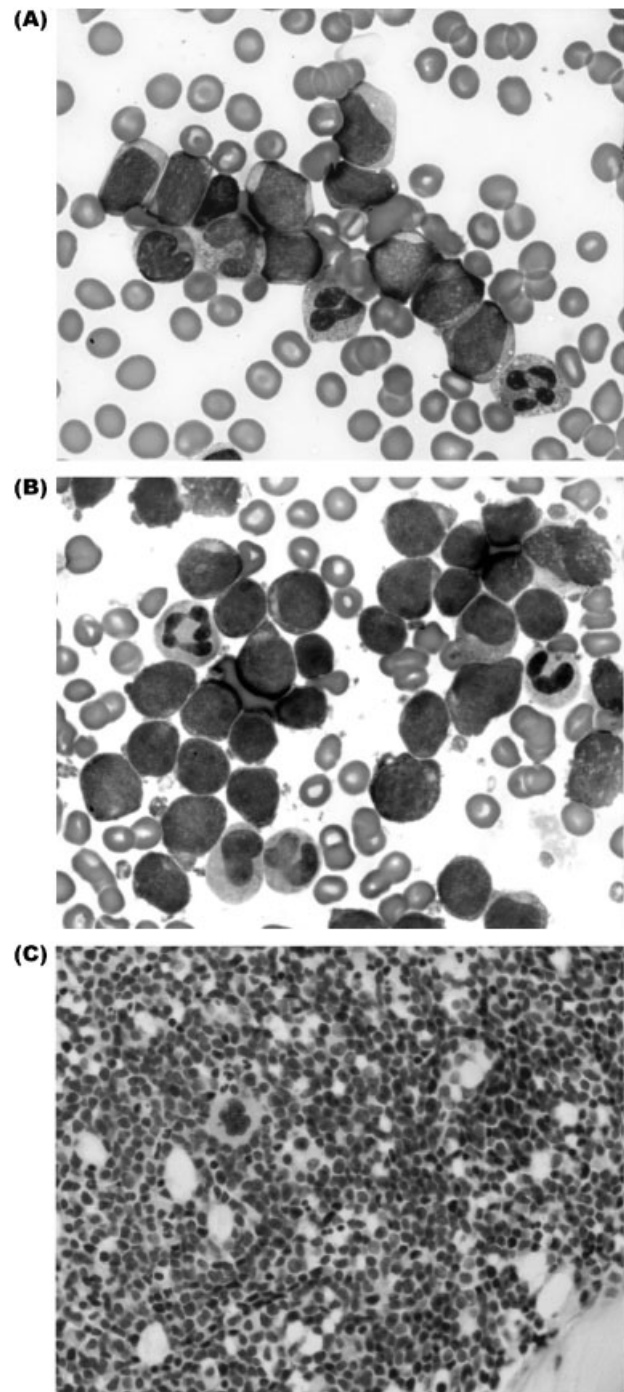


**Fig. 14.** Diagnostic application of immunoperoxidase staining and RT-PCR for the detection of B-cell non-Hodgkin lymphoma. The patient was a 53 year-old man with a history of follicular lymphoma. (A) Photomicrograph of bone marrow aspirate showing rare large, atypical cells (1000x), (B) Photomicrograph of bone marrow biopsy showing a small non-caseating granuloma and scattered lymphocytes (400x). No well-formed lymphoid aggregates were identified. (C) Immunohistochemical stain of the bone marrow biopsy for CD20 (400x). Several aggregates of CD20-positive cells are seen. For molecular analysis, sections of the paraffin block of the bone marrow clot section were deparaffinized and subject to standard phenol/chloroform DNA extraction with ethanol preparation. The extracted DNA was subjected to PCR using primers to the major breakpoint region of the t(14;18) BCL-2. The specimen was positive. PCR analyses run concurrently for T-cell and B-cell gene rearrangements were both negative. The patient also had some pelvic lymphadenopathy. He underwent an FNA and that material was positive for a B-cell gene rearrangement.

amplified and detected in a few hours. The chief advantage of such molecular analysis is high sensitivity, but other virtues of PCR include minimal tissue requirements, shortened laboratory turn around time, and detection of submicroscopic abnormalities. In addition, these assays do not require dividing cells (340,341). PCR requires strategic use of nucleotide sequences that flank the genetic region of interest. PCR then amplifies this known DNA sequence flanked by the two DNA primers through repeated cycles of DNA denaturation, primer annealing, and extension with a thermostable DNA-polymerase in a thermocycler. PCR generates an exponential amount of amplified product of the targeted genetic sequence. Such amplified product can then be detected through various methods, including gel electrophoresis or by solution-based means, such as fluorescent or chemiluminescent systems (342).

As the World Health Organization has recently demonstrated in its classifications, genetic analysis of lymphomas and leukemias has prognostic and therapeutic implications (343). The molecular techniques in use today, and those being developed for the future, demonstrate either rearrangements in antigen receptors or translocations specific to hematologic or lymphoid disease (340). Immunoglobulin (Ig) and T-cell receptor (TCR) genes undergo considerable rearrangement during immunologic maturation. Monoclonal expression of Ig and/or TCR is sometimes expressed in lymphoid malignancies and is commonly detected by well-characterized DNA PCR methods. Similarly, there is a continuously expanding menu of assays using either PCR or reverse transcriptase PCR (RT-PCR) to detect chromosomal translocations described in hematologic malignancies (320,344–346). The difference between RT-PCR and DNA PCR is the starting material. In RT-PCR the starting material is mRNA that is then transcribed into cDNA by reverse transcriptase for subsequent PCR steps. In DNA PCR, the starting material is DNA. The breakpoint of the translocation on the DNA level may span a region over 100 kb. This is not suitable to amplify the fusion gene in different

patient by using DNA PCR. RT-PCR amplifies the cDNA that is derived from mRNA. The breakpoint of fusion mRNA is the same due to alternative splicing. Examples from this list are t(11;14), t(9;22), and t(15;17) of mantle cell lymphoma, CML, and acute promyelocytic leukemia, respectively. Both FISH and various types of PCR have proven highly sensitive for monitoring the BCR-ABL gene in patients receiving imatinib



**Fig. 15.** Diagnostic application of RT-PCR for the detection of BCR-ABL mRNA. This 48-year old man presented for medical care with a two-week history of severe fatigue, and was admitted to the hospital when his white cell count was found to be  $>200,000$ /microliter. His bone marrow biopsy was consistent with an acute leukemia. (A) Photomicrograph of peripheral blood demonstrating a cluster of blast cells (1000x). (B) Photomicrograph of the bone marrow aspirate smear showing numerous blast cells (1000x), (C) Photomicrograph of the bone marrow biopsy demonstrating marrow hypercellularity with numerous blast cells and rare megakaryocytes (400x). Subsequent PCR demonstrated a high quantitative level (nearly 100%) of t(9;22). His disease is now thought to be precursor B-cell acute leukemia with a p210 breakpoint t(9;22).

mesylate (Gleevec) chemotherapy or bone marrow transplantation (347–349) (Fig. 14). In childhood ALL, the presence of clonal antigen receptor gene rearrangements (IgH or TCR $\gamma$ ) at 12 or 24 months from diagnosis is highly predictive of relapse and reportedly has independent prognostic significance (350).

Most PCR methods are qualitative and are thus most useful for the initial diagnosis (Fig. 15). However, various methods now allow PCR quantitation (351). This technique allows monitoring of minimal residual disease and has been found to have the highest sensitivity, specificity, and reproducibility compared with non-PCR molecular methods. The most commonly used technique is real-time Taqman PCR, which, in addition to the two fluorescence-labeled primers, also uses a probe. The probe is a third primer that is labeled with a target dye and a quencher dye. The target signal is quenched by the quencher until the Taq polymerase releases the target dye. Only then can the signal be detected by the laser in the PCR machine. The introduction of the probe increases the specificity of the PCR reaction as well as sensitivity for detection. Real time Taqman RT-PCR for the detection of BCR-ABL mRNA is up to four orders of magnitude more sensitive than cytogenetics or FISH (352).

Monitoring of patients over time intervals or measuring more than one lesion at a time with PCR assays may be necessary in future patient scenarios (353). A recent study has demonstrated that simultaneous detection of seven common leukemia translocations, using a multiplex RT-PCR system from a single patient specimen, is extremely valuable for clinical practice (354). Other studies have demonstrated that the use of peripheral blood for monitoring disease by PCR may be used instead of the bone marrow evaluation (320,355,356). Thus, the noninvasive use of peripheral blood may be used for molecular methods in the future in lieu of bone marrow specimens for certain diseases or translocations. The future of PCR-based tests will bring on an increased number of assays and more sensitive tests. What must be kept in mind is that false negative PCR results do occur. Thus, the molecular-based assays in the future will still be used in combination with bone marrow morphology and other diagnostic tools.

Immunosuppressive and myeloablative chemotherapy and pretransplant conditioning regimens allow residual recipient hematopoietic cells to coexist with reconstituted hemopoietic tissue of donor origin following bone marrow transplantation. This extraordinary immunogenetic state, known as mixed chimerism, exerts a significant influence on transplant outcome including the rate of relapse, the severity of GVHD and the antileukemic effect (357–360). Polymorphic markers of the donor enable differentiation from the host. Cyto-

netic markers are the most frequently used based on gender differences (XX, XY) or on translocations associated with malignancy (Ph chromosome) or other chromosomal alterations present in the donor or recipient. An informative disease phenotype may also allow the detection of residual circulating malignant cells by multicolor flow immunocytometry. However, the most sensitive detection systems use DNA-based methodologies including PCR and RT-PCR. In the case of bone marrow transplantation, oncogenic markers reflect not just the chimeric state but also the presence of residual disease.

## SUMMARY

Bone marrow specimens contain a wealth of diagnostic and prognostic information, necessitating prior planning for the optimal use of this valuable resource. This includes detailed knowledge of the patient's history, present indications for the procedure, available ancillary assays, and the specimen requirements for each assay. Light microscopy of the bone marrow aspirate, core biopsy, biopsy touch imprints, and/or clot section remains the fundamental component of diagnostic interpretation, although morphologic evaluation is often supplemented by immunophenotypic analysis, cytogenetic analysis, molecular studies, chimerism, microbiologic cultures, or other ancillary studies. The successful interpretation of bone marrow specimens requires a thorough understanding of the function and anatomy of this organ, and the influence of different disease processes, and the recognition of many technical and procedural artifacts that may be present. Bone marrow morphologic examination is essentially a matter of pattern recognition, aided by detailed knowledge of the subtle morphologic differences that may differentiate some diagnostic entities. Some ancillary studies are requested at the time of specimen procurement, as part of a disease or treatment-specific protocol, while others are ordered for the further evaluation a light microscopic finding. However, all data obtained from ancillary studies must be correlated with historical information and morphological findings and a thorough understanding of the technical aspects of the procedure is necessary to resolve discrepancies.

## REFERENCES

1. Frisch B, Bartl R. *Biopsy Interpretation of Bone and Bone Marrow*. London: Arnold; 1999.
2. Gulati GL, Ashton JK, Hyun BH. Structure and function of the bone marrow and hematopoiesis. *Hematol Oncol Clin North Am* 1988;2:495–511.
3. Brown DC, Gatter KC. The bone marrow trephine biopsy: A review of normal histology. *Histopathology* 1993;22:411–422.



4. Frisch B, Bartl R. Evaluation of Bone and Bone Marrow Biopsies. *Biopsy Interpretation of Bone and Bone Marrow*. London: Arnold; 1999. p 12–37.
5. Travlos GS. Histopathology of bone marrow. *Toxicol Pathol* 2006;34:566–598.
6. Travlos GS. Normal structure, function, and histology of the bone marrow. *Toxicol Pathol* 2006;34:548–565.
7. Chanavaz M. Anatomy and histophysiology of the periosteum: Quantification of the periosteal blood supply to the adjacent bone with <sup>85</sup>Sr and gamma spectrometry. *J Oral Implantol* 1995;21: 214–219.
8. Frisch B, Bartl R. Normal Bone Marrow. *Biopsy Interpretation of Bone and Bone Marrow*. London: Arnold; 1999. p 38–54.
9. Nardi NB, Alfonso ZZ. The hematopoietic stroma. *Braz J Med Biol Res* 1999;32:601–609.
10. Gordon MY. Physiology and function of the haemopoietic microenvironment. *Br J Haematol* 1994;86:241–243.
11. Mayani H, Guilbert LJ, Janowska-Wieczorek A. Biology of the hemopoietic microenvironment. *Eur J Haematol* 1992;49: 225–233.
12. Gimble JM, Robinson CE, Wu X, Kelly KA. The function of adipocytes in the bone marrow stroma: an update. *Bone* 1996;19:421–428.
13. Smith C. Hematopoietic stem cells and hematopoiesis. *Cancer Control* 2003;10:9–16.
14. Mauch P, Botnick LE, Hannon EC, Obbogy J, Hellman S. Decline in bone marrow proliferative capacity as a function of age. *Blood* 1982;60:245–252.
15. Fey MF. Normal and malignant hematopoiesis. *Ann Oncol* 2007;18:i9–i13.
16. Saharinen P. Signaling Through The Jak/Stat Pathway: Regulation of Tyrosine Kinase Activity. Helsinki: University of Helsinki; 2002. 102p.
17. Kaushansky K. Lineage-specific hematopoietic growth factors. *N Engl J Med* 2006;354(19):2034–2045.
18. Juul S, Felderhoff-Mueser U. Epo and other hematopoietic factors. *Semin Fetal Neonatal Med* 2007;12:250–258.
19. Nervi B, Link DC, DiPersio JF. Cytokines and hematopoietic stem cell mobilization. *J Cell Biochem* 2006;99:690–705.
20. Bessis M. Blood Smears Reinterpreted. Brecher G, Translator. Berlin: Springer; 1977. 270p.
21. Mel HC, Prenant M, Mohandas N. Reticulocyte motility and form: Studies on maturation and classification. *Blood* 1977;49: 1001–1001.
22. Castoldi GL, Beutler E. Erythrocytes. In: Zucker-Franklin D, Greaves MF, Grossi CE, Marmont AM, editors. *Atlas of Blood Cells Function and Pathology*, second edition. Philadelphia: Lea & Febiger; 1988. p 47–156.
23. Wojchowski DM, Menon MP, Sathyanarayana P, et al. Erythropoietin-dependent erythropoiesis: New insights and questions. *Blood Cells Mol Dis* 2006;36:232–238.
24. Richmond TD, Chohan M, Barber DL. Turning cells red: Signal transduction mediated by erythropoietin. *Trends Cell Biol* 2005;15:146–155.
25. Testa U. Apoptotic mechanisms in the control of erythropoiesis. *Leukemia* 2004;18:1176–1199.
26. Chasis JA. Erythroblastic islands: Specialized microenvironmental niches for erythropoiesis. *Current Opin Hematol* 2006;13: 137–141.
27. Chervenick PA, Zucker-Franklin D, Moore MAS. In vitro and in vivo hematopoiesis. In: Zucker-Franklin D, Greaves MF, Grossi CE, Marmont AM, editors. *Atlas of Blood Cells Function and Pathology*, second edition. Philadelphia: Lea & Febiger; 1988. p 3–27.
28. Faurschou M, Borregaard N. Neutrophil granules and secretory vesicles in inflammation. *Microbes Infect* 2003;5: 1317–1327.
29. Lee WL, Harrison RE, Grinstein S. Phagocytosis by neutrophils. *Microbes Infect* 2003;5:1299–1306.
30. Roos D, van Bruggen R, Meischl C. Oxidative killing of microbes by neutrophils. *Microbes Infect* 2003;5:1307–1315.
31. Kostyak JC, Naik UP. Megakaryopoiesis: Transcriptional insights into megakaryocyte maturation. *Front Biosci* 2007;12: 2050–2062.
32. Kirito K, Kaushansky K. Transcriptional regulation of megakaryopoiesis: Thrombopoietin signaling and nuclear factors. *Current Opin Hematol* 2006;13:151–156.
33. Szalai G, LaRue AC, Watson DK. Molecular mechanisms of megakaryopoiesis. *Cell Mol Life Sci* 2006;63:2460–2476.
34. Vyas H, Krishnaswamy G. Paul Ehrlich's "Mastzellen"—From aniline dyes to DNA chip arrays: A historical review of developments in mast cell research. *Methods Mol Biol* 2006;315: 3–11.
35. Payne V, Kam PC. Mast cell tryptase: A review of its physiology and clinical significance. *Anaesthesia* 2004;59:695–703.
36. Muschler GF, Nitto H, Boehm CA, Easley KA. Age- and gender-related changes in the cellularity of human bone marrow and the prevalence of osteoblastic progenitors. *J Orthop Res* 2001;19: 117–125.
37. Hartsock RJ, Smith EB, Petty CS. Normal variations with aging of the amount of hematopoietic tissue in bone marrow from the anterior iliac crest. A study made from 177 cases of sudden death examined by necropsy. *Am J Clin Pathol* 1965;43:326–331.
38. Friebert SE, Shepardson LB, Shurin SB, Rosenthal GE, Rosenthal NS. Pediatric bone marrow cellularity: Are we expecting too much? *J Pediatr Hematol Oncol* 1998;20:439–443.
39. Thiele J, Kvasnicka HM, Facchetti F, Franco V, van der Walt J, Orazi A. European consensus on grading bone marrow fibrosis and assessment of cellularity. *Haematologica* 2005;90:1128–1132.
40. Gruppo RA, Lampkin BC, Granger S. Bone marrow cellularity determination: Comparison of the biopsy, aspirate, and buffy coat. *Blood* 1977;49:29–31.
41. Fong TP, Okafor LA, Schmitz TH, Thomas W, Westerman MP. An evaluation of cellularity in various types of bone marrow specimens. *Am J Clin Pathol* 1979;72:812–816.
42. Wolff SN, Katzenstein AL, Phillips GL, Herzig GP. Aspiration does not influence interpretation of bone marrow biopsy cellularity. *Am J Clin Pathol* 1983;80:60–62.
43. Paul M, Chandy M, Pulimood R, Krishnaswami H. Cellularity of bone marrow—A comparison of trephine biopsies and aspirate smears. *Indian J Pathol Microbiol* 1989;32:186–189.
44. Ho-Yen DO, Slidders W. Bone marrow cellularity assessed by point-counting. *J Clin Pathol* 1978;31:753–756.
45. Kerndrup G, Pallesen G, Melsen F, Mosekilde L. Histomorphometrical determination of bone marrow cellularity in iliac crest biopsies. *Scand J Haematol* 1980;24:110–114.
46. Elmore SA. Enhanced histopathology of the bone marrow. *Toxicol Pathol* 2006;34:666–686.
47. Stuart-Smith SE, Hughes DA, Bain BJ. Are routine iron stains on bone marrow trephine biopsy specimens necessary? *J Clin Pathol* 2005;58:269–272.
48. Bain BJ. Bone marrow aspiration. *J Clin Pathol* 2001;54:657–663.
49. Buesche G, Georgii A, Kreipe HH. Diagnosis and quantification of bone marrow fibrosis are significantly biased by the pre-staining processing of bone marrow biopsies. *Histopathology* 2006;48:133–148.
50. Bauermeister DE. Quantitation of bone marrow reticulin—A normal range. *Am J Clin Pathol* 1971;56:24–31.

51. Buesche G, Georgii A, Duensing A, Schmeil A, Schlue J, Kreipe HH. Evaluating the volume ratio of bone marrow affected by fibrosis: A parameter crucial for the prognostic significance of marrow fibrosis in chronic myeloid leukemia. *Hum Pathol* 2003;34:391–401.
52. Diebold J, Molina T, Camilleri-Broet S, Le Tourneau A, Audouin J. Bone marrow manifestations of infections and systemic diseases observed in bone marrow trephine biopsy review. *Histopathology* 2000;37:199–211.
53. Janssens AM, Offner FC, Van Hove WZ. Bone marrow necrosis. *Cancer* 2000;88:1769–1780.
54. Paydas S, Ergin M, Baslamisli F, et al. Bone marrow necrosis: Clinicopathologic analysis of 20 cases and review of the literature. *Am J Hematol* 2002;70:300–305.
55. Zhu AX, Niesvizky R, Hedrick E, Fata F, Filippa DA, Michaeli J. Extensive bone marrow necrosis associated with multiple myeloma. *Leukemia* 1999;13:2118–2120.
56. Kiraly 3rd JF, Wheby MS. Bone marrow necrosis. *Am J Med* 1976;60:361–368.
57. Norgard MJ, Carpenter Jr JT, Conrad ME. Bone marrow necrosis and degeneration. *Arch Intern Med* 1979;139:905–911.
58. Maisel D, Lim JY, Pollock WJ, Yatani R, Liu PI. Bone marrow necrosis: An entity often overlooked. *Ann Clin Lab Sci* 1988;18:109–115.
59. Llewelyn MJ, Noursedeghi M, Dogan A, Edwards SG, Miller RF. Diagnostic utility of bone marrow sampling in HIV-infected patients since the advent of highly active antiretroviral therapy. *Int J STD AIDS* 2005;16:686–690.
60. Foucar K. Non-Hodgkin's lymphoma and Hodgkin's disease in bone marrow. In: Foucar K, editor. *Bone Marrow Pathology*. Chicago (IL): ASCP Press. p 343–375.
61. Dominis M, Pesut A, Borovecki A, Marusic-Vrsalovic M, Kusec R. Bone marrow lymphoid aggregates in malignant lymphomas. *Croat Med J* 2005;46:410–416.
62. Thiele J, Zirbes TK, Kvasnicka HM, Fischer R. Focal lymphoid aggregates (nodules) in bone marrow biopsies: Differentiation between benign hyperplasia and malignant lymphoma—A practical guideline. *J Clin Pathol* 1999;52:294–300.
63. Buhr T, Langer F, Schlue J, et al. Reliability of lymphoma classification in bone marrow trephines. *Br J Haematol* 2002;118:470–476.
64. Torlakovic E, Torlakovic G, Brunning RD. Follicular pattern of bone marrow involvement by follicular lymphoma. *Am J Clin Pathol* 2002;118:780–786.
65. Thomas JSJ. The diagnosis of lymphoid infiltrates in the bone marrow trephine. *Curr Diagn Pathol* 2004;10:236–245.
66. Arber DA, George TI. Bone marrow biopsy involvement by non-Hodgkin's lymphoma: Frequency of lymphoma types, patterns, blood involvement, and discordance with other sites in 450 specimens. *Am J Surg Pathol* 2005;29:1549–1557.
67. Leong TY, Leong AS. How does antigen retrieval work? *Adv Anat Pathol* 2007;14:129–131.
68. Anagnostou D. Pitfalls in the pattern of bone marrow infiltration in lymphoproliferative disorders. *Curr Diagn Pathol* 2005;11:170–179.
69. Campbell J, Seymour JF, Matthews J, Wolf M, Stone J, Juneja S. The prognostic impact of bone marrow involvement in patients with diffuse large cell lymphoma varies according to the degree of infiltration and presence of discordant marrow involvement. *Eur J Haematol* 2006;76:473–480.
70. Cotta CV, Konoplev S, Medeiros LJ, Bueso-Ramos CE. Metastatic tumors in bone marrow: Histopathology and advances in the biology of the tumor cells and bone marrow environment. *Ann Diagn Pathol* 2006;10:169–192.
71. Graf BL, Korte W, Schmid L, Schmid U, Cogliatti SB. Impact of aspirate smears and trephine biopsies in routine bone marrow diagnostics: A comparative study of 141 cases. *Swiss Med Wkly* 2005;135:151–159.
72. Janni W, Rack B, Lindemann K, Harbeck N. Detection of micrometastatic disease in bone marrow: Is it ready for prime time? *Oncologist* 2005;10:480–492.
73. Zach O, Lutz D. Tumor cell detection in peripheral blood and bone marrow. *Curr Opin Oncol* 2006;18:48–56.
74. Juneja SK, Wolf MM, Cooper IA. Value of bilateral bone marrow biopsy specimens in non-Hodgkin's lymphoma. *J Clin Pathol* 1990;43:630–632.
75. Luoni M, Declich P, De Paoli AP, et al. Bone marrow biopsy for the staging of non-Hodgkin's lymphoma: Bilateral or unilateral trephine biopsy? *Tumori* 1995;81:410–413.
76. Luoni M, Fava S, Declich P. Bone marrow biopsy for staging Hodgkin's lymphoma: The value of bilateral or unilateral trephine biopsy. *J Clin Oncol* 1996;14:682–683.
77. Menon NC, Buchanan JG. Bilateral trephine bone marrow biopsies in Hodgkin's and non-Hodgkin's lymphoma. *Pathology* 1979;11:53–57.
78. Valdes-Sanchez M, Nava-Ocampo AA, Palacios-Gonzalez RV, Perales-Arroyo A, Medina-Sanson A, Martinez-Avalos A. Diagnosis of bone marrow metastases in children with solid tumors and lymphomas. Aspiration, or unilateral or bilateral biopsy? *Arch Med Res* 2000;31:58–61.
79. Wang J, Weiss LM, Chang KL, et al. Diagnostic utility of bilateral bone marrow examination: Significance of morphologic and ancillary technique study in malignancy. *Cancer* 2002;94:1522–1531.
80. Moid F, DePalma L. Comparison of relative value of bone marrow aspirates and bone marrow trephine biopsies in the diagnosis of solid tumor metastasis and Hodgkin lymphoma: Institutional experience and literature review. *Arch Pathol Lab Med* 2005;129:497–501.
81. Lau D, Mollnau H, Eiserich JP, et al. Myeloperoxidase mediates neutrophil activation by association with CD11b/CD18 integrins. *Proc Natl Acad Sci USA* 2005;102:431–436.
82. Mufti GJ, Flandrin G, Schaefer H-E, Sandberg AA, Kanfer EJ. Appendix I. Selected Histological and Cytochemical Methods. An Atlas of Malignant Haematology Cytology, Histology, and Cytogenetics. Philadelphia: Lippincott-Raven Publishers; 1996. p 383–398.
83. Tanaka KR, Valentine WN, Fredricks RE. Diseases or clinical conditions associated with low leukocyte alkaline phosphatase. *N Engl J Med* 1960;262:912–918.
84. Koler RD, Seaman AJ, Osgood EE, Vanbellinghen P. Myeloproliferative diseases; Diagnostic value of the leukocyte alkaline phosphatase test. *Am J Clin Pathol* 1958;30:295–301.
85. Kaplow LS. A histochemical procedure for localizing and evaluating leukocyte alkaline phosphatase activity in smears of blood and marrow. *Blood* 1955;10:1023–1029.
86. Wiltshaw E, Moloney WC. Histochemical and biochemical studies on leukocyte alkaline phosphatase activity. *Blood* 1955;10:1120–1131.
87. Okamoto T, Okada M, Yamada S, et al. Flow-cytometric analysis of leukocyte alkaline phosphatase in myelodysplastic syndromes. *Acta Haematol* 1999;102:89–93.
88. Alamo AL, Melnick SJ. Clinical application of four and five-color flow cytometry lymphocyte subset immunophenotyping. *Cytometry* 2000;42:363–370.
89. Bleesing JJ, Fleisher TA. Immunophenotyping. *Semin Hematol* 2001;38:100–110.

90. Brown M, Wittwer C. Flow cytometry: Principles and clinical applications in hematology. *Clin Chem* 2000;46:1221–1229.
91. Regeczy N, Kormos L, Nahajevszky S, et al. Immunophenotyping in acute leukaemias and its value in detection of residual disease. In: Mason D, Andre P, Bensussan A, et al., editors. *Leucocyte Typing VII White Cell Differentiation Antigens. Proceedings of the Seventh International Workshop and Conference Held in Harrogate, United Kingdom*. New York, NY: Oxford University Press; 2002.
92. Mason DY, Andre P, Bensussan A, et al. CD antigens 2001. *Tissue Antigens* 2001;58:425–430.
93. Zola H. Human leucocyte differentiation antigens as therapeutic targets: The CD molecules and CD antibodies. *Expert Opin Biol Ther* 2001;1:375–383.
94. Mason D, Andre P, Bensussan A, et al. CD antigens 2002. *Blood* 2002;99(10):3877–3880.
95. Mason D, Andre P, Bensussan A, et al., editors. *Leucocyte Typing VII. White Cell Differentiation Antigens. Proceedings of the Seventh International Workshop and Conference held in Harrogate, United Kingdom*. New York, NY: Oxford University Press; 2002.
96. Zola H, Swart B, Bounsell L, Mason DY. Human leucocyte differentiation antigen nomenclature: Update on CD nomenclature. Report of IUIS/WHO Subcommittee. *J Immunol Methods* 2003;275:1–8.
97. True LD, Liu AY. A challenge for the diagnostic immunohistopathologist. Adding the CD phenotypes to our diagnostic toolbox. *Am J Clin Pathol* 2003;120:13–15.
98. Institute NC. Protein Reviews on the Web; 2005.
99. Ichinohasama R. Immunophenotypic analysis in the diagnosis of malignant lymphoma. *Nippon Rinsho* 2000;58:591–597.
100. Chu PG, Chang KL, Arber DA, Weiss LM. Practical applications of immunohistochemistry in hematolymphoid neoplasms. *Ann Diagn Pathol* 1999;3:104–133.
101. Leers MP, Theunissen PH, Ramaekers FC, Schutte B, Nap M. Clonality assessment of lymphoproliferative disorders by multiparameter flow cytometry of paraffin-embedded tissue: An additional diagnostic tool in surgical pathology. *Human Pathol* 2000;31:422–427.
102. Stetler-Stevenson M, Braylan RC. Flow cytometric analysis of lymphomas and lymphoproliferative disorders. *Semin Hematol* 2001;38:111–123.
103. Scheffold A, Kern F. Recent developments in flow cytometry. *J Clin Immunol* 2000;20:400–407.
104. Stewart CC. Multiparameter flow cytometry. *J Immunoassay* 2000;21:255–272.
105. Bakke AC. The principles of flow cytometry. *Lab Med* 2001;32:207–211.
106. Givan AL. Principles of flow cytometry: An overview. *Methods Cell Biol* 2001;63:19–50.
107. McCoy P. Flow cytometry. In: McClatchey KD, editor. *Clinical Laboratory Medicine*, second edition. Philadelphia: Lippincott, Williams, and Wilkins; 2002. p 1401–1425.
108. Mendelsohn ML. The attributes and applications of flow cytometry. *Acta Pathol Microbiol Immunol Scand* 1980;S274:15–27.
109. Chapman GV. Instrumentation for flow cytometry. *J Immunol Methods* 2000;243:3–12.
110. Kremer M, Quintanilla-Martinez L, Nahrig J, von Schilling C, Fend F. Immunohistochemistry in bone marrow pathology: A useful adjunct for morphologic diagnosis. *Virchows Arch* 2005;447:920–937.
111. Protein Reviews on the Web. CD MOLECULES. Human cell surface molecules recognized by the International Workshops on Human Leucocyte Differentiation Antigens.
112. Dahlke MH, Larsen SR, Rasko JE, Schlitt HJ. The biology of CD45 and its use as a therapeutic target. *Leuk Lymphoma* 2004;45:229–236.
113. Holmes N. CD45: All is not yet crystal clear. *Immunology* 2006;117:145–155.
114. Irie-Sasaki J, Sasaki T, Penninger JM. CD45 regulated signaling pathways. *Curr Top Med Chem* 2003;3:783–796.
115. Huntington ND, Tarlinton DM. CD45: Direct and indirect government of immune regulation. *Immunol Lett* 2004;94:167–174.
116. Hermiston ML, Xu Z, Weiss A. CD45: A critical regulator of signaling thresholds in immune cells. *Annu Rev Immunol* 2003;21:107–137.
117. Shah VO, Civin CI, Loken MR. Flow cytometric analysis of human bone marrow. IV. Differential quantitative expression of T-200 common leukocyte antigen during normal hemopoiesis. *J Immunol* 1988;140:1861–1867.
118. Thomas ML, Lefrancois L. Differential expression of the leucocyte-common antigen family. *Immunol Today* 1988;9:320–326.
119. Nicholson JK, Hubbard M, Jones BM. Use of CD45 fluorescence and side-scatter characteristics for gating lymphocytes when using the whole blood lysis procedure and flow cytometry. *Cytometry* 1996;26:16–21.
120. Stelzer GT, Shults KE, Loken MR. CD45 gating for routine flow cytometric analysis of human bone marrow specimens. *Ann N Y Acad Sci* 1993;677:265–280.
121. Glencross D, Scott LE, Jani IV, Barnett D, Janossy G. CD45-assisted PanLeucogating for accurate, cost-effective dual-platform CD4<sup>+</sup> T-cell enumeration. *Cytometry* 2002;50:69–77.
122. Vial JP, Lacombe F. Immunophenotyping of acute leukemia: Utility of CD45 for blast cell identification. *Methods Cell Biol* 2001;64:343–358.
123. Wood B. Multicolor immunophenotyping: Human immune system hematopoiesis. *Methods Cell Biol* 2004;75:559–576.
124. Paietta E. Detection of terminal transferase in leukemia. *Methods Mol Biol* 1998;91:25–36.
125. Kaleem Z, Crawford E, Pathan MH, et al. Flow cytometric analysis of acute leukemias. Diagnostic utility and critical analysis of data. *Arch Pathol Lab Med* 2003;127:42–48.
126. Rimsza LM, Larson RS, Winter SS, et al. Benign hematogone-rich lymphoid proliferations can be distinguished from B-lineage acute lymphoblastic leukemia by integration of morphology, immunophenotype, adhesion molecule expression, and architectural features. *Am J Clin Pathol* 2000;114:66–75.
127. Liu L, McGavran L, Lovell MA, et al. Nonpositive terminal deoxynucleotidyl transferase in pediatric precursor B-lymphoblastic leukemia. *Am J Clin Pathol* 2004;121:810–815.
128. Walker J, Green JM. Structural requirements for CD43 function. *J Immunol* 1999;162:4109–4114.
129. Contos MJ, Kornstein MJ, Innes DJ, Ben-Ezra J. The utility of CD20 and CD43 in subclassification of low-grade B-cell lymphoma on paraffin sections. *Mod Pathol* 1992;5:631–633.
130. Segal GH, Stoler MH, Tubbs RR. The “CD43 only” phenotype. An aberrant, nonspecific immunophenotype requiring comprehensive analysis for lineage resolution. *Am J Clin Pathol* 1992;97:861–865.
131. Jung G, Eisenmann JC, Thiebault S, Henon P. Cell surface CD43 determination improves diagnostic precision in late B-cell diseases. *Br J Haematol* 2003;120:496–499.
132. Blumberg RS, Gerdes D, Chott A, Porcelli SA, Balk SP. Structure and function of the CD1 family of MHC-like cell surface proteins. *Immunol Rev* 1995;147:5–29.

133. Hava DL, Brigl M, van den Elzen P, Zajonc DM, Wilson IA, Brenner MB. CD1 assembly and the formation of CD1-antigen complexes. *Curr Opin Immunol* 2005;17:88–94.
134. Dougan SK, Kaser A, Blumberg RS. CD1 expression on antigen-presenting cells. *Curr Topics Microbiol Immunol* 2007;314:113–141.
135. Zajonc DM, Wilson IA. Architecture of CD1 proteins. *Curr Topics Microbiol Immunol* 2007;314:27–50.
136. Young DC, Moody DB. T-cell recognition of glycolipids presented by CD1 proteins. *Glycobiology* 2006;16:103R–112R.
137. Gumperz JE. The ins and outs of CD1 molecules: Bringing lipids under immunological surveillance. *Traffic* 2006;7:2–13.
138. Salamone MC, Roisman FR, Santiago J, Satz ML, Fainboim L. Analysis of CD1 molecules on haematological malignancies of myeloid and lymphoid origin. I. Cell surface antigen expression. *Dis Markers* 1990;8:265–274.
139. Salamone MC, Roisman FR, Morelli AE, Noli MI, Fainboim L. Analysis of CD1 molecules on haematological malignancies of myeloid and lymphoid origin. II. Intracellular detection of CD1 antigens. *Dis Markers* 1990;8:275–281.
140. Ferrara F, Cimino R, Antinolfi I, et al. Clinical relevance of immunological dissection in T-ALL: A report on 20 cases with stem cell (CD7<sup>+</sup>, CD4<sup>-</sup>, CD8<sup>-</sup>, CD1<sup>-</sup>) phenotype. *Am J Hematol* 1992;40:98–102.
141. Yang JJ, Ye Y, Carroll A, Yang W, Lee HW. Structural biology of the cell adhesion protein CD2: Alternatively folded states and structure-function relation. *Curr Protein Pept Sci* 2001;2:1–17.
142. Bromberg JS. The biology of CD2: Adhesion, transmembrane signal, and regulatory receptor of immunity. *J Surg Res* 1993;54:258–267.
143. McNerney ME, Kumar V. The CD2 family of natural killer cell receptors. *Curr Topics Microbiol Immunol* 2006;298:91–120.
144. Jamal S, Picker LJ, Aquino DB, McKenna RW, Dawson DB, Kroft SH. Immunophenotypic analysis of peripheral T-cell neoplasms. A multiparameter flow cytometric approach. *Am J Clin Pathol* 2001;116:512–526.
145. Lin P, Hao S, Medeiros LJ, et al. Expression of CD2 in acute promyelocytic leukemia correlates with short form of PML-RARalpha transcripts and poorer prognosis. *Am J Clin Pathol* 2004;121:402–407.
146. Della Porta MG. CD34 and CD2 expression in acute promyelocytic leukemia. *Haematologica* 2006;91:289C.
147. Kuhns MS, Davis MM, Garcia KC. Deconstructing the form and function of the TCR/CD3 complex. *Immunity* 2006;24:133–139.
148. Minguet S, Swamy M, Alarcon B, Luescher IF, Schamel WW. Full activation of the T cell receptor requires both clustering and conformational changes at CD3. *Immunity* 2007;26:43–54.
149. Mandy FF, Bergeron M, Minkus T. Evolution of leukocyte immunophenotyping as influenced by the HIV/AIDS pandemic: A short history of the development of gating strategies for CD4<sup>+</sup> T-cell enumeration. *Cytometry* 1997;30:157–165.
150. Nicholson JK. Immunophenotyping specimens from HIV-infected persons: Laboratory guidelines from the Centers for Disease Control and Prevention. *Cytometry* 1994;18:55–59.
151. Leahy DJ. A structural view of CD4 and CD8. *FASEB J* 1995;9:17–25.
152. Janeway Jr CA. The role of CD4 in T-cell activation: Accessory molecule or co-receptor? *Immunol Today* 1989;10:234–238.
153. Harmon CB, Witzig TE, Katzmann JA, Pittelkow MR. Detection of circulating T cells with CD4<sup>+</sup> CD7<sup>-</sup> immunophenotype in patients with benign and malignant lymphoproliferative dermatoses. *J Am Acad Dermatol* 1996;35:404–410.
154. Rappl G, Mucche JM, Abken H, et al. CD4<sup>(+)</sup>CD7<sup>(-)</sup> T cells compose the dominant T-cell clone in the peripheral blood of patients with Sezary syndrome. *J Am Acad Dermatol* 2001;44:456–461.
155. Sarrias MR, Gronlund J, Padilla O, Madsen J, Holmskov U, Lozano F. The Scavenger receptor cysteine-rich (SRCR) domain: An ancient and highly conserved protein module of the innate immune system. *Crit Rev Immunol* 2004;24:1–37.
156. Dono M, Cerruti G, Zupo S. The CD5<sup>+</sup> B-cell. *Int J Biochem Cell Biol* 2004;36:2105–2111.
157. Sempowski GD, Lee DM, Kaufman RE, Haynes BF. Structure and function of the CD7 molecule. *Crit Rev Immunol* 1999;19:331–348.
158. Chan AS, Reynolds PJ, Shimizu Y. Tyrosine kinase activity associated with the CD7 antigen: Correlation with regulation of T cell integrin function. *Eur J Immunol* 1994;24:2602–2608.
159. Barcena A, Muench MO, Roncarolo MG, Spits H. Tracing the expression of CD7 and other antigens during T- and myeloid-cell differentiation in the human fetal liver and thymus. *Leuk Lymphoma* 1995;17:1–11.
160. Pagnucco G, Vanelli L, Gervasi F. Multidimensional flow cytometry immunophenotyping of hematologic malignancy. *Ann N Y Acad Sci* 2002;963:313–321.
161. Tiftik N, Bolaman Z, Batun S, et al. The importance of CD7 and CD56 antigens in acute leukaemias. *Int J Clin Pract* 2004;58:149–152.
162. Murphy M, Fullen D, Carlson JA. Low CD7 expression in benign and malignant cutaneous lymphocytic infiltrates: Experience with an antibody reactive with paraffin-embedded tissue. *Am J Dermatopathol* 2002;24:6–16.
163. Chang H, Yeung J, Brandwein J, Yi QL. CD7 expression predicts poor disease free survival and post-remission survival in patients with acute myeloid leukemia and normal karyotype. *Leuk Res* 2007;31:157–162.
164. Singer A, Bosselut R. CD4/CD8 coreceptors in thymocyte development, selection, and lineage commitment: Analysis of the CD4/CD8 lineage decision. *Adv Immunol* 2004;83:91–131.
165. Zamoyska R. CD4 and CD8: Modulators of T-cell receptor recognition of antigen and of immune responses? *Curr Opin Immunol* 1998;10:82–87.
166. Devine L, Kavathas PB. Molecular analysis of protein interactions mediating the function of the cell surface protein CD8. *Immunol Res* 1999;19:201–210.
167. Gorczyca W, Weisberger J, Liu Z, et al. An approach to diagnosis of T-cell lymphoproliferative disorders by flow cytometry. *Cytometry* 2002;50:177–190.
168. van Sorge NM, van der Pol WL, van de Winkel JG. FcγR polymorphisms: Implications for function, disease susceptibility and immunotherapy. *Tissue Antigens* 2003;61:189–202.
169. Cohen-Solal JF, Cassard L, Fridman WH, Sautes-Fridman C. Fcγ receptors. *Immunol Lett* 2004;92:199–205.
170. Perussia B, Trinchieri G, Jackson A, et al. The Fc receptor for IgG on human natural killer cells: Phenotypic, functional, and comparative studies with monoclonal antibodies. *J Immunol* 1984;133:180–189.
171. Looney RJ, Abraham GN, Anderson CL. Human monocytes and U937 cells bear two distinct Fc receptors for IgG. *J Immunol* 1986;136:1641–1647.
172. Fleit HB. Monoclonal antibodies to human neutrophil FcγRIII (CD16) identify polypeptide epitopes. *Clin Immunol Immunopathol* 1991;59:222–235.
173. Groh V, Porcelli S, Fabbi M, et al. Human lymphocytes bearing T cell receptor gamma/delta are phenotypically diverse and

- evenly distributed throughout the lymphoid system. *J Exp Med* 1989;169:1277–1294.
174. Schubert J, Lanier LL, Schmidt RE. Cluster report: CD56. In: Knapp W, Dörken B, Rieber EP, et al., editors. *Leucocyte Typing IV White Cell Differentiation Antigens*. Oxford: Oxford University Press; 1989. p 699–702.
  175. Umezawa Y, Kuge S, Kikyo N, et al. Identity of brain-associated small cell lung cancer antigen and the CD56 (NKH-1/Leu-19) leukocyte differentiation antigen and the neural cell adhesion molecule. *Jpn J Clin Oncol* 1991;21:251–255.
  176. Cooper MA, Fehniger TA, Caligiuri MA. The biology of human natural killer-cell subsets. *Trends Immunol* 2001;22:633–640.
  177. Lee JJ, Chung IJ, Yang DH, et al. Clinical significance of CD56 expression in patients with acute myeloid leukemia. *Leuk Lymphoma* 2002;43:1897–1899.
  178. Ferrara F, Morabito F, Martino B, et al. CD56 expression is an indicator of poor clinical outcome in patients with acute promyelocytic leukemia treated with simultaneous all-trans-retinoic acid and chemotherapy. *J Clin Oncol* 2000;18:1295–1300.
  179. Yang DH, Lee JJ, Mun YC, et al. Predictable prognostic factor of CD56 expression in patients with acute myeloid leukemia with t(8:21) after high dose cytarabine or allogeneic hematopoietic stem cell transplantation. *Am J Hematol* 2007;82:1–5.
  180. Ely SA, Knowles DM. Expression of CD56/neural cell adhesion molecule correlates with the presence of lytic bone lesions in multiple myeloma and distinguishes myeloma from monoclonal gammopathy of undetermined significance and lymphomas with plasmacytoid differentiation. *Am J Pathol* 2002;160:1293–1299.
  181. Schubert J, Lanier L, Schmidt RE. Cluster report: CD57. In: Knapp W, Dörken B, Rieber EP, et al., editors. *Leucocyte Typing IV White Cell Differentiation Antigens*. Oxford: Oxford University Press; 1989. p 711–714.
  182. van den Berg LH, Sadiq SA, Thomas FP, Latov N. Characterization of HNK-1 bearing glycoproteins in human peripheral nerve myelin. *J Neurosci Res* 1990;25:295–299.
  183. Evans TG, Kallas EG, Luque AE, Menegus M, McNair C, Looney RJ. Expansion of the CD57 subset of CD8 T cells in HIV-1 infection is related to CMV serostatus. *Aids* 1999;13:1139–1141.
  184. Weekes MP, Wills MR, Mynard K, Hicks R, Sissons JG, Carmichael AJ. Large clonal expansions of human virus-specific memory cytotoxic T lymphocytes within the CD57<sup>+</sup> CD28<sup>-</sup> CD8<sup>+</sup> T-cell population. *Immunology* 1999;98:443–449.
  185. Rowbottom AW, Garland RJ, Lepper MW, et al. Functional analysis of the CD8<sup>+</sup> CD57<sup>+</sup> cell population in normal healthy individuals and matched unrelated T-cell-depleted bone marrow transplant recipients. *Br J Haematol* 2000;110:315–321.
  186. Pulford K, Mason D. CD246 (ALK) cluster report. In: Mason D, Andre P, Bensussan A, et al., editors. *Leucocyte Typing VII White Cell Differentiation Antigens*. Proceedings of the Seventh International Workshop and Conference held in Harrogate, United Kingdom. New York, NY: Oxford University Press; 2002.
  187. Morris SW, Naeve C, Mathew P, et al. ALK, the chromosome 2 gene locus altered by the t(2;5) in non-Hodgkin's lymphoma, encodes a novel neural receptor tyrosine kinase that is highly related to leukocyte tyrosine kinase (LTK). *Oncogene* 1997;14:2175–2188.
  188. Epstein J. Alk-1 expression in inflammatory myofibroblastic tumor of the urinary bladder. *Am J Surg Pathol* 2005;29:839.
  189. Jaffe ES. Anaplastic large cell lymphoma: The shifting sands of diagnostic hematopathology. *Mod Pathol* 2001;14:219–228.
  190. Gascoyne RD, Lamant L, Martin-Subero JJ, et al. ALK-positive diffuse large B-cell lymphoma is associated with Clathrin-ALK rearrangements: Report of 6 cases. *Blood* 2003;102:2568–2573.
  191. Bubala H, Malydy J, Wlodarska I, Sonta-Jakimeczyk D, Szczepanski T. ALK-positive diffuse large B-cell lymphoma. *Pediatr Blood Cancer* 2006;46:649–653.
  192. LeBien TW, McCormack RT. The common acute lymphoblastic leukemia antigen (CD10)—Emancipation from a functional enigma. *Blood* 1989;73:625–635.
  193. Turner AJ, Isaac RE, Coates D. The neprilysin (NEP) family of zinc metalloendopeptidases: Genomics and function. *Bioessays* 2001;23:261–269.
  194. Bene MC, Faure GC. CD10 in acute leukemias. GEIL (Groupe d'Etude Immunologique des Leucemies). *Haematologica* 1997;82:205–210.
  195. Xu Y, McKenna RW, Kroft SH. Comparison of multiparameter flow cytometry with cluster analysis and immunohistochemistry for the detection of CD10 in diffuse large B-Cell lymphomas. *Mod Pathol* 2002;15:413–419.
  196. Xu Y, McKenna RW, Kroft SH. Assessment of CD10 in the diagnosis of small B-cell lymphomas: A multiparameter flow cytometric study. *Am J Clin Pathol* 2002;117:291–300.
  197. Riley RS, Massey D, Jackson-Cook C, Idowu M, Romagnoli G. Immunophenotypic analysis of acute lymphocytic leukemia. *Hematol Oncol Clin North Am* 2002;16:245–299.
  198. Attarbaschi A, Mann G, Konig M, et al. Mixed lineage leukemia-rearranged childhood pro-B and CD10-negative pre-B acute lymphoblastic leukemia constitute a distinct clinical entity. *Clin Cancer Res* 2006;12:2988–2994.
  199. Hirose J, Kouro T, Igarashi H, Yokota T, Sakaguchi N, Kincaide PW. A developing picture of lymphopoiesis in bone marrow. *Immunol Rev* 2002;189:28–40.
  200. Bertram HC, Check IJ, Milano MA. Immunophenotyping large B-cell lymphomas. Flow cytometric pitfalls and pathologic correlation. *Am J Clin Pathol* 2001;116:191–203.
  201. Robak T. Monoclonal antibodies in the treatment of chronic lymphoid leukemias. *Leuk Lymphoma* 2004;45:205–219.
  202. Tedder TF, Distechi CM, Louie E, et al. The gene that encodes the human CD20 (B1) differentiation antigen is located on chromosome 11 near the t(11;14)(q13;q32) translocation site. *J Immunol* 1989;142:2555–2559.
  203. Cragg MS, Walshe CA, Ivanov AO, Glennie MJ. The biology of CD20 and its potential as a target for mAb therapy. *Curr Dir Autoimmun* 2005;8:140–174.
  204. Pescovitz MD. Rituximab, an anti-cd20 monoclonal antibody: History and mechanism of action. *Am J Transplant* 2006;6:859–866.
  205. Nadler LM, Stashenko P, Hardy R, van Agthoven A, Terhorst C, Schlossman SF. Characterization of a human B cell-specific antigen (B2) distinct from B1. *J Immunol* 1981;126:1941–1947.
  206. Iida K, Nadler L, Nussenzweig V. Identification of the membrane receptor for the complement fragment C3d by means of a monoclonal antibody. *J Exp Med* 1983;158:1021–1033.
  207. Tessier J, Cuvillier A, Glaudet F, Khamlichi AA. Internalization and molecular interactions of human CD21 receptor. *Mol Immunol* 2007;44:2415–2425.
  208. Dörken B, Möller P, Pezzutto A, Schwartz-Albeiz R, Moldenhauer G. B-cell antigens: CD21. In: Knapp W, Dörken B, Rieber EP, et al., editors. *Leucocyte Typing IV White Cell Differentiation Antigens*. Oxford: Oxford University Press; 1989. p 58–60.
  209. Cooper NR, Bradt BM, Rhim JS, Nemerow GR. CR2 complement receptor. *J Invest Dermatol* 1990;94:112S–117S.

210. Schuurman HJ, Hupples W, Verdonck LF, Van Baarlen J, Van Unnik JA. Immunophenotyping of non-Hodgkin's lymphoma. Correlation with relapse-free survival. *Am J Pathol* 1988;131:102-111.
211. Echeverri C, Fisher S, King D, Craig FE. Immunophenotypic variability of B-cell non-Hodgkin lymphoma: A retrospective study of cases analyzed by flow cytometry. *Am J Clin Pathol* 2002;117:615-620.
212. Shiozawa E, Yamochi-Onizuka T, Yamochi T, et al. Disappearance of CD21-positive follicular dendritic cells preceding the transformation of follicular lymphoma: Immunohistological study of the transformation using CD21, p53, Ki-67, and P-glycoprotein. *Pathol Res Pract* 2003;199:293-302.
213. Otsuka M, Yakushijin Y, Hamada M, Hato T, Yasukawa M, Fujita S. Role of CD21 antigen in diffuse large B-cell lymphoma and its clinical significance. *Br J Haematol* 2004;127:416-424.
214. Deaglio S, Vaisitti T, Bergui L, et al. CD38 and CD100 lead a network of surface receptors relaying positive signals for B-CLL growth and survival. *Blood* 2005;105:3042-3050.
215. Partida-Sanchez S, Rivero-Nava L, Shi G, Lund FE. CD38: An ecto-enzyme at the crossroads of innate and adaptive immune responses. *Adv Exp Med Biol* 2007;590:171-183.
216. Lin P, Owens R, Tricot G, Wilson CS. Flow cytometric immunophenotypic analysis of 306 cases of multiple myeloma. *Am J Clin Pathol* 2004;121:482-488.
217. Mainou-Fowler T, Dignum HM, Proctor SJ, Summerfield GP. The prognostic value of CD38 expression and its quantification in B cell chronic lymphocytic leukemia (B-CLL). *Leuk Lymphoma* 2004;45:455-462.
218. Thornton PD, Fernandez C, Giustolisi GM, et al. CD38 expression as a prognostic indicator in chronic lymphocytic leukaemia. *Hematol J* 2004;5:145-151.
219. Hus I, Podhorecka M, Bojarska-Junak A, et al. The clinical significance of ZAP-70 and CD38 expression in B-cell chronic lymphocytic leukaemia. *Ann Oncol* 2006;17:683-690.
220. Ng AP, Wei A, Bhurani D, Chapple P, Feleppa F, Juneja S. The sensitivity of CD138 immunostaining of bone marrow trephine specimens for quantifying marrow involvement in MGUS and myeloma, including samples with a low percentage of plasma cells. *Haematologica* 2006;91:972-975.
221. Sun WP, Wang FM, Xie F, et al. A novel anti-human Syndecan-1 (CD138) monoclonal antibody 4B3: Characterization and application. *Cell Mol Immunol* 2007;4:209-214.
222. Ekholm SV, Reed SI. Regulation of G(1) cyclin-dependent kinases in the mammalian cell cycle. *Curr Opin Cell Biol* 2000;12:676-684.
223. McGowan CH. Regulation of the eukaryotic cell cycle. *Prog Cell Cycle Res* 2003;5:1-4.
224. Tashiro E, Tsuchiya A, Imoto M. Functions of cyclin D1 as an oncogene and regulation of cyclin D1 expression. *Cancer Sci* 2007;98:629-635.
225. Lesage D, Troussard X, Sola B. The enigmatic role of cyclin D1 in multiple myeloma. *Int J Cancer* 2005;115:171-176.
226. Liu H, Wang J, Epner EM. Cyclin D1 activation in B-cell malignancy: Association with changes in histone acetylation, DNA methylation, and RNA polymerase II binding to both promoter and distal sequences. *Blood* 2004;104:2505-2513.
227. Oertel J, Kingreen D, Busemann C, Stein H, Dorken B. Morphologic diagnosis of leukaemic B-lymphoproliferative disorders and the role of cyclin D1 expression. *J Cancer Res Clin Oncol* 2002;128:182-188.
228. Vasef MA, Medeiros LJ, Koo C, McCourty A, Brynes RK. Cyclin D1 immunohistochemical staining is useful in distinguishing mantle cell lymphoma from other low-grade B-cell neoplasms in bone marrow. *Am J Clin Pathol* 1997;108:302-307.
229. Yatabe Y, Suzuki R, Matsuno Y, et al. Morphological spectrum of cyclin D1-positive mantle cell lymphoma: Study of 168 cases. *Pathol Int* 2001;51:747-761.
230. Droin NM, Green DR. Role of Bcl-2 family members in immunity and disease. *Biochim Biophys Acta* 2004;1644:179-188.
231. Walensky LD. BCL-2 in the crosshairs: Tipping the balance of life and death. *Cell Death Differ* 2006;13:1339-1350.
232. Cook JR, Craig FE, Swerdlow SH. bcl-2 expression by multi-color flow cytometric analysis assists in the diagnosis of follicular lymphoma in lymph node and bone marrow. *Am J Clin Pathol* 2003;119:145-151.
233. Pasqualucci L, Bereschenko O, Niu H, et al. Molecular pathogenesis of non-Hodgkin's lymphoma: The role of Bcl-6. *Leuk Lymphoma* 2003;44:S5-S12.
234. Ranuncolo SM, Polo JM, Dierov J, et al. Bcl-6 mediates the germinal center B cell phenotype and lymphomagenesis through transcriptional repression of the DNA-damage sensor ATR. *Nat Immunol* 2007;8:705-714.
235. Torlakovic E, Torlakovic G, Nguyen PL, Brunning RD, Delabie J. The value of anti-pax-5 immunostaining in routinely fixed and paraffin-embedded sections: A novel pan pre-B and B-cell marker. *Am J Surg Pathol* 2002;26:1343-1350.
236. Foss HD, Reusch R, Demel G, et al. Frequent expression of the B-cell-specific activator protein in Reed-Sternberg cells of classical Hodgkin's disease provides further evidence for its B-cell origin. *Blood* 1999;94:3108-3113.
237. Zhang X, Lin Z, Kim I. Pax5 expression in non-Hodgkin's lymphomas and acute leukemias. *J Korean Med Sci* 2003;18:804-808.
238. Browne P, Petrosyan K, Hernandez A, Chan JA. The B-cell transcription factors BSAP, Oct-2, and BOB.1 and the pan-B-cell markers CD20, CD22, and CD79a are useful in the differential diagnosis of classic Hodgkin lymphoma. *Am J Clin Pathol* 2003;120:767-777.
239. Springer TA, Dustin ML, Kishimoto TK, Marlin SD. The lymphocyte function-associated LFA-1, CD2, and LFA-3 molecules: Cell adhesion receptors of the immune system. *Annu Rev Immunol* 1987;5:223-252.
240. Mazzone A, Ricevuti G. Leukocyte CD11/CD18 integrins: Biological and clinical relevance. *Haematologica* 1995;80:161-175.
241. Graf M, Reif S, Kroll T, Hecht K, Nuessler V, Schmetzer H. Expression of MAC-1 (CD11b) in acute myeloid leukemia (AML) is associated with an unfavorable prognosis. *Am J Hematol* 2006;81:227-235.
242. Robbins BA, Ellison DJ, Spinosa JC, et al. Diagnostic application of two-color flow cytometry in 161 cases of hairy cell leukemia. *Blood* 1993;82:1277-1287.
243. Nicolaou F, Teodoridis JM, Park H, et al. CD11c gene expression in hairy cell leukemia is dependent upon activation of the proto-oncogenes ras and junD. *Blood* 2003;101:4033-4041.
244. Cowburn AS, Sobolewski A, Reed BJ, et al. Aminopeptidase N (CD13) regulates tumor necrosis factor-alpha-induced apoptosis in human neutrophils. *J Biol Chem* 2006;281:12458-12467.
245. Mina-Osorio P, Shapiro LH, Ortega E. CD13 in cell adhesion: Aminopeptidase N (CD13) mediates homotypic aggregation of monocytic cells. *J Leukoc Biol* 2006;79:719-730.
246. Reinhold D, Biton A, Pieper S, et al. Dipeptidyl peptidase IV (DP IV, CD26) and aminopeptidase N (APN, CD13) as regulators of T cell function and targets of immunotherapy in CNS inflammation. *Int Immunopharmacol* 2006;6:1935-1942.

247. Gadd S. Cluster report: CD13. In: Knapp W, Dörken B, Rieber EP, et al., editors. *Leucocyte Typing IV White Cell Differentiation Antigens*. Oxford: Oxford University Press; 1989. p 782–784.
248. Orfao A, Chillon MC, Bortolucci AM, et al. The flow cytometric pattern of CD34, CD15 and CD13 expression in acute myeloblastic leukemia is highly characteristic of the presence of PML-RARalpha gene rearrangements. *Haematologica* 1999; 84:405–412.
249. Kotylo PK, Seo IS, Smith FO, et al. Flow cytometric immunophenotypic characterization of pediatric and adult minimally differentiated acute myeloid leukemia (AML-M0). *Am J Clin Pathol* 2000;113:193–200.
250. Kraguljac N, Marisavljevic D, Jankovic G, et al. Characterization of CD13 and CD33 surface antigen-negative acute myeloid leukemia. *Am J Clin Pathol* 2000;114:29–34.
251. Ferrero E, Hsieh CL, Francke U, Goyert SM. CD14 is a member of the family of leucine-rich proteins and is encoded by a gene syntenic with multiple receptor genes. *J Immunol* 1990;145: 331–336.
252. Haziot A, Chen S, Ferrero E, Low MG, Silber R, Goyert SM. The monocyte differentiation antigen, CD14, is anchored to the cell membrane by a phosphatidylinositol linkage. *J Immunol* 1988;141:547–552.
253. Goyert SM, Ferrero E, Rettig WJ, Yenamandra AK, Obata F, Le Beau MM. The CD14 monocyte differentiation antigen maps to a region encoding growth factors and receptors. *Science* 1988;239:497–500.
254. Fujihara M, Muroi M, Tanamoto K, Suzuki T, Azuma H, Ikeda H. Molecular mechanisms of macrophage activation and deactivation by lipopolysaccharide: Roles of the receptor complex. *Pharmacol Ther* 2003;100:171–194.
255. Finberg RW, Kurt-Jones EA. CD14: Chaperone or matchmaker? *Immunity* 2006;24:127–129.
256. Goyert SM, Ferrero EM, Seremetis SV, Winchester RJ, Silver J, Mattison AC. Biochemistry and expression of myelomonocytic antigens. *J Immunol* 1986;137:3909–3914.
257. Ziegler-Heitbrock HW, Pechumer H, Petersmann I, et al. CD14 is expressed and functional in human B cells. *Eur J Immunol* 1994;24:1937–1940.
258. Skubitz KM, Snook 2nd RW. Monoclonal antibodies that recognize lacto-N-fucopentaose III (CD15) react with the adhesion-promoting glycoprotein family (LFA-1/HMac-1/gp 150,95) and CR1 on human neutrophils. *J Immunol* 1987;139: 1631–1639.
259. Warren HS, Altin JG, Waldron JC, Kinnear BF, Parish CR. A carbohydrate structure associated with CD15 (Lewis x) on myeloid cells is a novel ligand for human CD2. *J Immunol* 1996;156:2866–2873.
260. Schwartz-Albiez B. CD15 workshop report. In: Mason D, Andre P, Bensussan A, et al., editors. *Leucocyte Typing VII White Cell Differentiation Antigens*. Proceedings of the Seventh International Workshop and Conference held in Harrogate, United Kingdom. New York, NY: Oxford University Press; 2002. p 178–179.
261. Hakomori S. Le(X) and related structures as adhesion molecules. *Histochem J* 1992;24:771–776.
262. Peiper SC, Ashmun RA, Look AT. Molecular cloning, expression, and chromosomal localization of a human gene encoding the CD33 myeloid differentiation antigen. *Blood* 1988;72: 314–321.
263. Ulyanova T, Blasioli J, Woodford-Thomas TA, Thomas ML. The sialoadhesin CD33 is a myeloid-specific inhibitory receptor. *Eur J Immunol* 1999;29:3440–3449.
264. Wellhausen SR, Peiper SC. CD33: Biochemical and biological characterization and evaluation of clinical relevance. *J Biol Regul Homeost Agents* 2002;16:139–143.
265. Paul SP, Taylor LS, Stansbury EK, McVicar DW. Myeloid specific human CD33 is an inhibitory receptor with differential ITIM function in recruiting the phosphatases SHP-1 and SHP-2. *Blood* 2000;96:483–490.
266. Mingari MC, Vitale C, Romagnani C, Falco M, Moretta L. Regulation of myeloid cell proliferation and survival by p75/AIRM1 and CD33 surface receptors. *Adv Exp Med Biol* 2001;495:55–61.
267. Avril T, Attrill H, Zhang J, Raper A, Crocker PR. Negative regulation of leucocyte functions by CD33-related siglecs. *Biochem Soc Trans* 2006;34:1024–1027.
268. Linenberger ML. CD33-directed therapy with gemtuzumab ozogamicin in acute myeloid leukemia: Progress in understanding cytotoxicity and potential mechanisms of drug resistance. *Leukemia* 2005;19:176–182.
269. Nakase K, Kita K, Shiku H, et al. Myeloid antigen, CD13, CD14, and/or CD33 expression is restricted to certain lymphoid neoplasms. *Am J Clin Pathol* 1996;105:761–768.
270. Sutherland DR, Watt SM, Dowden G, et al. Structural and partial amino acid sequence analysis of the human hemopoietic progenitor cell antigen CD34. *Leukemia* 1988;2:793–803.
271. Tenen DG, Satterthwaite AB, Borson R, Simmons D, Eddy RL, Shows TB. Chromosome 1 localization of the gene for CD34, a surface antigen of human stem cells. *Cytogenet Cell Genet* 1990;53:55–57.
272. Krause DS, Fackler MJ, Civin CI, May WS. CD34: Structure, biology, and clinical utility. *Blood* 1996;87:1–13.
273. Fackler MJ, Civin CI, Sutherland DR, Baker MA, May WS. Activated protein kinase C directly phosphorylates the CD34 antigen on hematopoietic cells. *J Biol Chem* 1990;265: 11056–11061.
274. Furness SG, McNagny K. Beyond mere markers: Functions for CD34 family of sialomucins in hematopoiesis. *Immunol Res* 2006;34:13–32.
275. Fina L, Molgaard HV, Robertson D, et al. Expression of the CD34 gene in vascular endothelial cells. *Blood* 1990;75: 2417–2426.
276. Sowala H, Wunder E, Henon P. Purification and characterisation of the CD34<sup>+</sup> hematopoietic precursor cell population by flow cytometry. *Bone Marrow Transplant* 1990;5:9–10.
277. Barton Furness SG, McNagny K. Beyond mere markers: Functions for CD34 family of sialomucins in hematopoiesis. *Immunol Res* 2006;34:13–32.
278. Civin CI, Trischmann TM, Fackler MJ, et al. Report on the CD34 cluster. In: Knapp W, Dörken B, Rieber EP, et al., editors. *Leucocyte Typing IV White Cell Differentiation Antigens*. Oxford: Oxford University Press; 1989. p 818–825.
279. Satterthwaite AB, Borson R, Tenen DG. Regulation of the gene for CD34, a human hematopoietic stem cell antigen, in KG-1 cells. *Blood* 1990;75:2299–2304.
280. Gajkowska A, Oldak T, Jastrzevska M, et al. Flow cytometric enumeration of CD34<sup>+</sup> hematopoietic stem and progenitor cells in leukapheresis product and bone marrow for clinical transplantation: A comparison of three methods. *Folia Histochem Cytobiol* 2006;44:53–60.
281. Borowitz MJ, Gockerman JP, Moore JO, et al. Clinicopathologic and cytogenetic features of CD34 (My 10)-positive acute non-lymphocytic leukemia. *Am J Clin Pathol* 1989;91:265–270.
282. Borowitz MJ, Shuster JJ, Civin CI, et al. Prognostic significance of CD34 expression in childhood B-precursor acute lymphocytic leukemia: A Pediatric Oncology Group study. *J Clin Oncol* 1990;8:1389–1398.

283. Majdic O. B-cell antigens: CD64. In: Knapp W, Dörken B, Rieber EP, et al., editors. *Leucocyte Typing IV White Cell Differentiation Antigens*. Oxford: Oxford University Press; 1989. p 835–836.
284. Krasinskas AM, Wasik MA, Kamoun M, Schretzenmair R, Moore J, Sallhany KE. The usefulness of CD64, other monocyte-associated antigens, and CD45 gating in the subclassification of acute myeloid leukemias with monocytic differentiation. *Am J Clin Pathol* 1998;110:797–805.
285. Stockinger H. B-cell antigens: CD68. In: Knapp W, Dörken B, Rieber EP, et al., editors. *Leucocyte Typing IV White Cell Differentiation Antigens*. Oxford: Oxford University Press; 1989. p 841–843.
286. Binder SW, Said JW, Shintaku IP, Pinkus GS. A histiocyte-specific marker in the diagnosis of malignant fibrous histiocytoma. Use of monoclonal antibody KP-1 (CD68). *Am J Clin Pathol* 1992;97:759–763.
287. Strobl H, Scheinecker C, Csmarits B, Majdic O, Knapp W. Flow cytometric analysis of intracellular CD68 molecule expression in normal and malignant haemopoiesis. *Br J Haematol* 1995;90:774–782.
288. Beranek JT. CD68 is not a macrophage-specific antigen. *Ann Rheum Dis* 2005;64:342–343; author reply 343–344.
289. Galli SJ, Zsebo KM, Geissler EN. The kit ligand, stem cell factor. *Adv Immunol* 1994;55:1–96.
290. Ashman LK. The biology of stem cell factor and its receptor C-kit. *Int J Biochem Cell Biol* 1999;31:1037–1051.
291. Dunphy CH, Polski JM, Evans HL, Gardner LJ. Evaluation of bone marrow specimens with acute myelogenous leukemia for CD34, CD15, CD117, and myeloperoxidase. *Arch Pathol Lab Med* 2001;125:1063–1069.
292. Newell JO, Cessna MH, Greenwood J, Hartung L, Bahler DW. Importance of CD117 in the evaluation of acute leukemias by flow cytometry. *Cytometry B Clin Cytom* 2003;52:40–43.
293. Naresh KN, Lampert IA. CD117 Expression as an aid to identify immature myeloid cells and foci of ALIP in bone marrow trephines. *Am J Hematol* 2006;81:79.
294. Fullard JF. The role of the platelet glycoprotein IIb/IIIa in thrombosis and haemostasis. *Curr Pharm Des* 2004;10:1567–1576.
295. von dem Borne AEG, Modderman PW. Cluster report: CD41. In: Knapp W, Dörken B, Rieber EP, et al., editors. *Leucocyte Typing IV White Cell Differentiation Antigens*. Oxford: Oxford University Press; 1989. p 997–999.
296. van Pampus EC, Denkers IA, van Geel BJ, et al. Expression of adhesion antigens of human bone marrow megakaryocytes, circulating megakaryocytes and blood platelets. *Eur J Haematol* 1992;49:122–127.
297. Debili N, Robin C, Schiavon V, et al. Different expression of CD41 on human lymphoid and myeloid progenitors from adults and neonates. *Blood* 2001;97:2023–2030.
298. Clemetson KJ, Clemetson JM. Molecular abnormalities in Glanzmann's thrombasthenia, Bernard-Soulier syndrome, and platelet-type von Willebrand's disease. *Curr Opin Hematol* 1994;1:388–393.
299. Gassmann W, Löffler H. Acute megakaryoblastic leukemia. *Leuk Lymphoma* 1995;18:69–73.
300. Von Dem Borne AEG, Modderman PW. Cluster report: CD42. In: Knapp W, Dörken B, Rieber EP, et al., editors. *Leucocyte Typing IV White Cell Differentiation Antigens*. Oxford: Oxford University Press; 1989. p 1000–1002.
301. Nieuwenhuis HK. Report on functional studies. In: Knapp W, Dörken B, Rieber EP, et al., editors. *Leucocyte Typing IV White Cell Differentiation Antigens*. Oxford: Oxford University Press; 1989. p 1002–1003.
302. Modderman PW. Cluster report: CD61. In: Knapp W, Dörken B, Rieber EP, et al., editors. *Leucocyte Typing IV White Cell Differentiation Antigens*. Oxford: Oxford University Press; 1989. p 1025.
303. Law HK, Bol SJ, Palatsides M, Williams NT. Analysis of human megakaryocytic cells using dual-color immunofluorescence labeling. *Cytometry* 2000;41:308–315.
304. Kafer G, Willer A, Ludwig W, Kramer A, Hehlmann R, Hastka J. Intracellular expression of CD61 precedes surface expression. *Ann Hematol* 1999;78:472–474.
305. Anstee DJ, Lisowska E. Monoclonal antibodies against glycoporphins and other glycoproteins. *J Immunogenet* 1990;17:301–308.
306. Cartron JP, Rahuel C. Human erythrocyte glycoporphins: Protein and gene structure analyses. *Transfus Med Rev* 1992;6:63–92.
307. Chasis JA, Mohandas N. Red blood cell glycoporphins. *Blood* 1992;80:1869–1879.
308. Van Der Schoot CE, Baardman R, Lighthart P, et al. CD235a and CD235b—Glycophorin A and Glycophorin B. In: Mason D, Andre P, Bensussan A, et al., editors. *Leucocyte Typing VII White Cell Differentiation Antigens*. Proceedings of the Seventh International Workshop and Conference held in Harrogate, United Kingdom. New York, NY: Oxford University Press; 2002. p 577–579.
309. Loken MR, Civin CI, Bigbee WL, Langlois RG, Jensen RH. Coordinate glycosylation and cell surface expression of glycophorin A during normal human erythropoiesis. *Blood* 1987;70:1959–1961.
310. Loken MR, Shah VO, Dattilio KL, Civin CI. Flow cytometric analysis of human bone marrow: I. Normal erythroid development. *Blood* 1987;69:255–263.
311. Sadahira Y, Kanzaki A, Wada H, Yawata Y. Immunohistochemical identification of erythroid precursors in paraffin embedded bone marrow sections: Spectrin is a superior marker to glycophorin. *J Clin Pathol* 1999;52:919–921.
312. Chakrabarti A, Kelkar DA, Chattopadhyay A. Spectrin organization and dynamics: New insights. *Biosci Rep* 2006;26:369–386.
313. Mohandas N, An X. New insights into function of red cell membrane proteins and their interaction with spectrin-based membrane skeleton. *Transfus Clin Biol* 2006;13:29–30.
314. Gallagher PG. Hereditary elliptocytosis: Spectrin and protein 4.1R. *Semin Hematol* 2004;41:142–164.
315. Scholzen T, Gerdes J. The Ki-67 protein: From the known and the unknown. *J Cell Physiol* 2000;182:311–322.
316. Bryant RJ, Banks PM, O'Malley DP. Ki67 staining pattern as a diagnostic tool in the evaluation of lymphoproliferative disorders. *Histopathology* 2006;48:505–515.
317. Maga G, Hubscher U. Proliferating cell nuclear antigen (PCNA): A dancer with many partners. *J Cell Sci* 2003;116:3051–3060.
318. Deptala A, Mayer SP. Detection of minimal residual disease. *Methods Cell Biol* 2001;64:385–420.
319. Paietta E. Assessing minimal residual disease (MRD) in leukemia: A changing definition and concept? *Bone Marrow Transplant* 2002;29:459–465.
320. Schuler F, Dolken G. Detection and monitoring of minimal residual disease by quantitative real-time PCR. *Clin Chim Acta* 2006;363:147–156.
321. Spurbeck JL, Adams SA, Stupca PJ, Dewald GW. Primer on medical genomics. Part XI: Visualizing human chromosomes. *Mayo Clin Proc* 2004;79:58–75.
322. Smeets DF. Historical prospective of human cytogenetics: From microscope to microarray. *Clin Biochem* 2004;37:439–446.



323. Swansbury J. Introduction to the analysis of the human G-banded karyotype. *Methods Mol Biol* 2003;220:259–269.
324. Sumner AT. The nature and mechanisms of chromosome banding. *Cancer Genet Cytogenet* 1982;6:59–87.
325. Schrock E, du Manoir S, Veldman T, et al. Multicolor spectral karyotyping of human chromosomes. *Science* 1996;273:494–497.
326. Bayani J, Squire JA. Spectral karyotyping. *Methods Mol Biol* 2002;204:85–104.
327. Van Stedum S, King W. Basic FISH techniques and troubleshooting. *Methods Mol Biol* 2002;204:51–63.
328. Min T, Swansbury J. Cytogenetic studies using FISH: Background. *Methods Mol Biol* 2003;220:173–191.
329. Levsky JM, Singer RH. Fluorescence in situ hybridization: Past, present and future. *J Cell Sci* 2003;116:2833–2838.
330. Liehr T, Starke H, Weise A, Lehrer H, Claussen U. Multicolor FISH probe sets and their applications. *Histol Histopathol* 2004;19:229–237.
331. Jain KK. Current status of fluorescent in-situ hybridisation. *Med Device Technol* 2004;15:14–17.
332. Liebisch P, Viardot A, Bassermann N, et al. Value of comparative genomic hybridization and fluorescence in situ hybridization for molecular diagnostics in multiple myeloma. *Br J Haematol* 2003;122:193–201.
333. Cady FM, Muto DN, Ciabetteri G, Johns A, Gainey Church K, Wolff DJ. Utility of interphase FISH panels for routine clinical cytogenetic evaluation of chronic lymphocytic leukemia and multiple myeloma. *J Assoc Genet Technol* 2004;30:77–81.
334. Nilsson T, Lenhoff S, Rylander L, et al. High frequencies of chromosomal aberrations in multiple myeloma and monoclonal gammopathy of undetermined significance in direct chromosome preparation. *Br J Haematol* 2004;126:487–494.
335. Bergsagel PL. Prognostic factors in multiple myeloma: It's in the genes. *Clin Cancer Res* 2003;9:533–534.
336. Dewald GW. Cytogenetic and FISH studies in myelodysplasia, acute myeloid leukemia, chronic lymphocytic leukemia and lymphoma. *Int J Hematol* 2002;76:65–74.
337. Najfeld V. Diagnostic application of FISH to hematological malignancies. *Cancer Invest* 2003;21:807–814.
338. Spagnolo DV, Ellis DW, Juneja S, et al. The role of molecular studies in lymphoma diagnosis: A review. *Pathology* 2004;36:19–44.
339. Steensma DP, List AF. Genetic testing in the myelodysplastic syndromes: Molecular insights into hematologic diversity. *Mayo Clin Proc* 2005;80:681–698.
340. Bagg A, Kallakury BV. Molecular pathology of leukemia and lymphoma. *Am J Clin Pathol* 1999;112:S76–S92.
341. Ding C, Cantor CR. Quantitative analysis of nucleic acids—The last few years of progress. *J Biochem Mol Biol* 2004;37:1–10.
342. Erlich HA. Principles and applications of the polymerase chain reaction. *Rev Immunogenet* 1999;1:127–134.
343. Jaffe ES, Harris NL, Stein H, editors. *Pathology and Genetics of Tumours of Haematopoietic and Lymphoid tissues (World Health Organization Classification of Tumours: 3)*. Lyon, France: International Agency for Research on Cancer; 2001.
344. Anastasi J. Genetic and molecular genetic studies in the diagnosis of myeloid diseases. *Hum Pathol* 2003;34:306–313.
345. Fenk R, Haas R, Kronenwett R. Molecular monitoring of minimal residual disease in patients with multiple myeloma. *Hematology* 2004;9:17–33.
346. Paschka P, Merx K, Hochhaus A. Molecular surveillance of chronic myeloid leukemia patients in the imatinib era—Evaluation of response and resistance. *Acta Haematol* 2004;112:85–92.
347. Frater JL, Tallman MS, Variakojis D, et al. Chronic myeloid leukemia following therapy with imatinib mesylate (Gleevec). Bone marrow histopathology and correlation with genetic status. *Am J Clin Pathol* 2003;119:833–841.
348. Kim YJ, Kim DW, Lee S, et al. Comprehensive comparison of FISH, RT-PCR, and RQ-PCR for monitoring the BCR-ABL gene after hematopoietic stem cell transplantation in CML. *Eur J Haematol* 2002;68:272–280.
349. Schoch C, Schnittger S, Bursch S, et al. Comparison of chromosome banding analysis, interphase- and hypermetaphase-FISH, qualitative and quantitative PCR for diagnosis and for follow-up in chronic myeloid leukemia: A study on 350 cases. *Leukemia* 2002;16:53–59.
350. Marshall GM, Haber M, Kwan E, et al. Importance of minimal residual disease testing during the second year of therapy for children with acute lymphoblastic leukemia. *J Clin Oncol* 2003;21:704–709.
351. Cross NC. Quantitative PCR techniques and applications. *Br J Haematol* 1995;89:693–697.
352. Schiffer CA, Hehlmann R, Larson R. Perspectives on the treatment of chronic phase and advanced phase CML and Philadelphia chromosome positive ALL(1). *Leukemia* 2003;17:691–699.
353. Bagg A. Commentary: Minimal residual disease: How low do we go? *Mol Diagn* 2001;6:155–160.
354. Markoulatos P, Siafakas N, Moncany M. Multiplex polymerase chain reaction: A practical approach. *J Clin Lab Anal* 2002;16:47–51.
355. van der Velden VH, Jacobs DC, Wijkhuijs AJ, et al. Minimal residual disease levels in bone marrow and peripheral blood are comparable in children with T cell acute lymphoblastic leukemia (ALL), but not in precursor-B-ALL. *Leukemia* 2002;16:1432–1436.
356. Wu CJ, Neuberg D, Chillemi A, et al. Quantitative monitoring of BCR/ABL transcript during STI-571 therapy. *Leuk Lymphoma* 2002;43:2281–2289.
357. Bertheas MF, Lafage M, Levy P, et al. Influence of mixed chimerism on the results of allogeneic bone marrow transplantation for leukemia. *Blood* 1991;78:3103–3106.
358. McCann SR, Lawler M. Mixed chimaerism; Detection and significance following BMT. *Bone Marrow Transplant* 1993;11:91–94.
359. Price CM, Colman SM, Kanfer EJ. Persistence of multilineage host haemopoiesis following allogeneic bone marrow transplantation. *Br J Haematol* 1995;90:465–468.
360. Huss R, Deeg HJ, Gooley T, et al. Effect of mixed chimerism on graft-versus-host disease, disease recurrence and survival after HLA-identical marrow transplantation for aplastic anemia or chronic myelogenous leukemia. *Bone Marrow Transplant* 1996;18:767–776.