

ORIGINAL ARTICLE

Bone Marrow Transplantation for Recessive Dystrophic Epidermolysis Bullosa

John E. Wagner, M.D., Akemi Ishida-Yamamoto, M.D., Ph.D.,
John A. McGrath, M.D., Maria Hordinsky, M.D., Douglas R. Keene, B.S.,
Megan J. Riddle, B.A., Mark J. Osborn, Ph.D., Troy Lund, M.D., Ph.D.,
Michelle Dolan, M.D., Bruce R. Blazar, M.D., and Jakub Tolar, M.D., Ph.D.

ABSTRACT

BACKGROUND

Recessive dystrophic epidermolysis bullosa is an incurable, often fatal mucocutaneous blistering disease caused by mutations in *COL7A1*, the gene encoding type VII collagen (C7). On the basis of preclinical data showing biochemical correction and prolonged survival in *col7^{-/-}* mice, we hypothesized that allogeneic marrow contains stem cells capable of ameliorating the manifestations of recessive dystrophic epidermolysis bullosa in humans.

METHODS

Between October 2007 and August 2009, we treated seven children who had recessive dystrophic epidermolysis bullosa with immunomyeloablative chemotherapy and allogeneic stem-cell transplantation. We assessed C7 expression by means of immunofluorescence staining and used transmission electron microscopy to visualize anchoring fibrils. We measured chimerism by means of competitive polymerase-chain-reaction assay, and documented blister formation and wound healing with the use of digital photography.

RESULTS

One patient died of cardiomyopathy before transplantation. Of the remaining six patients, one had severe regimen-related cutaneous toxicity, with all having improved wound healing and a reduction in blister formation between 30 and 130 days after transplantation. We observed increased C7 deposition at the dermal-epidermal junction in five of the six recipients, albeit without normalization of anchoring fibrils. Five recipients were alive 130 to 799 days after transplantation; one died at 183 days as a consequence of graft rejection and infection. The six recipients had substantial proportions of donor cells in the skin, and none had detectable anti-C7 antibodies.

CONCLUSIONS

Increased C7 deposition and a sustained presence of donor cells were found in the skin of children with recessive dystrophic epidermolysis bullosa after allogeneic bone marrow transplantation. Further studies are needed to assess the long-term risks and benefits of such therapy in patients with this disorder. (Funded by the National Institutes of Health; ClinicalTrials.gov number, NCT00478244.)

From the Blood and Marrow Transplant Program, Department of Pediatrics (J.E.W., M.J.R., M.J.O., T.L., B.R.B., J.T.), Center for Translational Medicine (J.E.W., B.R.B., J.T.), and the Departments of Dermatology (M.H.) and Laboratory Medicine and Pathology (M.D.), University of Minnesota, Minneapolis; the Department of Dermatology, Asahikawa Medical College, Asahikawa, Japan (A.I.-Y.); St. John's Institute of Dermatology, King's College London (Guy's Campus), London (J.A.M.); and Microimaging Center, Shriners Hospital for Children, Portland, OR (D.R.K.). Address reprint requests to Dr. Wagner at the Division of Pediatric Hematology/Oncology and Blood and Marrow Transplantation, University of Minnesota, Mayo Mail Code 366, 420 Delaware St. SE, Minneapolis, MN 55455, or at wagne002@umn.edu.

Drs. Blazar and Tolar contributed equally to this article.

N Engl J Med 2010;363:629-39.
Copyright © 2010 Massachusetts Medical Society.

LOSS OF SKIN INTEGRITY THAT LEADS TO trauma-induced blisters and erosions is a defining feature of epidermolysis bullosa, a heterogeneous group of more than 20 inherited blistering diseases with highly variable clinical severity.¹ One of the most severe forms is recessive dystrophic epidermolysis bullosa, caused by loss-of-function mutations in the collagen type VII (C7) gene (*COL7A1*).²⁻⁶ These mutations result in severely diminished expression of C7, a collagen localized at the dermal-epidermal junction. C7 is the major component of the anchoring fibrils that tether the epidermal basement membrane to the dermal matrix. In the absence of normal C7 expression, these fibrils do not form properly, and epidermal-dermal adherence is lost beneath the lamina densa of the basement membrane.

From birth on, children with recessive dystrophic epidermolysis bullosa have painful erosions and blisters on mucosal membranes and skin, often resulting in esophageal strictures, mutilating scars, local and systemic infections, joint contractures, fusion of fingers and toes, and aggressive squamous-cell carcinomas.⁷⁻⁹ For patients with the Hallopeau-Siemens variant of recessive dystrophic epidermolysis bullosa, severe mucocutaneous disease is apparent at birth and the median survival is approximately 30 years, whereas persons with other types of recessive dystrophic epidermolysis bullosa have a median survival of 55 to 65 years.¹⁰

To date, the care of patients with recessive dystrophic epidermolysis bullosa has been palliative and restricted to the treatment of individual wounds.^{11,12} To assess the potential effectiveness of bone marrow stem-cell transplantation for the systemic correction of recessive dystrophic epidermolysis bullosa, we evaluated this approach in a mouse model¹³ and observed that a stem-cell-enriched fraction of bone marrow prevented postnatal death in a proportion of mice with recessive dystrophic epidermolysis bullosa. Fifteen percent of the treated mice survived for longer than 80 days after transplantation; these mice had expression of wild-type C7 in skin and mucosa, formation of new anchoring fibrils, and resistance to blistering.¹⁴ We then conducted a phase 1-phase 2 clinical trial of bone marrow transplantation for the treatment of severe recessive dystrophic epidermolysis bullosa.

METHODS

PATIENTS AND TREATMENT

Between October 2007 and August 2009, we enrolled seven children with recessive dystrophic epidermolysis bullosa in a trial of immunomyeloablative chemotherapy and transplantation of allogeneic stem cells. Follow-up data are reported through January 8, 2010.

To optimize engraftment, we used a modified conditioning regimen for immunomyeloablation that consisted of busulfan (0.8 mg per kilogram of body weight per dose for children who weighed 12 kg or more and 1.1 mg per kilogram for those who weighed less than 12 kg, delivered intravenously every 6 hours on days 9 to 6 before transplantation, with dose modifications based on pharmacokinetics, targeting 1000 μmol per minute for the area under the curve), fludarabine (25 mg per square meter of body-surface area per day, given intravenously on days 5 to 3 before transplantation), and cyclophosphamide (50 mg per kilogram per day, given intravenously on days 5 to 2 before transplantation). (The treatment schema is shown in Fig. 1 in the Supplementary Appendix, available with the full text of this article at NEJM.org.) Immunoprophylaxis against graft-versus-host disease consisted of cyclosporine (targeting trough levels of 200 to 400 μg per liter on day 3 before transplantation to day 100 after transplantation, with the dose tapered by 10% each week thereafter) and mycophenolate mofetil (15 mg per kilogram on day 3 before transplantation to day 45 after transplantation).

On the day of transplantation, five patients received unfiltered marrow stem cells from an HLA-identical sibling; one of the five (Patient 1) concomitantly received umbilical-cord blood from the same sibling donor. Patient 3 received umbilical-cord blood from an unrelated donor (HLA-5/6, with B antigen mismatched). Owing to severe chemotherapy-related toxicity, one patient (Patient 2) did not receive the scheduled marrow infusion. Except for intensive skin care and placement of a gastrostomy tube to minimize vomiting, supportive care was standard for the recipients of an allogeneic bone marrow transplant.¹⁵ The study protocol was approved by the University of Minnesota institutional review board. Parents of all the study participants provided writ-

ten informed consent, and Patient 7 provided assent.

LABORATORY ASSESSMENTS

To quantify and determine the location of C7, skin-biopsy specimens were obtained at perilesional sites on the extremities, approximately 1 mm away from an erosion, and were stained with anti-C7 antibodies. Six areas were selected at random locations along the dermal–epidermal junction to quantify the C7 fluorescent-signal intensity (see the Methods section in the Supplementary Appendix).

Skin samples were also fixed and processed for transmission electron microscopy, as described previously.¹⁴ Qualitative and quantitative assessments, made at specific time points after treatment, focused on the development of anchoring fibrils beneath the lamina densa. Previously defined criteria for ultrastructural evaluation were applied^{16–18}; specifically, the insertion of a fibrillar structure into the dermal surface of the lamina densa and central cross-banding, a fan-shaped appearance, or both were considered morphologic hallmarks of anchoring fibrils. Electron-microscopical images were reviewed independently by three dermatopathologists without knowledge of clinical outcome data.

We carried out fluorescence in situ hybridization (FISH) with the use of established methods (see the Supplementary Appendix) and determined the extent of blood and skin chimerism by means of competitive polymerase-chain-reaction analysis of polymorphic variable-number tandem-repeat regions.¹⁵ We used a quantitative enzyme-linked immunosorbent assay to test for anti-C7 antibodies in blood samples.¹⁹ Images were scanned with the Epson Perfection V700 Photo Scanner, and densitometry was performed with the use of ImageJ software.

RESULTS

PATIENT AND GRAFT CHARACTERISTICS

Six children with recessive dystrophic epidermolysis bullosa between the ages of 15 months and 14.5 years completed treatment and could be evaluated. Characteristics of the patients and grafts and the outcomes of transplantation are summarized in Table 1. Pretransplantation evaluations showed extensive cutaneous disease in each of the six patients and severe mucosal disease in four of the six, who required esophageal dilation and gastrostomy-tube placement for nutritional support.

Five patients had severe mitten deformities, and four used wheelchairs. In addition, two had clinically significant renal impairment (glomerular filtration rate, 26.01 and 79.49 ml per minute per 1.73 m² of body-surface area in Patient 2 and Patient 4, respectively) and four had severe iron-deficiency anemia.

TRANSPLANTATION-RELATED EVENTS

Despite a 50% reduction in the dose of fludarabine because of a reduced glomerular filtration rate, Patient 2 died before the bone marrow infusion could be carried out as a result of hemorrhagic cardiomyopathy that was probably due to cyclophosphamide cardiotoxicity. Among the six patients who underwent transplantation, neutrophil recovery ($\geq 5 \times 10^8$ cells per liter) occurred on days 11, 24, 16, 12, 14, and 18, in Patients 1, 3, 4, 5, 6, and 7, respectively, and platelet recovery ($\geq 5 \times 10^{10}$ platelets per liter) occurred on days 43, 33, 46, 37, and 41 in Patients 1, 4, 5, 6, and 7, respectively, but was not achieved in Patient 3. Regimen-related toxicity included grade 3 mucositis (in six patients); transient, clinically significant hyperbilirubinemia (in four patients), with a peak total bilirubin level of 6.9 to 19 mg per deciliter (118 to 325 μmol per liter); renal insufficiency requiring 3 days of hemodialysis for fluid management (in two patients), with peak creatinine levels of 1.66 mg per deciliter (146.7 μmol per liter) in Patient 4 and 1.58 mg per deciliter (139.7 μmol per liter) in Patient 5; and opportunistic infections (candidemia in Patients 4 and 7 and viral reactivations in Patient 3 [adenovirus, Epstein–Barr virus, BK virus, and human herpesvirus type 6] and Patient 4 [BK virus]). No patient had acute or chronic graft-versus-host disease. Five patients were alive 799, 387, 268, 196, and 130 days after bone marrow transplantation, with Patients 1, 4, 5, and 6 having been taken off all immunosuppressive therapy and Patient 7 tolerating the tapering of the cyclosporine dose. Patient 3, who required a second transplant because of graft rejection, had hematopoietic recovery (on day 22 after the second infusion of umbilical-cord blood) with complete marrow chimerism; however, subsequent infections resulted in his death on day 183.

ASSESSMENT OF MUCOCUTANEOUS BLISTERING AND WOUND HEALING

Mucocutaneous blistering was not adversely affected early after transplantation except in Patient 7, in whom grade 4 cutaneous toxicity developed on

Table 1. Characteristics of Patients and Grafts and Outcomes of Transplantation.*

Variable	Patient 1	Patient 3†	Patient 4	Patient 5	Patient 6	Patient 7
Sex and age	M, 15 mo	M, 5.9 yr	M, 6.3 yr	F, 6.2 yr	F, 6.9 yr	F, 14.5 yr
Clinical features	Mitten deformity, esophageal stricture, FTT	Mitten deformity, gastrotomy, pulmonary-artery stenosis, flexion contractures, FTT	Esophageal stricture, perirectal fissures	Mitten deformity, flexion contractures, esophageal stricture, FTT, anemia	Mitten deformity, flexion contractures, esophageal stricture, FTT, perirectal fissures, anemia	Mitten deformity, flexion contractures, esophageal stricture, FTT, anemia, active pseudomonas cellulitis
C7 mutations	c.3472delC (p.Pro1158fsX3); IVS51+1G→A	c.3472delC (p.Pro1158fsX3); IVS51+1G→A	IVS85-2delAG; IVS92+5G→A	c.6176A→G (p.Glu2059Gly); IVS5+1G→A	c.4919delG (p.Gly1640fsX70); c.8254-8255delAG (p.Arg2751fsX20)	c.6781C→T (p.Arg2261X); IVS110-1G→C
Donor	Brother	Unrelated male donor for each of two transplants	Sister	Brother	Sister	Sister
HLA match‡	8/8	First transplant: 5/6 (B mismatch) Second transplant: 5/6 (DRB1 mismatch)	8/8	8/8	8/8	8/8
Cell dose (neutrophil count × 10 ⁸ /kg of body weight)	3.04	—	3.76	3.07	5.04	3.00
Bone marrow	0.66	First transplant: 0.55 Second transplant: 0.56	—	—	—	—
Umbilical-cord blood	0.66	After first transplantation: hyperbilirubinemia (peak bilirubin, 10 mg/dl, day 12) with no hepatomegaly or ascites	Renal insufficiency (peak creatinine, 1.7 mg/dl, day 5) requiring hemodialysis for fluid management (3 days); candida sepsis; need for mechanical ventilation (5 days)	Renal insufficiency (peak creatinine, 1.6 mg/dl, day 27) requiring hemodialysis for fluid management (3 days); hyperbilirubinemia (peak value, 9.6 mg/dl, day 12) with no hepatomegaly or ascites	Hyperbilirubinemia (peak bilirubin, 2.6 mg/dl, day 10) with no hepatomegaly or ascites	Renal insufficiency (peak creatinine, 1.7 mg/dl, day 11) not requiring hemodialysis; candida sepsis; hyperbilirubinemia (peak bilirubin, 19 mg/dl, day 11) with no hepatomegaly or ascites; grade 4 skin toxicity (day 17)
Severe adverse events related to transplantation	Improved rate of wound healing; subjective reduction in dressings§	Improved rate of wound healing; subjective reduction in dressings§	Improved rate of wound healing; 50 to 70% reduction in dressings§	Improved rate of wound healing; 25 to 50% reduction in dressings; no recurrence of anemia	Improved rate of wound healing; increased resistance to blistering on exposure to negative pressure	Improved rate of wound healing; marked reduction in blisters at day 30, but recurrent blistering between days 60 and 100; increased resistance to blistering on exposure to negative pressure
Clinical outcome	Improved rate of wound healing; subjective reduction in dressings§	Improved rate of wound healing; subjective reduction in dressings§	Improved rate of wound healing; 50 to 70% reduction in dressings§	Improved rate of wound healing; 25 to 50% reduction in dressings; no recurrence of anemia	Improved rate of wound healing; increased resistance to blistering on exposure to negative pressure	Improved rate of wound healing; marked reduction in blisters at day 30, but recurrent blistering between days 60 and 100; increased resistance to blistering on exposure to negative pressure

Ultrastructural findings on electron microscopy	On day 365: scanty, thin fibrillar structures with insertion into lamina densa; no AFs	On day 145: scanty, thin fibrillar structures with insertion into lamina densa; no AFs	On day 198: thickened lamina densa; a few thickened AF-like structures present	On day 180: thickened lamina densa; increased thickness of fibrillar structures with insertion into lamina densa; no AFs	On day 102: scanty, thin fibrillar structures with insertion into lamina densa; no AFs	On day 100: increased thickness of fibrillar structures with insertion into lamina densa; no AFs
Tissue chimerism	On skin biopsy day 365	On skin biopsy day 145, and 0 to 11.2% in samples from multiple skin biopsies and 46.8% in a sample from a biopsy of esophageal mucosa on day 183	On skin biopsy day 29, 0% on day 60, 12.4% on day 103, and 10.0% on day 198	On skin biopsy day 25, 93.0% on day 100, and 25.0% on day 180	On skin biopsy day 28, 20.0% on day 60, and 33.0% on day 102	On skin biopsy day 30, 18.0% on day 60, and 18.0% on day 100
Survival status	Alive on day 799	Died on day 183	Alive on day 387	Alive on day 268	Alive on day 196	Alive on day 130

* AF denotes anchoring fibril, ARDS acute respiratory distress syndrome, and FTT failure to thrive. To convert the values for bilirubin to micromoles per liter, multiply by 17.1. To convert the values for creatinine to micromoles per liter, multiply by 88.4

† Because of graft rejection, Patient 3 received a second transplant 47 days after receipt of the first transplant. Before transplantation of a second HLA 5/6 unit of umbilical-cord blood, conditioning consisted of rituximab (375 mg per square meter of body-surface area given intravenously as a single dose on day 5 before the procedure) and antithymocyte globulin (15 mg per kilogram of body weight per day given intravenously on days 4, 3, and 2, before transplantation, for a total dose of 45 mg per kilogram).

‡ HLA typing of patients and donors was performed at the allele level for HLA-A, HLA-B, HLA-C, and HLA-DRB1 in the bone marrow recipients; in unrelated recipients of umbilical-cord blood, HLA typing was performed at the antigen level for HLA-A and HLA-B and at the allele level for HLA-DRB1.

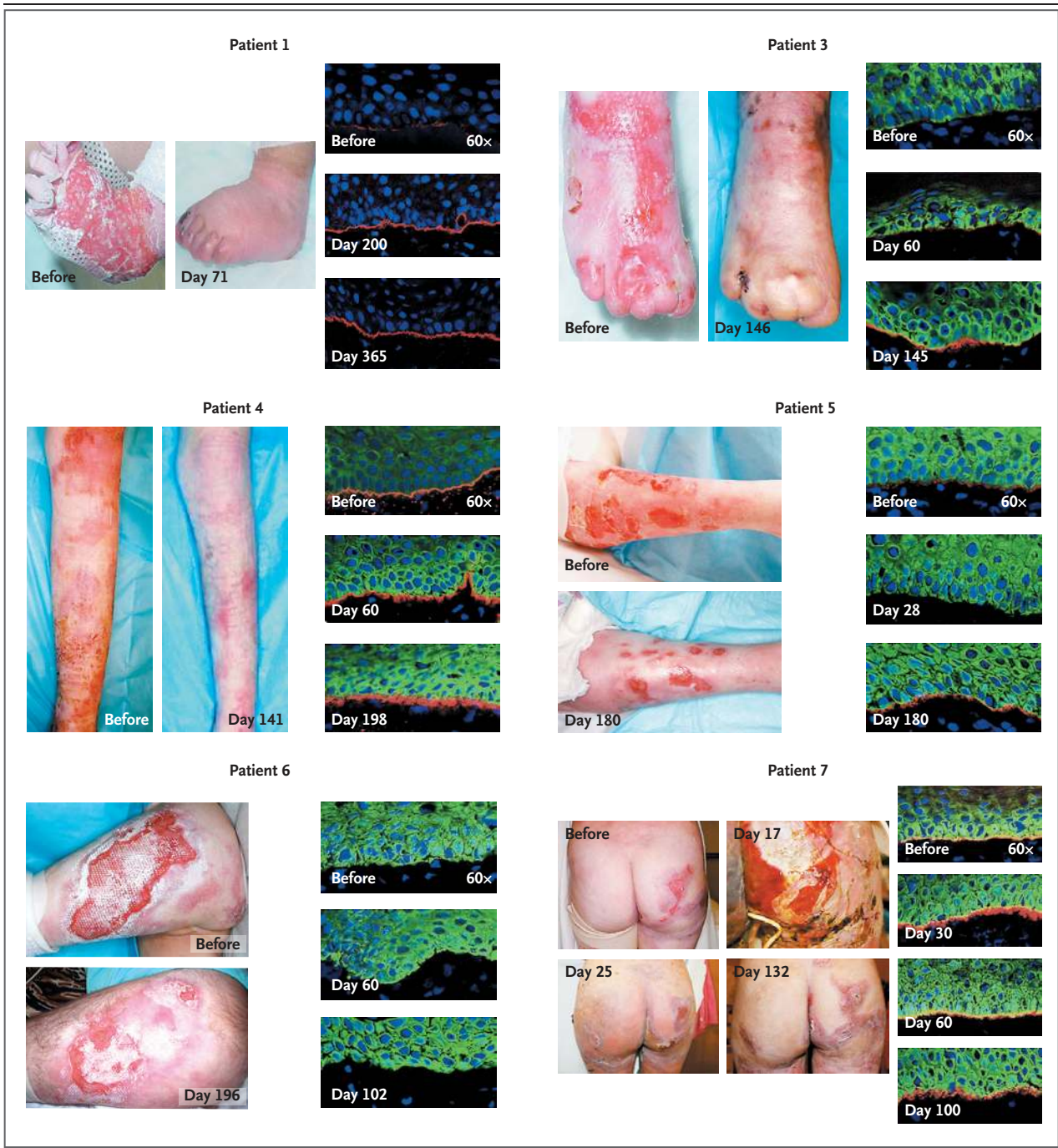
§ Before and after transplantation, parents reported the weight of precut dressings before application. The percent reduction in dressings after transplantation is relative to the pretransplantation weight.

day 17, presumably related to the chemotherapy regimen. All the patients had increased wound healing and decreased mucocutaneous blistering within the first 100 days after transplantation (Fig. 1). Patients 4, 5, and 7 had marked clinical improvement as early as day 30. The percentage of body-surface area affected was reduced in Patients 1, 3, and 6 according to parents' reports and clinical observation, with more objective evidence provided by documented reductions in bandage use (assessed on the basis of the weight of precut dressings) in Patient 5 at 6 months and in Patient 4 at 1 year, as compared with bandage use before transplantation (Table 1). The parents of each patient reported substantial improvements in the rate of wound healing and marked reductions in oral mucosal lesions. We tested the skin of the two most recently enrolled patients (Patients 6 and 7) for resistance to blister formation on exposure to negative pressure. In both patients, the time to blister formation gradually increased after transplantation and exceeded that observed before transplantation (Fig. 2 in the Supplementary Appendix).

BIOCHEMICAL AND ULTRASTRUCTURAL ASSESSMENTS OF SKIN

Skin-biopsy specimens were evaluated for the presence of C7 (Fig. 1). In Patient 1, skin immunofluorescence microscopy at baseline revealed faint linear and interrupted C7 immunolabeling at the dermal-epidermal junction; in contrast, by day 200 there was bright linear C7 immunoreactivity at the dermal-epidermal junction, which was even more intense by day 365 after transplantation. Skin-biopsy specimens from Patients 3, 4, 5, and 7 also revealed increases in C7 immunoreactivity at the dermal-epidermal junction after transplantation. In addition, we found that cultured fibroblasts from skin-biopsy specimens obtained after transplantation produced C7, as detected on Western blotting (data not shown).

Skin-biopsy specimens from all the patients except Patient 1 were evaluated with the use of six anti-C7 antibodies, which could potentially recognize different epitopes on wild-type C7. Testing with at least one anti-C7 antibody revealed a progressive increase in C7 expression as measured by increased fluorescence intensity over time in five of the six patients (Fig. 2); in Patient 6, C7 could not be detected at any point in time. C7 was either absent or barely detectable with at least one anti-C7 antibody before treatment in Patients 3 and 4; however, expression of C7 became readily apparent



after transplantation and increased substantially over time.

Electron micrographs obtained at baseline revealed a complete absence of mature anchoring fibrils in all the patients. After transplantation, electron micrographs in all but one patient revealed only scanty, wispy structures under the lamina densa, as shown in Patient 7 (Fig. 3). Although this fibrillar material could represent very

rudimentary anchoring fibrils or fragmented elastic microfibrils, more precise interpretation or reproducible quantification was not possible. In Patient 4, we observed occasional fibrillar structures below the lamina densa that were consistent with rudimentary anchoring fibrils (Fig. 3), but these structures were thin and generally lacked central cross-banding. After transplantation, all patients had an increase in the number

Figure 1 (facing page). Clinical Photographs and Skin-Biopsy Specimens before and after Transplantation in Six Patients with Recessive Dystrophic Epidermolysis Bullosa.

Photographs and skin-biopsy specimens were taken immediately before treatment and at scheduled time points after transplantation. The clinical photographs show specific areas that were consistently blistered before treatment. More rapid wound healing and reepithelialization were noted after transplantation in all six patients, with variable reductions in skin blistering. In Patient 7, marked cutaneous toxicity developed (presumably as a result of the chemotherapy) and was most pronounced on day 17 after transplantation but showed marked improvement by day 25. Immunofluorescence staining for C7 was carried out with skin-biopsy specimens obtained from all six patients, with the use of anti-C7 antibodies provided by Drs. D.T. Woodley and M. Chen (Keck School of Medicine, University of Southern California) for Patient 1 and purchased from BD Biosciences for the other five patients. For Patient 1, immunofluorescence staining before transplantation revealed faint, stippled labeling of C7; continuous, bright, linear C7 labeling was observed at all time points after bone marrow infusion. For Patient 3, faint, stippled C7 labeling was also observed at the dermal-epidermal junction before transplantation and through day 60 after transplantation, with continuous, bright, linear C7 labeling noted on day 145. For Patient 4, a bright, continuous band was observed at the dermal-epidermal junction before transplantation, with the use of anti-C7 antibody from BD Biosciences, whereas a thicker, brighter band was noted on day 198 after transplantation; this observation was confirmed with the use of LH7.2 anti-C7 antibody from Sigma-Aldrich, with no labeling before transplantation but bright labeling on day 198. For Patient 5, faint, stippled C7 labeling was observed at the dermal-epidermal junction with loss of demonstrable C7 labeling early after transplantation (day 28); however, continuous, bright linear, C7 labeling was observed on day 180. For Patient 6, no immunofluorescence staining was detectable before transplantation or at any time after transplantation, through day 102. For Patient 7, immunofluorescence staining before transplantation revealed stippled C7 labeling and continuous, bright, linear C7 labeling at the dermal-epidermal junction as early as day 30 after transplantation. For Patients 3 through 7, keratinocytes (green) were visualized with the use of anti-cytokeratin 5 antibody.

of such structures, but none had the morphologic hallmarks of normal anchoring fibrils. Other ultrastructural changes included thickening of the lamina densa in Patients 4 and 5 (Table 1 and Fig. 3).

ANTI-C7 ANTIBODY EVALUATION

Because anti-C7 antibodies could interfere with the benefit of transplantation, we assayed levels

of anti-C7 antibodies in serum. Before transplantation, we detected low antibody titers in Patients 1, 3, and 7; no anti-C7 antibodies have been detected since transplantation.

CHIMERISM ASSESSMENTS

After transplantation, all patients (including Patient 3, who required a second umbilical-cord blood transplant) had complete replacement of the marrow and blood by donor lymphohematopoietic cells. Moreover, all patients had evidence of donor cells in the skin, with a median of 20% (range, 0 to 93) being of donor origin. The percentage of donor cells varied between time points and with the biopsy site (Table 1). Patient 5 had a sex-mismatched donor. With the use of FISH to identify X and Y chromosomes (male donor), anti-CD45 and anti-CD31 fluorochromes were used to determine the identity of the donor cells in the skin-biopsy specimens. We observed extravascular localization of CD45+ (hematopoietic) donor cells and CD45-CD31- (nonhematopoietic, non-endothelial) donor cells in the papillary dermis and epidermis in this patient (Fig. 3 in the Supplementary Appendix).

DISCUSSION

We found that the infusion of allogeneic bone marrow can partially correct the C7 deficiency and improve skin and mucosal integrity in patients with recessive dystrophic epidermolysis bullosa. The observation that partial C7 correction is associated with a clinical benefit is consistent with previous work showing that a C7 level as low as 10% of the wild-type level of expression is associated with stability of the skin.²⁰ The rates of recovery and ultimate outcomes varied among the surviving patients. Patients 4 and 5 had rapid and substantial clinical improvement relative to baseline, whereas Patient 1 had slow improvement, with only a modest overall benefit, and Patient 7 had a recurrence of blistering after an early period (days 30 to 60) of almost no blistering.

Unexpectedly, we detected substantial proportions of donor cells in the skin and mucosa after treatment; these proportions varied over time and with the location of the biopsy site. Many of the donor cells were located some distance away from blood vessels, and many were hematopoietic in origin (CD45+ cells). Although more work needs to be done to determine the identity of the CD45-CD31- donor cells, we favor the possibil-

ity that these healthy donor cells residing in the skin secrete C7 and that the secreted C7 is subsequently incorporated into the lamina densa at the dermal-epidermal junction.

The effect of new C7 on the morphologic features of anchoring fibrils, however, is not clear. Because all the patients except Patient 6 had mutant C7 expression at baseline (with Patients 4, 5, and 7 having higher levels of expression than Patients 1 and 3), it is possible that small amounts of newly formed C7 assembled with wild-type C7 early after transplantation to form a trimer and thus improved mucocutaneous integrity. This hypothesis also predicts that the C7 gene dose (i.e., the zygosity status of the donor) could influence the rate of improvement and is consistent with the blunted overall clinical outcome in Patient 1, who had a heterozygous donor with only one normal C7 gene. An initial scaffold of rudimentary anchoring fibrils in the host might be necessary for optimal deposition of wild-type C7 from the allogeneic cells, but it is clear that a clinical response does not depend on the presence of increased numbers of anchoring fibrils. Our data are limited to assessments of skin-biopsy specimens obtained within the first year after transplantation. Although rare anchoring-fibril-like structures were seen in Patient 4, the development of anchoring fibrils that fulfill the established ultrastructural criteria may require a longer interval after bone marrow infusion. Together, our findings suggest that the infusion of bone marrow from a healthy donor can ameliorate recessive dystrophic epidermolysis bullosa in humans, as has previously been shown in the mouse model of the disorder. Substantial efforts are under way to understand the physiology of the apparent clinical response after bone marrow transplantation and to identify the stem-cell population responsible for this effect.

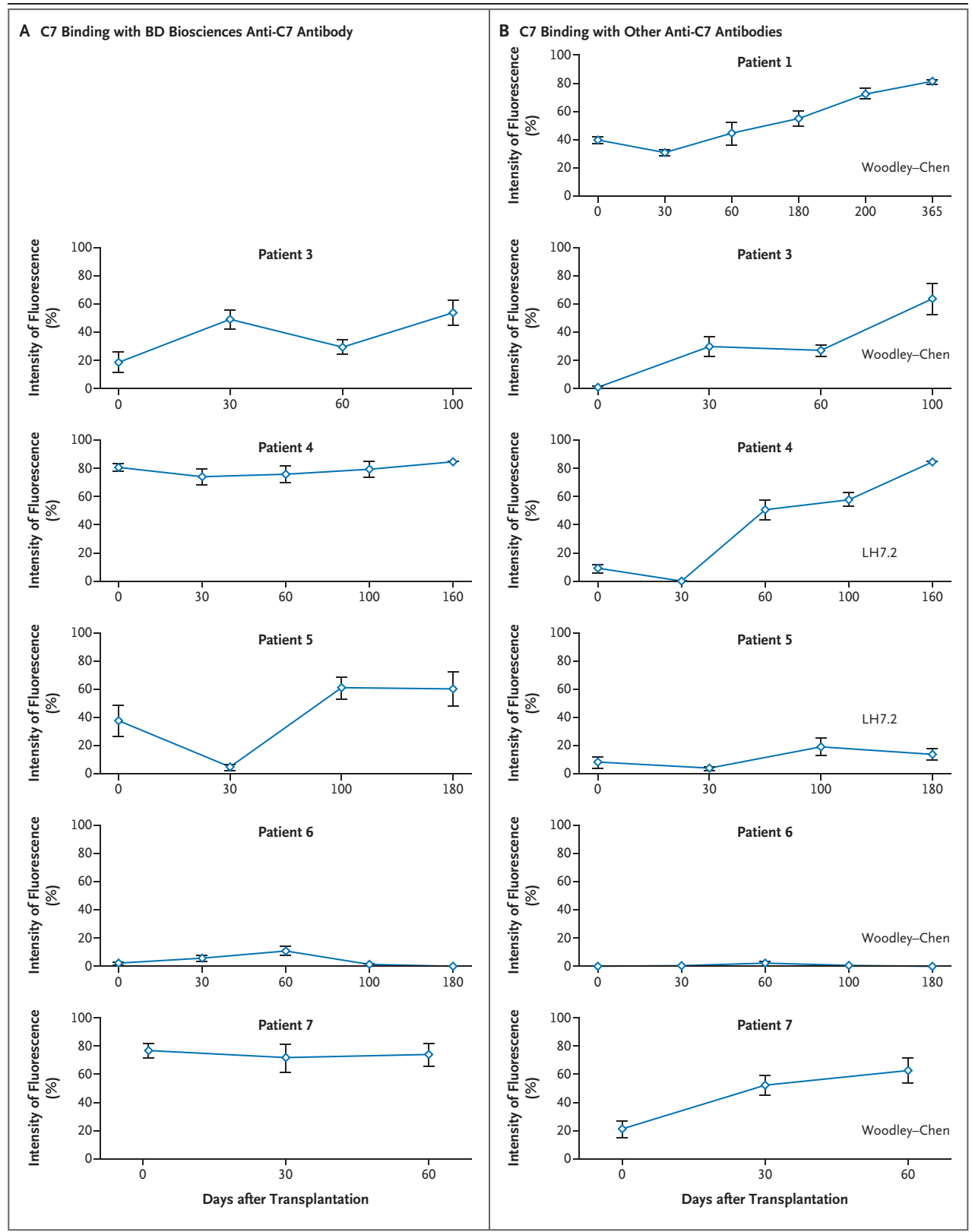
Despite the apparent beneficial effect of bone marrow stem cells in patients with recessive dystrophic epidermolysis bullosa, allogeneic bone marrow transplantation remains a high-risk procedure typically reserved for patients with imminently life-threatening disease, such as those with high-risk lymphohematopoietic malignant disease.²¹ Before this clinical trial, it was not known whether patients with preexisting mucocutaneous disease could tolerate the conventional conditioning regimens used as preparation for allogeneic bone marrow transplantation. Although

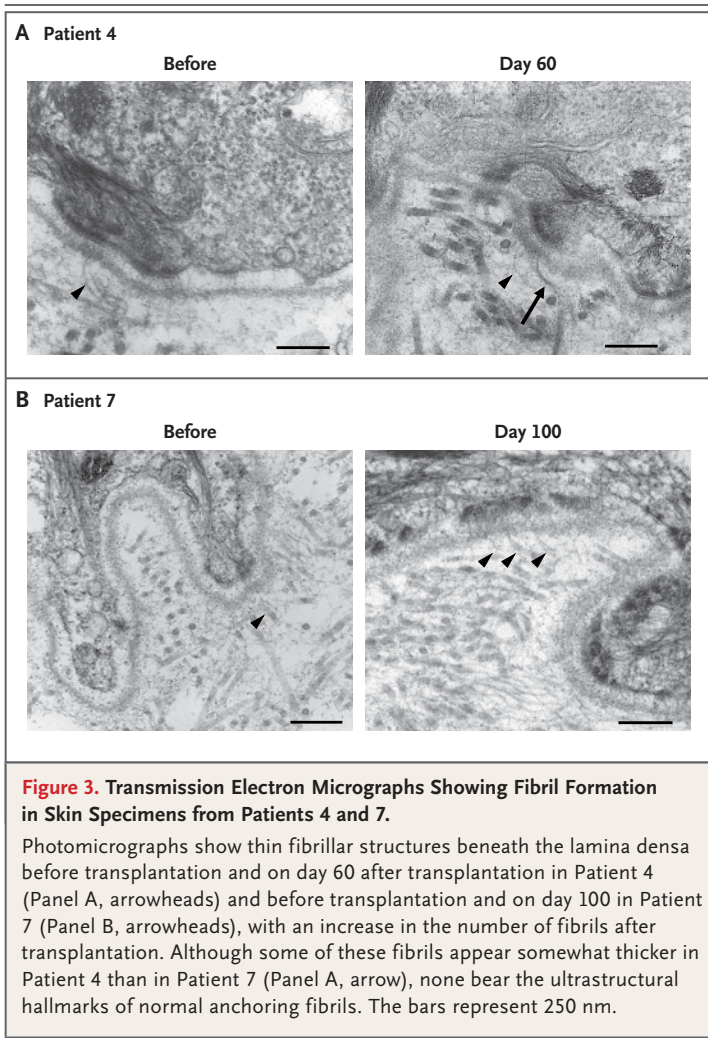
Figure 2 (facing page). Mean (\pm SE) Quantification of C7 Fluorescence Intensity at Specific Time Points after Transplantation.

Panel A shows the relative fluorescence intensity with the use of an anti-C7 antibody from BD Biosciences. Panel B shows the results with the use of additional anti-C7 antibodies, which in some cases failed to bind mutant C7 before transplantation but did bind C7 after transplantation. An anti-C7 antibody provided by Drs. D.T. Woodley and M. Chen (Keck School of Medicine, University of Southern California) was used for Patients 1, 3, 6, and 7), and an anti-C7 antibody (LH7.2) made by Sigma-Aldrich was used for Patients 4 and 5. (Each antibody was applied to tissue from Patients 3 through 7; the data presented are for samples showing the most pronounced changes in C7 expression.) Species-specific and isotype-specific control antibodies, which were used in assays performed on the same day as those carried out with anti-C7 antibodies, yielded negative results (data not shown). Note that 100% is the maximal measurable fluorescence intensity on the gray scale.

grade 3 mucositis occurred in all the patients in our study, as is typical for patients without pre-existing mucocutaneous disease, only one patient had severe cutaneous toxicity. Notably, no patient had uncontrolled cellulitis, despite pretransplantation bacterial or fungal skin colonization. Clearly, the risks of bone marrow transplantation need to be weighed against the risks and benefits of alternative innovative therapies now being explored (e.g., injections of C7 protein or ex vivo grafting of allogeneic or gene-corrected autologous cells).^{17,22-35} Although these measures may prove to ameliorate morbidity, recessive dystrophic epidermolysis bullosa is a systemic disease, and the benefits of these other interventions have thus far been brief or limited to small areas of skin. Therefore, new approaches, such as the one we describe here, are being explored. Already, we and others are considering modifications to enhance safety, such as the coinfusion of mesenchymal stromal cells or the use of reduced-dose conditioning before bone marrow transplantation, recognizing that the latter approach may increase the risk of opportunistic infection as a result of delayed immune reconstitution brought about by the additional immunosuppression.

In summary, our data suggest that the infusion of allogeneic bone marrow stem cells can lead to increased C7 deposition and reduced blistering in patients with severe recessive dystrophic epidermolysis bullosa. However, the unique skin and





mucosal membrane defects of this disease pose a particular challenge to any bone marrow transplantation program. Clearly, much remains to be learned regarding the mechanism of the apparent functional correction as well as the long-term risks and benefits of this therapeutic approach, including the risk of squamous-cell carcinoma, which may occur after chemotherapy or as a result of incomplete correction of the underlying disease. Despite the potential benefits of marrow transplantation, it is a high-risk therapeutic approach that could shorten the expected survival of patients with recessive dystrophic epidermolysis bullosa, particularly those with less severe clinical manifestations. Nevertheless, the results to date support the study of stem-cell-based approaches for patients who have the severest forms of epidermolysis bullosa.

Supported in part by grants from the National Institutes of Health (5R01-HL049997, to Dr. Blazar), from the Ministry of Health, Labor, and Welfare of Japan and the Ministry of Education, Culture, Sports, Science, and Technology of Japan (to Dr. Ishida-Yamamoto), and from the University of Minnesota Academic Health Center, the Epidermolysis Bullosa (Liao Family) Research Fund, the Sarah Rose Mooreland EB Fund, and the Children's Cancer Research Fund.

Disclosure forms provided by the authors are available with the full text of this article at NEJM.org.

We thank Dr. Angela M. Christiano for her helpful review of the original treatment protocol; Ron McElmurry, Brandon Peacock, Lily Xia, Amanda Kobs, Cindy Eide, Trevor Keyler, Christopher Lees, Carolyn Mann-Sandbakken, Meghan Munger, Michael Gitler, Dr. Ana Junqueira, Teresa Kivisto, and Pat Fidler for their technical and clinical help; Drs. Mei Chen and David Woodley for the anti-C7 antibody and for testing of anti-C7 antibodies in patients' blood before and after transplantation; and Noriko Takashita and Stomi Igawa for preparing the electron-microscopical images for the study.

REFERENCES

1. Fine JD, Eady RA, Bauer EA, et al. The classification of inherited epidermolysis bullosa (EB): report of the Third International Consensus Meeting on Diagnosis and Classification of EB. *J Am Acad Dermatol* 2008;58:931-50.
2. Dang N, Murrell DF. Mutation analysis and characterization of COL7A1 mutations in dystrophic epidermolysis bullosa. *Exp Dermatol* 2008;17:553-68.
3. Wessagowit V, Kim SC, Woong Oh S, McGrath JA. Genotype-phenotype correlation in recessive dystrophic epidermolysis bullosa: when missense doesn't make sense. *J Invest Dermatol* 2005;124:863-6.
4. Shimizu H, McGrath JA, Christiano AM, Nishikawa T, Uitto J. Molecular basis of recessive dystrophic epidermolysis bullosa: genotype/phenotype correlation in a case of moderate clinical severity. *J Invest Dermatol* 1996;106:119-24.
5. Pulkkinen L, Uitto J. Mutation analysis and molecular genetics of epidermolysis bullosa. *Matrix Biol* 1999;18:29-42.
6. Woodley DT, Hou Y, Martin S, Li W, Chen M. Characterization of molecular mechanisms underlying mutations in dystrophic epidermolysis bullosa using site-directed mutagenesis. *J Biol Chem* 2008;283:17838-45.
7. Pillay E. Epidermolysis bullosa. 1. Causes, presentation and complications. *Br J Nurs* 2008;17:292-6. [Erratum, *Br J Nurs* 2008;17:413.]
8. Abercrombie EM, Mather CA, Hon J, Graham-King P, Pillay E. Recessive dystrophic epidermolysis bullosa. 2. Care of the adult patient. *Br J Nurs* 2008;17:S6, S8, S10 passim.
9. Fine JD, Johnson LB, Weiner M, Li KP, Suchindran C. Epidermolysis bullosa and the risk of life-threatening cancers: the National EB Registry experience, 1986-2006. *J Am Acad Dermatol* 2009;60:203-11.
10. Fine J-D. Premature death in epidermolysis bullosa. In: Fine J-D, Hinter H, eds. *Life with epidermolysis bullosa (EB): etiology, diagnosis, multidisciplinary care and therapy*. New York: Springer-Verlag, 2009: 197-203.
11. Mellerio JE, Weiner M, Denyer JE, et al. Medical management of epidermolysis bullosa: Proceedings of the IInd International Symposium on Epidermolysis Bullosa, Santiago, Chile, 2005. *Int J Dermatol* 2007;46:795-800.
12. Ly L, Su JC. Dressings used in epidermolysis bullosa blister wounds: a review. *J Wound Care* 2008;17:482, 484-6, 488 passim.
13. Heinonen S, Männikkö M, Klement JF, Whitaker-Menezes D, Murphy GF, Uitto J. Targeted inactivation of the type VII

- collagen gene (Col7a1) in mice results in severe blistering phenotype: a model for recessive dystrophic epidermolysis bullosa. *J Cell Sci* 1999;112:3641-8.
14. Tolar J, Ishida-Yamamoto A, Riddle M, et al. Amelioration of epidermolysis bullosa by transfer of wild-type bone marrow cells. *Blood* 2009;113:1167-74.
 15. Brunstein CG, Barker JN, Weisdorf DJ, et al. Umbilical cord blood transplantation after nonmyeloablative conditioning: impact on transplantation outcomes in 110 adults with hematologic disease. *Blood* 2007;110:3064-70.
 16. Tidman MJ, Eady RA. Evaluation of anchoring fibrils and other components of the dermal-epidermal junction in dystrophic epidermolysis bullosa by a quantitative ultrastructural technique. *J Invest Dermatol* 1985;84:374-7.
 17. Wong T, Gammon L, Liu L, et al. Potential of fibroblast cell therapy for recessive dystrophic epidermolysis bullosa. *J Invest Dermatol* 2008;128:2179-89.
 18. Tidman MJ, Eady RA. Ultrastructural morphometry of normal human dermal-epidermal junction: the influence of age, sex, and body region on lamellar and non-lamellar components. *J Invest Dermatol* 1984;83:448-53.
 19. Chen M, Chan LS, Cai X, O'Toole EA, Sample JC, Woodley DT. Development of an ELISA for rapid detection of anti-type VII collagen autoantibodies in epidermolysis bullosa acquisita. *J Invest Dermatol* 1997;108:68-72.
 20. Fritsch A, Loeckermann S, Kern JS, et al. A hypomorphic mouse model of dystrophic epidermolysis bullosa reveals mechanisms of disease and response to fibroblast therapy. *J Clin Invest* 2008;118:1669-79.
 21. Armitage JO. Bone marrow transplantation. *N Engl J Med* 1994;330:827-38.
 22. Woodley DT, Keene DR, Atha T, et al. Injection of recombinant human type VII collagen restores collagen function in dystrophic epidermolysis bullosa. *Nat Med* 2004;10:693-5.
 23. Woodley DT, Remington J, Huang Y, et al. Intravenously injected human fibroblasts home to skin wounds, deliver type VII collagen, and promote wound healing. *Mol Ther* 2007;15:628-35.
 24. Remington J, Wang X, Hou Y, et al. Injection of recombinant human type VII collagen corrects the disease phenotype in a murine model of dystrophic epidermolysis bullosa. *Mol Ther* 2009;17:26-33.
 25. Mecklenbeck S, Compton SH, Mejía JE, et al. A microinjected COL7A1-PAC vector restores synthesis of intact procollagen VII in a dystrophic epidermolysis bullosa keratinocyte cell line. *Hum Gene Ther* 2002;13:1655-62.
 26. Chen M, Kasahara N, Keene DR, et al. Restoration of type VII collagen expression and function in dystrophic epidermolysis bullosa. *Nat Genet* 2002;32:670-5.
 27. Woodley DT, Keene DR, Atha T, et al. Intradermal injection of lentiviral vectors corrects regenerated human dystrophic epidermolysis bullosa skin tissue in vivo. *Mol Ther* 2004;10:318-26.
 28. Woodley DT, Krueger GG, Jorgensen CM, et al. Normal and gene-corrected dystrophic epidermolysis bullosa fibroblasts alone can produce type VII collagen at the basement membrane zone. *J Invest Dermatol* 2003;121:1021-8.
 29. Ortiz-Urda S, Thyagarajan B, Keene DR, et al. Stable nonviral genetic correction of inherited human skin disease. *Nat Med* 2002;8:1166-70. [Erratum, *Nat Med* 2003;9:237]
 30. Ortiz-Urda S, Lin Q, Green CL, Keene DR, Marinkovich MP, Khavari PA. Injection of genetically engineered fibroblasts corrects regenerated human epidermolysis bullosa skin tissue. *J Clin Invest* 2003;111:251-5.
 31. Gache Y, Baldeschi C, Del Rio M, et al. Construction of skin equivalents for gene therapy of recessive dystrophic epidermolysis bullosa. *Hum Gene Ther* 2004;15:921-33.
 32. Ferrari S, Pellegrini G, Matsui T, Mavilio F, De Luca M. Gene therapy in combination with tissue engineering to treat epidermolysis bullosa. *Expert Opin Biol Ther* 2006;6:367-78.
 33. Ferrari S, Pellegrini G, Mavilio F, De Luca M. Gene therapy approaches for epidermolysis bullosa. *Clin Dermatol* 2005;23:430-6.
 34. Fivenson DP, Scherschun L, Choucair M, Kukuruga D, Young J, Shwayder T. Graftskin therapy in epidermolysis bullosa. *J Am Acad Dermatol* 2003;48:886-92.
 35. De Luca M, Pellegrini G, Mavilio F. Gene therapy of inherited skin adhesion disorders: a critical overview. *Br J Dermatol* 2009;161:19-24.

Copyright © 2010 Massachusetts Medical Society.

POWERPOINT SLIDES OF JOURNAL FIGURES AND TABLES

At the *Journal's* Web site, subscribers can automatically create PowerPoint slides. In a figure or table in the full-text version of any article at NEJM.org, click on Get PowerPoint Slide. A PowerPoint slide containing the image, with its title and reference citation, can then be downloaded and saved.