

Bone metastases from differentiated thyroid carcinoma

M M Muresan¹, P Olivier², J Leclère¹, F Sirveaux³, L Brunaud⁴, M Klein¹, R Zarnegar⁵ and G Weryha¹

¹Endocrinology Department and ²Nuclear Medicine Department, Hôpital Brabois Adultes, CHU Nancy, 54500 Vandoeuvre, France

³Clinic of Traumatology and Orthopaedics, 54000 Nancy, France

⁴Digestive and Endocrine Surgery Department, Hôpital Brabois Adultes, CHU Nancy, 54500 Vandoeuvre, France

⁵Department of Surgery, Weill Cornell Medical College, 525 East 68th Street, F-2024, New York, New York 10065, USA

(Correspondence should be addressed to M M Muresan; Email: m.muresan@chr-metz-thionville.fr)

Abstract

The presence of distant metastases from differentiated thyroid carcinoma decreases the 10-year survival of patients by 50%. Bone metastases represent a frequent complication especially of follicular thyroid cancer and severely reduce the quality of life causing pain, fractures, and spinal cord compression. Diagnosis is established by correlating clinical suspicion with imaging. Imaging is essential to detect, localize, and assess the extension of the lesions and should be used in conjunction with clinical evidence. Bone metastases are typically associated with elevated markers of bone turnover, but these markers have not been evaluated in differentiated thyroid cancer. Skeletal and whole-body magnetic resonance imaging and fusion 2-deoxy-2-[¹⁸F]fluoro-D-glucose whole-body positron emission tomography/computed tomography (PET/CT) are the best anatomic and functional imaging techniques available in specialized centers. For well-differentiated lesions, iodine-PET scan combined ¹²⁴I-PET/CT is the newest imaging development and ¹³¹I is the first line of treatment. Bisphosphonates reduce the complications rate and pain, alone or in combination with radioiodine, radionuclides, or external beam radiotherapy and should be employed. Surgery and novel minimally invasive consolidation techniques demand an appropriate patient selection for best results on a multimodal approach. Basic research on interactions between tumor cells and bone microenvironment are identifying potential novel targets for future more effective therapeutic interventions for less differentiated tumors.

Endocrine-Related Cancer (2008) 15 37–49

Introduction

Patients with differentiated thyroid carcinoma (DTC) have a 10-year survival rate of 80–95%. However, when distant metastases are present, the overall 10-year survival rate is 40% (Hoie *et al.* 1988, Ruegamer *et al.* 1988, Mizukami *et al.* 1990, Samaan *et al.* 1992, Schlumberger 1998). One selected compendium of 13 studies found that among 1231 patients, 25% of metastases were to the bone, 49% to the lung, 15% to both lung and bone, and 10% to other soft tissues (Mazzaferri 1993). The methods used more than 15 years ago for diagnosis and treatment differ, however, from the present management. A more recent study shows that survival drops to 14% for patients older than 40 years with macronodular lung metastases or multiple bone metastases (Durante *et al.* 2006).

After the age of 40 years, 10% of patients with papillary thyroid carcinoma (PTC), 25% of patients with follicular thyroid carcinoma (FTC), and 35% of patients with Hurthle cell carcinoma (Lopez-Penabad *et al.* 2003) develop distant metastases. Bone metastases from DTC occur in 2–13% of patients (McCormack 1966, Marcocci *et al.* 1989, Proye *et al.* 1992, Schlumberger *et al.* 1996, Fanchiang *et al.* 1998, Lin *et al.* 1999, Pittas *et al.* 2000, Bernier *et al.* 2001). The study of Durante *et al.* (2006) found 44% of bone metastases in 444 metastatic DTC patients. They are more frequent in FTC (7–28%) compared with PTC (1.4–7%).

When bone metastases are present, the overall survival at 10 years was reported to range from 13 to 21% (Beierwaltes *et al.* 1982, Schlumberger *et al.*

1986, Marcocci *et al.* 1989). The extent of metastatic disease to bone (Ruegamer *et al.* 1988, Lin *et al.* 1999) and its response to radioactive iodine (Schlumberger *et al.* 1986, Lin *et al.* 1999) are associated with survival. Palliative treatment is frequently the only option at diagnosis. These osteolytic lesions reduce severely the quality of life causing pain, fractures, and spinal cord compression.

Accurate staging for appropriate follow-up allows early detection and improves treatment results (Hindie *et al.* 2007). Furthermore, gene expression profiling could detect evidence on tumor aggressive characteristics and propensity to metastasize. This profiling and several staining techniques could be available on FNAB specimens also (Kebebew *et al.* 2007, Rodolico *et al.* 2007, Vasko & Saji 2007).

Physiopathology of bone metastases from DTC

Disseminated cells of various cancers are clonally different from primary tumors. Different genotypes might be selected by different microenvironments. Some studies have shown that bone involvement is more frequent in well-DTC compared with moderately or poorly DTC (Nagamine *et al.* 1985, Marcocci *et al.* 1989, Glinsky *et al.* 2005). These findings gave rise to terms such as benign metastasizing thyroid tumor, metastasizing adenoma, and malignant adenoma. However, the study of Marcocci did not include poorly DTC. Out of a total of 780 patients, only 30 (3.8%) had bone metastases. In two studies reporting a total of 190 follicular carcinoma patients with bone metastases, 148 were moderately differentiated (Massin *et al.* 1984, Schlumberger *et al.* 1986). In the series from Memorial Sloan-Kettering Cancer Center (MSKCC) on 79 DTC patients with bone metastases, two-thirds had either poorly differentiated or undifferentiated lesions at both the primary and metastatic sites (Tickoo *et al.* 2000). In one series of metastatic patients, multiple bone metastases correlated with poor survival (Durante *et al.* 2006).

Only cancer cells that exchange biological information with bone environments are able to establish bone metastases. Paget (1989) 'seed and soil' hypothesis is widely accepted (Liotta & Kohn 2001, Fidler 2002): circulating cancer cells (seeds) have a propensity to metastasize to organs with the micro-environment (soil) advantageous for their growth. The ability of cells to survive, multiply, and recruit a blood supply gives rise to metastases. Bone is a large repository for immobilized growth factors, including transforming growth factor, insulin-like growth

factor-I and -II (IGF-I and -II), fibroblast growth factors, platelet-derived growth factors, bone morphogenetic proteins, and calcium. Released and activated during bone resorption these factors render the bone fertile for tumor growth (Roodman 2004).

More than 80% of bone metastases from all tumors including DTC are located in axial skeleton red marrow where blood flow is high (vertebrae, ribs, and hips). Tumor cell adhesive molecules bind the tumor cells to marrow stromal cells and bone matrix allowing them to grow and produce angiogenic and bone-resorbing factors.

One recent review concentrated on the physiopathology of bone metastases from thyroid cancers (Wexler & Sharretts 2007). Molecular biology studies try to explain the higher propensity of follicular and less differentiated cancers to metastasize to bone. One hypothesis was the difference in the expression of tumor suppressor genes, caveolin-1 and caveolin-2. Although the expression is up-regulated in FTC and down-regulated in PTC, the down-regulation was also found in the anaplastic thyroid cancer cells (Aldred *et al.* 2003, 2004). The latter group expresses in large amounts focal adhesion kinase (FAK). FAK affects adhesion, motility, and distant site tumor growth (Owens *et al.* 1996). Follicular thyroid cancer cells express less fibronectin resulting in higher cellular adhesion and migration (Chen *et al.* 2001).

Most DTC patients have predominantly osteolytic lesions, with secondary formation of bone in response to bone destruction. There is usually a concomitant increase in both technetium-labeled bisphosphonates uptake on bone scintigraphy (indicating bone formation) and N-telopeptide values (NTx, a marker of bone resorption). Bone sialoprotein (Bellahcene *et al.* 1998) and integrin avb3 (Pecheur *et al.* 2002) were found to be up-regulated in thyroid cancer cells and involved in tumor aggressiveness and tumor osteolysis.

Clinical evolution and symptoms

The most common manifestations of bone metastases from DTC: pain, fractures, and spinal cord compression are associated with lesions in the axial skeleton.

Pain often presents as the principal symptom of metastatic bone involvement (Coleman 2001) and progressively becomes more severe and resistant to commonly used non-opioid analgesics. Metastatic bone pain is associated with local chemical release of cytokines by tumor cells causing stimulation of intraosseous nerves, and pressure or mass effect of the tumor tissue within the bone (Selvaggi & Scagliotti 2005).

One retrospective study found that spinal cord compression occurs more frequently in DTC when compared with other bone-seeking cancers: 28% compared with prostate (10%) and breast cancers (8%) (Coleman 2006). The incidence of pathological fractures was 13%, and the incidence of both spinal cord compression and pathological fracture was 6%. (Bernier *et al.* 2001). Early diagnosis, high-dose corticosteroid treatment, decompressive surgery, and spinal stabilization or radiotherapy are essential for neurological recovery within the first 24–48 h of presentation for bone metastases (Onimus *et al.* 1996, Alvarez *et al.* 2003). Back pain associated with an abnormality on a plain spinal radiograph in these cancer patients has a 60% incidence of epidural disease on magnetic resonance imaging (MRI).

Diagnosis

Diagnosis is established by correlating clinical suspicion with imaging. For cancers with high tropism to bone, elevated bone turnover markers could be the first sign of bone involvement but are not yet explored in thyroid cancer.

Biology

In other types of cancer, elevated markers of bone turnover predict survival and early tumor response to treatment (Coleman *et al.* 2005). Specific tests include markers of bone formation (osteocalcin, bone-specific alkaline phosphatase (BSAP), and the cleaved amino and carboxy terminal peptides from procollagen: the N and C terminal propeptides of human procollagen type I) and especially bone resorption (the C terminal telopeptide and N terminal telopeptide NTx of collagen type I and deoxypyridinoline; Demers *et al.* 2003) and markers of osteoclastogenesis: the soluble receptor activator of nuclear factor- κ B ligand (sRANK-L), its receptor (RANK), and its decoy receptor osteoprotegerin (OPG; Demers *et al.* 2003). These markers have not been evaluated in differentiated thyroid cancer.

Imaging

Imaging is essential to detect, localize, and assess the extension of the lesions and should be used in conjunction with clinical and biochemical evidence (Rosenthal 1997, Rybak & Rosenthal 2001). Imaging can also guide biopsies for histomorphological diagnosis.

Anatomic imaging

Plain radiographs can show bone destruction, sclerosis, and the absence of pedicles by tumor infiltration, but lesions may not appear on X-rays for several months with the limit of detection of lesions > 1 cm. In the study of Schlumberger, among 115 thyroid cancer patients who had bone metastases only, bone radiographs documented a single bone metastasis in 33 patients, multiple bone metastases in 74 patients, and were normal in 8 patients (Durante *et al.* 2006).

Computed tomography (CT) can evaluate the extent of metastatic lesions and is particularly useful for sites that are difficult to evaluate, i.e., the spine and pelvis. For bone-seeking cancers, diagnostic sensitivity is 71–100%. CT describes foci before bone destruction has occurred as increased attenuation of the normally fatty bone marrow. Low soft tissue contrast and lack of information on broad areas of the spine represent the technique's shortcomings.

Skeletal and whole-body MRI provides detailed images of both bone and bone marrow, so it is best employed when spinal cord compression and involvement by the tumor is suspected. Whole-body MRI yielded a sensitivity of 94% and diagnostic accuracy of 91% when screening for bone metastases in patients with different cancer types (Schmidt *et al.* 2006) with a cut-off size for the detection of malignant bone lesions of 2 mm.

No data are available on the sensitivity and specificity of CT and whole-body MRI in screening for bone metastases from DTC, but when bone involvement is suspected (aggressive tumor behavior, metastases at other sites, clinical data), whole-body MRI or (non)enhanced CT must be employed for risk assessment and treatment planning.

Functional imaging

The perimetastatic osteoblastic reaction (increased blood flow, new bone formation, and enhanced bone matrix turnover) accounts for abnormal radiopharmaceutical uptake on bone scan. ^{99m}Tc -labeled diphosphonates such as methylene diphosphonate (MDP) are most commonly used for localization and staging. Bone scan can also assess response to treatment of some bone-seeking cancers. When compared with anatomic imaging, the single-photon emission CT (SPECT) and SPECT/CT could make MRI better for vertebral body lesions and SPECT for the posterior elements (Ryan & Fogelman 1995, Kosuda *et al.* 1996).

However, bone scintigraphy relies on the detection of osteoblastic reaction. In thyroid cancer, bone metastases are primarily osteolytic, so the proportion of false-negative and false-positive results is high (Ito *et al.* 2007).

Tumor cell imaging by ^{131}I or ^{123}I whole-body scan (WBS) are both more specific and sensitive than $^{99\text{m}}\text{Tc}$ -MDP but only for well-differentiated, NIS-positive thyroid tumors (Schirrmeister et al. 2001, de Geus-Oei et al. 2002). However, multiple site bone involvement usually correlates with aggressive, less differentiated tumor types.

2-Deoxy-2-[^{18}F]fluoro-D-glucose whole-body positron emission tomography (FDG-PET) shows preferential tracer uptake in malignant cells with a high turnover rate by increased glucose metabolism. In thyroid cancer, PET imaging is useful in patients with metastatic poorly differentiated tumors, with high thyroglobulin (Tg) levels and negative ^{131}I -WBS. A positive FDG scan has a strong negative prognostic value as it was associated, by itself, with an eightfold increased risk of death (Wang et al. 2000, Robbins et al. 2006).

In one study that compared different imaging techniques for the detection of distant metastases from thyroid cancer, whole-body ^{18}F -FDG PET, $^{99\text{m}}\text{Tc}$ -MIBI SPET, and post-therapeutic ^{131}I -Na scintigraphy all demonstrated five of the six bone metastases (83.3%; Iwata et al. 2004).

Thyrotrophin (TSH) stimulates thyrocyte metabolism, glucose transport, and glycolysis. FDG is a glucose analog. Several studies showed that rhTSH stimulation improves the detection of occult thyroid metastases with FDG PET, compared with scans performed on TSH suppression (Chin et al. 2004).

The advantages of rhTSH-stimulated FDG PET and PET-CT fusion scanning in metastatic thyroid cancer are currently under evaluation (ClinicalTrials.gov Identifier: NCT00181168).

Developments in tumor cell imaging for DTC

Positron-emitting radioisotope ^{124}I (half-life, 4.2 days) uses the sodium iodide symporter and is employed for three-dimensional imaging of the distribution of radioiodine uptake within the benign and malignant thyroid disease since (the 1980s) 1985 (Frey et al. 1986). In DTC CT, ^{131}I -WBS, ^{124}I -PET, and combined ^{124}I -PET/CT imaging detected 56, 83, 87, and 100% of lesions respectively (Freudenberg et al. 2004). ^{124}I -PET detected more small bone metastases compared with ^{131}I -WBS. ^{124}I -PET is performed as soon as 24 h after the administration of the radiotracer and yields the same diagnostic accuracy as high-dose WBS does. These results warranted confirmation through a clinical trial that will start recruiting at the Stanford University (ClinicalTrials.gov Identifier: NCT00373711).

Treatment

Management of these patients must involve a multidisciplinary approach consisting of medical treatment (analgesia and bisphosphonates), radiotherapy, surgery, and radioisotopes.

Current treatments

Radioactive iodine

All series on radioactive iodine therapy for bone metastases showed that bone metastases are generally resistant to commonly used activities of ^{131}I and may require other approaches (Schlumberger et al. 1996). The low remission rate (29–35%) could be related to the large extent of disease at presentation (Marcocci et al. 1989, Pacini et al. 1994, Zettinig et al. 2002) and the dose delivery to bone metastases. Patient-specific, three-dimensional (3D) imaging-based dosimetry with ^{124}I -PET is the subject of ongoing investigation for thyroid cancer (Sgouros et al. 2004).

A retrospective study evaluated therapeutic outcome, total administered radioiodine activities, and side effects (blood count alterations grades I–IV, WHO classification, and acute leukemia) in 107 patients with initial bone metastases (Petrich et al. 2001). Patients younger than 45 years were classified as group 1 (stage II, ‘low risk’, WHO classification) and those over 45 years as group 2 (stage IV, ‘high risk’). Total or partial remissions were more frequent in group 1 than group 2 (62.5% vs 49.5%) with lower delivered activities (18.89 ± 15.08 GBq vs 41.97 ± 31.25 GBq). Three out of four group 1 patients with three or less bone metastases had complete remission (11.1 GBq). Long-term and partial remission were obtained in a large proportion of patients, 24 and 27% of cases respectively, with low overall rate and degree of side effects. This study concluded that initial bone metastases in selected DTC patients up to 45 years and especially in those with less than three bone metastases can be treated with curative intent.

Surgery

The main indications for surgery are persistent pain refractory to medical therapy, tumors with poor radioactive uptake, and spinal instability with or without neural compression. Various scoring systems guiding the surgical strategy are based on the primary tumor type, the presence of visceral metastases, and number of bone metastases (Tokuhashi et al. 1990, Enkaoua et al. 1997, Tomita et al. 2001).

Few studies have analyzed the impact of surgery on DTC bone metastases (Marcocci et al. 1989, Proye et al. 1992, Pittas et al. 2000). Reports have shown that

surgical removal of up to five bone metastases are associated with improved survival and quality of life (Niederle *et al.* 1986, Bernier *et al.* 2001, Zettinig *et al.* 2002). Therefore, some groups recommend surgical excision for accessible, solitary, isolated metastases evident on X-ray with pre- and post-operative radioiodine as complementary treatment (Proye *et al.* 1992). In patients without extra-skeletal metastases, the radical surgical extirpation of bone metastases from DTC may be associated with improved survival.

New minimally invasive techniques have been developed for select groups of patients. Percutaneous vertebroplasty (first developed in France for the treatment of aggressive vertebral angiomas; Galibert *et al.* 1987) and kyphoplasty represent viable alternatives to surgery in patients with metastatic vertebral fractures from different cancer types without neurological damage or spinal instability (Fourney *et al.* 2003). Both procedures involve percutaneous injection of polymethylmethacrylate bone cement into a collapsed vertebral body. In kyphoplasty, a balloon is first inflated, thereby restoring the vertebral body height and reducing kyphosis, followed by low-pressure cement injection. The latter is performed on an outpatient basis is rarely associated with complications and highly effective in reducing axial spinal pain (Gaitanis *et al.* 2005). New orthopedic prosthetic devices for hips, pelvis, and shoulders may also provide a better outcome in terms of pain and restoration of function. Very little data are available for these techniques in DTC (Greenblatt & Chen 2007).

Embolization can be used for palliative relief of skeletal pain and prevention of further tumor growth in bone metastases. It can also be used preoperatively to reduce blood loss. Several case reports suggest beneficial effects without severe complications for bone metastases of DTC (Keller *et al.* 1983, Monteil *et al.* 1985, Leger 1995).

Studies have evaluated embolization in combination with radioiodine therapy in patients with large unresectable bone metastases from DTC. Endpoints of this combined treatment were Tg levels, pain, and neurological symptoms. The outcomes were compared with a control group treated only with radioiodine therapy (Van Tol *et al.* 2000). In the embolization group, serum Tg after two ^{131}I therapies had decreased dramatically compared with the control group. CT showed a median volume reduction of the metastasis after radioiodine treatment combined with embolization of 52.5%. Both strategies resulted in a rapid resolution of pain and neurological symptoms (Eustatia-Rutten *et al.* 2003).

Radiofrequency ablation (RFA) and ethanol injection are minimally invasive techniques that require a highly specialized team and appropriate patient selection. The role in differentiated thyroid cancer lesions is being investigated (Monchik *et al.* 2006, Wexler & Sharretts 2007).

External radiotherapy

DTC bone metastases without affinity for radioactive iodine may respond to external beam radiation therapy (EBRT; Simpson *et al.* 1988, Simpson 1990, Tsang *et al.* 1998). EBRT is a palliative treatment indicated only when pain, risk for fracture, and neurological complications of spinal cord compression are present.

Complete or partial pain relief is obtained in more than 80% of patients for at least 6 months in 50% of cases. Irrespective of the fractionation schedule, the number of subsequent spinal cord compression or pathological fractures is low. All prospective randomized trials for different bone-seeking cancers showed that single fraction regimens are at least as effective as fractionated regimens with increased convenience and cost control (Falkmer *et al.* 2003, Frassica 2003).

For DTC, the combination of external radiotherapy and radioiodine therapy has been reported to have an impact on cancer recurrence and pain relief (Tubiana *et al.* 1985). When employed after surgery, it results in reduced risk for further bone destruction (Fig. 1).

RFA prevents cytokine release from tumor cells and reduces tumor growth into the periosteum. When combined with surgery (Dupuy *et al.* 2001, Halpin *et al.* 2004, 2005), it may improve the outcome of bone-seeking cancers. Currently, there are no data on the association of RFA with radioiodine for bone metastases of DTC.

Chemotherapy

A variety of different chemotherapeutic regimens have been used for metastatic thyroid cancer (Shimaoka *et al.* 1985, Ahuja & Ernst 1987, Hoskin & Harmer 1987, De Besi *et al.* 1991, Casara *et al.* 1993), with limited effect and duration of response. The addition of TSH stimulation to a conventional regimen of chemotherapy could increase its therapeutic effect without increased morbidity (Santini *et al.* 2002). Consistent data on chemotherapy response of bone metastases from poorly DTC are not yet available.

Bisphosphonates

In addition to strictly palliative interventions, bisphosphonates represent a very effective therapeutic option for the prevention of skeletal complications of bone

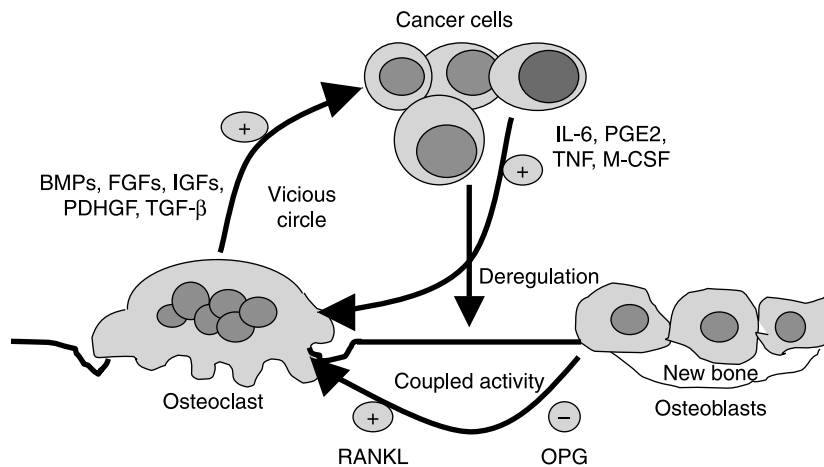


Figure 1 The vicious circle at the bone remodeling unit. Tumor cells produce factors that increase the formation of osteoclasts through the RANK-RANKL (receptor activator of nuclear factor- κ B ligand) system: IL-6 (interleukin-6), prostaglandin E2 (PGE2), tumor necrosis factor (TNF), macrophage colony-stimulating factor (M-CSF), and parathyroid hormone-related peptide (PTH-rP). During bone resorption, osteoclasts release transforming growth factor- β (TGF- β), insulin-like growth factors (IGFs), fibroblast growth factors (FGFs), platelet-derived growth factor (PDGF), and bone morphogenetic proteins (BMPs), which increase the production of parathyroid hormone-related peptide by tumor cells, as well as growth factors that increase tumor growth. This represents the vicious circle that increases bone destruction and tumor growth. OPG, osteoprotegerin. Adapted from (Clamp *et al.* 2004, Roodman 2004).

metastases from different primary tumors. They bind preferentially to bone at the sites of active bone metabolism, are released from the bone matrix during bone resorption, and inhibit osteoclast activity, thereby reducing osteoclast-mediated bone resorption. There are several reports of sclerosis of lytic bone metastases on X-ray after bisphosphonates (Morton *et al.* 1988, Tanaka *et al.* 1996, Kokufu *et al.* 1998, 2000).

Nitrogen-containing bisphosphonates, such as zoledronic acid, pamidronate, and ibandronate, have a unique mechanism of action and greater clinical activity than first-generation bisphosphonates (Coleman 2004) with $\sim 50\%$ reduction in the skeletal-related events. Still, these drug effects on tumor cells and reduction of tumor burden have to be further elucidated, as well as their potential as adjuvant therapy for cancer metastases.

Anti-resorptive effect. A recent study on patients with prostate cancer showed fewer skeletal-related events in the zoledronic acid arm compared with placebo (Canil & Tannock 2002). However, zoledronic acid failed to delay disease progression, lengthen survival, or improve quality of life. The same results were obtained in breast cancer.

In one small study, DTC patients who had been administered pamidronate (90 mg, as a 2-hour i.v. infusion monthly for 12 consecutive cycles) showed a significant decrease in bone pain, improved performance status, and improved quality of life. However, no significant decrease in analgesic

consumption was recorded. Partial radiographic response of bone lesions was observed in two out of ten patients. Side effects were mild and transient (Vitale *et al.* 2001).

Vehicles for radioisotopes. Bisphosphonates-triggered radioisotopes for the palliation of metastatic bone have been proposed for patients with painful disseminated skeletal metastases in whom external beam radiotherapy cannot be administered (Finlay *et al.* 2005).

Commercially available bone-seeking radiopharmaceuticals that target the perimetastatic osteoblastic reaction include: ^{153}Sm -EDTMP, ^{186}Re -HEDP, or ^{89}Sr chloride (Pandit-Taskar *et al.* 2004). The β -emitting radionuclides deliver energy over a range of several millimeters. The newest developments are radionuclides with high-linear energy transfer (LET) α -particles like ^{223}Ra (Nilsson *et al.* 2005) enhance radiobiological potency with increased energy delivery, providing an anti-tumor effect in addition to palliation.

All isotopes seem to be effective in terms of pain control and response rates are between 40 and 95% (Lam *et al.* 2007) for breast and prostate cancers. Thrombocytopenia and neutropenia, which are common to all isotopes, are generally mild and reversible side effects. Dosimetric studies are underway to reduce side effects and provide response predictions. Treatment efficacy is improved with combination therapy. In 126 prostate cancer patients with bone metastases that all received external beam radiotherapy in combination with either

^{89}Sr or placebo; at 3 months, 59% of patients in the active group when compared with 34% within the placebo group were free of new painful metastases, suggesting an ^{89}Sr anti-tumor effect (Porter *et al.* 1993). The combination of zoledronic acid with ^{89}Sr improves pain reduction (Storto *et al.* 2006), leading to the speculation that strontium could have increased availability due to greater bone remodeling associated with bisphosphonates. Finally, several studies evaluated the radionuclides/chemotherapy combined regimen for prostate cancer (Tu *et al.* 2001). These compounds have yet to be investigated for bone metastases from thyroid cancer.

Anti-tumor effect. Preliminary studies suggest that bisphosphonates can exhibit anti-tumor activity both *in vitro* and *in vivo* (Cleazardin *et al.* 2003, 2005, Green 2003). Nitrogen-containing bisphosphonates inhibit the mevalonate pathway that induces apoptosis in osteoclasts and tumor cells alike. They can impair tumor cell adhesion, invasion (Woodward *et al.* 2005) and proliferation, reinforce the effects of cytotoxic agents, and exhibit anti-angiogenic effects. In thyroid cancer cell lines, clodronate inhibited cell growth of endocytic macrophages, osteoclasts, and several cancer cells in a dose-dependent manner. It transiently increased cytosolic Ca^{2+} on slow-growing SW579 thyroid cancer cells but not on fast-growing ARO cells. This implies that clodronate-mediated cell growth inhibition in slow-growing thyroid cancer cells might correlate with a Ca^{2+} signaling pathway (Yang *et al.* 2004).

Nevertheless, the concentrations required for these effects *in vitro* and in animal models were usually much higher than those used in clinical practice. In humans, there is no evidence from any of the clinical trials of bisphosphonates suggesting a beneficial effect on soft tissue metastasis.

In light of these data and comparing the risk of skeletal events in thyroid cancer with other cancers, where bisphosphonates are conventionally employed, bisphosphonates treatment should be employed in bone metastases from DTC. We are using in our practice the same protocols as for breast or prostate cancer, but definitive studies in this area are warranted. Selection of patients for other techniques (surgical procedures and radiotherapy) is made on the basis of a multidisciplinary approach.

Developments and perspectives

Bone resorption inhibitors: targeting osteoclastogenesis

New approaches to prevent and treat bone metastases are being developed (Wittrant *et al.* 2004). Examples

include molecules that directly counter the receptor activator of RANKL, PTH-rP inhibitors (the major mediator of osteolytic disease), and anti-Dkk1.

Targeting the OPG/RANK/RANKL axis may offer a novel therapeutic approach to malignant osteolytic pathologies (Wittrant *et al.* 2004, Croucher *et al.* 2005). Clinical trials with AMG 162 (denosumab, a human monoclonal antibody to RANKL) are currently underway in Europe for patients with myeloma, breast, and prostate cancer skeletal metastases (Body *et al.* 2003). In the United States, several Phase II/III Clinical Trials with denosumab in patients with solid organ tumors or multiple myeloma with radiographic evidence of one or more bone metastases currently receiving oral or i.v. bisphosphonates are underway.

There are no such studies available yet (or for other targets of common osteotropic cancers: TGF- β , PTH-rP/Gli2, BMP-7) specifically for thyroid cancer bone metastases.

Anti-angiogenic factors

In radioactive iodine unresponsive thyroid cancer, several therapeutic approaches are being investigated. Tyrosine kinase receptors control angiogenesis and tumor growth. Tyrosine kinase receptors are targeted through: anti-VEGF – bevacizumab (Avastin), anti-Epidermal growth factor receptor (EGFR; Iressa), anti-Her2/neu (Herceptin) antibodies, and through small molecules (ZD6474 and high-affinity PPARgamma agonist RS-5444) inhibiting VEGFR, EGFR, TIE-2, and RET oncoproteins. Thalidomide blocks the angiogenesis cascade and combrestatins have pro-apoptotic effects. Other molecules target Ras, Raf (ISIS 5132), MEK, TNF-related apoptosis-inducing ligand (TRAIL), Akt/mTOR and HSP90 (geldanamycin), histone deacetylase (FR901228, depsipeptide), and COX2 (celecoxib).

FTC is the most angiogenic-dependent tumor of the thyroid gland. VEGF mRNA and protein levels are associated with mitogenic activity and tumor growth in FTC cell lines. Inhibition of VEGF production or VEGFR phosphorylation has been shown to reduce the growth of FTC xenografts (Soh *et al.* 2000, Ye *et al.* 2002, Schoenberger *et al.* 2004). EGF and its receptor (EGFR) are also over-expressed in thyroid carcinomas (Aasland *et al.* 1990, van der Laan *et al.* 1995) and co-expression of EGF and EGFR is associated with FTC bone metastases (Gorgoulis *et al.* 1992).

Therefore, blockade of both EGFR and VEGFR kinase activities and their downstream targets (Akt and mitogen-activated protein kinase) can offer an attractive approach for the treatment of FTC bone

metastases. One study is underway in France using sunitinib malate (Pfizer): Sutent (THYSU, ClinicalTrials.gov Identifier: NCT00510640).

AEE788 (Novartis Pharma) inhibits both the EGFR and VEGFR receptors (Traxler *et al.* 2004). AEE788 alone or in combination with paclitaxel can significantly reduce tumor size and subsequent bone destruction by FTC in nude mice by direct anti-tumor and anti-angiogenic effects. A phase I study is currently recruiting adult patients with stage IV solid tumors (ClinicalTrials.gov Identifier: NCT00118456).

Gene therapy

Strategies of gene therapy in oncology are: oncogene silencing, tumor suppressor replacement, prodrug therapy, immunotherapy, genetic immunization, anti-sense therapy, ribozyme therapy, antibody neutralization, chemoprotection, and radioiodide therapy.

Several agents are being evaluated for iodine-negative metastases from thyroid cancer, aiming mainly at tumor re-differentiation and increased expression of hNIS. These agents include lithium, retinoids (isotretinoin Accutane, bexarotene Tagretin), and thiazolidinediones (Zarnegar *et al.* 2002, Park *et al.* 2005). hNIS gene transfer into hNIS-defective thyroid cancer could improve the response to radioiodine of iodine-negative bone metastases (Haberkorn *et al.* 2004).

Assessment of therapeutic response

Tg and ^{131}I -WBS have been established as important markers for follow-up in DTC. These markers are not specific for metastatic bone disease in DTC. There are very little data on DTC bone metastases with respect to techniques usually employed for other cancer types due to the reliability of ^{131}I -WBS. However, they are valuable in poorly differentiated or undifferentiated iodine-negative thyroid cancers.

Many studies' aim is to identify biological or imaging markers able to select patients with bone metastases, who are likely to respond to bisphosphonates and anti-neoplastic therapy and to indicate whether these interventions are effective (Clamp *et al.* 2004). Studies that use bone-specific biomarkers to tailor treatment with bisphosphonate or anti-neoplastic therapy have been developed like the multicenter bisphosphonate therapy directed by bone resorption markers (BISMARK) trial recruiting patients with breast cancer and associated metastatic bone disease. The trial is powered to prove non-inferiority between standard and marker-directed administration of zoledronate for the prevention of skeletal-related events.

On X-ray, positive response of the skeletal lesions may be visible as lesion sclerosis progressing from the periphery toward its center.

On bone scan, healing lesions usually demonstrate decreased radioisotope tracer uptake. The 'flare' phenomenon with increased uptake in the early phases of therapy can also be seen due to isotope uptake, by healing bone, and it has been suggested that an increase in the number of lesions is a more reliable marker of disease progression than an increase in the intensity of uptake.

CT density change can evaluate re-mineralization of osteolytic lesions with palliative radiotherapy (Reinbold *et al.* 1989, Chow *et al.* 2004). For less differentiated cancers, ^{18}F -FDG-PET allows for earlier assessment of response compared with bone scan (Stafford *et al.* 2002). In the case of thyroid cancer, one clinical trial will try to evaluate overall response (complete and partial responses) rate based on conventional imaging methods (CT scan, RECIST) and tumor markers as well as early (7 days) and late (3 months) response rates based on functional imaging ^{18}F -FDG-PET and to compare response rates by CT scan versus FDG-PET in patients treated by sunitinib malate (ClinicalTrials.gov Identifier: NCT00519896).

Conclusion

The presence of bone metastases alters the prognosis of patients with DTC. Radioiodine is the first-line treatment for NIS-positive lesions, but significant results are obtained only in select number of patients. In bone-seeking cancers, bisphosphonates are known to increase the time to skeletal complications and relieve pain especially when employed in combination with radioiodine, radionuclides, or external beam radiotherapy. The optimal timing and duration of bisphosphonate therapy and their potential in the prevention of bone metastases is under investigation in clinical trials for solid tumors. Selection of patients is crucial to optimize the multimodal approach of surgery and novel minimally invasive techniques. Apart from tumor and bone-targeted treatment, pain management, and psychological support are essential in clinical decision making. Therefore, a multidisciplinary approach provides an improved quality of life. Basic research on interactions between tumor cells and bone microenvironment are identifying potential novel targets for future more effective therapeutic interventions for poorly DTC.

Acknowledgements

The authors declare that there is no conflict of interest that would prejudice the impartiality of this scientific work.

References

- Aasland R, Akslen LA, Varhaug JE & Lillehaug JR 1990 Co-expression of the genes encoding transforming growth factor- α and its receptor in papillary carcinomas of the thyroid. *International Journal of Cancer* **46** 382–387.
- Ahuja S & Ernst H 1987 Chemotherapy of thyroid carcinoma. *Journal of Endocrinological Investigation* **10** 303–310.
- Aldred MA, Ginn-Pease ME, Morrison CD, Popkie AP, Gimm O, Hoang-Vu C, Krause U, Dralle H, Jhiang SM, Plass C *et al.* 2003 Caveolin-1 and caveolin-2, together with three bone morphogenetic protein-related genes, may encode novel tumor suppressors down-regulated in sporadic follicular thyroid carcinogenesis. *Cancer Research* **63** 2864–2871.
- Aldred MA, Huang Y, Liyanarachchi S, Pellegata NS, Gimm O, Jhiang S, Davuluri RV, de la Chapelle A & Eng C 2004 Papillary and follicular thyroid carcinomas show distinctly different microarray expression profiles and can be distinguished by a minimum of five genes. *Journal of Clinical Oncology* **22** 3531–3539.
- Alvarez L, Perez-Higueras A, Quinones D, Calvo E & Rossi RE 2003 Vertebroplasty in the treatment of vertebral tumors: postprocedural outcome and quality of life. *European Spine Journal* **12** 356–360.
- Beierwaltes WH, Nishiyama RH, Thompson NW, Copp JE & Kubo A 1982 Survival time and ‘cure’ in papillary and follicular thyroid carcinoma with distant metastases: statistics following University of Michigan therapy. *Journal of Nuclear Medicine* **23** 561–568.
- Bellahcene A, Albert V, Pollina L, Basolo F, Fisher LW & Castronovo V 1998 Ectopic expression of bone sialoprotein in human thyroid cancer. *Thyroid* **8** 637–641.
- Bernier MO, Leenhardt L, Hoang C, Aurengo A, Mary JY, Menegaux F, Enkaoua E, Turpin G, Chiras J, Saillant G *et al.* 2001 Survival and therapeutic modalities in patients with bone metastases of differentiated thyroid carcinomas. *Journal of Clinical Endocrinology and Metabolism* **86** 1568–1573.
- De Besi P, Busnardo B, Toso S, Girelli ME, Nacamulli D, Simioni N, Casara D, Zorat P & Fiorentino MV 1991 Combined chemotherapy with bleomycin, adriamycin, and platinum in advanced thyroid cancer. *Journal of Endocrinological Investigation* **14** 475–480.
- Body JJ, Greipp P, Coleman RE, Facon T, Geurs F, Fermand JP, Harousseau JL, Lipton A, Mariette X, Williams CD *et al.* 2003 A phase I study of AMGN-0007, a recombinant osteoprotegerin construct, in patients with multiple myeloma or breast carcinoma related bone metastases. *Cancer* **97** 887–892.
- Canil CM & Tannock IF 2002 Should bisphosphonates be used routinely in patients with prostate cancer metastatic to bone? *Journal of National Cancer Institute* **94** 1422–1423.
- Casara D, Rubello D, Saladini G, Masarotto G, Favero A, Girelli ME & Busnardo B 1993 Different features of pulmonary metastases in differentiated thyroid cancer: natural history and multivariate statistical analysis of prognostic variables. *Journal of Nuclear Medicine* **34** 1626–1631.
- Chen KT, Lin JD, Chao TC, Hsueh C, Chang CA, Weng HF & Chan EC 2001 Identifying differentially expressed genes associated with metastasis of follicular thyroid cancer by cDNA expression array. *Thyroid* **11** 41–46.
- Chin BB, Patel P, Cohade C, Ewertz M, Wahl R & Ladenson P 2004 Recombinant human thyrotropin stimulation of fluoro-D-glucose positron emission tomography uptake in well-differentiated thyroid carcinoma. *Journal of Clinical Endocrinology and Metabolism* **89** 91–95.
- Chow E, Holden L, Rubenstein J, Christakis M, Sixel K, Vidmar M, Finkelstein J, Hayter C, Loblaw A, Wong R *et al.* 2004 Computed tomography (CT) evaluation of breast cancer patients with osteolytic bone metastases undergoing palliative radiotherapy – a feasibility study. *Radiotherapy and Oncology* **70** 291–294.
- Clamp A, Danson S, Nguyen H, Cole D & Clemons M 2004 Assessment of therapeutic response in patients with metastatic bone disease. *Lancet Oncology* **5** 607–616.
- Clezardin P, Fournier P, Boissier S & Peyruchaud O 2003 *In vitro* and *in vivo* antitumor effects of bisphosphonates. *Current Medicinal Chemistry* **10** 173–180.
- Clezardin P, Ebetino FH & Fournier PG 2005 Bisphosphonates and cancer-induced bone disease: beyond their antiresorptive activity. *Cancer Research* **65** 4971–4974.
- Coleman RE 2001 Metastatic bone disease: clinical features, pathophysiology and treatment strategies. *Cancer Treatment Reviews* **27** 165–176.
- Coleman RE 2004 Bisphosphonates: clinical experience. *Oncologist* **9** (Supplement 4) 14–27.
- Coleman RE 2006 Clinical features of metastatic bone disease and risk of skeletal morbidity. *Clinical Cancer Research* **12** 6243s–6249s.
- Coleman RE, Major P, Lipton A, Brown JE, Lee KA, Smith M, Saad F, Zheng M, Hei YJ, Seaman J *et al.* 2005 Predictive value of bone resorption and formation markers in cancer patients with bone metastases receiving the bisphosphonate zoledronic acid. *Journal of Clinical Oncology* **23** 4925–4935.
- Croucher P, Hohen I & Eaton C 2005 Nonosseous effects of osteoprotegerin. *Cancer Treatment Reviews* **31** S14.
- Demers LM, Costa L & Lipton A 2003 Biochemical markers and skeletal metastases. *Clinical Orthopaedics and Related Research* **415** (Supplement) S138–S147.
- Dupuy DE, Monchik JM, Decrea C & Pisharodi L 2001 Radiofrequency ablation of regional recurrence from well-differentiated thyroid malignancy. *Surgery* **130** 971–977.

- Durante C, Haddy N, Baudin E, Leboulleux S, Hartl D, Travagli JP, Caillou B, Ricard M, Lumbroso JD, De Vathaire F *et al.* 2006 Long-term outcome of 444 patients with distant metastases from papillary and follicular thyroid carcinoma: benefits and limits of radioiodine therapy. *Journal of Clinical Endocrinology and Metabolism* **91** 2892–2899.
- Enkaoua EA, Doursounian L, Chatellier G, Mabesoone F, Aimard T & Saillant G 1997 Vertebral metastases: a critical appreciation of the preoperative prognostic tokuhashi score in a series of 71 cases. *Spine* **22** 2293–2298.
- Eustatia-Rutten CF, Romijn JA, Guijt MJ, Vielvoye GJ, van den Berg R, Corssmit EP, Pereira AM & Smit JW 2003 Outcome of palliative embolization of bone metastases in differentiated thyroid carcinoma. *Journal of Clinical Endocrinology and Metabolism* **88** 3184–3189.
- Falkmer U, Jarhult J, Wersall P & Cavallin-Stahl E 2003 A systematic overview of radiation therapy effects in skeletal metastases. *Acta Oncologica* **42** 620–633.
- Fanchiang JK, Lin JD, Huang MJ & Shih HN 1998 Papillary and follicular thyroid carcinomas with bone metastases: a series of 39 cases during a period of 18 years. *Changgheng Yi Xue Za Zhi* **21** 377–382.
- Fidler IJ 2002 Critical determinants of metastasis. *Seminars in Cancer Biology* **12** 89–96.
- Finlay IG, Mason MD & Shelley M 2005 Radioisotopes for the palliation of metastatic bone cancer: a systematic review. *Lancet Oncology* **6** 392–400.
- Fourney DR, Schomer DF, Nader R, Chlan-Fourney J, Suki D, Ahrar K, Rhines LD & Gokaslan ZL 2003 Percutaneous vertebroplasty and kyphoplasty for painful vertebral body fractures in cancer patients. *Journal of Neurosurgery* **98** 21–30.
- Frassica DA 2003 General principles of external beam radiation therapy for skeletal metastases. *Clinical Orthopaedics and Related Research* **415** (Supplement) S158–S164.
- Freundenberg LS, Antoch G, Jentzen W, Pink R, Knust J, Gorges R, Muller SP, Bockisch A, Debatin JF & Brandau W 2004 Value of (124)I-PET/CT in staging of patients with differentiated thyroid cancer. *European Radiology* **14** 2092–2098.
- Frey P, Townsend D, Flattet A, De Gautard R, Widgren S, Jeavons A, Christin A, Smith A, Long A & Donath A 1986 Tomographic imaging of the human thyroid using ¹²⁴I. *Journal of Clinical Endocrinology and Metabolism* **63** 918–927.
- Gaitanis IN, Hadjipavlou AG, Katonis PG, Tzermiadianos MN, Pasku DS & Patwardhan AG 2005 Balloon kyphoplasty for the treatment of pathological vertebral compressive fractures. *European Spine Journal* **14** 250–260.
- Galibert P, Deramond H, Rosat P & Le Gars D 1987 Note préliminaire sur le traitement des angiomes vertébraux par vertébroplastie acrylique percutanée. *Neuro-Chirurgie* **33** 166–168.
- de Geus-Oei LF, Oei HY, Hennemann G & Krenning EP 2002 Sensitivity of 123I whole-body scan and thyroglobulin in the detection of metastases or recurrent differentiated thyroid cancer. *European Journal of Nuclear Medicine and Molecular Imaging* **29** 768–774.
- Glinsky GV, Berezovska O & Glinskii AB 2005 Microarray analysis identifies a death-from-cancer signature predicting therapy failure in patients with multiple types of cancer. *Journal of Clinical Investigation* **115** 1503–1521.
- Gorgoulis V, Aninos D, Priftis C, Evagelopoulou C, Karameris A, Kanavaros P & Spandidos DA 1992 Expression of epidermal growth factor, transforming growth factor-alpha and epidermal growth factor receptor in thyroid tumors. *In Vivo* **6** 291–296.
- Green JR 2003 Antitumor effects of bisphosphonates. *Cancer* **97** 840–847.
- Greenblatt DY & Chen H 2007 Palliation of advanced thyroid malignancies. *Surgical Oncology* **16** 237–247.
- Haberkorn U, Beuter P, Kubler W, Eskerski H, Eisenhut M, Kinscherf R, Zitzmann S, Strauss LG, Dimitrakopoulou-Strauss A & Altmann A 2004 Iodide kinetics and dosimetry *in vivo* after transfer of the human sodium iodide symporter gene in rat thyroid carcinoma cells. *Journal of Nuclear Medicine* **45** 827–833.
- Halpin RJ, Bendok BR & Liu JC 2004 Minimally invasive treatments for spinal metastases: vertebroplasty, kyphoplasty, and radiofrequency ablation. *Journal of Supportive Oncology* **2** 339–351.
- Halpin RJ, Bendok BR, Sato KT, Liu JC, Patel JD & Rosen ST 2005 Combination treatment of vertebral metastases using image-guided percutaneous radiofrequency ablation and vertebroplasty: a case report. *Surgical Neurology* **63** 469–474.
- Hindie E, Zanotti-Fregonara P, Keller I, Duron F, Devaux JY, Calzada-Nocaudie M, Sarfati E, Moretti JL, Bouchard P & Toubert ME 2007 Bone metastases of differentiated thyroid cancer: impact of early 131I-based detection on outcome. *Endocrine-Related Cancer* **14** 799–807.
- Hoie J, Stenwig AE, Kullmann G & Lindegaard M 1988 Distant metastases in papillary thyroid cancer. A review of 91 patients. *Cancer* **61** 1–6.
- Hoskin PJ & Harmer C 1987 Chemotherapy for thyroid cancer. *Radiotherapy and Oncology* **10** 187–194.
- Ito S, Kato K, Ikeda M, Iwano S, Makino N, Tadokoro M, Abe S, Nakano S, Nishino M, Ishigaki T *et al.* 2007 Comparison of ¹⁸F-FDG PET and bone scintigraphy in detection of bone metastases of thyroid cancer. *Journal of Nuclear Medicine* **48** 889–895.
- Iwata M, Kasagi K, Misaki T, Matsumoto K, Iida Y, Ishimori T, Nakamoto Y, Higashi T, Saga T & Konishi J 2004 Comparison of whole-body 18F-FDG PET, 99mTc-MIBI SPET, and post-therapeutic ¹³¹I-Na scintigraphy in the detection of metastatic thyroid cancer. *European Journal of Nuclear Medicine and Molecular Imaging* **31** 491–498.
- Kebebew E, Weng J, Bauer J, Ranvier G, Clark OH, Duh QY, Shihru D, Bastian B & Griffin A 2007 The prevalence and prognostic value of BRAF mutation in thyroid cancer. *Annals of Surgery* **246** 466–470.

- Keller FS, Rosch J & Bird CB 1983 Percutaneous embolization of bony pelvic neoplasms with tissue adhesive. *Radiology* **147** 21–27.
- Kokufu I, Kim YH, Peng YF, Fukuda K, Yamamoto M, Yano T, Yamada K & Kitano H 1998 A case of osteolytic metastases from breast cancer effectively treated with pamidronate. *Gan to Kagaku Ryoho* **25** 1221–1224.
- Kokufu I, Taniguchi H, Kim YH, Fukuda K, Yamamoto M, Yano T, Yamada K & Kitano H 2000 Two bedridden patients with bone metastases from breast cancer effectively treated with pamidronate therapy. *Gan to Kagaku Ryoho* **27** 1751–1754.
- Kosuda S, Kaji T, Yokoyama H, Yokokawa T, Katayama M, Iriye T, Uematsu M & Kusano S 1996 Does bone SPECT actually have lower sensitivity for detecting vertebral metastasis than MRI? *Journal of Nuclear Medicine* **37** 975–978.
- van der Laan BF, Freeman JL & Asa SL 1995 Expression of growth factors and growth factor receptors in normal and tumorous human thyroid tissues. *Thyroid* **5** 67–73.
- Lam MG, de Klerk JM, van Rijk PP & Zonnenberg BA 2007 Bone seeking radiopharmaceuticals for palliation of pain in cancer patients with osseous metastases. *Anti-Cancer Agents in Medicinal Chemistry* **7** 381–397.
- Leger AF 1995 Métastases à distance des cancers thyroïdiens différenciés. Diagnostic par l'iode 131 (I131) et traitement. *Annales d'Endocrinologie* **56** 205–208.
- Lin JD, Huang MJ, Juang JH, Chao TC, Huang BY, Chen KW, Chen JY, Li KL, Chen JF & Ho YS 1999 Factors related to the survival of papillary and follicular thyroid carcinoma patients with distant metastases. *Thyroid* **9** 1227–1235.
- Liotta LA & Kohn EC 2001 The microenvironment of the tumour–host interface. *Nature* **411** 375–379.
- Lopez-Penabad L, Chiu AC, Hoff AO, Schultz P, Gaztambide S, Ordonez NG & Sherman SI 2003 Prognostic factors in patients with Hurthle cell neoplasms of the thyroid. *Cancer* **97** 1186–1194.
- Marcocci C, Pacini F, Elisei R, Schipani E, Ceccarelli C, Miccoli P, Arganini M & Pinchera A 1989 Clinical and biologic behavior of bone metastases from differentiated thyroid carcinoma. *Surgery* **106** 960–966.
- Massin JP, Savoie JC, Garnier H, Guiraudon G, Leger FA & Bacourt F 1984 Pulmonary metastases in differentiated thyroid carcinoma. Study of 58 cases with implications for the primary tumor treatment. *Cancer* **53** 982–992.
- Mazzaferri E 1993 Thyroid carcinoma: papillary and follicular. In *Endocrine Tumors*, pp 278–333. Eds E Mazzaferri & N Saaman. Cambridge, MA: Blackwell Scientific.
- McCormack KR 1966 Bone metastases from thyroid carcinoma. *Cancer* **19** 181–184.
- Mizukami Y, Michigishi T, Nonomura A, Hashimoto T, Terahata S, Noguchi M, Hisada K & Matsubara F 1990 Distant metastases in differentiated thyroid carcinomas: a clinical and pathologic study. *Human Pathology* **21** 283–290.
- Monchik JM, Donatini G, Iannuccilli J & Dupuy DE 2006 Radiofrequency ablation and percutaneous ethanol injection treatment for recurrent local and distant well-differentiated thyroid carcinoma. *Annals of Surgery* **244** 296–304.
- Monteil JP, Houlbert D, Saliba N, Despreaux G & Tran Ba Huy P 1985 Les métastases crâniennes et cervicales a caractère vasculaire des cancers thyroïdiens. A propos de 2 cas. *Annales d'Oto-Laryngologie* **102** 53–57.
- Morton AR, Cantrill JA, Pillai GV, McMahon A, Anderson DC & Howell A 1988 Sclerosis of lytic bone metastases after disodium aminohydroxypropylidene bisphosphonate (APD) in patients with breast carcinoma. *BMJ* **297** 772–773.
- Nagamine Y, Suzuki J, Katakura R, Yoshimoto T, Matoba N & Takaya K 1985 Skull metastasis of thyroid carcinoma. Study of 12 cases. *Journal of Neurosurgery* **63** 526–531.
- Niederle B, Roka R, Schemper M, Fritsch A, Weissel M & Ramach W 1986 Surgical treatment of distant metastases in differentiated thyroid cancer: indication and results. *Surgery* **100** 1088–1097.
- Nilsson S, Larsen RH, Fossa SD, Balteskard L, Borch KW, Westlin JE, Salberg G & Bruland OS 2005 First clinical experience with alpha-emitting radium-223 in the treatment of skeletal metastases. *Clinical Cancer Research* **11** 4451–4459.
- Onimus M, Papin P & Gangloff S 1996 Results of surgical treatment of spinal thoracic and lumbar metastases. *European Spine Journal* **5** 407–411.
- Owens LV, Xu L, Dent GA, Yang X, Sturge GC, Craven RJ & Cance WG 1996 Focal adhesion kinase as a marker of invasive potential in differentiated human thyroid cancer. *Annals of Surgical Oncology* **1** 100–105.
- Pacini F, Cetani F, Miccoli P, Mancusi F, Ceccarelli C, Lippi F, Martino E & Pinchera A 1994 Outcome of 309 patients with metastatic differentiated thyroid carcinoma treated with radioiodine. *World Journal of Surgery* **18** 600–604.
- Paget S 1989 The distribution of secondary growths in cancer of the breast, 1889. *Cancer Metastasis Reviews* **8** 98–101.
- Pandit-Taskar N, Batraki M & Divgi CR 2004 Radiopharmaceutical therapy for palliation of bone pain from osseous metastases. *Journal of Nuclear Medicine* **45** 1358–1365.
- Park JW, Zarnegar R, Kanauchi H, Wong MG, Hyun WC, Ginzinger DG, Lobo M, Cotter P, Duh QY & Clark OH 2005 Troglitazone, the peroxisome proliferator-activated receptor-gamma agonist, induces antiproliferation and redifferentiation in human thyroid cancer cell lines. *Thyroid* **15** 222–231.
- Pécheur I, Peyruchaud O, Serre CM, Guglielmi J, Volland C, Bourre F, Margue C, Cohen-Solal M, Buffet A, Kieffer N *et al.* 2002 Integrin alpha(v)beta3 expression confers on tumor cells a greater propensity to metastasize to bone. *FASEB Journal* **16** 1266–1268.
- Petric T, Widjaja A, Musholt TJ, Hofmann M, Brunkhorst T, Ehrenheim C, Oetting G & Knapp WH 2001 Outcome after radioiodine therapy in 107 patients with differentiated

- thyroid carcinoma and initial bone metastases: side-effects and influence of age. *European Journal of Nuclear Medicine* **28** 203–208.
- Pittas AG, Adler M, Fazzari M, Tickoo S, Rosai J, Larson SM & Robbins RJ 2000 Bone metastases from thyroid carcinoma: clinical characteristics and prognostic variables in one hundred forty-six patients. *Thyroid* **10** 261–268.
- Porter AT, McEwan AJ, Powe JE, Reid R, McGowan DG, Lukka H, Sathyanarayana JR, Yakemchuk VN, Thomas GM, Erlich LE et al. 1993 Results of a randomized phase-III trial to evaluate the efficacy of strontium-89 adjuvant to local field external beam irradiation in the management of endocrine resistant metastatic prostate cancer. *International Journal of Radiation Oncology, Biology, Physics* **25** 805–813.
- Proye CA, Dromer DH, Carnaille BM, Gontier AJ, Goropoulos A, Carpentier P, Lefebvre J, Decoulx M, Wemeau JL, Fossati P et al. 1992 Is it still worthwhile to treat bone metastases from differentiated thyroid carcinoma with radioactive iodine? *World Journal of Surgery* **16** 640–645.
- Reinbold WD, Wannenmacher M, Hodapp N & Adler CP 1989 Osteodensitometry of vertebral metastases after radiotherapy using quantitative computed tomography. *Skeletal Radiology* **18** 517–521.
- Robbins RJ, Wan Q, Grewal RK, Reibke R, Gonen M, Strauss HW, Tuttle RM, Drucker W & Larson SM 2006 Real-time prognosis for metastatic thyroid carcinoma based on 2-[18F]fluoro-2-deoxy-D-glucose-positron emission tomography scanning. *Journal of Clinical Endocrinology and Metabolism* **91** 498–505.
- Rodolico V, Cabibi D, Pizzolanti G, Richiusa P, Gebbia N, Martorana A, Russo A, Amato MC, Galluzzo A & Giordano C 2007 BRAF V600E mutation and p27 kip1 expression in papillary carcinomas of the thyroid \leq 1 cm and their paired lymph node metastases. *Cancer* **110** 1218–1226.
- Roodman GD 2004 Mechanisms of bone metastasis. *New England Journal of Medicine* **350** 1655–1664.
- Rosenthal DI 1997 Radiologic diagnosis of bone metastases. *Cancer* **80** 1595–1607.
- Ruegger JJ, Hay ID, Bergstralh EJ, Ryan JJ, Offord KP & Gorman CA 1988 Distant metastases in differentiated thyroid carcinoma: a multivariate analysis of prognostic variables. *Journal of Clinical Endocrinology and Metabolism* **67** 501–508.
- Ryan PJ & Fogelman I 1995 The bone scan: where are we now? *Seminars in Nuclear Medicine* **25** 76–91.
- Rybak LD & Rosenthal DI 2001 Radiological imaging for the diagnosis of bone metastases. *Quarterly Journal of Nuclear Medicine* **45** 53–64.
- Samaan NA, Schultz PN, Hickey RC, Goepfert H, Haynie TP, Johnston DA & Ordonez NG 1992 The results of various modalities of treatment of well differentiated thyroid carcinomas: a retrospective review of 1599 patients. *Journal of Clinical Endocrinology and Metabolism* **75** 714–720.
- Santini F, Bottici V, Elisei R, Montanelli L, Mazzeo S, Basolo F, Pinchera A & Pacini F 2002 Cytotoxic effects of carboplatinum and epirubicin in the setting of an elevated serum thyrotropin for advanced poorly differentiated thyroid cancer. *Journal of Clinical Endocrinology and Metabolism* **87** 4160–4165.
- Schirmmeister H, Buck A, Guhlmann A & Reske SN 2001 Anatomical distribution and sclerotic activity of bone metastases from thyroid cancer assessed with F-18 sodium fluoride positron emission tomography. *Thyroid* **11** 677–683.
- Schlumberger MJ 1998 Papillary and follicular thyroid carcinoma. *New England Journal of Medicine* **338** 297–306.
- Schlumberger M, Tubiana M, De Vathaire F, Hill C, Gardet P, Travagli JP, Fragu P, Lumbroso J, Caillou B & Parmentier C 1986 Long-term results of treatment of 283 patients with lung and bone metastases from differentiated thyroid carcinoma. *Journal of Clinical Endocrinology and Metabolism* **63** 960–967.
- Schlumberger M, Challeton C, De Vathaire F, Travagli JP, Gardet P, Lumbroso JD, Francese C, Fontaine F, Ricard M & Parmentier C 1996 Radioactive iodine treatment and external radiotherapy for lung and bone metastases from thyroid carcinoma. *Journal of Nuclear Medicine* **37** 598–605.
- Schmidt GP, Schoenberg SO, Schmid R, Stahl R, Tiling R, Becker CR, Reiser MF & Baur-Melnyk A 2006 Screening for bone metastases: whole-body MRI using a 32-channel system versus dual-modality PET-CT. *European Radiology* **174** 939–949.
- Schoenberger J, Grimm D, Kossmehl P, Infanger M, Kurth E & Eilles C 2004 Effects of PTK787/ZK222584, a tyrosine kinase inhibitor, on the growth of a poorly differentiated thyroid carcinoma: an animal study. *Endocrinology* **145** 1031–1038.
- Selvaggi G & Scagliotti GV 2005 Management of bone metastases in cancer: a review. *Critical Reviews in Oncology/Hematology* **56** 365–378.
- Sgouros G, Kolbert KS, Sheikh A, Pentlow KS, Mun EF, Barth A, Robbins RJ & Larson SM 2004 Patient-specific dosimetry for 131I thyroid cancer therapy using ^{124}I PET and 3-dimensional-internal dosimetry (3D-ID) software. *Journal of Nuclear Medicine* **45** 1366–1372.
- Shimaoka K, Schoenfeld DA, DeWys WD, Crech RH & DeConti R 1985 A randomized trial of doxorubicin versus doxorubicin plus cisplatin in patients with advanced thyroid carcinoma. *Cancer* **56** 2155–2160.
- Simpson WJ 1990 Radioiodine and radiotherapy in the management of thyroid cancers. *Otolaryngologic Clinics of North America* **23** 509–521.
- Simpson WJ, Panzarella T, Carruthers JS, Gospodarowicz MK & Sutcliffe SB 1988 Papillary and follicular thyroid cancer: impact of treatment in 1578 patients. *International Journal of Radiation Oncology, Biology, Physics* **14** 1063–1075.

- Soh EY, Eigelberger MS, Kim KJ, Wong MG, Young DM, Clark OH & Duh QY 2000 Neutralizing vascular endothelial growth factor activity inhibits thyroid cancer growth *in vivo*. *Surgery* **128** 1059–1065.
- Stafford SE, Gralow JR, Schubert EK, Rinn KJ, Dunnwald LK, Livingston RB & Mankoff DA 2002 Use of serial FDG PET to measure the response of bone-dominant breast cancer to therapy. *Academic Radiology* **9** 913–921.
- Storto G, Klain M, Paone G, Liuzzi R, Molino L, Marinelli A, Soricelli A, Pace L & Salvatore M 2006 Combined therapy of Sr-89 and zoledronic acid in patients with painful bone metastases. *Bone* **39** 35–41.
- Tanaka M, Fushimi H, Fuji T & Ford JM 1996 Sclerosis of lytic metastatic bone lesions during treatment with pamidronate in a patient with adenocarcinoma of unknown primary site. *European Spine Journal* **5** 198–200.
- Tickoo SK, Pittas AG, Adler M, Fazzari M, Larson SM, Robbins RJ & Rosai J 2000 Bone metastases from thyroid carcinoma: a histopathologic study with clinical correlates. *Archives of Pathology & Laboratory Medicine* **124** 1440–1447.
- Tokuhashi Y, Matsuzaki H, Toriyama S, Kawano H & Ohsaka S 1990 Scoring system for the preoperative evaluation of metastatic spine tumor prognosis. *Spine* **15** 1110–1113.
- Van Tol KM, Hew JM, Jager PL, Vermey A, Dullaart RP & Links TP 2000 Embolization in combination with radioiodine therapy for bone metastases from differentiated thyroid carcinoma. *Clinical Endocrinology* **52** 653–659.
- Tomita K, Kawahara N, Kobayashi T, Yoshida A, Murakami H & Akamaru T 2001 Surgical strategy for spinal metastases. *Spine* **26** 298–306.
- Traxler P, Allegrini PR, Brandt R, Brueggen J, Cozens R, Fabbro D, Grosios K, Lane HA, McSheehy P, Mestan J *et al.* 2004 AEE788: a dual family epidermal growth factor receptor/ErbB2 and vascular endothelial growth factor receptor tyrosine kinase inhibitor with antitumor and antiangiogenic activity. *Cancer Research* **64** 4931–4941.
- Tsang RW, Brierley JD, Simpson WJ, Panzarella T, Gospodarowicz MK & Sutcliffe SB 1998 The effects of surgery, radioiodine, and external radiation therapy on the clinical outcome of patients with differentiated thyroid carcinoma. *Cancer* **82** 375–388.
- Tu SM, Millikan RE, Mengistu B, Delpassand ES, Amato RJ, Pagliaro LC, Daliani D, Papandreou CN, Smith TL, Kim J *et al.* 2001 Bone-targeted therapy for advanced androgen-independent carcinoma of the prostate: a randomised phase II trial. *Lancet* **357** 336–341.
- Tubiana M, Haddad E, Schlumberger M, Hill C, Rougier P & Sarrazin D 1985 External radiotherapy in thyroid cancers. *Cancer* **55** 2062–2071.
- Vasko VV & Saji M 2007 Molecular mechanisms involved in differentiated thyroid cancer invasion and metastasis. *Current Opinion in Oncology* **19** 11–17.
- Vitale G, Fonderico F, Martignetti A, Caraglia M, Ciccarelli A, Nuzzo V, Abbruzzese A & Lupoli G 2001 Pamidronate improves the quality of life and induces clinical remission of bone metastases in patients with thyroid cancer. *British Journal of Cancer* **84** 1586–1590.
- Wang W, Larson SM, Fazzari M, Tickoo SK, Kolbert K, Sgouros G, Yeung H, Macapinlac H, Rosai J & Robbins RJ 2000 Prognostic value of [18F]fluorodeoxyglucose positron emission tomographic scanning in patients with thyroid cancer. *Journal of Clinical Endocrinology and Metabolism* **85** 1107–1113.
- Wexler JA & Sharretts J 2007 Thyroid and bone. *Endocrinology and Metabolism Clinics of North America* **36** 673–705.
- Wittrant Y, Theoleyre S, Chipoy C, Padrines M, Blanchard F, Heymann D & Redini F 2004 RANKL/RANK/OPG: new therapeutic targets in bone tumours and associated osteolysis. *Biochimica et Biophysica Acta* **1704** 49–57.
- Woodward JK, Coleman RE & Holen I 2005 Preclinical evidence for the effect of bisphosphonates and cytotoxic drugs on tumor cell invasion. *Anticancer Drugs* **16** 11–19.
- Yang DM, Chi CW, Chang HM, Wu LH, Lee TK, Lin JD, Chen ST & Lee CH 2004 Effects of clodronate on cancer growth and Ca²⁺ signaling of human thyroid carcinoma cell lines. *Anticancer Research* **24** 1617–1623.
- Ye C, Feng C, Wang S, Liu X, Lin Y & Li M 2002 Antiangiogenic and antitumor effects of endostatin on follicular thyroid carcinoma. *Endocrinology* **143** 3522–3528.
- Zarnegar R, Brunaud L, Kanauchi H, Wong M, Fung M, Ginzinger D, Duh QY & Clark OH 2002 Increasing the effectiveness of radioactive iodine therapy in the treatment of thyroid cancer using Trichostatin A, a histone deacetylase inhibitor. *Surgery* **132** 984–990.
- Zettinig G, Fueger BJ, Passler C, Kaserer K, Pirich C, Dudczak R & Niederle B 2002 Long-term follow-up of patients with bone metastases from differentiated thyroid carcinoma – surgery or conventional therapy? *Clinical Endocrinology* **56** 377–382.