
Bone Reactions to Anorganic Bovine Bone (Bio-Oss) Used in Sinus Augmentation Procedures: A Histologic Long-Term Report of 20 Cases in Humans

Maurizio Piattelli, MD, DDS*/Gian Antonio Favero, MD, DDS**/
Antonio Scarano, DDS***/Giovanna Orsini, DDS***/Adriano Piattelli, MD, DDS****

Many materials are used for sinus augmentation procedures. Anorganic bovine bone (Bio-Oss) has been reported to be osteoconductive, and no inflammatory responses have been observed with the use of this biomaterial. One of the main questions pertaining to Bio-Oss concerns its biodegradation and substitution by host bone. Some investigators have observed rapid replacement by host bone, while other researchers observed slow resorptive activity or no resorption at all. The aim of the present study was to conduct a long-term histologic analysis of retrieved specimens in humans where Bio-Oss was used in sinus augmentation procedures. Specimens were retrieved from 20 patients after varying periods from 6 months to 4 years and were processed to obtain thin ground sections. Bio-Oss particles were surrounded for the most part by mature, compact bone. In some Haversian canals it was possible to observe small capillaries, mesenchymal cells, and osteoblasts in conjunction with new bone. No gaps were present at the interface between the Bio-Oss particles and newly formed bone. In specimens retrieved after 18 months and 4 years, it was also possible to observe the presence of osteoclasts in the process of resorbing the Bio-Oss particles and neighboring newly formed bone. Bio-Oss appears to be highly biocompatible and osteoconductive, is slowly resorbed in humans, and can be used with success as a bone substitute in maxillary sinus augmentation procedures. (INT J ORAL MAXILLOFAC IMPLANTS 1999;14:835-840)

Key words: anorganic bovine bone, biomaterials, sinus augmentation

Rehabilitation of the edentulous posterior maxilla with dental implants is often very difficult, because of insufficient bone volume produced by pneumatization of the maxillary sinus and by crestal bone resorption.¹⁻³ Three main surgical

grafting procedures have been proposed: (1) placement of bone grafts as inlays on the sinus floor, (2) placement of bone grafts as onlays to augment the alveolar ridges, and (3) placement of bone grafts as inlays in the floor of the mouth and the maxillary sinus following a Le Fort I osteotomy.⁴ With the sinus floor augmentation procedure, as first described by Boyne and James in 1980,⁵ implants can be placed into sites that were previously deemed unsuitable because of inadequate bone height. Numerous clinical studies have reported excellent prognosis for dental implants placed in augmented sites.⁶ Sinus floor augmentation can provide the necessary bone mass to place and stabilize implants that is essential for the initial steps leading toward osseointegration.⁷

It is not clear as to which bone grafting material is most suitable for this technique. Many materials

*Researcher, Dental School, University of Chieti, Chieti, Italy.

**Professor, Dental School, University of Padua, Padua, Italy.

***Research Fellow, Dental School, University of Chieti, Chieti, Italy.

****Professor of Oral Medicine and Pathology, Dental School, University of Chieti, Chieti, Italy; and Honorary Senior Lecturer, Eastman Dental Institute for Oral Health Care Sciences, London, United Kingdom.

Reprint requests: Prof A. Piattelli, Via F. Sciucchi 63, 66100 Chieti, Italy. Fax: 39-0871-3554076. E-mail: apiattelli@unich.it

have been proposed for sinus augmentation: autogenous bone grafts,⁸⁻¹⁰ allografts,^{11,12} alloplast,¹¹⁻¹⁴ and xenografts.^{11,15,16} Cancellous autogenous bone is the ideal graft material, but its use is restricted by difficulties inherent in the harvesting procedure; consequently, a variety of bone substitutes or xenografts have been tested.¹⁷⁻¹⁹

It has been said that an ideal bone substitute should have the following characteristics: it should be biocompatible and be replaced by newly formed bone, and it should have osteoinductive or osteoconductive properties.²⁰ Implant survival in maxillary sinuses augmented with autogenous bone, hydroxyapatite/autogenous bone, hydroxyapatite/demineralized freeze-dried bone, and hydroxyapatite alone has been reported as stable after 6 months, and is between 87% and 98% after 18 months.²¹ Osteoconduction refers to the process whereby the grafting material provides an architectural matrix or scaffold onto which bone may form.²⁰

Bio-Oss (Geistlich, Wolhusen, Switzerland) is a deproteinized sterilized bovine bone with 75% to 80% porosity and with a crystal size of approximately 10 nm¹⁷ in the form of cortical and cancellous granules and cortical and cancellous blocks.^{20,22} Bio-Oss has a size of inner macropores that is similar to natural cancellous bone.¹⁹ No local B-cell or T-cell inflammatory responses have been reported with the use of anorganic bone.^{1,22,23} Bio-Oss seems to be more effective than hydroxyapatite in being replaced by the host bone when used in alveolar ridge restoration,⁵ and it appears to undergo physiologic remodeling with incorporation into the host bone.^{19,23} Moreover, Bio-Oss has been shown to be highly biocompatible with oral hard tissues in animals and humans and to fulfill the criteria of an osteoconductive material.^{19,24,25} Different opinions have been expressed about the degradation of Bio-Oss; in some cases it appeared to be rapidly replaced by the host bone,²⁶ while other investigators observed few resorption lacunae, indicating slow resorptive activity^{19,20} or no resorption at all.¹⁶

Histologic data regarding the outcome of treatment involving sinus floor augmentation procedures in humans are scarce.¹⁶ Even when the specimens were obtained by different clinical centers, they were retrieved from patients for whom the surgical procedure was successful. The aim of the present study was to conduct a long-term histologic analysis of the bone response to and resorption of Bio-Oss used in sinus augmentation procedures.

Materials and Methods

Twenty patients with severely atrophic resorbed maxillae underwent sinus augmentation with Bio-Oss. The sinus procedures were all carried out as described by Boyne and James in 1980.⁵ In all patients, the sinus augmentation procedure was considered to be successful, and the placement of implants of at least 12 mm in length was done in 1 stage. A total of 20 biopsy specimens was retrieved at time intervals ranging from 6 months to 4 years. Eight biopsy specimens were retrieved after 6 months, 6 after 9 months, and 3 after 18 months; 3 more biopsies were retrieved after 4 years. A small biopsy of the regenerated tissues was obtained using a 4-mm trephine (Straumann, Waldenburg, Switzerland) under generous saline irrigation. The cores were obtained to a mean depth of 10 mm. The specimens were retrieved, washed in saline solution, and immediately fixed in 4% para-formaldehyde and 0.1% glutaraldehyde in 0.15 mol/L cacodylate buffer at 4°C and pH 7.4 to be processed for histology. The specimens were processed to obtain thin ground sections with the Precise 1 Automated System (Assing, Rome, Italy).²⁷ The specimens were dehydrated in an ascending series of alcohol rinses and embedded in a glycolmethacrylate resin (Technovit 7200 VLC, Kulzer, Wehrheim, Germany). After polymerization, the specimens were sectioned with a high-precision diamond disc at about 150 µm and ground to about 30 µm. The slides were stained with acid fuchsin, toluidine blue, and silver nitrate and observed in normal transmitted light under a Leitz Laborlux microscope (Leitz, Wetzlar, Germany). Three slides were obtained for each specimen. The histomorphometry was done under a Laborlux-S light microscope (Leitz) using an Intel Pentium II 300 MMX, a video-acquired schedules Matrox, a videocamera, and KS 100 Software (Zeiss, Hallbergmoos, Germany). The images acquired were analyzed using the described software. The histochemical analysis of acid and alkaline phosphatases was carried out according to a previously described protocol.²⁸

Results

Light microscopy showed the same findings for each time point for all 3 sections of all specimens, and there was no range in variability.

Specimens at 6 Months. Bio-Oss particles were easily distinguished from the newly formed bone. They tended to be less stained because of the low collagen content. Most of the particles were sur-

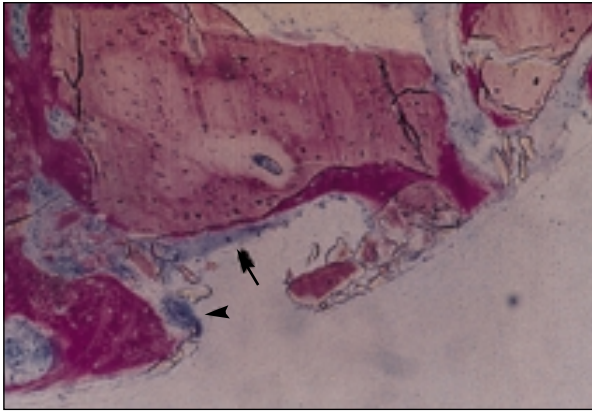


Fig 1 Specimen at 6 months. Osteoblasts (*arrow*) are depositing newly formed bone directly on the biomaterials surface. No gaps are present at the bone-biomaterial interface. An osteoclast (*arrowhead*) is in close contact with the newly regenerated bone and the Bio-Oss particles (original magnification $\times 100$; acid fuchsin-toluidine blue).

rounded by newly formed bone. This bone was mature and compact and presented a structure with well-organized osteons. In a few areas, marrow spaces, in which it was possible to find small capillaries, were present at the interface with the particles. In some fields osteoblasts were observed in the process of apposing bone directly on the particle surface (Fig 1). In most of the microscopic fields the particles were united by newly formed bone (Fig 2). No gaps were present at the bone-particle interface, and the bone was always in close contact with the particles. The histochemical staining (von Kossa) showed that most of the newly formed bone was highly mineralized. In only a few areas of the bone-biomaterial interface was it possible to observe an osteoid material (as yet not mineralized). No inflammatory cells were present around the particles or at the interface. It was possible to observe osteoclasts that were in close contact with Bio-Oss particles and neighboring newly formed bone (Fig 2). There were no alkaline and acid phosphatase-positive cells, perhaps as a result of fixation of the specimens and also because it was not possible to keep them at $+4^{\circ}\text{C}$ during processing. The histomorphometric analysis showed that about 40% of the specimens were composed of marrow spaces, about 30% by newly formed bone, and about 30% by Bio-Oss particles.

Specimens at 9 Months. The microscopic features were similar to those observed at 6 months. At higher magnification, it was possible to observe that the most peripheral osteocyte lacunae of the particles had been filled by cells with the same morphology of osteocytes, while the central lacunae appeared to still be empty (Fig 3). In some

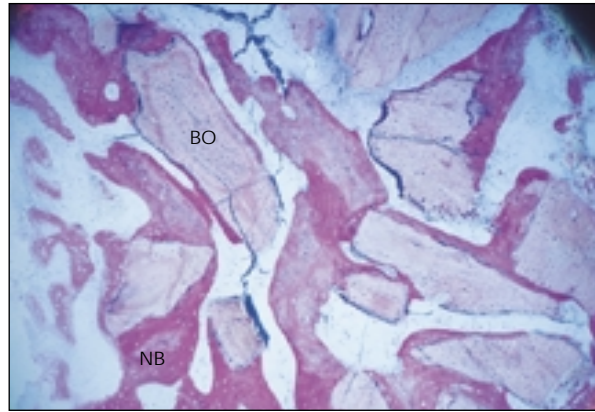


Fig 2 Specimen at 6 months. Most of the Bio-Oss (BO) particles were surrounded by newly formed bone (NB) (original magnification $\times 50$; acid fuchsin-toluidine blue).

Haversian canals, it was possible to observe small capillaries, mesenchymal cells, and osteoblasts forming new bone (Figs 3 and 4). Newly formed bone was seen around the particles. No inflammatory cells were observed.

Specimens at 18 Months. All particles were easily recognized because of their lower staining affinity for dyes. Mineralization of the newly formed bone appeared to be increased with the histochemical staining for calcium salts (von Kossa). No inflammatory infiltrate was present at the interface or around the particles. No gap was present at the interface. All Haversian canals had been filled by newly formed bone, and they had assumed the appearance of an osteocyte lacuna (Fig 5).

Specimens at 4 Years. The Bio-Oss particles were still easily recognizable (Fig 6). The histochemical staining (von Kossa) showed that mineralization of the newly formed bone was similar to that observed at 18 months (Fig 6). Osteoclasts in the process of resorbing Bio-Oss particles and neighboring newly formed bone were present (Fig 7). Multinucleated giant cells were seen around Bio-Oss particles (Fig 8).

Discussion

In recent years, several reports concerning Bio-Oss in different clinical conditions have been reported in the literature. New bone formation has been observed over exposed implant surfaces using Bio-Oss in association with membranes²⁹ and significantly more new bone in Bio-Oss-treated defects than in those treated with bioglass.³⁰ Moreover, the use of Bio-Oss alone resulted in nearly complete

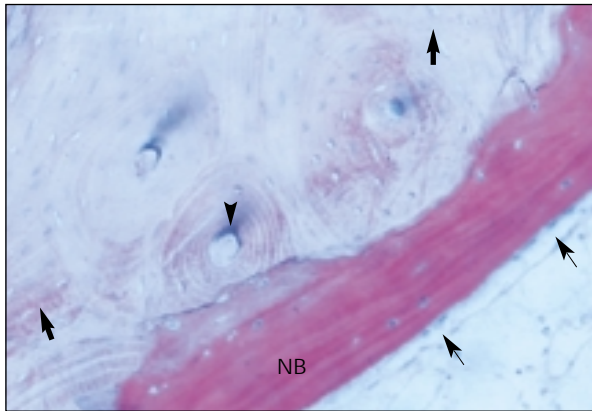


Fig 3 Specimen at 9 months. No gaps were present between Bio-Oss and newly formed bone (NB). Cells were present inside the osteocyte lacunae (*large arrows*). Osteoblasts (*small arrows*) were producing bone directly on the Bio-Oss. It was possible to observe colonization by cells and capillaries in the Haversian canals (*arrowhead*) (original magnification $\times 100$; acid fuchsin-toluidine blue).

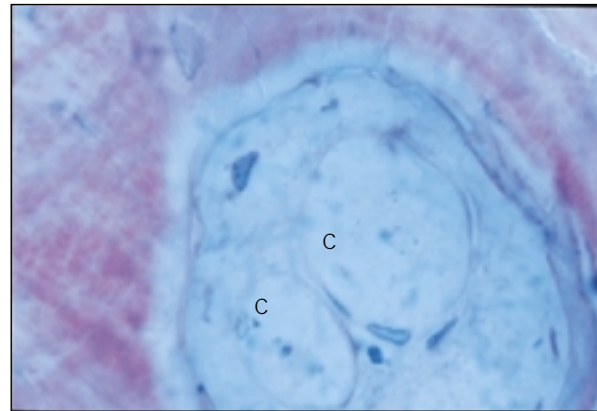


Fig 4 Specimen at 9 months. At higher magnification it is possible to see the presence of capillaries (C) and fibroblasts inside the Haversian canals (original magnification $\times 1200$; acid fuchsin-toluidine blue).

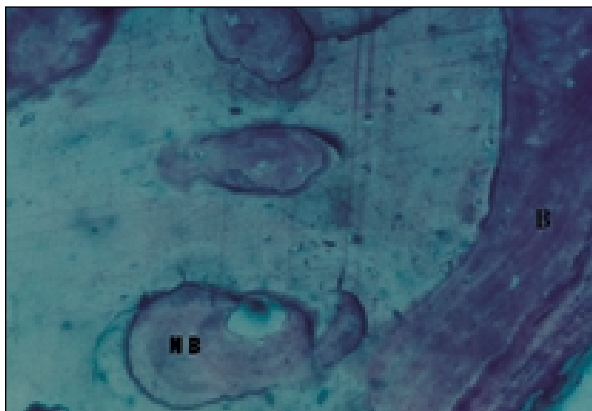


Fig 5 Specimen at 18 months. The Bio-Oss particles are lined by bone (B). Newly formed bone (NB) is found inside the Haversian canals. Almost all osteocyte lacunae are colonized by cells (original magnification $\times 100$; acid fuchsin-toluidine blue).




Fig 6 Specimen at 4 years. The bone (NB) surrounding the Bio-Oss particles is highly mineralized (original magnification $\times 100$; silver nitrate).

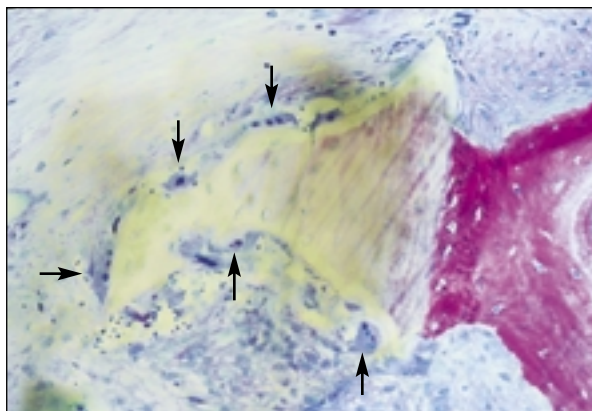


Fig 7 Specimen at 4 years. It is possible to observe osteoclasts (*arrows*) in close contact with Bio-Oss particles and neighboring newly formed bone. Where the osteoclasts are present, resorption lacunae are observed (original magnification $\times 100$; acid fuchsin-toluidine blue).

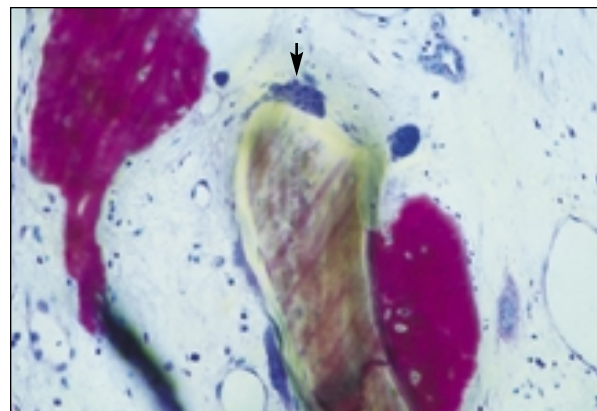


Fig 8 Specimen at 4 years. A multinucleated cell (*arrow*) is in close contact with a Bio-Oss particle (original magnification $\times 200$; acid fuchsin-toluidine blue).

bone closure of the osteotomy window in sinus augmentation,¹ the implants placed in Bio-Oss required a significantly higher pull-out force than the control implants,⁶ and maxillary sinus augmentation using Bio-Oss resulted in a better bond between implant and bone in sheep.³ In the present specimens, the Bio-Oss particles were surrounded, in all cases, by an abundant quantity of newly formed lamellar bone. In addition, apposition of osteoid by a seam of active osteoblasts, distinguished by an elongated shape and high staining affinity for toluidine blue and for osteoid matrix, was often found directly on the graft particle surface.¹⁶ Bio-Oss seemed to undergo a slow resorption process. These results were also seen in a dog study where, after 5 months of observation, most of the grafting material was still in place.¹⁸ The authors asserted that the bone graft appeared to have acted as a scaffold, along which new bone formed.

In another study, Klinge et al³² showed that Bio-Oss, in particular, seemed to promote more early bone formation than other substitutes. The Bio-Oss particles appeared to have acted as a resorbable osteoconductive material in the augmented sinus, since newly formed lamellar bone was in close contact with the graft particles.¹⁷ In all specimens, it was possible to observe close contact between Bio-Oss particles and newly formed bone, with no gaps at the interface; similar histologic results have been reported by Storgard-Jensen et al,²⁰ Hurzeler et al,¹⁷ and Valentini et al.¹⁶ Positive osteoconductive properties of Bio-Oss may be documented by close contact between the material and newly formed bone.^{16,31} The interconnected porous system of Bio-Oss appears to have a size and structure conducive to vessel ingrowth.^{20,22} In these specimens at 6 months, small capillaries,¹⁶ mesenchymal cells, and osteoblasts inside some Haversian canals were seen, while at 18 months all the Haversian canals had been filled by newly regenerated bone.

Based on these findings, it would seem possible to confirm the previously reported data that Bio-Oss particles can be resorbed by osteoclasts.^{20,31,32} On the contrary, other researchers reported that no overt signs of resorption of the graft particles were visible.^{16,30} Clergeau et al²² reported some anorganic bovine bone particles remaining at 36 weeks, while Wallace et al³³ observed a complete lack of anorganic bovine matrix after a 20-month period. These data contrast with the observations of Pinholt et al,²⁴ who reported a very slow substitution of anorganic bone in rats; Diès et al,³⁴ who found only limited resorption of Bio-Oss particles at 9 months; and Avera et al,¹⁵ who showed, in

humans, Bio-Oss particles present in the graft area at 44 months. In the present human specimens the graft particles were present after 4 years. In experimental alveolar ridge augmentation in rats using Bio-Oss, Pinholt et al²⁴ found the presence of giant cells and an inflammatory reaction around the material.

Conclusion

The findings of the present study support the use of Bio-Oss as a bone substitute in maxillary sinus augmentation procedures. When used as a grafting material in sinus floor augmentation, Bio-Oss may lead to appropriate osseointegration of a dental implant and can be used to create adequate bone volume before implant placement. Bio-Oss undergoes very slow resorption; in these specimens, the Bio-Oss particles were present 4 years after their placement.

Acknowledgments

This work was partially supported by the National Research Council (C.N.R.), Rome, Italy: Finalized Project "Materials Tailored for Advanced Technologies" (PF MSTA II); and by the Ministry of the University, Research, Science and Technology (M.U.R.S.T.), Rome, Italy.

References

1. McAllister BS, Margolin MD, Cogan AG, Taylor M, Wollins J. Residual lateral wall defects following sinus grafting with recombinant human osteogenic protein-1 or Bio-Oss in the chimpanzee. *Int J Periodontics Restorative Dent* 1998;18:227-239.
2. Fugazzotto PA, Vlassis J. Long-term success of sinus augmentation using various surgical approaches and grafting materials. *Int J Oral Maxillofac Implants* 1998;13:52-58.
3. Haas R, Donath K, Fodiger M, Watzek G. Bovine hydroxyapatite for maxillary sinus grafting: Comparative histomorphometric findings in sheep. *Clin Oral Implants Res* 1998;9:107-116.
4. Lorenzetti M, Mozzati M, Campanino PP, Valente G. Bone augmentation of the inferior floor of the maxillary sinus with autogenous bone or composite bone grafts: A histologic-histomorphometric preliminary report. *Int J Oral Maxillofac Implants* 1998;13:69-76.
5. Boyne PJ, James RA. Grafting of the maxillary sinus floor with autogenous marrow and bone. *J Oral Surg* 1980;38:613-616.
6. Haas R, Mailath G, Dortbudak O, Watzek G. Bovine hydroxyapatite for maxillary sinus augmentation: Analysis of interfacial bond strength of dental implants using pull-out tests. *Clin Oral Implants Res* 1998;9:117-122.
7. Smiler PG, Holmes RE. Sinus lift procedure using porous hydroxyapatite: A preliminary clinical report. *J Oral Implantol* 1987;13:239-244.
8. Kent JN, Block MS. Simultaneous maxillary sinus floor bone grafting and placement of hydroxylapatite-coated implants. *J Oral Maxillofac Surg* 1989;7:238-242.

9. Jensen J, Simonsen EK, Sindet-Pedersen S. Reconstruction of the severely resorbed maxilla with bone grafting and osseointegrated implants: A preliminary report. *J Oral Maxillofac Surg* 1990;48:27-32.
10. Raghoobar GM, Brouwer TJ, Reintsema H, Van Oort RP. Augmentation of the maxillary sinus floor with autogenous bone for the placement of endosseous implants: A preliminary report. *J Oral Maxillofac Surg* 1993;51:1198-1203.
11. Smiler DG, Johnson PW, Lozada JL, Misch C, Rosenlicht JL, Tatum JRH, Wagner JR. Sinus lift grafts and endosseous implants: Treatment of the atrophic posterior maxilla. *Dent Clin North Am* 1992;36:151-186.
12. Small SA, Zinner ID, Panno FV, Shapiro HJ, Stein JL. Augmenting the maxillary sinus for implants: Report of 27 patients. *Int J Oral Maxillofac Implants* 1993;8:523-528.
13. Tidwell JK, Blijorp PA, Stoeltinga PJW, Brouns JB, Hinderks F. Composite grafting of the maxillary sinus for placement of endosteal implants: A preliminary report of 48 patients. *Int J Oral Maxillofac Implants* 1992;7:204-209.
14. Moy PK, Lundgren S, Holmes RE. Maxillary sinus augmentation: Histomorphometric analysis of graft materials for maxillary sinus floor augmentation. *J Oral Maxillofac Surg* 1993;51:857-862.
15. Avera SP, Stampely WA, McAllister BS. Histologic and clinical observations of resorbable and non-resorbable barrier membranes used in maxillary sinus graft containment. *Int J Oral Maxillofac Implants* 1997;12:88-94.
16. Valentini P, Abensur D, Densari D, Graziani JN, Hammerle C. Histological evaluation of Bio-Oss in a 2-stage sinus floor elevation and implantation procedure. A human case report. *Clin Oral Implants Res* 1998;9:59-64.
17. Hurzeler MB, Quinones CR, Kirsch A, Gloker C, Schubach P, Strub JR, Caffesse RG. Maxillary sinus augmentation using different grafting materials and dental implants in monkeys. Part I. Evaluation of anorganic bovine-derived bone matrix. *Clin Oral Implants Res* 1997;8:476-486.
18. Wetzel A, Stich H, Caffesse RG. Bone apposition onto oral implants in the sinus area filled with different grafting materials. *Clin Oral Implants Res* 1995;6:155-163.
19. Berglundh T, Lindhe J. Healing around implants placed in bone defects treated with Bio-Oss: An experimental study in the dog. *Clin Oral Implants Res* 1997;8:117-124.
20. Storgard-Jensen S, Aaboe M, Pinholt ES, Hjørting-Hansen E, Melsen F, Ruyter IE. Tissue reaction and material characteristics of four bone substitutes. *Int J Oral Maxillofac Implants* 1996;11:55-66.
21. Tong DC, Rioux K, Drangsholt M, Beirne OR. A review of survival rates for implants placed in grafted maxillary sinuses using meta-analysis. *Int J Oral Maxillofac Implants* 1998;13:175-182.
22. Clergeau LP, Danan M, Clergeau-Guerithault S, Brion M. Healing response to anorganic bone implantation in periodontal bony defects in dogs. Part I. Bone regeneration. A micrographic study. *J Periodontol* 1996;67:1140-1149.
23. Hislop WS, Finlay PM, Moos KE. A preliminary study into the uses of anorganic bone in oral and maxillofacial surgery. *Br J Oral Maxillofac Surg* 1993;31:149-153.
24. Pinholt EM, Bang G, Haanaes HR. Alveolar ridge augmentation in rats by Bio-Oss. *Scand J Dent Res* 1991;99:1-7.
25. Denissen HW, De Groot K, Makkes PC, Van den Hoof A, Klopper PJ. Tissue response to dense apatite implants in rats. *J Biomed Mater Res* 1980;14:713-721.
26. Wheeler SL, Holmes RE, Calhoun CJ. Six-year clinical and histologic study of sinus-lift grafts. *Int J Oral Maxillofac Implants* 1996;11:26-34.
27. Piattelli A, Scarano A, Quaranta M. High-precision, cost-effective system for producing thin sections of oral tissues containing dental implants. *Biomaterials* 1997;18:577-579.
28. Piattelli A, Scarano A, Piattelli M. Detection of alkaline and acid phosphatase around titanium implants: A light microscopical and histochemical study in rabbits. *Biomaterials* 1995;16:1333-1338.
29. Zitzman NU, Naef R, Schärer P. Resorbable versus nonresorbable membrane in combination with Bio-Oss for guided bone regeneration. *Int J Oral Maxillofac Implants* 1997;12:844-852.
30. Schmitt JM, Buck DC, Joh SP, Lynch SE, Hollinger JO. Comparison of porous bone mineral and biologically active glass in critical-sized defects. *J Periodontol* 1997;68:1043-1053.
31. Hammerle CHF, Chiantella GC, Karring T, Lang NP. The effect of a deproteinized bovine bone mineral on bone regeneration around titanium dental implants. *Clin Oral Implants Res* 1998;9:151-162.
32. Klinge B, Alberius P, Isaksson S, Jonsson J. Osseous response to implanted natural bone mineral and synthetic hydroxylapatite ceramics in the repair of experimental skull bone defects. *J Oral Maxillofac Surg* 1992;50:241-249.
33. Wallace SS, Froum SJ, Tarnow DP. Histologic evaluation of sinus elevation procedure: A clinical report. *Int J Periodontics Restorative Dent* 1996;16:47-51.
34. Diès F, Etienne D, Bou Abboud N, Ouhayoun JP. Bone regeneration in extraction sites after immediate placement of an e-PTFE membrane with or without a biomaterial. A report of 12 consecutive cases. *Clin Oral Implants Res* 1996;7:277-285.