

Brain structures related to active and passive finger movements in man

Tatsuya Mima,¹ Norihiro Sadato,² Shogo Yazawa,¹ Takashi Hanakawa,¹ Hidenao Fukuyama,¹ Yoshiharu Yonekura² and Hiroshi Shibasaki¹

¹Department of Brain Pathophysiology, Kyoto University Graduate School of Medicine, Kyoto and ²Department of Radiology and Biomedical Imaging Research Center, Fukui Medical School, Fukui, Japan

Correspondence to: Hiroshi Shibasaki, MD, Department of Brain Pathophysiology, Kyoto University School of Medicine, Shogoin, Sakyo-ku, Kyoto 606-8507, Japan

Summary

A PET study was performed in six normal volunteers to elucidate the functional localization of the sensory afferent component during finger movement. Brain activation during the passive movement driven by a servo-motor was compared with that during an auditory-cued active movement which was controlled kinematically in the same way as the passive one. A newly developed device was used for selectively activating proprioception with a minimal contribution from tactile senses. Active movement was associated with activation of multiple areas, including the contralateral primary sensorimotor cortex, premotor cortex, supplementary motor area (SMA), bilateral

secondary somatosensory areas and basal ganglia and ipsilateral cerebellum. In contrast, only the contralateral primary and secondary somatosensory areas were activated by the passive movement. It is likely that the contribution of proprioceptive input to the activation of the premotor cortex, SMA, cerebellum and basal ganglia, if any, is small. However, the present results do not rule out the possibility that the cutaneous afferent input or the combination of cutaneous and proprioceptive input participates in the activation of those areas during the active movement.

Keywords: passive movement; active movement; PET; primary sensorimotor cortex

Abbreviations: fMRI = functional MRI; rCBF = regional cerebral blood flow; SI = primary somatosensory cortex; SII = secondary somatosensory cortex; SI-MI = primary sensorimotor complex; SMA = supplementary motor area; SPM = statistical parametric map

Introduction

The cortical representation of voluntary movement revealed by activation studies in humans includes both input and output functions of motor control. Previous PET and functional MRI (fMRI) studies of active movements showed the participation of the primary sensorimotor cortex (SI-MI), lateral premotor cortex, supplementary motor area (SMA), superior and inferior parietal cortex, basal ganglia and cerebellum (Roland *et al.*, 1980; Colebatch *et al.*, 1991; Deiber *et al.*, 1991, 1996; Grafton *et al.*, 1993; Matelli *et al.*, 1993; Sabatini *et al.*, 1993; Shibasaki *et al.*, 1993; Dettmers *et al.*, 1995, 1996; Sadato *et al.*, 1996). However, the motor tasks employed in those studies were inevitably accompanied by somatosensory feedback (input) components. Attempts to segregate the motor output function from the contribution of the afferent component have rarely been reported. Weiller and colleagues reported that the brain activation associated with the active motor task at the elbow was essentially the same as that associated with passive movement (Weiller *et al.*, 1996).

In the present study, we investigated the brain structures involved in active and passive finger movements, by comparing the same joint displacement caused either by a servo-motor or by volitional muscle contraction. Since the execution of finger movement is the most common task that has been used in various experimental designs, it is important to separate the planning/execution of the volitional finger movement from the afferent input. The servo-motor system used here was specially designed to selectively activate the human proprioceptors, and this enabled us to detect the cortical representation of proprioception (Mima *et al.*, 1996, 1997b). The kinematics of the active and passive movement were controlled by video and EMG monitoring.

Subjects and methods

Subjects

We studied six normal right-handed men, aged 20–27 years (mean 22.5 years). All subjects gave written informed consent

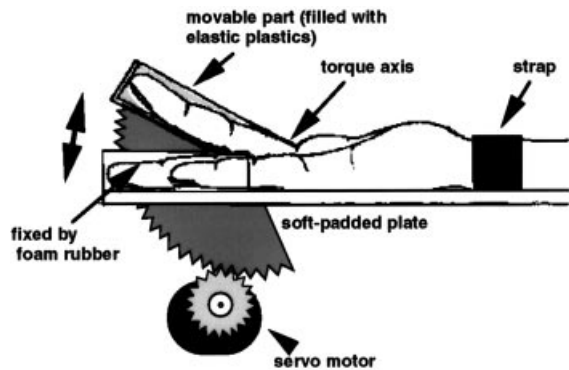


Fig. 1 Schematic illustration of the stimulation device used in the present study. The middle finger was tightly fixed to the movable part of the device by means of individually moulded plastic cap. Torque axis was adjusted to the metacarpophalangeal joint. Other fingers were immobilized by foam rubber. The same device was used in a previous study for a different purpose (Mima *et al.*, 1996).

before the experiments, which were approved by the Committee of Medical Ethics, Graduate School of Medicine and Faculty of Medicine, Kyoto University, and Fukui Medical University. A small catheter was placed in the cubital vein of each subject's left arm for injection of the radiotracer. The subjects lay in a supine position with their eyes closed and covered by a patch. The subject's head was immobilized with an elastic band and sponge cushions. During PET scans, surface EMG from bilateral finger extensors (extensor digiti communi muscle), bilateral wrist flexors (flexor carpi radialis muscle) and the right biceps and triceps muscles, and the bipolar electrooculogram were recorded using an EEG machine (Synafit, San-ei Co., Tokyo, Japan). The movement was also monitored by video recording.

For anatomical reference, a high-resolution whole-brain MRI for each subject was obtained separately, using a standard 1.5 T MRI system (GE Signa, Milwaukee, Wis., USA). A regular head coil and a conventional T_1 -weighted, spoiled-Grass volume sequence with a flip angle of 30° , echo time of 5 ms, repetition time of 33 ms and field of view of 24 cm were used. Matrix size was 256×256 , slice thickness 1.5 mm and pixel size 0.937×0.937 mm. Volume data of 124 sagittal slices were interpolated and resliced to transaxial images with voxel size $0.937 \times 0.937 \times 0.937$ mm. Each high-resolution image was normalized to the template T_1 -weighted images by linear transformation.

Tasks

For the passive movement task, a specially equipped device for flexing the finger joint was used (MySystems Inc., Yamaguchi, Japan) (Mima *et al.*, 1996). The task was a repetitive flexion–extension movement of the right middle finger at the metacarpophalangeal joint (Fig. 1). The distal part of the middle finger was immobilized by an individually moulded plastic cap (Exafine, GC Co., Tokyo, Japan) which could effectively abolish the pressure or tactile sense caused

by the passive movement. This selective stimulation of the proprioceptors has been confirmed in previous electrophysiological studies (Mima *et al.*, 1996, 1997b). Other fingers of the right hand were fixed to the device and held in a rubber pad. Brisk passive movement was elicited every 0.5 s by a servo-motor, which was driven so as to cause a 20° flexion movement of the finger in 0.1 s. The flexed finger then returned to the resting position in 0.1 s, followed by the next movement 0.3 s later. Each flexion–extension movement was accompanied by a beep produced by the equipment. The kinematic parameters of the passive movement were determined by the preliminary recordings of the active repetitive movement using a mechanogram.

An active movement task was performed at the same joint. By using the same plastic cap as that used for the passive movement task, unwanted displacement of the other joints was avoided. The movement was auditory-cued by the beeps produced by the device described above. Before the scanning of each active movement task, subjects practised in order to be able to mimic the passive movement and to move their middle finger rapidly and constantly through an angle of 20° .

For the resting condition, the subjects lay quietly without any intentional movement. During the passive movement and the resting scans, subjects were instructed not to mentally simulate or practise the movement. To cancel the effects of auditory stimuli, beeps caused by the device were presented to the subjects during all scans, including those carried out in the resting condition.

PET scans

The PET scans were performed with a General Electric Advance tomograph (GE Medical Systems, Milwaukee, Wis., USA) with the interslice septa retracted. The physical characteristics of this scanner have been described in detail previously (DeGrado *et al.*, 1994). This scanner acquires 35 slices with an interslice spacing of 4.25 mm. In 3D mode, the scanner acquires oblique sinograms with a maximum cross-coincidence of ± 11 rings. A 10-min transmission scan using two rotating ^{68}Ge sources was performed for attenuation correction. Images of regional cerebral blood flow (rCBF) were obtained by summing the activity during the 60 s period following the first detection of an increase in cerebral radioactivity after intravenous bolus injection of 10 mCi of ^{15}O -labelled water (Sadato *et al.*, 1997). The images were reconstructed with the Kinahan–Rogers reconstruction algorithm (Kinahan and Rogers, 1989). Hanning filters were used, giving transaxial and axial resolutions of 6 and 10 mm (full-width at half-maximum), respectively. The field of view and pixel size of the reconstructed images were 256 and 2 mm, respectively. No arterial blood sampling was performed, and thus the images collected were those of tissue activity. Tissue activity recorded by this method is nearly linearly related to rCBF (Fox *et al.*, 1984; Fox and Mintun, 1989).

Both active and passive movement tasks started 30 s prior to the injection. The pixel size of the reconstructed images

was 2 mm. Each subject had 12 consecutive scans (four scans for each condition) performed at 10 min intervals. The sequential order of tasks was pseudorandomized and counterbalanced among the subjects.

Data analysis

The data acquired were analysed with the Statistical Parametric Mapping (SPM95, Wellcome Department of Cognitive Neurology, London, UK) software implemented in Matlab (The Mathworks Inc., Mass., USA). The scans of

each subject were realigned, and all images were transformed into a standard stereotaxic space (Talairach and Tournoux, 1988). Each image was smoothed by using a Gaussian filter of 15 mm in the *x*, *y* and *z* axes to improve the signal-to-noise ratio. ANCOVA (analysis of covariance), using the global activity as a confounding covariate, was performed on a pixel-to-pixel basis. The results of *t* statistics (SPM{*t*}) were then transformed to a normal standard distribution (SPM{*Z*}). The threshold for SPM{*Z*} was set to $Z > 3.09$ with correction for multiple comparisons at voxel level using the theory of Gaussian fields (Friston *et al.*, 1995). The statistical threshold used was a corrected *P* value of <0.05 .

To further clarify the location of the activated areas with respect to the central sulcus, PET images of each subject were realigned to the MRI scan without stereotaxic normalization and analysed. Additionally, the change in rCBF at the peak activation area of interest was compared among the three conditions using ANOVA (analysis of variance).

Results

Task performance

The EMG of the right hand was silent during the passive movement and the resting conditions. During the active movement condition, all subjects followed the auditory cue correctly and performed the controlled finger movement at 2 Hz. The kinematics of the active movement (duration and magnitude) showed no significant difference among four similar sessions for each subject and did not differ from those of the passive movement. The mean duration of the active flexion–extension movement was 22.9 ± 4.0 ms (mean \pm standard deviation), while that for the passive movement was 22 ms. The mean magnitude was $22.4 \pm 6.4^\circ$, whereas it was 20° for the passive movement. No significant eye or left hand movement was detected during any PET scan.

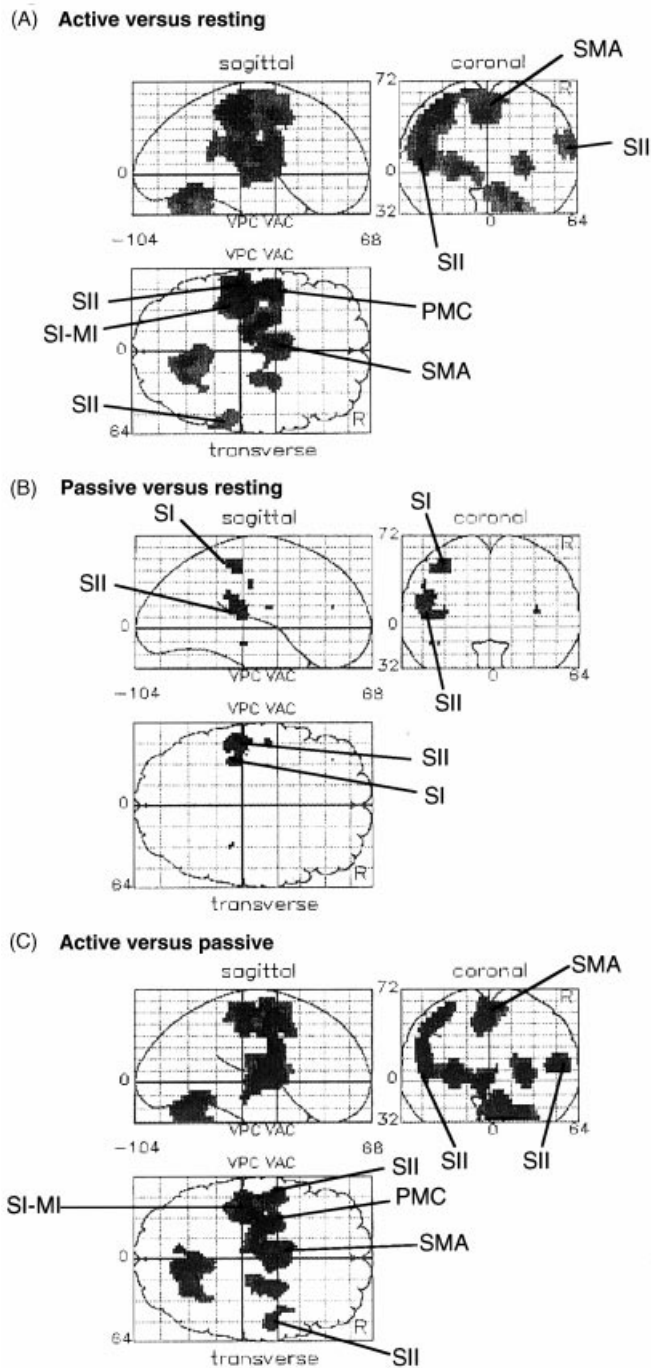


Fig. 2 Statistical parametric maps (SPMs) for the comparison of active and passive movement of the right middle finger, and the resting condition. Pixels exceeding the significance threshold of $Z > 3.09$ are displayed using a grey scale, with the lower *Z* score represented in light grey and the higher *Z* score in dark grey. Pixels are displayed on single sagittal, coronal and axial projections of the brain. The anterior commissure–posterior commissure (AC–PC) line is used for the *x* and *z* axes. The vertical line through the anterior commissure (VAC) is used as the *z*-axis. Coordinates are in mm above (+) and below (–) the AC–PC line (*z*-axis), anterior (+) and posterior (–) to the VAC line, and the left (–) and right (+) of the midline. In the active movement compared with the resting condition (A), the significant increases in rCBF are seen in the left SI-MI, PMC, SMA, bilateral SII, bilateral basal ganglia and right cerebellum. In the passive movement compared with the resting condition (B), the left SI-MI and SII are activated. When the active movement is compared with the passive one (C), greater activation in the former than in the latter is seen in the same area as in (A).

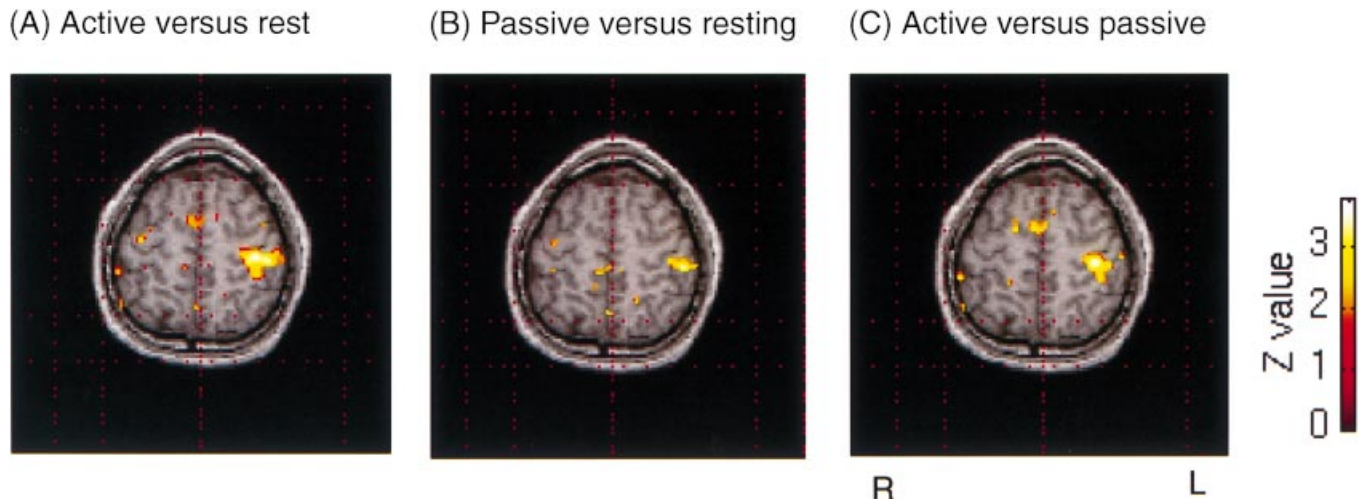


Fig. 3 Comparison of rCBF activation in the active and passive movement of the right middle finger, and the resting condition in a normal subject coregistered with his own MRI. The slices including the hand primary sensorimotor cortex are displayed. The SMA and the left SI are activated by the active movement compared with the resting condition (A) as well as with the passive movement (C). In the passive movement compared with the resting condition (B), only SI is activated at this slice level.

Table 1 Brain areas activated by movement of the right middle finger

Region (Brodmann area)	Talairach coordinates			Z score	P value
	x	y	z		
Active movement					
Left SI-MI (4, 3, 1, 2)	-36	-26	52	6.23	<0.001
Left PMC (6)-SMA (6)	-46	-4	12	6.52	<0.001
Left SII (40, 42, 43)	-50	-28	16	5.39	<0.001
Right cerebellum	10	-68	-16	4.92	0.003
Right basal ganglia (Pu)	24	-4	8	4.56	0.013
Right superior temporal gyrus (22)	60	-48	16	4.29	0.039
Right inferior parietal lobe (40)*	48	-34	28	3.89	0.152
Passive movement					
Left SI (3, 1, 2)*	-42	-30	48	3.26	0.669
Left SII (40, 42, 43)*	-48	-30	16	3.82	0.188
Areas activated to a greater extent by the active movement than the passive movement					
Left MI (4)	-36	-24	52	4.71	0.007
SMA (6)	-8	-2	48	4.61	0.011
Left PMC (6)	-46	-4	12	4.80	0.005
Left basal ganglia (GP)	-26	-12	4	5.04	0.002
Right cerebellum	10	-70	-20	5.22	0.001
Right basal ganglia (Pu)	24	-4	8	4.88	0.003
Right SII (40, 42, 43)	50	-8	16	4.85	0.004

L = left; R = right; GP = globus pallidus; PMC = premotor cortex; Pu = putamen. *Significance was defined as $P < 0.05$ after correction at a cluster level. Some functionally important areas with higher P values are also included.

Change in rCBF

The rCBF changes were assessed using a categorical design (active movement versus resting, passive movement versus resting and active versus passive movement) (Fig. 2). When the passive movement was compared with the active one, no significant focal activation was revealed. The stereotaxic coordinates of the activated foci and the Z value at the maxima for each comparison are shown in Table 1.

Passive movement activated the left primary somatosensory

area (SI), posterior to the posterior commissure line, and the inferior parietal lobule, probably corresponding to the second somatosensory area (SII). However, both sites failed to reach statistical significance. In contrast, activation caused by active movement at the same joint included the left SI-MI, the SMA, the left lateral premotor cortex, the left inferior parietal lobe, the right superior temporal lobule extending to the inferior parietal lobe, the right cerebellum and the bilateral basal ganglia. When active movement was compared with

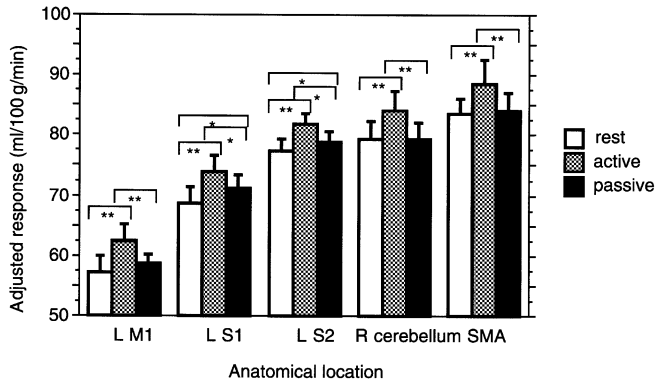


Fig. 4 Adjusted rCBF response at the peak pixels of the left (L) MI, left SI, left SII, right (R) cerebellum and SMA. In the left MI, right cerebellum and SMA, activation caused by the active movement was significantly greater than that with either passive movement or the rest condition. In these three locations, activation during the passive movement was not significantly different from that during the resting condition. In the left SI and SII, both active and passive movements caused significant change in rCBF compared with the resting condition. The degree of activation was significantly larger during the active movement than during the passive one. * $P < 0.05$, ** $P < 0.01$.

passive movement, a similar activation was revealed in the same areas as those where active movement showed activation compared with the resting condition. However, the activated area around SI-MI was more localized to the anteromedial part when active movement was compared with passive movement than with the resting condition. Individual analysis coregistered with individual MRI clearly disclosed the anatomical relationship between these activated foci around the central sulcus (Fig. 3).

To strengthen the power of the statistical analysis, we examined the adjusted response at some of the pixels which showed the peak activation [Table 1: left MI (-36, -24, 52), left SI (-42, -30, 48), left SII (-48, 30, 16), right cerebellum (10, -70, -20) and SMA (-8, -2, 48) in Talairach space]. *Post hoc* comparisons among the three conditions were tested using Scheffe's method (Fig. 4). At the left SI and SII, the adjusted response during both active and passive movements was significantly larger than that during the rest condition, and that during the active movement was larger than that during the passive movement. At the left MI, right cerebellum and SMA, the response during the active movement was significantly larger than that during both the passive movement and the resting condition. However, the difference between the responses during the passive movement and the resting condition did not reach statistical significance.

Discussion

Brain structures activated in association with passive and active movements of the finger were clearly different. Passive movement elicited a weak and spatially limited brain activation compared with active movement, which was controlled kinematically in the same way as passive

movement. These findings contrast strongly with a previous PET study on passive movement (Weiller *et al.*, 1996) and a sensory activation study using fMRI (Puce *et al.*, 1995; Yetkin *et al.*, 1995), both of which demonstrated similar sensorimotor cortical activation during the sensory and the motor task. However, these results are not directly comparable with the present results because of the difference in the sensory tasks employed. The previous PET study by Weiller and colleagues adopted a larger movement (90°) at the proximal joint (elbow) without controlling the tactile input (Weiller *et al.*, 1996). For the fMRI study, tactile stimulation such as the use of an air-puff or brushing was used for activation (Puce *et al.*, 1995; Yetkin *et al.*, 1995). A recent fMRI study using a 'passive movement' (Alary *et al.*, 1998) did not monitor muscle activity during the task and did not report the kinematic parameters of the stimuli in a quantitative way.

Brain regions related to the active movement included most parts of the classical motor system and were consistent with previous reports (Roland *et al.*, 1980; Colebatch *et al.*, 1991; Deiber *et al.*, 1991, 1996; Grafton *et al.*, 1993; Matelli *et al.*, 1993; Sabatini *et al.*, 1993; Shibasaki *et al.*, 1993; Dettmers *et al.*, 1995, 1996; Sadato *et al.*, 1996). Cortical representation of the proprioception elicited by the passive finger movement included the contralateral SI and SII. Although the rCBF increase did not reach statistical significance in the multiple comparison using the whole brain volume, the present result is physiologically reliable (Kaas, 1983; Burton, 1986; Johnson and Hsiao, 1992) and similar to previous activation studies using vibrotactile or electrical nerve stimulation (Fox *et al.*, 1987; Seitz and Roland, 1992; Tempel and Perlmutter, 1992; Burton *et al.*, 1993; Ibanez *et al.*, 1995; Casey *et al.*, 1996). Peak activation at SI was also statistically larger in the passive movement condition than in the resting condition. Previous electrophysiological studies have suggested modality-specific organization within SI (deep versus cutaneous receptors for areas 3a + 2 versus areas 3b + 1, respectively) (Mima *et al.*, 1997b; for reviews, see Mountcastle, 1984; Kaas and Pons, 1988). However, it is impossible to identify which part of SI was primarily activated by the proprioceptive stimulation because of the limited spatial resolution of the PET technique. For the same reason, it is difficult to differentiate between the activations at SI and MI. In proprioceptive stimulation, it is most likely that the activated area is confined to the postcentral area in Talairach's coordinates (posterior to the posterior commissure line at the level of the hand sensorimotor area). This notion was supported by the coregistration to the individual MRI using a single-subject analysis and also by the comparison of peak activation at SI and MI between tasks. The absence of MI activation in somatosensory stimulation generally agrees with previous reports (Fox *et al.*, 1987; Seitz and Roland, 1992; Tempel and Perlmutter, 1992; Burton *et al.*, 1993; Ibanez *et al.*, 1995; Casey *et al.*, 1996), although the somatosensory afferent input to MI has been shown in primates and humans (Goldring and Ratcheson, 1972; Lucier

et al., 1975; Hore *et al.*, 1976; Asanuma *et al.*, 1980). The most likely reason for the absence of MI activation in the present study is that the sensory afferents were too small and transient to be detected by rCBF measurement. The present study demonstrates for the first time the different cortical representation of active and passive movements of the finger.

The active movement showed a greater rCBF increase at SI than the passive movement, suggesting that SI was more activated during the active movement. Because of the limited resolution of PET, we cannot exclude the possibility that the large MI activation caused an apparent expansion of the significant area in SPM analysis. Additional SI activation during active movement can be explained either by a corollary discharge from MI to SI (Pandya and Kuypers, 1969; for review, see Hepp-Raymond, 1988) or by the change in excitability of SI caused by the motor task (Rushton *et al.*, 1981; Cohen and Starr, 1987; Prud'homme and Kalaska, 1994). Ipsilateral SI-MI was not activated by the active movement, probably because the motor task employed was a simple and easy, repetitive movement. The activation of the ipsilateral SI-MI has been reported in the various motor tasks (Colebatch *et al.*, 1991; Grafton *et al.*, 1992; Shibasaki *et al.*, 1993; Kawashima *et al.*, 1994), only when the complex and/or proximal limb movements were required.

The other area which showed a significant rCBF increase during passive movement was the contralateral inferior parietal cortex, corresponding to SII (Hari *et al.*, 1983; Burton *et al.*, 1995; Krubitzer *et al.*, 1995; Mima *et al.*, 1997a). Involvement of the insular or frontal cortex (Burton *et al.*, 1997) was unclear due to spatial smoothing and normalization. Previous PET studies applying somatosensory stimulation revealed bilateral or contralateral SII activation depending on the stimulation method (Fox *et al.*, 1987; Meyer *et al.*, 1991; Seitz and Roland, 1992; Burton *et al.*, 1993, 1997; Ibanez *et al.*, 1995; Bonda *et al.*, 1996; Xu *et al.*, 1997). This divergence is probably associated with the fact that SII has bilateral but contralaterally dominant receptive fields (for review, see Burton, 1986). Interestingly, the ipsilateral SII was activated during the active movement but not during the passive one. Moreover, the contralateral SII was even more activated in the active movement condition compared with the passive one. Lesion studies in patients and primates suggest that the function of SII is that of a higher order somatosensory centre (Ridley and Ettlenger, 1976, 1978; Mishkin, 1979; Friedman *et al.*, 1986; Murray *et al.*, 1992; Caselli, 1993). In the active movement task in the present study, the 20° movement without visual feedback is likely to need tight coupling between the sensory and motor systems. Thus, it is highly probable that the activation of SII during active movement is associated with the sensorimotor integration using an auditory cue and proprioceptive afferent feedback (Huttunen *et al.*, 1996). In a recent patient study, a sensorimotor integrative role of the human inferior parietal lobe was proposed (Mattingley *et al.*, 1998). The other possible explanation is an effect of implicit attention to the

moving hand, as active attention has been reported to increase SII activity (Mima *et al.*, 1998).

The SMA receives inputs from the somatosensory system, especially proprioceptors (Cadoret and Smith, 1997; Mima *et al.*, 1999). However, in spite of the fact that we compared the rCBF change at the peak pixel, there was no SMA activation associated with the passive movement. It is possible that the response of the SMA in the present passive movement task was too small or was temporally transient, so that the sensitivity of the PET was insufficient to delineate the activation. These results clearly suggest that the SMA represents kinematically similar active and passive movements in a very different way. The present study, indicating an absence of SMA activation associated with the sensory stimuli, disagrees with the previous studies using vibrotactile stimulation (Fox *et al.*, 1987; Tempel and Perlmutter, 1992) but agrees with a study using electrical nerve stimulation (Ibanez *et al.*, 1995). A possible contribution of motor response (tonic vibration reflex) elicited by the vibration stimuli was suggested as the generating mechanism of SMA activation (Ibanez *et al.*, 1995). It is also probable that the sensory discrimination task may induce the subject to perform some exploratory movement or active touch, unconsciously. However, the present study does not rule out the possibility that the specific combination of cutaneous and proprioceptive inputs during the active movement may contribute to the activation of the SMA during the active movement task. It is possible that the SMA is sensitive to afferent information during the active motor task rather than that during the passive movement. The location of the activated foci within the SMA that are associated with the active movement is consistent with previous reports (for review, see Picard and Strick, 1996). Activation predominantly involved the posterior SMA (SMA proper) caudal to the anterior commissure line rather than the pre-SMA, probably because we made use of the simple externally triggered finger movement. However, our active movement task required the subject to control the timing, direction and amplitude of the movement so as to fit the preset joint angle. These specific requirements might also explain the activation at the left dorsal premotor cortex during the active movement (set-related neurons) (Mushiaki *et al.*, 1991; Kurata, 1993).

The absence of activation in the primary and secondary motor areas during the passive movement task can be partly explained by the lack of somatosensory attention during the passive movement which is present during the active movement. Even during the passive movement task, large and infrequent passive movements, such as the task used by Weiller and colleagues (Weiller *et al.*, 1996), might implicitly capture the subject's attention and induce the brain activation associated with the somatosensory attentional shift. It has been reported that MI or SMA neurons are involved in the discrimination or categorization of the somatosensory stimuli (Mountcastle *et al.*, 1992; Romo *et al.*, 1993).

Subcortical structures including the bilateral basal ganglia

and the ipsilateral (right) cerebellum were activated during the active movement but not during the passive one. This result is not surprising because these areas have been regarded as part of the motor system in the classical sense (for review, see Brooks, 1995). Although the absence of cerebellar activation during the sensory task generally agrees with previous reports (Fox *et al.*, 1987; Seitz and Roland, 1992; Tempel and Perlmutter, 1992; Burton *et al.*, 1993; Ibanez *et al.*, 1995; Casey *et al.*, 1996), a role for the cerebellum in sensory perception has been suggested recently (Gao *et al.*, 1996; Jueptner *et al.*, 1997). The absence of the cerebellar activation in the present study is in accord with an animal experiment in which the passive sensory stimulus itself failed to activate the dentate nuclei (Strick *et al.*, 1983). Unlike previous studies in which cerebellar activation was observed (Weiller *et al.*, 1996), the passive movement task in the present study strictly controlled the contribution of tactile sense and required neither conscious discrimination of the stimuli nor an active response to the stimuli.

Acknowledgements

We wish to thank Dr Mark Hallett and Dr Kenji Ishii for useful comments and discussions. This study was partly supported by Grants-in-Aid for Scientific Research (A)09308031, (A)08558083 and (C)09670655, Priority Areas Grant 08279106 and International Scientific Research 10044269 from the Japan Ministry of Education, Science, Sports and Culture, Research for the Future Program Grant JSPS-RFTF97L00201 and JSPS-RFTF97L00203 from the Japan Society for the Promotion of Science and General Research Grant for Aging and Health from the Japan Ministry of Health and Welfare.

References

- Alary F, Doyon B, Loubinoux I, Carel C, Boulanouar K, Ranjeva JP, et al. Event-related potentials elicited by passive movements in humans: characterization, source analysis, and comparison to fMRI. *Neuroimage* 1998; 8: 377–90.
- Asanuma H, Larsen K, Yumiya H. Peripheral input pathways to the monkey motor cortex. *Exp Brain Res* 1980; 38: 349–55.
- Bonda E, Petrides M, Evans A. Neural systems for tactual memories. *J Neurophysiol* 1996; 75: 1730–7.
- Brooks DJ. The role of the basal ganglia in motor control: contributions from PET. [Review]. *J Neurol Sci* 1995; 128: 1–13.
- Burton H. Second somatosensory cortex and related areas. In: Jones EG, Peters A, editors. *Cereb cortex*, Vol. 5. New York: Plenum Press; 1986. p. 31–98.
- Burton H, Videen TO, Raichle ME. Tactile-vibration-activated foci in insular and parietal-opercular cortex studied with positron emission tomography: mapping the second somatosensory area in humans. *Somatosens Motor Res* 1993; 10: 297–308.
- Burton H, Fabri M, Alloway K. Cortical areas within the lateral sulcus connected to cutaneous representations in areas 3b and 1: a revised interpretation of the second somatosensory area in macaque monkeys. *J Comp Neurol* 1995; 355: 539–62.
- Burton H, MacLeod A-MK, Videen TO, Raichle ME. Multiple foci in parietal and frontal cortex activated by rubbing embossed grating patterns across fingerpads: a positron emission tomography study in humans. *Cereb Cortex* 1997; 7: 3–17.
- Cadore G, Smith AM. Comparison of the neuronal activity in the SMA and the ventral cingulate cortex during prehension in the monkey. *J Neurophysiol* 1997; 77: 153–66.
- Caselli RJ. Ventrolateral and dorsomedial somatosensory association cortex damage produces distinct somesthetic syndromes in humans [see comments]. *Neurology* 1993; 43: 762–71. Comment in: *Neurology* 1993; 43: 2423–4.
- Casey KL, Minoshima S, Morrow TJ, Koeppe RA. Comparison of human cerebral activation pattern during cutaneous warmth, heat pain, and deep cold pain. *J Neurophysiol* 1996; 76: 571–81.
- Cohen LG, Starr A. Localization, timing and specificity of gating of somatosensory evoked potentials during active movement in man. *Brain* 1987; 110: 451–67.
- Colebatch JG, Deiber MP, Passingham RE, Friston KJ, Frackowiak RS. Regional cerebral blood flow during voluntary arm and hand movements in human subjects. *J Neurophysiol* 1991; 65: 1392–401.
- DeGrado TR, Turkington TG, Williams JJ, Stearns CW, Hoffman JM. Performance characteristics of a whole-body PET scanner. *J Nucl Med* 1994; 35: 1398–406.
- Deiber MP, Passingham RE, Colebatch JG, Friston KJ, Nixon PD, Frackowiak RS. Cortical areas and the selection of movement: a study with positron emission tomography. *Exp Brain Res* 1991; 84: 393–402.
- Deiber MP, Ibañez V, Sadato N, Hallett M. Cerebral structures participating in motor preparation in humans: a positron emission tomography study. *J Neurophysiol* 1996; 75: 233–47.
- Dettmers C, Fink GR, Lemon RN, Stephan KM, Passingham RE, Silbersweig D, et al. Relation between cerebral activity and force in the motor areas of the human brain. *J Neurophysiol* 1995; 74: 802–15.
- Dettmers C, Lemon RN, Stephan KM, Fink GR, Frackowiak RS. Cerebral activation during the exertion of sustained static force in man. *Neuroreport* 1996; 7: 2103–10.
- Fox PT, Mintun MA. Noninvasive functional brain mapping by change-distribution analysis of averaged PET images of H₂¹⁵O tissue activity. *J Nucl Med* 1989; 30: 141–9.
- Fox PT, Mintun MA, Raichle ME, Herscovitch P. A noninvasive approach to quantitative functional brain mapping with H₂¹⁵O and positron emission tomography. *J Cereb Blood Flow Metab* 1984; 4: 329–33.
- Fox PT, Burton H, Raichle ME. Mapping human somatosensory cortex with positron emission tomography. *J Neurosurg* 1987; 67: 34–43.
- Friedman DP, Murray EA, O'Neill JB, Mishkin M. Cortical connections of the somatosensory fields of the lateral sulcus of

- macaques: evidence for a corticolimbic pathway for touch. *J Comp Neurol* 1986; 252: 323–47.
- Friston KJ, Holmes AP, Worsley KJ, Poline JB, Frith CD, Frackowiak RSJ. Statistical parametric maps in functional imaging: a general linear approach. *Hum Brain Mapp* 1995; 2: 189–210.
- Gao JH, Parsons LM, Bower JM, Xiong J, Li J, Fox PT. Cerebellum implicated in sensory acquisition and discrimination rather than motor control [see comments]. *Science* 1996; 272: 545–457. Comment in: *Science* 1996; 272: 482–3.
- Goldring S, Ratcheson R. Human motor cortex: sensory input data from single neuron recordings. *Science* 1972; 175: 1493–5.
- Grafton ST, Mazziotta JC, Woods RP, Phelps ME. Human functional anatomy of visually guided finger movements. *Brain* 1992; 115: 565–87.
- Grafton ST, Woods RP, Mazziotta JC. Within-arm somatotopy in human motor areas determined by positron emission tomography imaging of cerebral blood flow. *Exp Brain Res* 1993; 95: 172–6.
- Hari R, Hämäläinen M, Kaukoranta E, Reinikainen K, Teszner D. Neuromagnetic responses from the second somatosensory cortex in man. *Acta Neurol Scand* 1983; 68: 207–12.
- Hepp-Raymond MC. Functional organization of motor cortex and its participation in voluntary movements. In: Steklis HD, Erwin J, editors. *Comparative primate biology*, Vol. 4. New York: Alan R. Liss; 1988. p. 501–624.
- Hore J, Preston JB, Cheney PD. Responses of cortical neurons (areas 3a and 4) to ramp stretch of hindlimb muscles in the baboon. *J Neurophysiol* 1976; 39: 484–500.
- Huttunen J, Wikström H, Korvenoja A, Seppäläinen A, Aronen H, Ilmoniemi J. Significance of the second somatosensory cortex in sensorimotor integration: enhancement of sensory responses during finger movements. *Neuroreport* 1996; 7: 1009–12.
- Ibanez V, Deiber MP, Sadato N, Toro C, Grissom J, Woods RP, et al. Effects of stimulus rate on regional cerebral blood flow after median nerve stimulation. *Brain* 1995; 118: 1339–51.
- Johnson KO, Hsiao SS. Neural mechanisms of tactual form and texture perception. [Review]. *Annu Rev Neurosci* 1992; 15: 227–50.
- Jueptner M, Ottinger S, Fellows SJ, Adamschewski J, Flerich L, Müller SP, et al. The relevance of sensory input for the cerebellar control of movements. *Neuroimage* 1997; 5: 41–8.
- Kaas JH. What, if anything, is SI? Organization of first somatosensory area of cortex. *Physiol Rev* 1983; 63: 206–31.
- Kaas JH, Pons TP. The somatosensory system of primates. In: Steklis HD, Erwin J, editors. *Comparative primate biology*, Vol. 4. New York: Alan R. Liss; 1988. p. 421–68.
- Kawashima R, Roland PE, O'Sullivan BT. Activity in the human primary motor cortex related to ipsilateral hand movements. *Brain Res* 1994; 663: 251–6.
- Kinahan PE, Rogers JG. Analytic 3D image reconstruction using all detected events. *IEEE Trans Nucl Sci* 1989; 36: 964–8.
- Krubitzer L, Clarey J, Tweedale R, Elston G, Calford M. A redefinition of somatosensory areas in the lateral sulcus of macaque monkeys. *J Neurosci* 1995; 15: 3821–39.
- Kurata K. Premotor cortex of monkeys: set- and movement-related activity reflecting amplitude and direction of wrist movements. *J Neurophysiol* 1993; 69: 187–200.
- Lucier GE, Rüegg DC, Wiesendanger M. Responses of neurones in motor cortex and in area 3A to controlled stretches of forelimb muscles in cebus monkey. *J Physiol (Lond)* 1975; 251: 833–53.
- Matelli M, Rizzolatti G, Bettinardi V, Gilardi MC, Perani D, Rizzo G, et al. Activation of precentral and mesial motor areas during the execution of elementary proximal and distal arm movements: a PET study. *Neuroreport* 1993; 4: 1295–8.
- Mattingley JB, Husain M, Rorden C, Kennard C, Driver J. Motor role of human inferior parietal lobe revealed in unilateral neglect patients. *Nature* 1998; 392: 179–82.
- Meyer E, Ferguson SS, Zattore RJ, Alivisatos B, Marrett S, Evans AC, et al. Attention modulates somatosensory cerebral blood flow response to vibrotactile stimulation as measured by positron emission tomography. *Ann Neurol* 1991; 29: 440–3.
- Mima T, Terada K, Maekawa M, Nagamine T, Ikeda A, Shibasaki H. Somatosensory evoked potentials following proprioceptive stimulation of fingers in man. *Exp Brain Res* 1996; 111: 233–45.
- Mima T, Ikeda A, Nagamine T, Yazawa S, Kunieda T, Mikuni N, et al. Human second somatosensory area: subdural and magnetoencephalographic recording of somatosensory evoked responses. *J Neurol Neurosurg Psychiatry* 1997a; 63: 501–5.
- Mima T, Ikeda A, Terada K, Yazawa S, Mikuni N, Kunieda T, et al. Modality-specific organization for cutaneous and proprioceptive sense in human primary sensory cortex studied by chronic epicortical recording. *Electroencephalogr Clin Neurophysiol* 1997b; 104: 103–7.
- Mima T, Nagamine T, Nakamura K, Shibasaki H. Attention modulates both primary and second somatosensory cortical activities in humans: a magnetoencephalographic study. *J Neurophysiol* 1998; 80: 2215–21.
- Mima T, Ikeda A, Yazawa S, Kunieda T, Nagamine T, Taki W, et al. Somesthetic function of supplementary motor area during voluntary movements. *Neuroreport* 1999; 10: 1859–962.
- Mishkin M. Analogous neural models for tactual and visual learning. *Neuropsychologia* 1979; 17: 139–51.
- Mountcastle VB. Central nervous mechanisms in mechanoreceptive sensibility. In: Brookhart JM, Mountcastle VB, editors. *Handbook of physiology: Sect 1, Vol. 3*. Bethesda (MD): American Physiological Society; 1984. p. 789–878.
- Mountcastle VB, Atluri PD, Romo R. Selective output-discriminative signals in the motor cortex of waking monkeys. *Cereb Cortex* 1992; 2: 277–94.
- Murray GM, Zhang HQ, Kaye AN, Sinnadurai T, Campbell DH, Rowe MJ. Parallel processing in rabbit first (SI) and second (SII) somatosensory cortical areas: effects of reversible inactivation by cooling of SI on responses in SII. *J Neurophysiol* 1992; 68: 703–10.
- Mushiaki H, Inase M, Tanji J. Neuronal activity in the primate premotor, supplementary, and precentral motor cortex during visually guided and internally determined sequential movements. *J Neurophysiol* 1991; 66: 705–18.

- Pandya DN, Kuypers HGM. Cortico-cortical connections in the rhesus monkey. *Brain Res* 1969; 13: 13–36.
- Picard N, Strick PL. Motor areas of the medial wall. [Review]. *Cereb Cortex* 1996; 6: 342–53.
- Prud'homme MJL, Kalaska JF. Proprioceptive activity in primate primary somatosensory cortex during active arm reaching movements. *J Neurophysiol* 1994; 72: 2280–301.
- Puce A, Constable RT, Luby ML, McCarthy G, Nobre AC, Spencer DD, et al. Functional magnetic resonance imaging of sensory and motor cortex: comparison with electrophysiological localization. *J Neurosurg* 1995; 83: 262–70.
- Ridley RM, Ettlinger G. Impaired tactile learning and retention after removal of the second somatic sensory projection cortex (SII) in the monkey. *Brain Res* 1976; 109: 656–60.
- Ridley RM, Ettlinger G. Further evidence of impaired tactile learning after removal of the second somatic sensory projection cortex (SII) in the monkey. *Exp Brain Res* 1978; 31: 475–88.
- Roland PE, Larsen B, Lassen NA, Skinhoj E. Supplementary motor area and other cortical areas in organization of voluntary movements in man. *J Neurophysiol* 1980; 43: 118–36.
- Romo R, Ruiz S, Crespo P, Zainos A, Merchant H. Representation of tactile signals in primate supplementary motor area. *J Neurophysiol* 1993; 70: 2690–4.
- Rushton DN, Rothwell JC, Craggs MD. Gating of somatosensory evoked potentials during different kinds of movement in man. *Brain* 1981; 104: 465–91.
- Sabatini U, Chollet F, Rascol O, Celsis P, Rascol A, Lenzi GL, et al. Effect of side and rate of stimulation on cerebral blood flow changes in motor areas during finger movements in humans. *J Cereb Blood Flow Metab* 1993; 13: 639–45.
- Sadato N, Ibañez V, Deiber MP, Campbell G, Leonardo M, Hallett M. Frequency-dependent changes of regional cerebral blood flow during finger movements. *J Cereb Blood Flow Metab* 1996; 16: 23–33.
- Sadato N, Carson RE, Daube-Witherspoon ME, Campbell G, Hallett M, Herscovitch P. Optimization of noninvasive activation studies with ¹⁵O-water and three-dimensional positron emission tomography. *J Cereb Blood Flow Metab* 1997; 17: 732–9.
- Seitz RJ, Roland PE. Vibratory stimulation increases and decreases the regional cerebral blood flow and oxidative metabolism: a positron emission tomography (PET) study. *Acta Neurol Scand* 1992; 86: 60–7.
- Shibasaki H, Sadato N, Lyshkow H, Yonekura Y, Honda M, Nagamine T, et al. Both primary motor cortex and supplementary motor area play an important role in complex finger movement. *Brain* 1993; 116: 1387–98.
- Strick PL. The influence of motor preparation on the response of cerebellar neurons to limb displacements. *J Neurosci* 1983; 3: 2007–20.
- Talairach J, Tournoux P. Co-planar stereotaxic atlas of the human brain. Stuttgart: Thieme; 1988.
- Tempel LW, Perlmutter JS. Vibration-induced regional cerebral blood flow responses in normal aging. *J Cereb Blood Flow Metab* 1992; 12: 554–61.
- Weiller C, Jüptner M, Fellows S, Rijntjes M, Leonhardt G, Kiebel S, et al. Brain representation of active and passive movements. *Neuroimage* 1996; 4: 105–10.
- Xu X, Fukuyama H, Yazawa S, Mima T, Hanakawa T, Magata Y, et al. Functional localization of pain perception in the human brain studied by PET. *Neuroreport* 1997; 8: 555–9.
- Yetkin FZ, Mueller WM, Hammeke TA, Morris GL 3rd, Houghton VM. Functional magnetic resonance imaging mapping of the sensorimotor cortex with tactile stimulation. *Neurosurgery* 1995; 36: 921–5.

Received March 7, 1999. Accepted May 4, 1999