

This is an Open Access article licensed under the terms of the Creative Commons Attribution-NonCommercial-NoDerivs 3.0 License (www.karger.com/OA-license), applicable to the online version of the article only. Distribution for non-commercial purposes only.

Branch Retinal Artery Occlusion Caused by Toxoplasmosis in an Adolescent

Elizabeth Chiang^{a, b} Debra A. Goldstein^a Michael J. Shapiro^{b–d}
Marilyn B. Mets^{a, b}

^aDepartment of Ophthalmology, Feinberg School of Medicine, Northwestern University,

^bDepartment of Ophthalmology, Ann & Robert H. Lurie Children's Hospital of Chicago,

and ^cDepartment of Ophthalmology and Visual Sciences, Illinois Eye and Ear Infirmary, University of Illinois at Chicago, Chicago, Ill., and ^dRetina Consultants Ltd.,

Des Plaines, Ill., USA

Key Words

Toxoplasmosis · Branch retinal artery occlusion · Vascular occlusion · Uveitis · Inflammation

Abstract

Purpose: Branch retinal artery occlusion (BRAO), while not uncommon in elderly patient populations, is rare in children and adolescents. We report a case of a BRAO secondary to toxoplasmosis in this demographic.

Case: A previously healthy 17-year-old male developed a unilateral BRAO in conjunction with inflammation and increased intraocular pressure. Family history was positive for cerebrovascular accidents in multiple family members at relatively young ages. The patient had a hypercoagulable workup as well as a cardiovascular workup which were both normal. A rheumatologic workup was unremarkable. By 3 weeks, a patch of retinitis was more easily distinguished from the BRAO and the diagnosis of ocular toxoplasmosis was made. Treatment was started with prednisone and azithromycin with subsequent improvement in vision. Toxoplasma antibody levels were elevated for IgG and negative for IgM, IgA, and IgE. The etiology of the BRAO was attributed to ocular toxoplasmosis.

Conclusions: Vascular occlusions are rare in toxoplasmosis. This is the third case report of a BRAO in a patient in the pediatric population. The diagnosis of ocular toxoplasmosis should be considered in young patients with retinal artery occlusions associated with inflammation.

Introduction

In elderly patients, obstruction of retinal arteries is most often attributed to emboli from atherosclerotic vascular disease. Branch retinal artery occlusion (BRAO) in children is rare. Conditions that promote embolus formation in children include atrial myxoma, mitral valve prolapse, rheumatic heart disease, and endocarditis secondary to IV drug abuse [1, 2]. Children may also develop a hypercoagulable state secondary to homocystinuria, factor V Leiden mutations, or antiphospholipid antibody syndrome [1, 2]. Less commonly, BRAO can be associated with infections including ocular *Bartonella henselae*, West Nile virus, and syphilis [3–5]. Other causes for retinal artery occlusion in children include sickle cell disease, orbital trauma, and neoplastic disorders [1, 2]. We report a case of retinal artery occlusion in an adolescent secondary to ocular toxoplasmosis.

Case Report

A 17-year-old male presented with right eye (OD) pain, headache, and floaters. There was no history of trauma and past medical history was unremarkable. Family history was significant for thromboembolic and cardiovascular disease of unknown etiology. The patient's father had a stroke at the age of 37, and his mother's sister had a stroke at the age of 49. Both of his grandfathers died of heart attacks in their 50s.

Initial examination revealed best corrected visual acuity of count fingers at 10 feet in the OD and 20/20 in the left eye (OS). The pupils were equal, round, and reactive with right relative afferent pupillary defect. Confrontational field testing revealed an inferior field deficit OD. Extraocular movements were full but the patient had pain OD on medial gaze. Intraocular pressure was 40 mm Hg OD and 12 mm Hg OS.

Slit-lamp examination showed 1+ conjunctival injection and a hazy cornea OD that precluded good view of the anterior segment. The OS was normal. Dilated fundus examination revealed a superotemporal BRAO OD, with a subtle, small, white, elevated area of retinitis at the proximal portion of the occluded vessel, not appreciated on initial examination (fig. 1a). The left fundus was normal. Fundus fluorescein angiography OD revealed an occlusion of the superotemporal branch retinal artery (fig. 1b, c). Fundus fluorescein angiography of the OS was normal.

The patient was admitted to the hospital for further evaluation, and he was started on topical dorzolamide and timolol. Coagulation testing including prothrombin time, activated partial thromboplastin time, protein S, protein C, and antithrombin III was normal. Factor V Leiden, von Willebrand's factor and antigen, and prothrombin gene testing were normal. The patient was heterozygous for the MTHFR C677T polymorphism which is associated with intermediate levels of enzyme-specific activity, but not increased homocysteine levels. Hemoglobin and protein electrophoresis were normal.

Rheumatological workup revealed no antinuclear antibodies, anticardiolipin antibodies, or beta-2 glycoprotein 1 antibodies. Erythrocyte sedimentation rate and C-reactive protein were both normal. Complete blood count and basic metabolic panel were unremarkable. An electrocardiogram and transthoracic echocardiogram of the heart revealed no cardiovascular abnormalities. Troponin I, lipid panel, and lipoprotein A were normal. Magnetic resonance imaging examination of the brain and orbits and magnetic resonance angiogram of the head and neck were unremarkable.

Humphrey visual field testing done on day 15 showed an inferior field defect (fig. 2a). Slit-lamp examination revealed inferior keratic precipitates (fig. 3), 1+ cell and flare in the anterior chamber and 1+ cell in the anterior vitreous. At this point in time, the retinitis was more easily distinguished from the BRAO (fig. 1d), and the diagnosis of ocular toxoplasmosis was suggested by a consultant. Serum antitoxoplasma IgG antibody levels were elevated at 1:512 (Dye test; Palo Alto Medication Foundation, Palo Alto, Calif., USA). IgM, IgA, and IgE ELISA tests were negative. Treatment with oral

azithromycin 500 mg daily and oral prednisone 40 mg daily was started. By 2 months after presentation, visual acuity had improved to 20/70. Repeat visual field testing showed moderate improvement (fig. 2b).

Discussion

Ocular toxoplasmosis is an uncommon but important cause of retinal artery occlusion [6]. It should be considered in patients with inflammation and high intraocular pressure. An area of retinitis should be sought at the proximal point of the occlusion. Retinal whitening due to ischemia may obscure the lesion initially. In our patient, it is also possible that an undefined coagulopathy contributed to the development of vascular occlusion.

A literature search was performed on Medline using a combination of the search terms ‘artery occlusion,’ ‘artery obstruction,’ ‘retina,’ ‘retinal,’ ‘toxoplasma,’ and ‘toxoplasmosis.’ Only articles with abstracts written in English and articles written in English, French, or German were included. The literature search for retinal arterial occlusion associated with toxoplasmosis revealed 12 papers [7–18]. From these papers, 17 cases included imaging or sufficient description to identify the relationship of retinitis to the occlusion. Seventy-six percent of the obstructed arterioles passed through the toxoplasmosis lesion, and 24% of the obstructed arterioles were within one optic disc diameter of the lesion. Twenty-one patients, ranging in age from 14 to 70 years, with an average age of 33, had BRAO secondary to toxoplasmosis. Nine of the 17 patients were below the age of 30, and only 2 patients were under the age of 18. This is the third reported case of a BRAO due to toxoplasmosis in a patient under the age of 18.

This case highlights that BRAO can occur in the pediatric population due to retinal infection with toxoplasmosis. The diagnosis of ocular toxoplasmosis should be considered in young patients with retinal artery occlusion associated with inflammation. Earlier diagnosis in this patient may have spared an exhaustive workup.

Disclosure Statement

None of the authors have any financial conflicts of interest to declare.

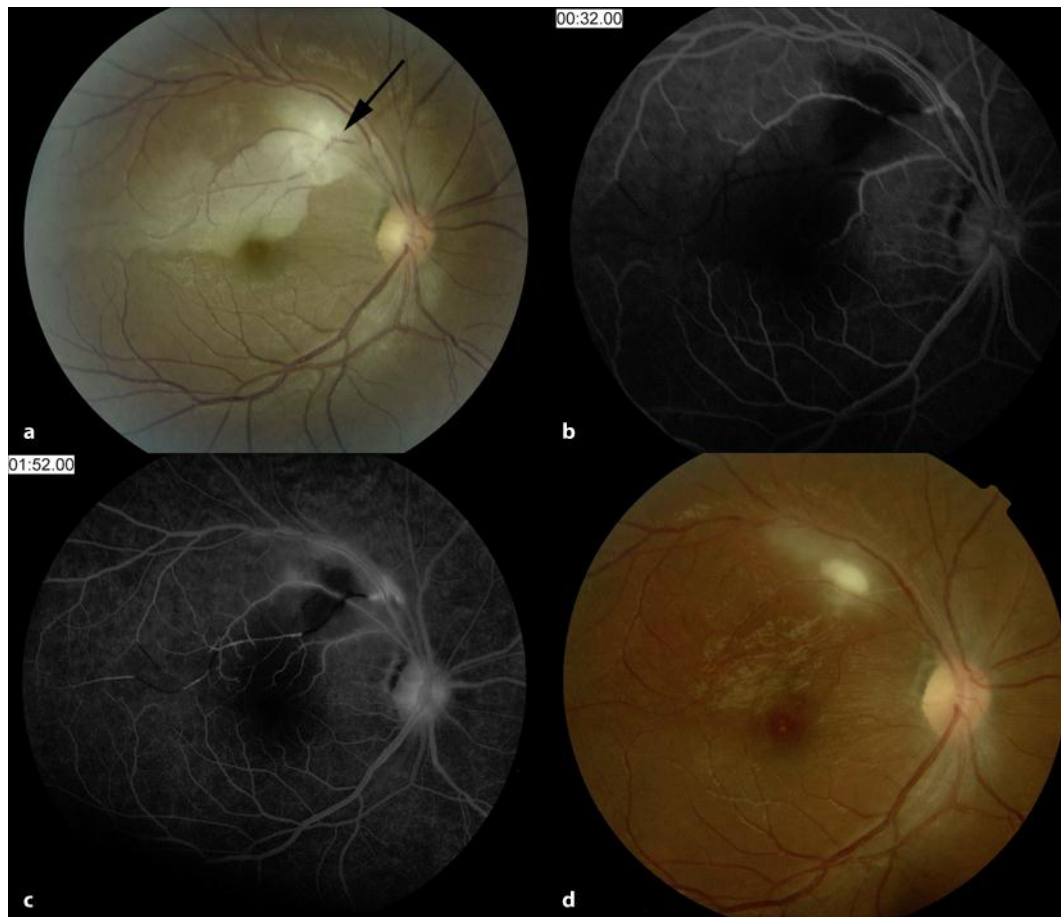


Fig. 1. Fundus photographs of the OD. **a** On day 1 of presentation, the right fundus showed ischemic retinal whitening along the superior arcade, with the arrow indicating the occluded vessel. **b** Fluorescein angiography of the OD on day 1 of presentation showing the blocked vessel in the superior arcade. In the venous phase, the arteriole distal to the inflammatory lesion does not fill with fluorescein. **c** During the recirculation phase, the distal arteriole shows retrograde filling but the segment of the arteriole in the inflamed region remains hypofluorescent and nonperfused. **d** By day 37, a sharply demarcated lesion consistent with toxoplasmosis is seen proximal to the occlusion of the retinal arteriole.




Fig. 2. Humphrey visual field of the OD. **a** Visual field on day 15 demonstrates an inferior field deficit consistent with loss of vision along the superior arcade. **b** There is mild improvement of the visual field seen on day 57.

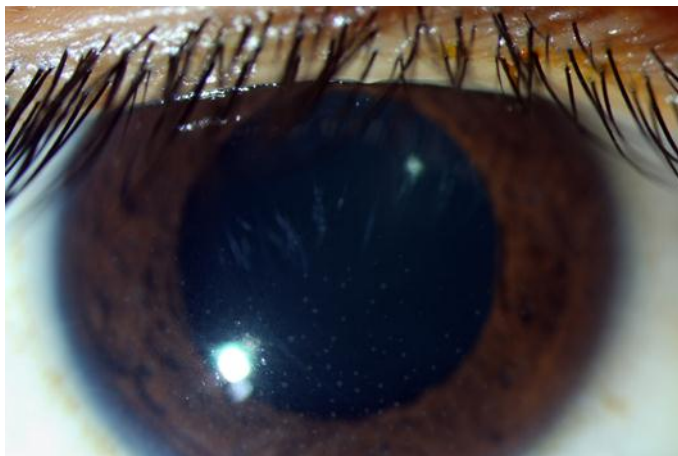


Fig. 3. Slit-lamp photo of the OD on day 15 of presentation showing keratic precipitates.

References

- 1 Brown GC, Magargal LE, Shields JA, Goldberg RE, Walsh PN: Retinal artery obstruction in children and young adults. *Ophthalmol* 1981;85:18–25.
- 2 Greven CM, Slusher MM, Weaver RG: Retinal arterial occlusions in young adults. *Am J Ophthalmol* 1995;120:776–784.
- 3 Ormerod LD, Skolnick KA, Menosky MM, Pavan PR, Pon DM: Retinal and choroidal manifestations of cat-scratch disease. *Ophthalmol* 1998;105:1024–1031.
- 4 Teitelbaum BA, Newman TL, Tresley DJ: Occlusive retinal vasculitis in a patient with West Nile virus. *Clin Exp Optom* 2007;90:463–467.

- 5 Yokoi M, Kase M: Retinal vasculitis due to secondary syphilis. *Jpn J Ophthalmol* 2004;48:65–67.
- 6 Smith JR, Cunningham ET: Atypical presentations of ocular toxoplasmosis. *Curr Opin Ophthalmol* 2002;13:387–392.
- 7 Braunstein RA, Gass JD: Branch artery obstruction caused by acute toxoplasmosis. *Arch Ophthalmol* 1980;98:512–513.
- 8 Cunningham ET Jr, Schatz H, McDonald HR, Johnson RN: Acute multifocal retinitis. *Am J Ophthalmol* 1997;123:347–357.
- 9 Gaynon MW, Boldrey EE, Strahlman ER, Fine SL: Retinal neovascularization and ocular toxoplasmosis. *Am J Ophthalmol* 1984;98:585–589.
- 10 Gentile RC, Berinstein DM, Oppenheim R, Walsh JB: Retinal vascular occlusions complicating acute toxoplasmic retinochoroiditis. *Can J Ophthalmol* 1997;32:354–358.
- 11 Haefliger E, Müller O: Branch artery occlusion due to focal necrotizing retinitis – probably caused by toxoplasmosis, article in German. *Klin Monbl Augenheilkd* 1980;176:613–618.
- 12 Iijima H, Tsukahara Y, Imasawa M: Angiographic findings in eyes with active ocular toxoplasmosis. *Jpn J Ophthalmol* 1995;39:402–410.
- 13 Küçükerdönmez C, Yilmaz G, Akova YA: Branch retinal arterial occlusion associated with toxoplasmic chorioretinitis. *Ocul Immunol Inflamm* 2004;12:227–231.
- 14 Miserocchi E, Modorati G, Rama P: Atypical toxoplasmosis masquerading late occurrence of typical findings. *Eur J Ophthalmol* 2009;19:1091–1093.
- 15 Morgan CM, Gragoudas ES: Branch retinal artery occlusion associated with recurrent toxoplasmic retinochoroiditis. *Arch Ophthalmol* 1987;105:130–131.
- 16 Pakalin S, Arnaud B: Arterial occlusion associated with toxoplasmic chorioretinitis, article in French. *J Fr Ophtalmol* 1990;13:554–556.
- 17 Theodossiadis P, Kokolakis S, Ladas I, Kollia AC, Chatzoulis D, Theodossiadis G: Retinal vascular involvement in acute toxoplasmic retinochoroiditis. *Int Ophthalmol* 1995;19:19–24.
- 18 Willerson D, Aaberg TM, Reeser F, Meredith TA: Unusual ocular presentation of acute toxoplasmosis. *Br J Ophthalmol* 1977;61:693–698.