

Bronchogenic cyst presenting as neck swelling in an adult: a case report

Shreya Bhattacharya^a, Smitha N. Vijayan^b, Subramania Iyer^a

Bronchogenic cysts are rare congenital malformations originating from budding of the tracheobronchial component during foregut development. Most cysts are located in the mediastinum and the intrapulmonary region. Localization in the cervical area is unusual. The majority of cases have been reported in the pediatric population and few cases in adults. We report an unusual case of bronchogenic cyst presenting as a deep lateral neck mass with dysphagia in an adult female. This case presented with three unusual elements: adult female, lateral cervical location, and presence of symptoms. *Egypt J Broncho* 2015 9:221–223

Introduction

Bronchogenic cysts are rare congenital malformations originating from budding of the tracheobronchial component during foregut development [1]. Most cysts are located in the mediastinum and the intrapulmonary region. Localization in the cervical area is unusual. The majority of cases have been reported in the pediatric population and few cases in adults [2]. We report an unusual case of bronchogenic cyst presenting as a deep lateral neck mass with dysphagia in an adult female.

Case report

A 48-year-old female patient with past history of Hashimoto's thyroiditis, presented with left-sided neck swelling associated with mild dysphagia. The patient had symptoms for the preceding 4 months. On examination, a diffuse cystic swelling was felt over the left supraclavicular region. The rest of the head and neck examination was normal. An ultrasonogram revealed a hypochoic cystic lesion separate from the thyroid gland. Computed tomogram of the neck and thorax showed a left lower cervical mass lesion measuring 4.7 × 4.3 cm extending from below the lower pole of the left thyroid gland and ending to the level of first costochondral junction (Fig. 1). The lesion was insinuating between the trachea and esophagus medially, displacing them to the right and the left carotid laterally, posteriorly abutting the prevertebral space. Fine needle aspiration cytology showed macrophages and lymphocytes in a background of proteinaceous material. Surgical excision of the cervicothoracic cyst was performed through a lower neck crease incision. Intraoperative findings revealed a cystic mass with thick walls deep to the carotid, between the trachea

© 2015 Egyptian Journal of Bronchology.

Egyptian Journal of Bronchology 2015 9:221–223

Keywords: bronchogenic cyst, congenital neck mass, head and neck, neck mass

Departments of ^aHead and Neck Surgery and Oncology, ^bPathology, Amrita Institute of Medical Sciences, Amrita University, Kochi, Kerala, India

Correspondence to Shreya Bhattacharya, MS, MCh (Resident), Department of Head and Neck Surgery and Oncology, Amrita Institute of Medical Sciences, Kochi - 682 041, Kerala, India. Tel: +91 484 2801234; e-mail: shreyabhattacharya15@gmail.com

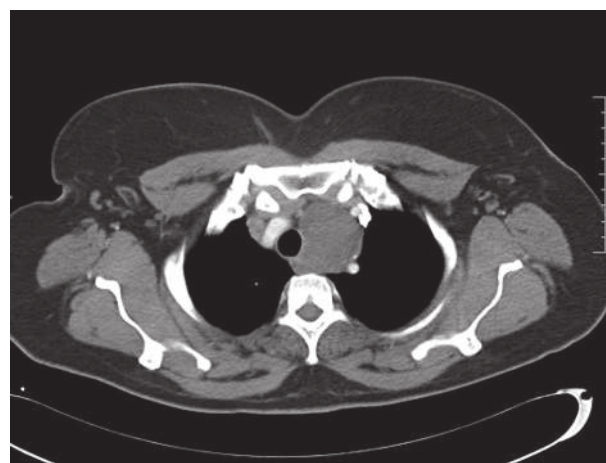Received 28 December 2014 **Accepted** 18 January 2015

and great vessels (Fig. 2). The mass was extending to the superior mediastinum. The histopathological study (Fig. 3) showed the existence of cystic lesion lined by respiratory and metastatic squamous epithelium with thickened walls containing smooth muscle, cartilage, seromucinous glands, lymphoid follicles, and hyalinized fibrocollagenous tissue. These features were compatible with the diagnosis of a bronchogenic cyst. After 1-year follow-up, the patient showed no recurrence of the lesion.

Discussion

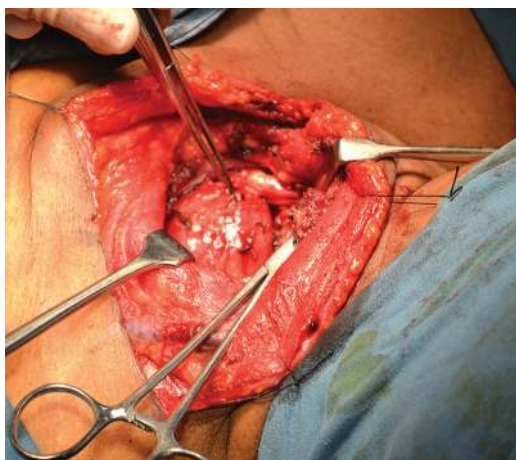Bronchogenic cysts are rare congenital malformations of ventral foregut development. During the fifth week of embryogenesis, the primitive foregut divides

Fig. 1



Computed tomogram showing the lower lateral cervical cyst extending to the mediastinum.

Fig. 2

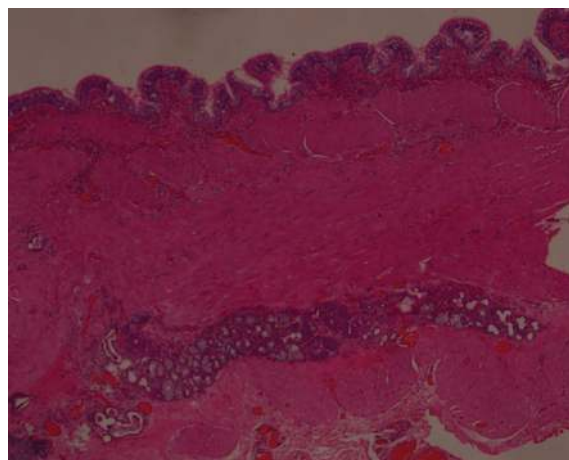


Intraoperative photograph.

into ventral trachea and dorsal esophagus. Abnormal budding of tracheobronchial tree into more than two bronchial buds can give rise to this pathology [3]. The location can be either intrathoracic or extrathoracic. Intrathoracic cysts are usually found in the mediastinum or the lung parenchyma and may remain connected to the airway [4]. In the absence of an attachment, they can migrate and occasionally get displaced anteriorly by the fusion of mesenchymal bars forming the sternum. In the extrathoracic type, a superficial presternal or suprasternal location is most common and deep neck or laterally located cysts are comparatively rare [5]. A review of the literature revealed that 75% of cervical cysts are located in the midline, whereas the rest are located in lateral lines [6]. The thyroid and paratracheal regions were more frequently affected compared with the supraclavicular region [5,6]. Other rare locations include the abdomen, diaphragm, subcutaneous tissues, and retroperitoneum [2,5]. In addition, a predilection for the male population with a ratio of 2.2 : 1.3 was found.

Cervical bronchogenic cysts are usually asymptomatic, but large cysts may cause dyspnea, cough, and dysphagia. Occasionally, secondary infection may occur, resulting in sinus tract or abscess formation. These cysts are typically unilocular, filled with mucoid content, and are not in communication with the airway. However, when a patent connection exists, the risk of developing infectious complications increases [4]. MRI is the study of choice due to its excellent soft tissue detail, which is critical in planning of surgery. In majority, MRI reveals a lesion with high-intensity signal in T1 and T2, believed to be due to the presence of proteinaceous material or blood [5]. Aspiration cytology is an alternative diagnostic tool for a neck mass. Here, the sensitivity may be low because relatively few diagnostic

Fig. 3



Histopathology: hematoxylin and eosin staining showing the thickened cyst wall with respiratory epithelial lining.

ciliated columnar epithelial cells may be scattered in the cystic components [1]. Definitive diagnosis requires histopathological confirmation. The lining of the cyst is respiratory in origin, having ciliated pseudostratified columnar epithelium overlying a fibrous connective tissue wall containing seromucinous glands, smooth muscle fibers, and cartilage [2,5,6]. The differential diagnosis includes branchial cysts, thyroglossal cysts, thymic and thyroid cysts, lymphangiomas, cystic hygromas, and dermoids [7].

Complete surgical excision remains the treatment of choice [1–8]. In addition to confirming the diagnosis, an early intervention prevents future complications such as infections, hemorrhage, compressive symptoms, and malignant transformation. In the literature, there are well-documented cases of bronchogenic cysts turning into bronchoalveolar carcinoma, adenocarcinoma, and even squamous cell carcinoma [2,4,9]. This further emphasizes the importance of total surgical excision. In adults, there are no reports of recurrences in the completely resected lesion.

Conclusion

Despite being rare, bronchogenic cysts must be considered in the differential diagnosis of all adults who present with cystic neck masses. This case presented with three unusual elements: adult female, lateral cervical location, and presence of symptoms.

Acknowledgements

Conflicts of interest

None declared.

References

- 1 Yang S, Lin M, Jan I, Lee J. Adult bronchogenic cyst of the neck presenting as large neck abscess. *Formosan J Surg* 2013; **46**:204–207.
- 2 Crespo Del Hierro J, Esteban Álvarez V, Ruiz Gonzalez M, Lopez Perez R. Cervical bronchogenic cysts. *Acta Otorrinolaringol Esp* 2013; **64**:379–381.
- 3 Hadjihannas E, Ray J, Rhys-Williams S. A cervical bronchogenic cyst in an adult. *Eur Arch Otorhinolaryngol* 2003; **260**:216–218.
- 4 Al-Kasspoles MF, Alberico RA, Douglas WG, Litwin AM, Wiseman SM, Rigual NR, *et al.* Bronchogenic cyst presenting as a symptomatic neck mass in an adult: case report and review of the literature. *Laryngoscope* 2004; **114**:2214–2217.
- 5 Moz U, Gamba P, Pignatelli U, D'Addazio G, Zorzi F, Fiaccavento S, *et al.* Bronchogenic cysts of the neck: a rare localization and review of the literature. *Acta Otorhinolaryngol Ital* 2009; **29**:36–40.
- 6 Ustundag E, Iseri M, Keskin G. Cervical bronchogenic cysts in head and neck region. *J Laryngol Otol* 2005; **119**:419–423.
- 7 Ibáñez Aguirre J, Marti Cabane J, Bordas Rivas JM, Valenti Ponsa C, Erro Azcárate JM, de Simone P. A lump in the neck: cervical bronchogenic cyst mimicking a thyroid nodule. *Minerva Chir* 2006; **61**:71–72.
- 8 Calzada AP, Wu W, Salvado AR, Lai CK, Berke GS. Poorly differentiated adenocarcinoma arising from a cervical bronchial cyst. *Laryngoscope* 2011; **121**:1446–1448.
- 9 Jakopovic M, Slobodnjak Z, Krizanac S. Large cell carcinoma arising in bronchogenic cyst. *J Thorac Cardiovasc Surg* 2005; **130**:610–612.