

Case Reports

Caesarean Scar Pregnancy - A Rare Case Report

RAZIA SULTANA¹, SAIFUL ISLAM², NURJAHAN³

Abstract:

Objective: The aim is to publish the case report of the rarely occurring and life threatening ectopic pregnancy developing in a Caesarean section scar causing uterine rupture.

Methods and Results: This patient was diagnosed initially as a case of incomplete abortion. Other possible diagnoses were molar pregnancy, mass in the cervix. She was admitted in hospital for evacuation and curettage. During the procedure she developed severe pervaginal bleeding leading to hypovolumic shock. So decision was taken for emergency laparotomy. After opening the abdomen rupture was found in the lower uterine segment extending upto upper part of cervix. So hysterectomy was performed and histopathology confirmed the diagnosis of ectopic pregnancy that developed in a Caesarean section scar. Analysis of the women's obstetric history revealed that she had been previously operated because of breech presentation.

Conclusion: Heightened awareness of the possibility of pregnancy in caesarean scar and early diagnosis by means of transvaginal sonography along with colour doppler can improve outcome and minimize the need for emergency extended surgery.

Key words: Caesarean scar Pregnancy(CSP), Transvaginal ultrasound, Total Abdominal Hysterectomy (TAH).

Introduction:

Implantation of a pregnancy within a Caesarean fibrous tissue scar also known as intramural pregnancy is considered to be the rarest form of ectopic pregnancy and a life threatening condition¹. This is because of the very high risk for uterine rupture and all the maternal complications related to it^{1,2,3}. Caesarean scar pregnancy is a rare form of ectopic pregnancy where the gestation sac is surrounded by myometrium and fibrous tissue of scar from the previous caesarean section separated from endometrial cavity and endocervical canal^{4,5}. Caesarean scar pregnancies (CSPs) are more commonly seen today, both in the East and the West, as a result of a significant increase in the proportion of Caesarean deliveries over the last three decades⁶. It is often misdiagnosed as Molar pregnancy or Inevitable Abortion and can be associated with massive hemorrhage and pervaginal bleeding leading to uterine rupture. Here a case of Caesarean scar pregnancy is reported who presented with history of caesarean section, amenorrhea and pervaginal bleeding. Dilatation and curettage was planned but

during the operative procedure profuse bleeding started leading to hypovolaemic shock which was managed by blood transfusion and venesection. After recovering from shock emergency laparotomy was done followed by Total Abdominal Hysterectomy as life saving procedure. Postoperative period was uneventful and the patient was discharged on 8th postoperative day. Early diagnosis is important as caesarean scar pregnancy is associated with life threatening complications such as uterine rupture, massive hemorrhage and the need for hysterectomy with subsequent loss of fertility.

Case History

Mrs. X a young lady, 25 year old, mother of one child with history of caesarean section presented with history of amenorrhea for about 8 weeks, with mild pervaginal bleeding for two months. She was diagnosed initially as a case of incomplete abortion. She underwent ultrasonography of pelvic organs giving the differential diagnosis of molar pregnancy, mass in the cervix or incomplete abortion. She was admitted in hospital for evacuation and curettage.

1. Junior Consultant, Dept. of Obs & Gynae, Islami Bank Hospital Khulna
2. Asst. Professor, Dept. of Obs & Gynae, Khulna Medical College Hospital.
3. Medical Officer, Islami Bank Hospital, Khulna.

During the procedure she developed severe pervaginal bleeding leading to hypovolaemic shock. She was managed by blood transfusion & venesection. So decision was taken for emergency hysterectomy. After transfusion of 5 units of blood she underwent total abdominal hysterectomy. On laparotomy, there was a longitudinal rupture on the lower part of body of the uterus including the upper part of cervix and there was moderate amount of clotted blood present in the uterine cavity. Urinary bladder was intact. Postoperative period was uneventful. On 8th postoperative day the patient was discharged. Histopathology report confirmed the diagnosis of ectopic pregnancy that developed in the previous caesarean scar area.

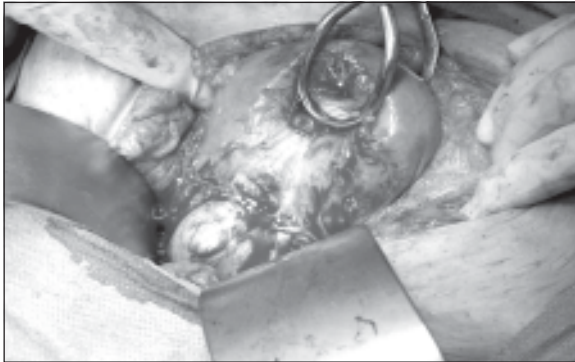


Fig.-1: Showing laparotomy findings of caesarean scar pregnancy

Discussion:

Pregnancy within a caesarean fibrous tissue scar was first reported by Lansen and Solomon in 1978⁷ is probably the rarest of ectopic pregnancies^{8,9}. These patients often present with uterine rupture and hypovolemic shock; however, they may also present with painless vaginal bleeding^{10,11}. It may constitute a life threatening condition because of its high risk for massive vaginal bleeding and uterine rupture^{12,13}. Predisposing risk factors include prior uterine trauma, caesarean section and adenomyosis^{14,15}. The true incidence of pregnancy in scar has not been determined because so few cases have been reported in the literature: there are only 18 published cases in the English medical literature between 1978 and 2001². In the last decade, it has been encountered more frequently worldwide. The increased number of cases may reflect the greatly increased incidence of caesarean deliveries and the adoption of transvaginal ultrasound or Colour

Doppler imaging in recent years^{16,17}. Caesarean scar pregnancy is diagnosed on patients having amenorrhoea and a history of prior caesarean section. Diagnosis is based on sonographic and Doppler flow findings: (a) an empty uterus and cervical canal; (b) The gestational sac is located in the anterior part of the isthmus of the uterus with a diminished myometrial layer between the bladder and sac, (c) A discontinuity in the anterior wall of the uterus¹⁸. Most patients diagnosed with caesarean scar pregnancy are managed using one of the following Primary treatments: Dilatation, Evacuation and Curettage (DE&C), systemic and local Methotrexate and Uterine Artery Embolization (UAE) and conservative surgical treatment. Excision of the gestational sac followed by repair of the caesarean scar defect using by Laparotomy or Laparoscopy, has emerged a conservative therapy¹⁹, however the operation still carries a significant risk of uncontrolled hemorrhage, leading to hysterectomy and loss of reproductive function in some patients²⁰.

The diagnosis is important as caesarean scar pregnancy (CSP) is associated with life threatening complications such as uterine rupture, massive hemorrhage and the need for hysterectomy with subsequent loss of fertility²¹⁻²³. Although the exact mechanism of CSP is not known, it is believed that a highly possible predisposing factor for CSP is a micro tubular tract between the caesarean section scar and the endometrial canal. This tract is developed from the trauma of uterine surgery²⁴. Another risk factor for scar implantation in the subsequent pregnancy may occur because of increased scar surface area. Thus conservative medical treatment, curettage and hysteroscopy that leave the uterine defect unrepaired may potentially cause the recurrence of CSP²⁵. Therefore transvaginal surgery for caesarean scar pregnancy appears to be effective, safe and minimally invasive surgical treatment to remove ectopic pregnancy tissue and repair the underlying defect^{16,17}. Ultrasonography is useful for diagnosing CSP. Because outcomes and treatment may differ, CSP must be distinguished from other types of abnormally implanted pregnancies. Caesarean scar pregnancy is different from intrauterine pregnancy with placenta increta or percreta in that it is more aggressive, occurs in the first trimester and involves the complete embedding of the gestational sac in the myometrium. Valley et al⁹ reported a case confirmed

by MRI which also demonstrated that no normal endometrium existed between gestational sac and the bladder wall. Strict imaging criteria must be used in performing the diagnosis—an empty uterus, empty cervical canal, development of the sac in the anterior part of the isthmic portion and an absence of healthy myometrium between the bladder wall and the gestational sac. A retrospective cohort study was done in University hospital in China to determine the efficacy of Uterine Artery Embolisation (UAE) combined with local Methotrexate (MTX) for the treatment of Caesarean scar pregnancy between Jan 2003 and Dec 2008 and they concluded that UAE with local MTX is of benefit to women wishing to preserve fertility, and is suitable for use as a primary treatment of caesarean scar pregnancy²⁶. Because of difficult diagnosis and probably delayed treatment this patient developed complication resulting extended surgery with loss of fertility.

Conclusion:

Caesarean scar pregnancy is one of the causes of maternal morbidity. Accurate diagnosis made by ultrasonography and Doppler is obligatory for conservative medical and surgical management.

References:

- Bernstein H B, Thrall M, Clark W. Expectant management of intramural ectopic pregnancy. *ObstetGynecol* 2001; 97(2): 826-827
- Fylstra DL Ectopic pregnancy within a Caesarean scar: a review, *ObstetGynecol* 2002; 57: 537-43.
- Jurkovic D, Hillaby K, Woelfer B, Lawrence A, Saim R, Elson CJ, First trimester diagnosis and management of pregnancies implanted into the lower uterine segment Caesarean section scar. *Ultrasound ObstetGynecol* 2003; 21: 220-7
- C. M. Yan, "A report of four cases of caesarean scar pregnancy in a period of 12 months," *Hong Kong Medical Journal*, 2007; 13(2): 141–143.
- Coniglio C, Dickinson JE. Pregnancy following prior Caesarean scar pregnancy rupture: lessons for modern obstetric practice. *Aust N Z J Obstet Gynaecol* 2004; 44: 162–6.
- Ash A, Smith A, Maxwell D. Caesarean scar pregnancy. *BJOG* 2007; 114: 253–263
- Larsen JV, Solomon MH, Pregnancy in a uterine scar sacculus- an unusual case of post abortal haemorrhage. *S Afr Med J* 1978 ; 53: 142-3.
- Lee C L, Wang C, Chao A, Yen C-F, Soong Y-K. Laparoscopic management of an ectopic pregnancy in a previous caesarean section scar. *Hum Reprod* 1999; 14(5): 1234-1236
- Armstrong V, Hansen WF, Van Voorhis BJ and Syrop CH. Detection of Caesarian scars by transvaginal ultrasound. *ObstetGynecol* 2003; 101: 61–65.
- Vial Y, Petgnat P, Hohlfield P, Pregnancy in a caesarean scar. *Ultrasound ObstetGynecol* 2000; 16: 592-3.
- Jiao L-Z, Zhao J, Wan XR, Liu XY, Feng F, Ren T, et al. diagnosis and Treatment of caesarean Scar Pregnancy. *Chin Med Sci J* 2008, 23: 10-5.
- Herman A, Weinraub A, Avrecho, Maymon R, Ron El, Bukovsky Y. Follow up and outcome of isthmic pregnancy located in a previous caesarean section scar. *Br. J ObstetGynecol* 1995; 102: 839-4.
- Katano K, Ikuta K, Matsubara H, Oya N, Nishio M, Suzumori K. A case of successful chemotherapy for intramural pregnancy. *FertilSteril* 1999; 72: 744-746
- Khalifa Y, Redgment C J, Yazdani N, Taranissi M, Craft I L. Pregnancy. Intramural pregnancy following difficult embryo transfer. *Hum Reprod* 1994; 9: 2427-2428
- Rotas MA, Habermans, Levgar M. Caesarean scar ectopic Pregnancies: Etiology, Diagnosis and Management. *ObstetGynecol* 2006; 107: 1373-81.
- Maymon R, Halperin R, Mendlovic S, Schneider D, Vaknin Z, Herman A, et al. Ectopic pregnancies in caesarean section scar: the 8 year experience of one medical center. *Hum Reprod* 2004; 19: 278-84.
- Bregar AT, Cerar VM, Slaver ZZ, Verdenik I. Indications for caesarean deliveries between 1955 and 2005. *Wein Kin Wochenschr* 2008; 120: 161-5.

18. Eskew PN Jr, Sayweli RM, Zollinger TW, ERner BK, OserTh , Trends in the frequency of caesarean delivery. A 21 year experience, 1970-1990, *JReprod Med* 1994; 39: 809-17.
19. Graesslin O, Dedecker F, Quereux C, Gabriel R. Conservative treatment of ectopic pregnancy in a cesarean scar. *ObstetGynecol* 2005; 105(4): 869-871
20. Haswgawa J, Ichizuka K, Matsuoka R, Otsukik, Sekizawa A, Okait. Limitations of conservative treatment for repeat Caesarean scar pregnancy. *Ultrasound ObstetGynecol* 2005; 25: 310-1.
21. Wang Y, Sut, Chen H. Operative laparoscopy copy for unrupture dectopi pregnancy in a Caesarean scae. *BJOG* 2006; 113: 1035-8.
22. Wang CJ, Chao AS, Yeoun LT, Wang CW, Soong YK, Leec L. Endoscopic management of caesarean scar pregnancy. *FertilSteril*. 2006; 85: 49.
23. Valley M T, Pierce J G, Daniel T B, KaunitzA M. Cesarean scar pregnancy: imaging and treatment with conservative surgery. *ObstetGynecol* 1998; 91(5): 838-840
24. Kucera E, Helbich T, Sliutz G, Joura E A. The modern management of interstitial or intramural pregnancy—is MRI an “alloyed” diagnostic gold standard or the real thing?. *FertilSteril* 2000; 73(5): 1063-
25. Jin H, Zhou J, Yu Y, Dong M. Intramural pregnancy, a report of two cases. *J Reprod Med* 2004; 49(7): 569-572
26. X-Y Yang, H Yu, K Mli, Y-Y Chu, A Zheng. Uterine artery embolisation combined with local Methotrexate for treatment of caesarean scar Pregnancy, *I J Obstet and Gynecol (BJOG)*. 2010; 117: 990-996.