

Can Lung Ultrasound Replace Chest Radiography for the Diagnosis of Pneumonia in Hospitalized Children?

Francesca Reali^a Giuseppe Francesco Sferrazza Papa^a Paolo Carlucci^a
Paola Fracasso^a Fabiano Di Marco^a Marzia Mandelli^b Simone Soldi^c
Enrica Riva^b Stefano Centanni^a

^aRespiratory Unit, Dipartimento Scienze della Salute, ^bPediatric Department, and ^cU.O. Radiodiagnostica, San Paolo Hospital, Università degli Studi di Milano, Milan, Italy

Key Words

Community-acquired pneumonia · Lung sonography · Pediatric pneumonia · Ultrasonography

Abstract

Background: Lung ultrasound is a non-radiating accurate alternative tool to chest X-ray (CXR) in the diagnosis of community-acquired pneumonia (CAP) in adults. **Objectives:** The aim of our study was to define the accuracy of ultrasound in the diagnosis of CAP in children. **Methods:** 107 consecutive children with suspected CAP underwent clinical examination, blood sample analysis, CXR and lung ultrasound on admission to the Pediatric Department of the San Paolo Hospital. The diagnosis of pneumonia was made by an independent committee of physicians on the basis of the overall clinical and CXR data. **Results:** The diagnosis of CAP was confirmed by the committee in 81 patients (76%). Ultrasound and CXR were performed in all patients. Ultrasound had a sensitivity of 94% and specificity of 96%, while CXR showed a sensitivity of 82% and a specificity of 94%. In patients with CAP, ultrasound revealed subpleural consolidations with air bronchogram in 70 cases and focal B-lines in 6. A parapneumonic pleural effusion was detected in 17 patients by ultra-

sound, while only 11 of them could be detected by CXR. **Conclusions:** In our series, lung ultrasound was highly accurate for the diagnosis of CAP in hospitalized children. These results provide the rationale for a multicenter study in children.

© 2014 S. Karger AG, Basel

Introduction

Community-acquired pneumonia (CAP) is a leading cause of illness in children. For inpatients with suspected pneumonia, the diagnosis is confirmed by chest X-ray (CXR) executed in a single view to reduce radiologic exposure [1]. Serious concerns have been raised regarding the carcinogenic risk due to radiation exposure in children [2]. This alarm refers mainly to computed tomography (CT), but a safe dose in childhood is difficult to establish due to the latency of radiation exposure effects. Other concerns with radiography are poor patient cooperation and lack of reproducibility [3]. Lung sonography is a non-radiating imaging tool. It has been shown that

F.R. and G.F.S.P. contributed equally to this work.

lung ultrasound helps to identify subpleural lung consolidation in pneumonia [4], and, recently, a multicenter study proved the accuracy of the technique in the sonographic diagnosis of CAP in adults [5]. In our respiratory ward, we routinely perform lung ultrasound as consultants for the Pediatric Department. Albeit only preliminary reports exist in this population, some technical advantages (e.g. a thinner chest wall) theoretically enable an accurate detection of lung consolidations in children [6]. We designed a study to define the accuracy of lung ultrasound in the diagnosis of CAP in hospitalized children. We furthermore investigated the potential role of ultrasound in the diagnosis of parapneumonic pleural effusions in children.

Materials and Methods

Study Design and Setting

This was a prospective diagnostic accuracy study conducted in the Pediatric Department of the San Paolo Hospital, University of Milan. Inclusion criteria were: fever and/or clinical signs suggesting pneumonia in a previously healthy child examined between April 1 and December 31, 2011 [1]. This study was approved by the local ethics committee (San Paolo Hospital). We included patients aged ≤ 16 years. All patients underwent clinical examination, CXR, lung ultrasound and blood sample analysis in the first 24 h after admission. For ethical reasons, it was impossible to perform CT as a gold standard; therefore, the final diagnosis of pneumonia was made by an independent committee composed of a pulmonologist and a pediatrician according to Caiulo et al. [7]. This committee stated the final diagnosis on the basis of clinical history and course, CXR and blood sample analysis according to the guidelines of the British Thoracic Society [1]. CXR was performed with commercially available X-ray machines. As suggested by the guidelines, lateral radiographs were not routinely performed [1]. CXRs were interpreted by a pediatric radiologist blinded to the sonography results. Lung ultrasound was randomly carried out by a member of the research team (a pulmonologist and two residents) with a background of at least 100 procedures performed [5]. The examination was performed with the patient sitting upright or supine (or held by a parent according to compliance) using a standard ultrasound system (Mylab 25; Esaote, Genoa, Italy) in B-mode connected to a linear probe (7.5–10 MHz) according to a predefined scanning protocol, and findings were standardized in patterns according to a study by Caiulo et al. [8]. Anterior intercostal spaces were examined in longitudinal sections along the parasternal, midclavicular, anterior and midaxillary lines, and transversal sections from the second to the fifth intercostal space. Posteriorly, longitudinal sections were along the paravertebral, scapular and posterior-axillary lines, while transversal scans were obtained below the scapular spine. Ultrasound preset was optimized for soft tissue studies. Patterns were standardized as: normal (lung sliding with A-lines); consolidation (subpleural echo-poor or tissue-like structures); white lung and focal B-lines (coalescent B-lines forming areas of white lung and presence of multiple focal B-lines); pleural line abnormalities (ir-

regular appearance of the pleural line), and pleural effusion (echo-free or hypoechoic fluid space between the visceral and parietal pleura). The examiner was aware of the clinical suspicion but blinded to CXR.

Analysis

Demographic data are reported as means (SD) for continuous normal data. Ordinal and discrete variables are described as counts and proportions. We performed descriptive statistics and calculated ultrasonography and CXR test performance characteristics with sensitivity and specificity. The data analysis and test performance characteristics were elaborated using commercially available software (SPSS version 16.0 for Windows; SPSS Inc.).

Results

Of the 107 consecutive patients enrolled (aged 4 ± 3 years, mean \pm SD, 46 females), a final diagnosis of CAP was confirmed in 81 patients (76%) by the independent committee. Identified infectious agents, expressed in percentages of all confirmed pneumonias, were: *Streptococcus pneumoniae* 16%, *Mycoplasma pneumoniae* 16%, *Chlamydia pneumoniae* 10% and viruses 20%. Every patient underwent ultrasound and CXR. The patient's position was supine in 38%; 42% of the patients were sitting upright and 20% of the children were held by a parent. The mean execution time was 10 min. CXR was performed in 52% in the upright position, and the examination was judged positive for pneumonia in 66 children (sensitivity 82%), whilst ultrasound identified signs of pneumonia in 76 patients (sensitivity 94%; table 1). In the group of patients with pneumonia, 15 patients had a negative CXR (false negatives) and 5 had a negative ultrasound, resulting in a specificity of 92 versus 96%, respectively. In patients with a final diagnosis of CAP, sonographic findings were subpleural consolidation with dynamic air bronchogram in 70 patients (fig. 1) and focal B-lines in 6 patients (fig. 2); CXR detected 11 cases of parapneumonic pleural effusion of the 17 cases (21%) identified by ultrasound (internationally judged the gold standard), with a resulting sensitivity of CXR of 65%. The only sonographic false-positive result was a child affected by respiratory syncytial virus-related bronchiolitis in which ultrasound detected a small subpleural consolidation. There were two radiographic false-positive results. A left basal consolidation was found in a chest X-ray executed in a single view on admission. Due to the absence of fever and respiratory symptoms, radiography was repeated in two projections and resulted normal, and the commission judged the case based on the results of a composite image. The other case was a pleural effusion that

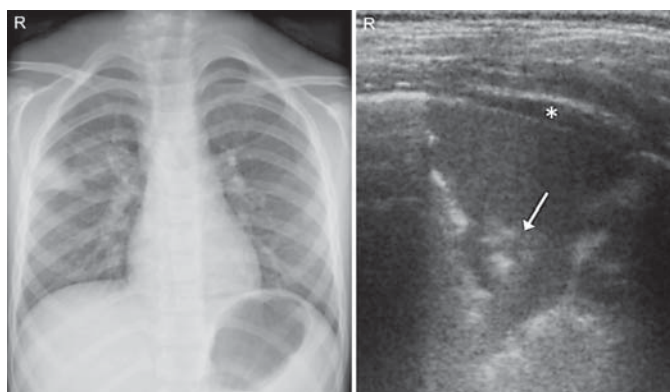


Fig. 1. A 5-year-old male with fever, cough and pleuritic chest pain. CXR was performed in posteroanterior view. Sonography was performed in the upright position with a linear probe (7.5 MHz) in B-mode. Radiography and ultrasound confirmed the diagnoses of pneumonia by showing a subpleural lung consolidation, and a transversal sonographic scan revealed a consolidation with air bronchogram (white spots highlighted by the arrow) and a minimal pleural effusion (asterisk). R = Right side. 70 kV; 2 mAs.

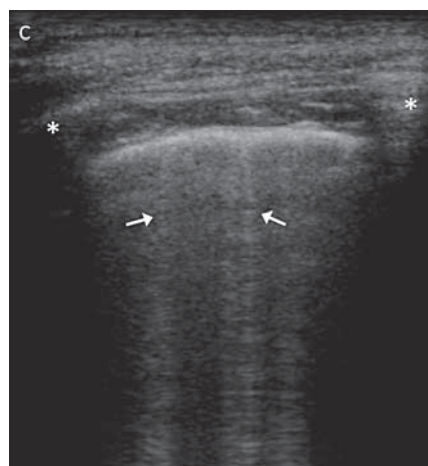


Fig. 2. A 13-year-old male with fever and productive cough. A sagittal sonographic scan of the right fourth intercostal space on the midclavicular line was performed in the upright position using a linear transducer (7.5 MHz) in B-mode. Focal B-lines are highlighted by arrows. This finding represents the sonographic appearance of perilesional inflammatory edema. The asterisks mark the upper and lower rib. C = Cephalic.

appeared as a consolidation on CXR. The patient had a spike of fever but no other symptoms, and he had recovered from a recent pneumonia; sonography (the gold standard for pleural effusions) confirmed a pleural effusion.

CT was performed in 4 patients with severe disease for clinical purposes (pneumonia complicated with pleural effusion or respiratory failure); in all these patients both radiography and sonography were positive for pneumonia.

Discussion

This study presents the largest series of children hospitalized for CAP studied with sonography and confirms the non-inferiority of lung ultrasound in the diagnosis of CAP compared to CXR. Our data correspond to those of the recent literature. Copetti and Cattarossi [6] reported the reliability of the sonographic diagnosis of pneumonia in 79 children with suspected pneumonia. The main concern of their study was the lack of a gold standard albeit CT was performed in patients with positive ultrasound and negative CXR. Caiulo et al. [7, 8] described sonographic features of CAP and bronchiolitis in hospitalized children. Lung ultrasound resulted positive in the diag-

Table 1. Baseline radiographic and sonographic findings in children according to the final diagnosis

	Patients with pneumonia			Patients without pneumonia		
	CXR+	CXR-	total	CXR+	CXR-	total
US+	61	15	76	0	1	1
US-	5	0	5	2	23	25
Total	66	15	81	2	24	26

The diagnosis of pneumonia was confirmed by an independent committee composed of a pulmonologist and a pediatrician on the basis of clinical history and course, radiography and blood sample analysis. US = Lung ultrasound; + = positive test results; - = negative test results.

nosis of pneumonia in 88 of 89 patients with CAP. Notably, in their study concerning bronchiolitis, ultrasound found subpleural lung consolidations in 44 of 52 patients affected by this disease. In our series, the only sonographic false-positive result was affected by bronchiolitis with small lung consolidations. Although the study was conceived as non-inferiority, sensitivity seems to be higher for ultrasound than radiography (94 vs. 82%). This may result from the summation image of different tissues of

the latter while sonography permits a dynamic analysis of every intercostal space during breathing. In 5 patients with pneumonia, no consolidations were detected by ultrasound. Two of these patients had paracardiac consolidations, 2 others were in the scapular area and 1 was in the medial lobe but not reaching the pleura. This is in line with the recent literature; in a multicenter study in adults with CAP, Reissig et al. [5] escaped 8% of the patients due to the same reasons (central consolidations). It seems very likely to be the actual limit of the technique, which may be overcome by integrating cardiac and abdominal scans of the lung through the diaphragm to the intercostal approach. However, there were 15 radiographic false-negative results due to the poor sensitivity of the technique for small subpleural consolidations. Recently, Shah et al. [9] published a diagnostic study on point-of-care ultrasound for the diagnosis of pneumonia in children and young adults. Although interesting, this study was affected by a low incidence of pneumonia in the population

study (18%). A limitation of our study is its single-center design. However, results are in agreement with other single-center studies in similar populations. Furthermore, in a multicenter study, Reissig et al. [5] and Reissig and Copetti [10] provided similar results with a sensitivity of 93% and a specificity of 98% for the sonographic diagnosis of pneumonia.

In conclusion, our preliminary study confirms the high accuracy of lung ultrasound in the diagnosis of CAP in hospitalized children. Albeit the title question remains at present unsolved outside reference centers, these data may represent a rationale for future multicenter studies on this issue.

Acknowledgments

The authors would like to express their sincere appreciation to Dr. Giulia M. Pellegrino for her assistance in writing this paper.

References

- 1 Harris M, Clark J, Coote N, Fletcher P, Harneden A, McKean M, Thomson A: British Thoracic Society guidelines for the management of community acquired pneumonia in children: update 2011. *Thorax* 2011;66(suppl 2): ii1–ii23.
- 2 Brenner DJ, Hall EJ: Computed tomography – an increasing source of radiation exposure. *N Engl J Med* 2007;357:2277–2284.
- 3 Davies HD, Wang EE, Manson D, Babyn P, Shuckett B: Reliability of the chest radiograph in the diagnosis of lower respiratory infections in young children. *Pediatr Infect Dis J* 1996;15:600–604.
- 4 Reissig A, Kroegel C: Sonographic diagnosis and follow-up of pneumonia: a prospective study. *Respiration* 2007;74:537–547.
- 5 Reissig A, Copetti R, Mathis G, Mempel C, Schuler A, Zechner P, Aliberti S, Neumann R, Kroegel C, Hoyer H: Lung ultrasound in the diagnosis and follow-up of community-acquired pneumonia. A prospective multicentre diagnostic accuracy study. *Chest* 2012;4:965–972.
- 6 Copetti R, Cattarossi L: Ultrasound diagnosis of pneumonia in children. *Radiol Med* 2008; 113:190–198.
- 7 Caiulo VA, Gargani L, Caiulo S, Fisicaro A, Moramarco F, Latini G, Picano E, Mele G: Lung ultrasound characteristics of community-acquired pneumonia in hospitalized children. *Pediatr Pulmonol* 2013;48:280–287.
- 8 Caiulo VA, Gargani L, Caiulo S, Fisicaro A, Moramarco F, Latini G, Picano E: Lung ultrasound in bronchiolitis: comparison with chest X-ray. *Eur J Pediatr* 2011;170:1427–1433.
- 9 Shah VP, Tunik MG, Tsung JW: Prospective evaluation of point-of-care ultrasonography for the diagnosis of pneumonia in children and young adults. *JAMA Pediatr* 2013;167: 119–125.
- 10 Reissig A, Copetti R: Lung ultrasound in community-acquired pneumonia and in interstitial lung diseases. *Respiration* 2014;87:179–189.