

CLINICAL NOTE

Can the vicious cycle of obscure or intractable gastrointestinal bleeding be broken in patients with atrial fibrillation subject to anticoagulant therapy? The role of percutaneous left atrial appendage closure

Diego Fernández-Rodríguez¹, Victoria Martín-Yuste^{1,3}, Faust Feu², Salvatore Brugaletta¹, Xavier Freixa^{1,3}, Ander Regueiro¹ and Manel Sabaté¹

Departments of ¹Cardiology and ²Digestive Diseases. Instituto del Tórax. ³Unitat de Fibril·lació Auricular. Hospital Clínic. Barcelona, Spain

ABSTRACT

Gastrointestinal bleeding of obscure origin or with an intractable cause is particularly common in patients with atrial fibrillation subject to oral anticoagulant therapy. This condition is highly recurrent and therefore gives rise to high morbidity and mortality rates, thus entailing a vicious cycle that is difficult to solve.

Percutaneous left atrial appendage closure has become a therapeutic alternative for patients with atrial fibrillation and a contraindication for oral anticoagulation. This technique would allow the discontinuation of oral anticoagulants, thus helping to reduce the risk for gastrointestinal bleeding, and would also be protective against embolic events in this group of patients, thereby eventually breaking this vicious cycle.

We report our experience with percutaneous left atrial appendage closure in the management of patients with atrial fibrillation who are subject to oral anticoagulation therapy and suffer from obscure or intractable gastrointestinal bleeding.

Key words: Atrial fibrillation. Oral anticoagulants. Obscure gastrointestinal bleeding. Intractable gastrointestinal bleeding. Percutaneous left atrial appendage closure.

INTRODUCTION

Obscure gastrointestinal bleeding (OGIB) is a condition clustering together all gastrointestinal bleedings (GIBs)

Fernández-Rodríguez D, Martín-Yuste V, Feu F, Brugaletta S, Freixa X, Regueiro A, Sabaté M. Can the vicious cycle of obscure or intractable gastrointestinal bleeding be broken in patients with atrial fibrillation subject to anticoagulant therapy? The role of percutaneous left atrial appendage closure. Rev Esp Enferm Dig 2014;106:350-353.

Received: 05-12-2013
Accepted: 24-02-2014

Correspondence: Victoria Martín-Yuste. Department of Cardiology. Instituto del Tórax. Hospital Clínic. c/ Villarroel, 170. 08036 Barcelona, Spain
e-mail: vmartiny@clinic.ub.es

secondary to causes that cannot be pinned down following attentive endoscopic and radiographic examinations (1). It is a condition particularly common in patients subject to therapy with oral anticoagulants (OACs) (1,2).

The management of patients with atrial fibrillation (AF) and high embolic risk who develop GIB and require treatment with OACs is not well established. The most common practice involves the performance of a comprehensive GI tract examination to elucidate the underlying disease and provide an appropriate etiologic therapy. OACs are usually reintroduced following stabilization; however, in a high percentage of patients relapse rates are high, either because no clear cause for GIB can be found or because its origin cannot be fully treated (e.g., when multifocal angiodysplasia is present) (2,3). Furthermore, relapsing bleeding results in multiple hospitalizations and is associated with high morbidity and mortality (2,4).

The primary origin of embolic events in patients with AF is the left atrial appendage (LAA) (5,6). It is for this reason that the percutaneous closure thereof together with OAC withdrawal may be considered an alternative therapeutic approach as it is protective against embolic events and concurrently decreases the risk for GIB. Several studies involving a number of devices are witness to this (6-9).

The goal of our paper is to describe our experience with percutaneous LAA closure using a device approved by regulatory authorities ("CE mark") for the management of this group of patients -the Amplatzer™ Cardiac Plug (ACP) device (Saint Jude Medical, St. Paul, USA).

CASE REPORTS

Between February 2012 and January 2013 four patients were selected to undergo percutaneous LAA closure using the ACP device after signing their informed consent according to a protocol previously established in our site. All four patients exhibited well-controlled anticoagulation

levels, and all had undergone multiple admissions requiring multiple transfusions. All were subjected to a comprehensive etiologic study including fiber gastroscopy, fiber colonoscopy, and capsule endoscopy on one or several occasions. Also, the patients were not considered eligible for treatment with lanreotide or thalidomide for the management of recurrent GIB.

Case report 1 was an 82-year-old woman with a history of high blood pressure (HBP), diabetes mellitus (DM), dyslipidemia, aortic valve replacement with a biological prosthesis, chronic iron-deficiency anemia, and AF with high embolic risk. The patient had a high AF-related embolic risk score (CHA₂DS₂VASc score: 5). The etiologic study demonstrated angiodysplasia lesions in the stomach, duodenum, and mid/distal jejunum that required repeated argon-beam applications, despite which GIB events persisted and made hospital admission necessary on four occasions.

Case 2 report was a 79-year-old woman with a history of HBP, DM, dyslipidemia, peripheral vasculopathy, chronic iron-deficiency anemia, and AF with high embolic risk (CHA₂DS₂VASc score: 6). Capsule endoscopy demonstrated multiple angiodysplasia lesions (duodenum, proximal jejunum, distal ileum) which resulted in persistent GIB despite multiple argon beam sessions. The patient required hospitalization for bleeding events on three occasions.

Case 3 was a 69-year-old male with a history of HBP, DM, dyslipidemia, mitral valve replacement with a biological prosthesis, chronic iron-deficiency anemia, and AF with high embolic risk (CHA₂DS₂VASc score: 3). An etiologic study revealed no specific origin for his bleeding during the two hospitalizations the patient required.

Case 4 was an 86-year-old woman with a history of HBP, dyslipidemia, cerebrovascular accident (CVA) with resolution ad integrum, ischemic heart disease, peripheral vasculopathy, chronic iron-deficiency anemia, and AF with high embolic risk (CHA₂DS₂VASc score: 7). The patient required admission to hospital on three occasions but diagnostic studies could not reveal the origin of GIB.

All patients had OACs withdrawn three days before implantation. The procedure was performed using general anesthesia, with prophylaxis against bacterial endocarditis, and under trans-esophageal echocardiographic (TEE) and angiographic control. Using a right femoral venous access a trans-septal puncture kit was advanced into the right atrium, following which complete unfractionated heparin (UFH) doses were administered with patient body weight adjustment. Subsequently the device delivery sheath was advanced into the left atrium, and the ACP device was implanted, completely covering the LAA ostium in all cases in a stable manner, with no evidence of device migration and no complications (Fig. 1 A-D).

All patients were discharged on an indefinite aspirin regimen, clopidogrel for 3 months, and proton pump inhibitors. In addition, prophylaxis was administered per protocol against bacterial endocarditis for 6 months after device implantation in the presence of any risky instrumen-

tation. A stringent echocardiographic follow-up protocol was implemented (using TEE on discharge and at 30 days, 3 months and 6 months, and trans-thoracic echocardiography at 12 months). Clopidogrel was withdrawn in the absence of device-related thrombosis on TEE at 3 months, except for case number 2. In this patient mild thrombosis was seen associated with the ACP device on TEE at 3 months, which required two weeks of inpatient therapy with intravenous UFH that eventually solved the problem. The patient then continued on clopidogrel until the TEE examination at month 6, which confirmed the absence of device-associated thrombosis and allowed withdrawal of clopidogrel. This patient had no complications related to device-associated thrombosis. Furthermore, no other complications were seen in association with implanted devices in the remaining echocardiographic controls.

After a mean follow-up of 9.3 ± 3.2 months, patients remain asymptomatic and have required no additional admissions for GIB; also, they have had neither ischemic, hemorrhagic stroke or infectious endocarditis events, nor any procedure-related complications.

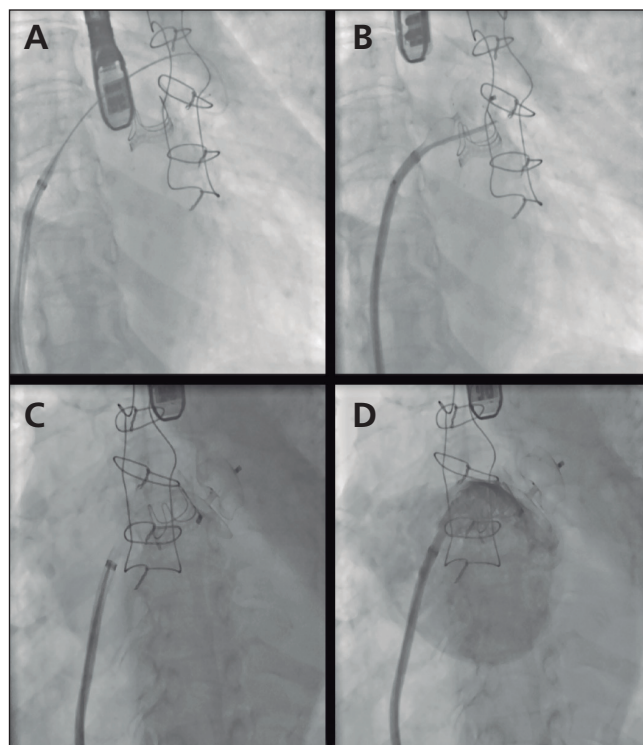


Fig. 1. Percutaneous implantation of the Amplatzer™ Cardiac Plug device for left atrial appendage (LAA) closure. A. The delivery sheath is advanced into the LAA. B. Procedure to release the self-expanding closure device within the LAA. C. The Amplatzer™ Cardiac Plug is appropriately released in the LAA. D. Control angiogram showing the appropriately placed Amplatzer™ Cardiac Plug device, now occluding the ostium of the LAA with minimal passage of contrast medium into the LAA.

DISCUSSION

The OGIB concept includes all GIB events with an unknown cause despite comprehensive endoscopic and radiographic testing including capsule endoscopy to assess the small bowel (1,10). Furthermore, capsule endoscopy is the only tool that can explore the whole GI tract in all its length, and discover smaller bleeding lesions such as angiodysplasia, which represents one of the most prevalent causes of OGIB (10).

AF is the most common type of sustained arrhythmia and also represents a major public health issue. Its prevalence increases with comorbidity and age, and may reach 5-15 % amongst the population older than 80 years of age (5). In addition, this problem will be more severe in the future as estimates anticipate prevalence twice as high within the next 50 years because of population ageing (5).

The most commonly feared complication of AF is arterial thromboembolism in association with blood stagnation inside the LAA, which represents over 90 % of emboli in these individuals (5,6). CVAs occurring in the context of AF are usually fatal, and surviving patients have severely impaired cognitive functions and quality of life (5).

The primary preventive therapy available is anticoagulation. In order to stratify the risk for CVAs among patients with valve-unrelated AF the CHA₂DS₂-VASc score was devised. This embolic risk score assigns 1 point to the presence of heart failure, HBP, DM, arterial vasculopathy, female gender, and age between 65 and 74 years, and 2 points to age \geq 75 years and a history of previous CVAs. The European Society of Cardiology guidelines (5) recommend OAC initiation in patients with a mid-to-high embolic risk (CHA₂DS₂-VASc score \geq 2).

However, in contrast with OAC benefits, patients with AF subject to OAC have a high risk of bleeding because of their anticoagulation effects. Also, the most common source of bleeding in these subjects has been found to be the GI tract (2-4), which may be responsible of up to 40 % of all bleeding events. Furthermore, severe bleeding requiring hospitalization is associated with high inpatient mortality and relapse rates (2, 4).

Given the prognostic significance of bleeding in this population, assessing bleeding risk should be an integral part of the evaluation prior to OAC onset. This is why the HAS-BLED bleeding risk score was designed for patients receiving OACs. This score assigns 1 point to HBP, abnormal renal function, abnormal liver functional, CVA, history of or predisposition to bleeding, international normalized ratio (INR) lability, age > 65 years, concomitant use of other antithrombotic agents, and alcohol abuse. A HAS-BLED score \geq 3 confers a high bleeding risk and requires more careful monitoring of INR values (5).

It is relevant to point out that both scores share a number of items, hence it is no wonder that patients with high CHA₂DS₂-VASc scores also have high HAS-BLED scores, and vice versa. Because of this, it is precisely patients with

a higher risk for embolic events that also have a higher risk for bleeding (11).

Given that this group of patients has a highly increased embolic risk, the strategy of withdrawing OACs for patients with AF having suffered from bleeding episodes would expose them to a too high risk for embolism and should not therefore be used. The fact that newer anti-coagulants have not solved this quandary should also be highlighted here, as the prevalence of GIB with these drugs (e.g., dabigatran) has been seen to be the same or even higher than with traditional OACs (Sintrom®) (5, 12).

There is, therefore, a group of patients with high embolic risk and a concurrent high risk for GIB for whom there was no effective, safe treatment. Since the most common source of embolism in patients with AF is the LAA, its percutaneous closure together with OAC withdrawal seems an appealing strategy for these patients and offers a dual benefit: a) Avoidance of new GIB events; and b) protection against embolic episodes.

Our short, prospective case series of patients undergoing percutaneous LAA closure using the ACP device showed that the vicious cycle of OGIB may be broken with this new endovascular therapy, which prevents readmission for GIB and at the same time protects patients against embolic events. These fine initial results suggest that our strategy (Fig. 2) may be appropriate in this clinical setting, and deserves further confirmation by future clinical trials.

A number of studies have shown the feasibility of implantation, and the efficacy and safety of the various devices intended for LAA closure (6-9); however, none was performed in this specific group of patients. The ELI-GIBLE study (NCT01628068), currently ongoing, will be the first trial to specifically assess the effectiveness and safety of percutaneous LAA closure in this type of patients. This study will shed light on the most appropriate management for this population.

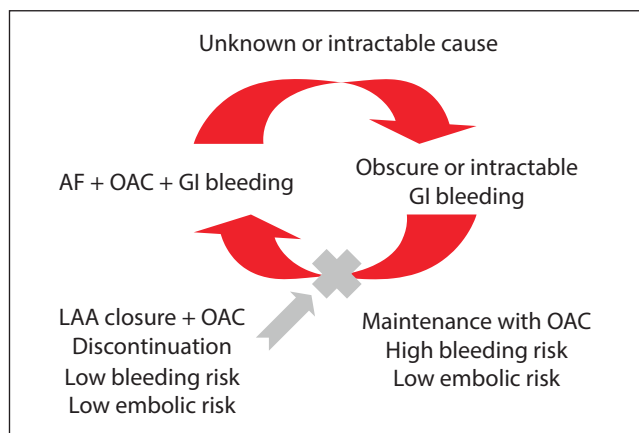


Fig. 2. The vicious cycle of obscure or intractable gastrointestinal bleeding in a patient with atrial fibrillation receiving oral anticoagulants (AF: Atrial fibrillation; OAC: Oral anticoagulant; LAA: Left atrial appendage).

In conclusion, obscure or intractable GI bleeding in patients with AF on OACs is a major cause of morbidity and mortality, and its management is complex. Percutaneous LAA closure and OAC discontinuation may well be an optimal therapeutic option to protect patients against both GIB and arterial embolism.

REFERENCES

1. Zuckerman GR, Prakash C, Askim MP, Lewis BS. AGA technical review on the evaluation and management of occult and obscure gastrointestinal bleeding. *Gastroenterology* 2000;118:201-21.
2. Guerrouij M, Uppal CS, Alklabi A, Douketis JD. The clinical impact of bleeding during oral anticoagulant therapy: Assessment of morbidity, mortality and post-bleed anticoagulant management. *J Thromb Thrombolysis* 2011;31:419-23.
3. Barada K, Abdul-Baki H, El Hajj II, Hashash JG, Green PH. Gastrointestinal bleeding in the setting of anticoagulation and antiplatelet therapy. *J Clin Gastroenterol* 2009;43:5-12.
4. Wolf AT, Wasan SK, Saltzman JR. Impact of anticoagulation on rebleeding following endoscopic therapy for nonvariceal upper gastrointestinal hemorrhage. *Am J Gastroenterol* 2007;102:290-6.
5. Guidelines for the management of atrial fibrillation: The Task Force for the Management of Atrial Fibrillation of the European Society of Cardiology (ESC). *Europace* 2010;12:1360-420.
6. Block PC, Burstein S, Casale PN, Kramer PH, Teirstein P, Williams DO, et al. Percutaneous left atrial appendage occlusion for patients in atrial fibrillation suboptimal for warfarin therapy: 5-year results of the PLAATO (Percutaneous Left Atrial Appendage Transcatheter Occlusion) Study. *JACC Cardiovasc Interv* 2009;2:594-600.
7. Bayard YL, Omran H, Neuzil P, Thuesen L, Pichler M, Rowland E, et al. PLAATO (Percutaneous Left Atrial Appendage Transcatheter Occlusion) for prevention of cardioembolic stroke in non-anticoagulation eligible atrial fibrillation patients: Results from the European PLAATO study. *EuroIntervention* 2010;6:220-6.
8. Holmes DR, Reddy VY, Turi ZG, Doshi SK, Sievert H, Buchbinder M, et al.; PROTECT AF Investigators. Percutaneous closure of the left atrial appendage versus warfarin therapy for prevention of stroke in patients with atrial fibrillation: a randomised non-inferiority trial. *Lancet* 2009;374:534-42.
9. Park JW, Bethencourt A, Sievert H, Santoro G, Meier B, Walsh K, et al. Left atrial appendage closure with amplatzer cardiac plug in atrial fibrillation: Initial European experience. *Catheter Cardiovasc Interv* 2011;77:700-6.
10. Appleyard M, Glukhovskiy A, Swain P. Wireless-capsule diagnostic endoscopy for recurrent small-bowel bleeding. *N Engl J Med* 2001;344:232-3.
11. Ruiz-Nodar JM, Marín F, Roldán V, Valencia J, Manzano-Fernández S, Caballero L, et al. Should we recommend oral anticoagulation therapy in patients with atrial fibrillation undergoing coronary artery stenting with a high HAS-BLED bleeding risk score? *Circ Cardiovasc Interv* 2012;5:459-66.
12. Connolly SJ, Ezekowitz MD, Yusuf S, Eikelboom J, Oldgren J, Parekh A, et al. Dabigatran versus warfarin in patients with atrial fibrillation. *N Engl J Med* 2009;361:1139-51.