

A randomized controlled study of a computer-generated three-dimensional model for teaching ear anatomy

Nicholson DT¹, Chalk C², Funnell WRJ³ & Daniel SJ⁴

¹ Post-Doctoral Fellow, Department of Medical Informatics and Clinical Epidemiology, Oregon Health & Science University, Portland, Oregon

² Associate Professor, Department of Neurology and Neurosurgery and Centre for Medical Education, McGill University, Montréal, Québec

³ Associate Professor, Departments of BioMedical Engineering and Otolaryngology, McGill University, Montréal, Québec

⁴ Assistant Professor, Department of Otolaryngology, McGill University, Montréal, Québec.

Medical Education: accepted 2006 May 5

Corresponding author

Dr. D. Nicholson
Department of Medical Informatics & Clinical Epidemiology
Oregon Health & Science University
3181 SW Sam Jackson Park Road
Mailcode: BICC
Portland, OR 97239-3098
USA
E-mail: darensesmail at yahoo.com
Telephone: +1-503-418-2317
Fax: +1-503-494-4551

Abstract

Introduction The use of computer-generated three-dimensional (3D) anatomical models to teach anatomy has proliferated. However, there is little evidence that these models are educationally effective. The purpose of this study was to test the educational effectiveness of a computer-generated 3D model of the middle and inner ear.

Methods We reconstructed a fully interactive model of the middle and inner ear from a magnetic resonance imaging scan of a human cadaver ear. To test the model's educational usefulness, we conducted a randomized control study in which 28 medical students completed a Web-based tutorial on ear anatomy that included the interactive model, while a control group of 29 students took the tutorial without exposure to the model. At the end of the tutorials, both groups were asked a series of 15 quiz questions to evaluate their knowledge of 3D relationships within the ear.

Results The intervention group's mean score on the quiz was 83%, while that of the control group was 65%. This difference in means was highly significant ($p < 0.001$).

Discussion Our findings stand in contrast to the handful of previous randomized controlled trials that evaluated the effects of computer-generated 3D anatomical models on learning. The equivocal and negative results of these previous studies may be due to the limitations of these studies (such as small sample size) as well as the limitations of the models that were studied (such as a lack of full interactivity). Given our positive results, we believe that further research is warranted concerning the educational effectiveness of computer-generated anatomical models.

Overview Box

What is already known on this subject.

There are only a few published evaluations of computerized anatomical models, and these studies have had negative or equivocal results.

What this study adds.

Our study presents positive results based on a relatively large sample size. In addition, our anatomical model is more interactive than the models used in previous studies.

Suggestions for further research.

Future studies with large sample sizes should be conducted to validate the positive results found in our study.

Introduction

The dramatic advances in computer technology over the past few decades have profoundly affected health care, including the domain of medical education. For years medical educators have shown great interest in using computer applications in medical-school curricula to augment, or in some cases replace, traditional teaching methods such as lectures, laboratories, and textbooks. In the domain of human anatomy, many medical educators have turned to three-dimensional (3D) computer models as an alternative means of teaching this fundamental body of knowledge. One obvious factor underlying this trend is the decreased use of human cadavers to teach anatomy. Many medical school curriculums do not include cadaver dissection labs (including eight of the eleven medical schools in Australia) (1). Reasons cited for this decline include the rising costs and decreasing availability of cadavers (2) as well as the advent of new teaching methods, such as problem-based learning, which do not include dissection labs (1).

In some instances traditional teaching modalities, such as cadaver dissection, prove to be ineffective teaching tools. For example, the complexity of the middle and inner ear, coupled with the small size of its anatomical structures, creates many obstacles to teaching ear anatomy with traditional instructional techniques. Because of the small size of ear specimens and because the ear is embedded in bone, studying a cadaveric ear requires advanced dissection skills, which most medical students lack. As an alternative or supplement to cadaveric ears, some educators use magnified, artificial models of the ear as a 3D demonstration aid. However, due to the high price and decreasing availability of such models, providing adequate access to artificial models for large medical schools is virtually impossible. Furthermore, many anatomical details are

absent from these models. Computerized 3D anatomical models promise to overcome many of these educational challenges.

Although many educators have developed computer-generated anatomical models as teaching tools, there has been little published research on the effectiveness of these models. In a recent literature review, Lewis found only one study (by Hallgren et al.) that had compared the efficacy of computer-assisted anatomy instruction (CAI) with that of traditional teaching methods (3). The educational intervention that Hallgren and colleagues described as "Web-based exercises" does not appear to involve computer-generated anatomical models (4).

To supplement the results of Lewis' review, we searched Medline (from April 1965 through June 1, 2005) using the combined MeSH headings *anatomy* and *computer-assisted instruction* and found only four randomized controlled studies that evaluated computer-generated anatomical models. Three of these four articles comprise a series of studies conducted by Garg and colleagues (5-7) that evaluated the educational effectiveness of an interactive 3D model of the carpal bones. The intervention groups in these studies were able to interact with the 3D model and thereby were exposed to multiple views of the carpal bones. By contrast, members of the control groups were presented with a limited number of "key" views of the carpal bones (such as the dorsal and palmar perspectives). This presentation of a small number of canonical views is consistent with the approach taken by most anatomical atlases. Based on the results of these three studies, the authors offered the following mixed conclusion: "the potential for dynamic display of multiple orientations provided by computer-based anatomy software may offer minimal advantage to some learners and...may disadvantage learners with poorer spatial ability" (7). The fourth randomized controlled study that we identified

compared the use of a shoulder arthroscopy simulator to the use of traditional two-dimensional (2D) images of shoulder anatomy. Both the control group and the intervention group scored poorly on the evaluation quiz, and there was no statistically significant difference between the groups' mean scores (8).

Computer-assisted anatomy instruction is generally perceived by medical students to be enjoyable (9) but whether it actually enhances learning is unproven. As our literature review attests, the evidence supporting the educational effectiveness of CAI is lukewarm at best. Furthermore, much of what is considered to be "computer-assisted instruction" is in reality little more than static text and images on a screen and does not truly exploit the unique advantages of the medium. Although the use of computer-generated 3D anatomical models has potential advantages over traditional anatomy instruction methods, the time and financial resources needed to develop and adopt these models are significant. For instance, the authors spent approximately 160 person-hours to develop the 3D ear model evaluated in this study (excluding the hundreds of hours previously spent writing the software used to generate the 3D model). We believe that it is important to properly evaluate the effectiveness of computer-generated anatomical models before continuing to invest time and financial resources in this new technology.

In this context we conducted a randomized controlled study to assess the educational value of a computer-generated 3D anatomical model of the ear. In designing the study, we specifically sought to test whether learning is enhanced by exploiting a property of computer technology for which good counterparts are lacking in traditional teaching media: the ability to manipulate 3D structures in space. A firm grasp of the 3D relationships of anatomical structures is central to the learning and clinical

application of anatomy. We hypothesized that student learning of 3D anatomical relationships within the ear would be improved by use of our computer-generated 3D model in addition to the standard teaching modalities of text and 2D images.

Methods

Study Design

We used a randomized control-group design for our study. The outcome measure was the score on a 15-item quiz administered after a computer-based anatomy tutorial. Our study was approved by the McGill University Institutional Review Board.

Participants

We recruited our study subjects from the first-year medical-school class at McGill University (Montréal, Québec) via e-mail and class announcements. All first-year students were eligible for the study. Participation in the study was voluntary and a small remuneration was offered for completion of the study. All volunteers provided written consent.

We felt that a difference of two or more in the mean quiz scores (of a total of 15) between the intervention and control groups would be a meaningful effect. To detect this difference in means at a significance level of 95% and with a power of 0.90, we estimated that a total sample size of 60 students (30 in each group) would be necessary.

Materials

The source of the 3D model used in our study was a high-resolution magnetic resonance imaging scan of the middle and inner ear of a human cadaver (10). From these images we reconstructed our model using software developed in our laboratory (specifically, two programs named Fie and Tr3, which were written and are maintained by one of the authors, WRJF, and can be downloaded free from the Internet at <http://audilab.bmed.mcgill.ca/~funnell/AudiLab/sw/>). The model includes the major anatomical structures (ossicles, tympanic membrane, vestibulocochlear apparatus, etc.)

of the middle and inner ear (see Figure 1). The model is stored as a Virtual Reality Modeling Language file. (VRML is an ISO standard for distributing 3D models on the Web). After generating the model, we built an online ear-anatomy tutorial around it. The tutorial is presented as a series of Web pages that display text and 2D images of the middle and inner ear with links to various versions of the 3D model. When a user clicks on a link to a 3D model, the model is displayed and can be manipulated by the user within the Web browser. A VRML viewer plug-in must be installed in the user's Web browser prior to using the tutorial. Several such viewers are freely available. During our study we used Cosmo Player. (Cosmo Player is no longer supported but it can still be downloaded from several sites on the Web.) Viewing capabilities in Cosmo Player include arbitrary rotation of the model and an in/out zoom feature. Also, when hovering the mouse over a given 3D structure, a label is displayed to identify the structure.

Procedures

Our study's ultimate goal was to evaluate whether our 3D model improves students' learning of 3D anatomical relationships in the ear. The 3D model is not meant to improve students' ability to simply recognize and name anatomical structures. To be certain that all participants in the study had sufficient *a priori* knowledge of the names and appearances of middle and inner ear structures, we required all participants to take an online tutorial that reviews these structures using text and 2D images (Phase 1 of the study). Following the Phase 1 tutorial, the students were required to pass a quiz (seven out of eight answers correct) to qualify for the main portion of the study (Phase 2). For each Phase 1 quiz question, a 2D representation of an anatomical ear structure was displayed and the student had to name the structure. Students who failed the quiz were allowed to retake the Phase 1 tutorial and quiz until they were able to achieve a passing

mark. We allowed the participants to complete this preliminary tutorial and quiz from any Internet-connected computer. At the end of Phase 1, we collected baseline information about the participants including their gender, their past experience with ear anatomy, and their past experience with visual-spatial tasks (see Figure 2). We also assessed their visual-spatial skills using a standard visual-spatial test (11).

Phases 1 and 2 of our study were conducted concurrently with the students' usual teaching about the anatomy of the ear (a one-hour whole-class lecture plus a small-group demonstration using a large plaster model of the ear). Phase 2 was conducted in a computer lab with students assigned to one of four sessions, which were offered over a two-day period. We randomly assigned the students (using a random-number table) to either the control or the intervention group. Students worked at their own pace through the on-line tutorial. This tutorial was identical for the two groups except that the links to the 3D model were disabled for those in the control group. Once a participant felt ready, he or she proceeded to the Phase 2 quiz page. The quiz consisted of 15 questions, each designed to assess the participants' perceptions of 3D relationships among ear structures. Twelve of these questions were multiple-choice, while the remaining three required the students to name a structure by completing a free-text data entry field. Participants were instructed not to return to the tutorial Web pages once they began the Phase 2 quiz. Web-server logs were used to calculate the time each student spent completing the tutorial and quiz.

Analysis

The primary outcome measurement of our study was the mean score on the Phase 2 quiz. We compared the mean scores of the intervention and control groups with a two-tailed Student's *t* test (using the statistical software SPSS). We also used the Student's *t* test to compare the mean scores on the visual-spatial test and the mean length of time taken to complete the Phase 2 tutorial and quiz. To analyze the participants' responses concerning their prior experience with 3D games, we conducted a Wilcoxin rank sum test. Finally, chi-square tests were used to ensure that the groups were comparable with respect to gender, previous exposure to ear anatomy, and experience in visual arts.

Results

Sixty-one students agreed to participate in the study, and we randomized them to either the control group (n=30) or the intervention group (n=31). Four of these students (one from the control group and three from the intervention group) were disqualified from the study because they returned to the tutorial Web pages after having begun the Phase 2 quiz. Thus, the final sample sizes were n=29 for the control group and n=28 for the intervention group.

The mean Phase 2 quiz score for the control group was 9.8/15 (65%) while that of the intervention group was 12.5/15 (83%) (see Figures 3 and 4). The standard deviations for the control and intervention groups were 1.8/15 (12%) and 1.7/15 (11%), respectively. This difference in mean quiz scores (18% with a confidence interval of 12% to 24%) was highly significant ($p < 0.001$). With regard to the participants' baseline information, there were no significant differences between the two groups (see Figure 4). There was a significant difference in the mean length of time spent to complete the Phase 2 tutorial and quiz (control group mean: 16 minutes; intervention group mean: 21 minutes; difference of means: 5 minutes; confidence interval of difference of means: 2.8 to 7.2 minutes; significance: $p < 0.001$).

Discussion

With this study we have demonstrated that a computer-based 3D anatomical model enhances medical students' learning of ear anatomy. Our findings stand in contrast to the handful of previous attempts to evaluate the effects of computer-generated 3D anatomical models on learning. The negative or equivocal results of previous studies may be in part the result of study design. The equivocal results found by Hariri et al. (shoulder model study) may be due to low statistical power (their sample size was only 29 students) (8). The three studies by Garg et al. (carpal bones model) failed to show any learning advantage using computer-generated 3D models. However, our 3D model of the middle and inner ear differs from the carpal-bones model of Garg et al. in several respects. For one, our 3D ear model is fully interactive: it may be zoomed in and out, panned across the screen, and rotated smoothly in all three directions (x, y, and z axes). Moreover, the structures involved in the middle and inner ear are far more complex and volumetric than the carpal bones. Indeed, Garg and colleagues themselves note that their findings might be "constrained" by the fact that the carpal bones "fall naturally into two planes" (7). Thus, it may be the greater level of interactivity inherent in our model and the greater complexity of the modeled structure that led to a positive effect on the participants' learning.

Our study also has limitations. First, our outcome measure (the Phase 2 quiz score) is merely a surrogate measure of 3D anatomical understanding. We did not test the reliability nor the validity of our outcome measure. Second, it was not possible to measure the participants' effort levels during the study. Without any incentive to score well on the quiz, some participants may well have worked at less than maximal efforts. Thus, our results could be due to a higher average effort level in the intervention group

as opposed to the control group. This limitation is not unique to our study and would apply to the previous work in this field. Finally, we did not impose a time limit on the participants. As noted, students in the intervention group spent more time completing the tutorial and quiz than did those in the control group. Perhaps the improvement in mean quiz scores was not due to the intrinsic value of the 3D model as a teaching tool; rather, the novelty of the 3D model may have encouraged the intervention group to spend more time and to concentrate more on the material as opposed to the control participants, thereby leading to better quiz scores. One can argue that, either way, the outcome is the same: better understanding of 3D anatomical relationships.

Although our study subjects were medical students, it seems plausible that our ear model would also be an effective method of teaching residents and practicing physicians. Indeed, our ear model, which we originally developed as a teaching tool for otolaryngology residents, was well received during teaching sessions for residents. Computer-based interactive 3D models may also be valuable teaching tools in other biomedical domains which involve complex 3D relationships, such as histology and cell biology, as well as 3D-intensive non-biomedical domains.

In summary, the use of CAI techniques in anatomy is already widespread. Only a few studies have attempted to evaluate the effectiveness of these teaching tools and, to date, there is little objective evidence that CAI improves anatomy instruction. The results of this study, however, are very positive and suggest that further work is warranted both on the development of interactive 3D models and on the evaluation of their effectiveness.

Acknowledgements

The authors would like to acknowledge Drs. O.W. Henson Jr. and M. Henson of the University of North Carolina at Chapel Hill for providing the MRI scan that we used to construct our 3D ear model. The MRI scan was conducted at Duke University's Center for In Vivo Microscopy. We would also like to thank Dr. Sam David of McGill University for his valuable input concerning the text of our tutorial.

Funding for this study was provided by the McGill University Centre for Medical Education and the Division of Neurology, Montreal General Hospital. Funding for the development of the ear model was provided by the Canadian Institutes of Health Research and by the Natural Sciences and Engineering Research Council (Canada). Dr. Nicholson was supported by National Library of Medicine Training Grant 5-T15-LM007088-14.

References

- (1) Parker LM. What's wrong with the dead body? Use of the human cadaver in medical education. *Med J Aust* 2002 Jan;176(2):74-6.
- (2) Berube D, Murray C, Schultze K. Cadaver and computer use in the teaching of gross anatomy in physical therapy education. *J Phys Ther Educ* 1999 Fall;13(2):41-46.
- (3) Lewis MJ. Computer-assisted learning for teaching anatomy and physiology in subjects allied to medicine. *Medical Teacher* 2003 Mar;25(2):204-206.
- (4) Hallgren RC, Parkhurst PE, Monson CL, Crewe NM. An interactive, web-based tool for learning anatomic landmarks. *Acad Med* 2002 Mar;77(3):263-265.
- (5) Garg A, Norman GR, Spero L, Maheshwari P. Do virtual computer models hinder anatomy learning? *Acad Med* 1999 Oct;74(10 Suppl):S87-9.
- (6) Garg AX, Norman G, Sperotable L. How medical students learn spatial anatomy. *Lancet* 2001 Feb 3;357(9253):363-364.
- (7) Garg AX, Norman GR, Eva KW, Spero L, Sharan S. Is there any real virtue of virtual reality?: the minor role of multiple orientations in learning anatomy from computers. *Acad Med* 2002 Oct;77(10 Suppl):S97-9.
- (8) Hariri S, Rawn C, Srivastava S, Youngblood P, Ladd A. Evaluation of a surgical simulator for learning clinical anatomy. *Med Educ* 2004 Aug;38(8):896-902.
- (9) Nieder GL, Nagy F. Analysis of medical students' use of web-based resources for a gross anatomy and embryology course. *Clin Anat* 2002 Nov;15(6):409-418.

(10) Henson OW, Henson M. Scan S16885. Available from: URL:
http://cbaweb2.med.unc.edu/henson_mrm/pages/Scans_Primates.html. Accessed
September 2003.

(11) Pennsylvania State University at Erie, The Behrend College. Visualization
Assessment and Training Project (VIZ). Available from: URL: <http://viz.bd.psu.edu/viz/>.
Accessed April 2004.

Figure 1 – Structures included in ear model

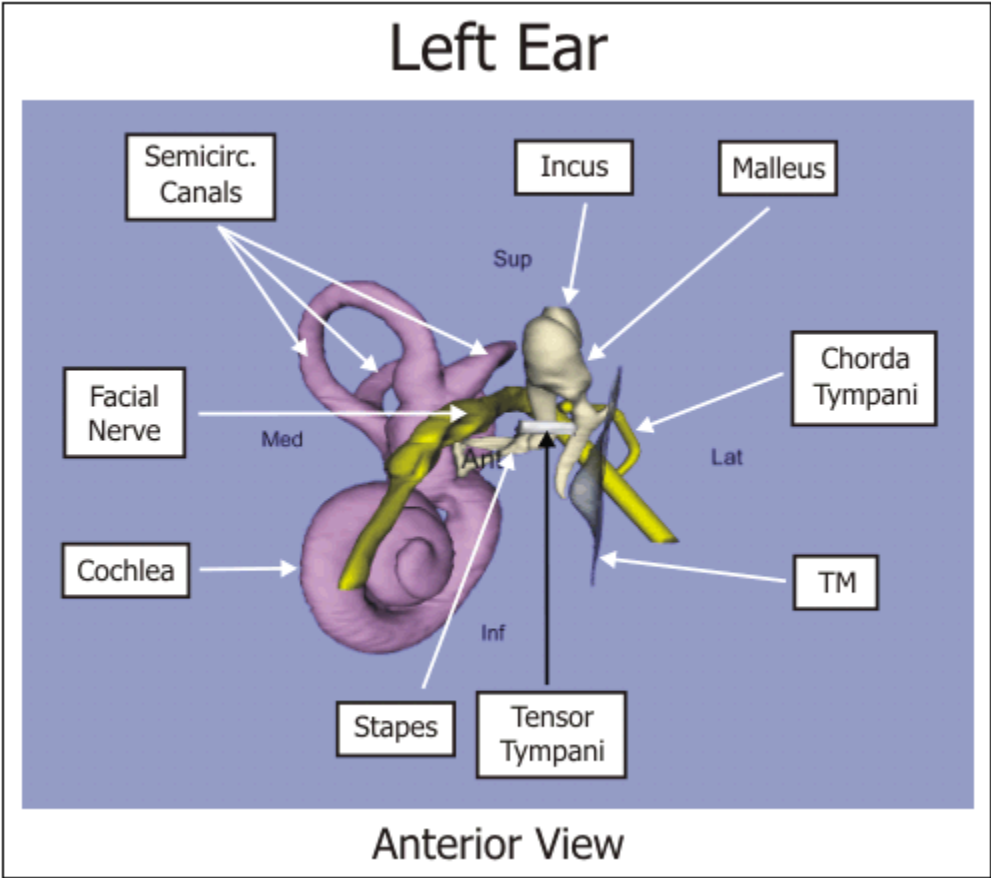


Figure 2 – Baseline information questions

1. Please select your sex (female or male)
2. Have you studied ear anatomy previous to medical school? (yes or no)
3. Do you regularly engage in any of the following activities: painting, sculpture, carpentry or 3D graphic design? (yes or no)
4. How much experience do you have playing 3D video games?
 - Never (I have never played 3D video games in the past)
 - Some (I play, or have played in the past, not more than once a month)
 - Moderate (I play, or have played in the past, more than once a month but less than 5 times per month)
 - Lots (I play, or have played in the past, 5 times per month or more often)

Figure 3 – Box plot of mean quiz scores

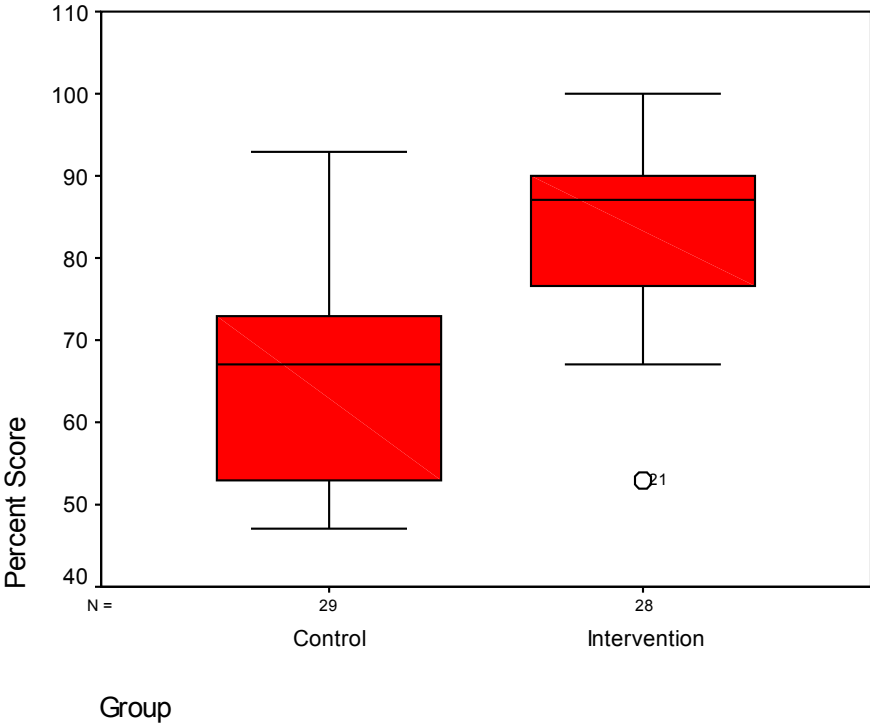


Figure 4 – Comparison of average data points between groups

Measure	Control Group Result	Intervention Group Result	Statistical Test	P-value
Mean score on Phase 2 quiz (%)	65	83	Student's <i>t</i>	< 0.001
Mean length of time to complete Phase 2 (minutes)	16	21	Student's <i>t</i>	< 0.001
Percentage female	62	64	chi-square	0.86
Percentage with prior anatomy experience	38	46	chi-square	0.52
Percentage with prior art experience	7	11	chi-square	0.61
Mean rank of prior 3D game experience	27.7	30.3	Wilcoxin rank sum	0.52
Mean percent-score on visual-spatial quiz	95	93	Student's <i>t</i>	0.56