

## CASE REPORT

## Canine olfactory detection of malignant melanoma

Leon Frederick Campbell,<sup>1</sup> Luke Farmery,<sup>2</sup> Susannah Mary Creighton George,<sup>3</sup> Paul B J Farrant<sup>3</sup>

<sup>1</sup>Brighton and Sussex University Hospitals NHS Trust, Brighton, UK

<sup>2</sup>Western Sussex Hospitals NHS Foundation Trust, Chichester, UK

<sup>3</sup>Department of Dermatology, Brighton and Sussex University Hospitals NHS Trust, Brighton, UK

**Correspondence to**

Dr Leon Frederick Campbell, leoncampbell@doctors.org.uk

**SUMMARY**

Our patient is a 75-year-old man who presented after his pet dog licked persistently at an asymptomatic lesion behind his right ear. Examination revealed a nodular lesion in the postauricular sulcus. Histology confirmed malignant melanoma, which was subsequently excised. Canine olfactory detection of human malignancy is a well-documented phenomenon. Advanced olfaction is hypothesised to explain canine detection of bladder, breast, colorectal, lung, ovarian, prostate and skin cancers. Further research in this area may facilitate the development of a highly accurate aid to diagnosis for many malignancies, including melanoma.

**CASE PRESENTATION**

A 75-year-old white Caucasian man presented to the dermatology clinic after his pet dog licked persistently at an asymptomatic lesion behind his right ear. The patient was previously unaware of the lesion. The dog, a female Alsatian (figure 1), was acquired from a rescue centre 4 years previously. Therefore, the dog's previous history and exact age was unknown. The patient had a history of significant sun exposure. He also suffered with eczema as an adolescent. There was no family history of skin disease or skin cancer. Medical history included multiple myeloma diagnosed 4 years previously, for which the patient had received chemotherapy, bortezomib and radiotherapy. At the time of presentation he was in slow relapse.

Clinical examination revealed a 2 cm, dry, scaly, nodular lesion in the right postauricular sulcus. It was asymmetrical with an irregular border and a peripheral ring of pigmentation (figure 2). It was initially suspected to be a basal cell carcinoma. The differential diagnosis included squamous cell carcinoma and MM and therefore a biopsy was taken to plan treatment.


**BACKGROUND**

Malignant melanoma (MM) is the most serious form of the common skin cancers. MM is the sixth most common cancer in the UK<sup>1</sup> with a crude incidence of 15.9/100 000, equating to 9500 new cases per annum.<sup>2</sup> Breslow thickness, the thickness of a melanoma in millimetres measured from the top of the granular layer of the epidermis,<sup>3</sup> is the most important prognostic indicator.<sup>4</sup> Excision of small, thin melanomas is potentially curative. Therefore, early detection is essential to improve 5-year survival rates.

MM diagnosis is made on the basis of clinical examination, which is inherently subjective relying on the physician's training and experience, and therefore results in a high-false-positive rate. An analysis of UK data revealed that the ratio of benign moles for each MM excised was 6:3.<sup>5</sup> Dermoscopy enhances diagnostic accuracy,<sup>6</sup> however, development of an independent objective technique may be a valuable adjunct in the early detection of MM.

Williams and Pembroke reported the first case of canine olfactory detection of MM in 1989.<sup>7</sup> The patient's dog, a Border Collie-Doberman cross, would sniff repeatedly at the patient's lesion even through clothing, revealing an olfactory origin to the behaviour. The authors surmised the dog had probably saved her owner's life by prompting her to seek treatment while the lesion, in this case a superficial spreading MM, was still at a 'thin and curable' stage.

This case report adds further anecdotal evidence of canine olfactory detection of MM and prompts further debate about the potential application of canine olfaction to early MM diagnosis in clinical practice.



**Figure 1** The patient's dog.

**To cite:** Campbell LF, Farmery L, George SMC, et al. *BMJ Case Rep* Published online: [please include Day Month Year] doi:10.1136/bcr-2013-008566

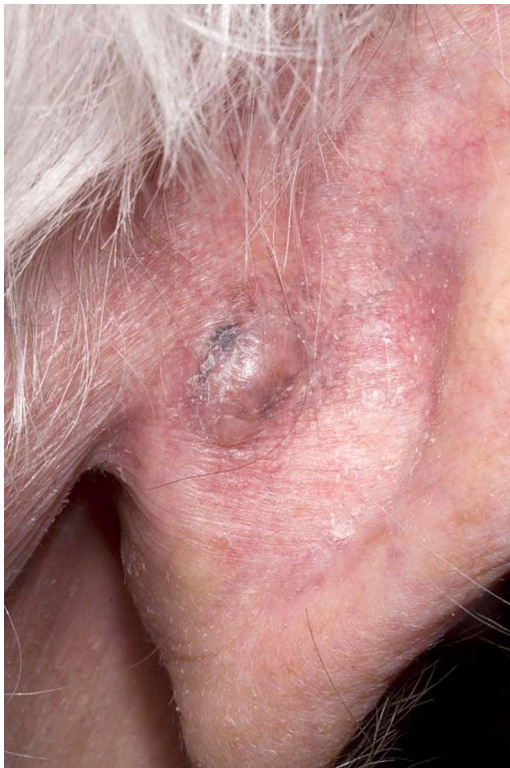

Figure 2 The patient's lesion.

**INVESTIGATIONS**

A 3 mm diameter punch biopsy was sent for histological evaluation. A microscopic analysis revealed an invasive, ulcerated MM, with an estimated Breslow thickness of 2.5 mm. Diagnosis was confirmed with Panmelanoma staining—an antibody cocktail (HMB45, anti-MART1, Melan A and antityrosinase) designed to detect melanocytic differentiation.<sup>8 9</sup>

**DIFFERENTIAL DIAGNOSIS**

The differential diagnosis of pigmented skin lesions includes: benign naevus, dysplastic naevus, seborrhoeic keratosis, pigmented-basal cell carcinoma, pigmented-squamous cell carcinoma and dermatofibroma.

**TREATMENT**

The MM was removed surgically with a 1 cm wide local excision, including the underlying cartilage. A concurrent full-thickness skin graft was performed.

**OUTCOME AND FOLLOW-UP**

The histological appearance of the specimen was of a completely regressed MM, with a small focus of residual lentigo maligna. The lesion was completely excised by a margin of 2.5 mm. Subsequent follow-up revealed a well-healed surgical site, with no evidence of local recurrence. A CT scan revealed no MM-related pathology, although lytic lesions in the axial skeleton associated with the patient's myeloma were observed. The patient had regular dermatology follow-up, with no evidence of recurrence of his MM, until his death 11 months later from progression of his multiple myeloma.

**DISCUSSION**

Since the first case report of canine olfactory detection of MM in 1989 there has been limited exploration of this phenomenon. The sole prospective trial to date involving MM<sup>10</sup> demonstrated sensitivity of 82% in seven patients. While these results are certainly encouraging, the authors noted several limitations to the study including the small patient cohort and the selection bias of the patients involved, who had been preselected by a dermatologist as likely having MM.

The original paper by Williams and Pembroke did not comment on the presence or absence of ulceration. In the cases described by Pickel *et al*, the melanomas were not ulcerated. In our case, the MM was ulcerated and it is possible that the dog merely detected the lesion because it smelled different to the rest of the skin, rather than detecting any melanoma-specific chemicals. However, evidence exists that dogs can be trained to detect MM and other cancers. It is the reproducibility of these results between patients that suggests the existence of malignancy-specific volatile organic chemicals (VOCs).

Considering other malignancies, there have been numerous case-reports and some small-scale trials demonstrating canine ability to detect bladder, breast, colorectal, lung, ovarian and prostate cancers (table 1).<sup>10–15</sup>

The literature suggests that canine olfactory detection of malignancy may have potential, both in terms of application in contemporary clinical practice and directing future research.

**Table 1** Summary of the published evidence of canine olfactory detection of human malignancy

Malignancy	Study type	Canine characteristics	Substrate	Number of cases (excluding controls)	Positive response	Sensitivity (%)	Specificity (%)
Melanoma <sup>10</sup>	Prospective	1 Standard Schnauzer (m), 1 Golden Retriever (f)	In vivo MM	7	Sitting and pawing or mouthing at sample	82	–
Bladder <sup>11</sup>	Prospective	6 dogs, no further details published	Urine	27	Lying next to positive sample	41	–
Breast <sup>12</sup>	Prospective	3 Labrador Retrievers (2m, 1f) 2 Portuguese Water Dogs (1m, 1f)	Exhaled breath	31	Sitting or lying in front of sample	88	98
Colorectal <sup>13</sup>	Prospective	1 Labrador Retriever (f)	Exhaled breath (B) and watery stools (S)	B 33 S 37	Sitting in front of sample	91	99
Lung <sup>12</sup>	Prospective	3 Labrador Retrievers (2m, 1f) 2 Portuguese Water Dogs (1m, 1f)	Exhaled breath	55	Sitting or lying in front of sample	99	99
Ovarian <sup>14</sup>	Prospective	2 Giant Schnauzers (2f)	Tissue (T) and blood (B)	T 10 B 10	Scratching at sample with forelegs	T 100 B 100	T 95 B 98
Prostate <sup>15</sup>	Prospective	Belgian Malinois (gender not published)	Urine	33	Sitting in front of sample	91	91

MM, malignant melanoma.

Further validation of canine olfactory detection of MM may provide evidence to support the introduction of 'sniffer dogs' to dermatological practice. Dogs are already widely used in health-care, for example, as guide dogs, hearing dogs and medical alert dogs. Thus large-scale patient acceptance is already demonstrated. In terms of financial viability, the training of scent detection dogs could be adopted from current training regimes used in other industries. This might offer a cost effective adjunct to diagnosis, particularly in resource poor settings where investigations are limited.

Alternatively, identification of the specific VOCs being detected by canine olfaction could facilitate the development of a technologically based scent detection system, a so-called 'electronic nose'.<sup>16</sup> A recent study has identified three VOCs preferentially expressed in MM: 4-methyl decane, dodecane and undecane.<sup>17</sup> This study involved various melanoma types, including: MM in situ, recurrent, superficial spreading, nodular and metastatic, revealing common VOC expression. While research into VOC detection has been pursued for decades, usually based on gas chromatography, currently canines significantly out-perform the technological equivalents. Further study of canine olfaction may help to refine the technology potentially improving the detection of melanoma and a variety of other malignancies, including those which are currently particularly difficult to detect at an early stage.

### Learning points

- ▶ There is extensive peer-reviewed evidence of canine olfactory detection of volatile organic chemicals associated with human cancers, including melanoma, bladder, breast, colorectal, lung, ovarian and prostate.
- ▶ Existing canine training regimes for example, explosive/narcotic detection, could be easily modified for cancer detection, making this a financially attractive diagnostic tool.
- ▶ Identification of the volatile organic chemicals being detected by canine olfaction may facilitate the development of a technologically based method for diagnosing a variety of malignancies.

**Contributors** LC and LF were involved in observing patient's clinical care, reviewing case notes, literature review, writing the case report. SMCG contributed by advising on writing case report, reviewing and editing case report, supervising medical students and approved the final version for submission. PBJF was involved in advising on writing the case report, reviewing and editing case report, supervising medical students and approved the final version for submission.

**Competing interests** None.

**Patient consent** Obtained.

**Provenance and peer review** Not commissioned; externally peer reviewed.

### REFERENCES

- 1 Office for National Statistics. *Cancer incidence and mortality in the UK, 2007–2009*. Newport: Office for National Statistics, 2012.
- 2 National Cancer Intelligence Network. *Cancer incidence and mortality by cancer network, UK, 2005*. London: National Cancer Intelligence Network Coordinating Centre, 2008.
- 3 Calonje E. The histological reporting of melanoma. *J Clin Pathol* 2000;53:587–90.
- 4 Breslow A. Thickness, cross-sectional areas and depth of invasion in the prognosis of cutaneous melanoma. *Ann Surg* 1970;172:902–8.
- 5 Sidhu S, Bodger O, Williams N, et al. The number of benign moles excised for each malignant melanoma: the number needed to treat. *Clin Exp Dermatol* 2012;37:6–9.
- 6 Kittler H, Pehamberger H, Wolff K, et al. Diagnostic accuracy of dermoscopy. *Lancet Oncol* 2002;3:159–65.
- 7 Williams H, Pembroke A. Sniffer dogs in the melanoma clinic? *Lancet* 1989;1:734.
- 8 Marsden JR, Newton-Bishop JA, Burrows L, et al. Revised UK guidelines for the management of cutaneous melanoma 2010. *Br J Dermatol* 2010;163:238–56.
- 9 Ohsie SJ, Sarantopoulos GP, Cochran AJ, et al. Immunohistochemical characteristics of melanoma. *J Cutan Pathol* 2008;35:433–44.
- 10 Pickel D, Manucy GP, Walker DB, et al. Evidence for canine olfactory detection of melanoma. *Appl Anim Behav Sci* 2004;89:107–16.
- 11 Willis CM, Church SM, Guest CM, et al. Olfactory detection of human bladder cancer by dogs: proof of principle study. *BMJ* 2004;329:712.
- 12 McCulloch M, Jezierski T, Broffman M, et al. Diagnostic accuracy of canine scent detection in early- and late-stage lung and breast cancer. *Integr Cancer Ther* 2006;5:30–9.
- 13 Sonoda H, Kohnoe S, Yamazato T, et al. Colorectal cancer screening with odour material by canine scent detection. *Gut* 2011;60:814–19.
- 14 Horvath G, Andersson H, Paulsson G. Characteristic odour in the blood reveals ovarian carcinoma. *BMC Cancer* 2010;10:643.
- 15 Cornu JN, Cancel-Tassin G, Ondet V, et al. Olfactory detection of prostate cancer by dogs sniffing urine: a step forward in early diagnosis. *Eur Urol* 2011;59:197–201.
- 16 Boedeker E, Friedel G, Walles T. Sniffer dogs as part of a bimodal bionic research approach to develop a lung cancer screening. *Interact Cardiovasc Thorac Surg* 2012;14:511–15.
- 17 Abaffy T, Duncan R, Riemer DD, et al. Differential volatile signatures from skin, naevi and melanoma: a novel approach to detect a pathological process. *PLoS One* 2010;5:e13813.

Copyright 2013 BMJ Publishing Group. All rights reserved. For permission to reuse any of this content visit

<http://group.bmj.com/group/rights-licensing/permissions>.

BMJ Case Report Fellows may re-use this article for personal use and teaching without any further permission.

Become a Fellow of BMJ Case Reports today and you can:

- ▶ Submit as many cases as you like
- ▶ Enjoy fast sympathetic peer review and rapid publication of accepted articles
- ▶ Access all the published articles
- ▶ Re-use any of the published material for personal use and teaching without further permission

For information on Institutional Fellowships contact [consortiasales@bmjgroup.com](mailto:consortiasales@bmjgroup.com)

Visit [casereports.bmj.com](http://casereports.bmj.com) for more articles like this and to become a Fellow