

- complications in children: a critical review of the literature. *J Pediatr* 1993; 123: 337-346.
6. van Ommen CH, Heijboer H, Buller HR, Hirasing RA, Heijmans HS, Peters M. Venous thromboembolism in childhood: A prospective two-year registry in the Netherlands. *J Pediatr* 2001; 39: 676-681.
 7. Carr ME. *Diabetes mellitus*: A hypercoagulable state. *J Diabetes Complications* 2001; 15: 44-54.
 8. Evan-Wong LA, Davidson RJ, Stowers JM. Alterations in erythrocytes in hyperosmolar diabetic compensation: a pathophysiological basis for impaired blood flow and for improved design of fluid therapy. *Diabetologica* 1985; 28: 739-742.
 9. Reid HL, Vigilance J, Wright-Pascoe RA, Choo-Kang E. The influence of persistent hyperglycaemia on hyperfibrinogenaemia and hyperviscosity in diabetes mellitus. *West Indian Med J* 2000; 49: 281-284.

Capillaria hepatica Infestation

Fazal Nabi
H.K. Palaha
Dipiti Sekhsaria
A. Chiatale

Capillaria hepatica is a very rare zoonotic infestation which primarily infest rodents and is rarely found in humans. The presenting features are fever of unknown origin, hepatomegaly and peripheral eosinophilia. Liver biopsy remains the cornerstone of diagnosis. Treatment of choice is Albendazole and outcome is generally good.

Capillaria hepatica primarily infests rodents and is rarely found in humans. Till date only 37 cases have been reported worldwide out of which two are from India. We hereby report a fourteen-month-old child who presented with pyrexia of unknown origin; later diagnosed to have *Capillaria hepatica* infestation.

From the Department of Pediatrics and Histopathology, Jaslok Hospital and Research Center, 15, Dr. G Deshmukh Marg, Mumbai 400 026, India.

Correspondence to: Dr. H.K. Palaha, Pediatric Intensivist, Jaslok Hospital and Research Centre, 15, Dr. G. Deshmukh Marg, Mumbai 400 026, India. E-mail: hkpalaha@rediffmail.com

*Manuscript received: July 3, 2006;
 Initial review completed: July 27, 2006;
 Revision accepted: May 9, 2007.*

A fourteen-month-old male child, resident of Nasik, was brought to our hospital with moderate to high grade fever for one month. This was preceded by loose stools for three days. On examination, the child was active and playful and weighed 10 Kg. Systemic examination was normal except for mild hepatomegaly.

Investigations revealed hemoglobin 8.7 g/dL, total leucocyte count—24,900/cumm, polymorphs—18%, lymphocytes—25%, eosinophils—55% and monocytes—2%. Liver function tests revealed mildly raised liver enzymes, viz., alanine aminotransferase—116 IU/L, aspartate aminotransferase—138 IU/L. Ultra-sound of the abdomen revealed mild hepatomegaly with a liver span of 9.7 cm, no intrahepatic biliary canalicular (IHBC) dilatation; portal vein and common bile duct were normal. There were enlarged lymph nodes in porta hepatis region, the largest one measuring 9 mm. CT abdomen revealed retropancreatic and preportal lymph nodes which were subcentrimetric. Bone marrow study was normal.

Meanwhile, the child continued to have moderate grade fever and was given symptomatic treatment. A liver biopsy was planned in absence of any diagnostic clues. The histopathological examination revealed classic spindle shaped eggs of nematode *Capillaria hepatica*. The eggs forms were pathog-nomic with outer striated wall and polar plugs on both end of the spindle. Some fibrosis was also seen (*Fig. 1*). Albendazole was started and child became afebrile, liver size regressed, serum transaminase levels became normal within 2 weeks of starting therapy.

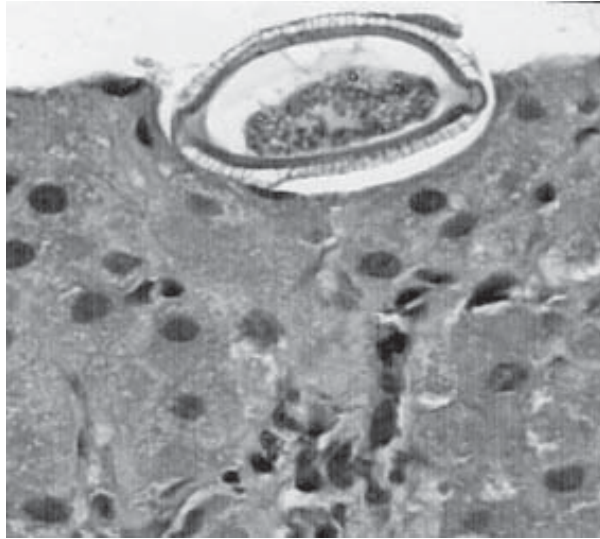


Fig. 1. Magnified view of *Capillaria hepatica* showing spindle shaped double walled eggs with outer striated wall and polar plugs on both side of the spindle shaped egg in liver biopsy, magnification 100 ×.

Capillaria hepatica is zoonotic nematode, primarily found in the liver of the rats(1). Human beings are accidental hosts. The unembryonated eggs of *Capillaria hepatica* are found in the liver of the first host and reach the intestine of the second host when the first host is eaten by a predator, or undergoes natural decomposition after death, whereby these eggs are released in the soil. They become embryonated in the soil and on ingestion by second host by feco-oral contamination, or geophagy, reach the intestine of second host. Here they migrate via the walls of intestines and through the portal vein, reach the liver where they grow into adult forms(2). This is known as genuine infestation and produces symptoms like persistent fever, hepatomegaly and eosinophilia(3). The differential diagnosis includes accidental tissue infestation by nematodes including *Toxocara cati*, *Toxocara canis*, *Fasciola hepatica* and visceral larva migrans. Liver biopsy remains the cornerstone of diagnosis, but serological testing by indirect immuno-

fluorescence assay is also recommended for diagnostic and screening purpose(4).

So far in the world literature only 37 cases of this disease have been reported, out of which 16 have been children(4). Two cases have been reported from India so far(5). Pica is an important presenting complaint, and this explains why this parasite infests the younger especially those between 1 and 5 years of age (94%). Anemia is frequently observed and so is hypergammaglobulinemia(3).

Treatment of choice is thiabendazole for 3 months. Alternative drugs include albendazole, and possibly ivermectin. Steroids are sometimes used to reduce hepatic inflammation(6). Prognosis depends on severity of infestation. With massive destruction of liver tissue, hepatic failure and death ensue if liver transplant is not available.

Contributors credit: FM Managed the case, HKP prepared the manuscript. DS worked up the case, AC did the histopathological reporting.

Funding: None.

Competing Interests: None stated.

REFERENCES

1. Bancroft TL. On the with-worm of the rats liver. J Proc R Soc New S Wales 1893; 27: 86-90.
2. Terrier, Hack, Hatz, Theintz G, Roulet M Hepatic Capillariasis in a 2-yr-old. J Pediatr Gastroenterol Nut 1999; 28: 338-340.
3. Choe G, Lee HS, Seo JK, Hepatic Capillariasis; First case report in Republic of Korea. Am J Trop Med Hyg 1993; 48: 610-625.
4. Juncker-Voss M, Prosi IH, Lussy H, Enzenberg U, Auer H, Nowotny N. Serological detection of *Capillaria hepatica* by indirect immuno-fluorescence assay, J Clin Microbiol 2000; 38: 431-433.
5. Govil H, Desai M. *Capillaria hepatica* parasitism. Indian J Pediatr 1996; 63: 698-700.
6. Pannabecker J, Miller TC, Miller J. *Capillaria hepatica*. Monatsschr Kinderheilkd 1990; 138: 767-777.