


Capillary Thrombosis as a Cause of Death in Experimental Anthrax

Frederic G. Dalldorf, MD, Chapel Hill, NC,
and Francis A. Beall, MS, Fort Detrick, Frederick, Md



The lungs of rats, rabbits, and guinea pigs that died of anthrax septicemia were studied by light and electron microscopy. In all three species, the clinical signs of respiratory failure that occurred during the terminal phase of the disease were associated with widespread pulmonary capillary thrombosis. The thrombi occurred in intact capillaries and were composed of platelets and fibrin. These results are compared with previous observations in rats given anthrax toxin and the significance of pulmonary capillary thrombosis as a factor in the cause of death in anthrax is discussed.

THE CLINICAL course of fatal anthrax septicemia in man can be divided into two phases.¹ The first phase, which apparently represents the establishment and early dissemination of the infection, lasts three or four days and is characterized by mild to moderate fever, malaise, and fatigue. The second phase, which represents the development of overwhelming septicemia and toxemia, appears suddenly during the last day of life and is characterized by the unexpected onset of dyspnea, cyanosis, and a rapid, failing pulse. Death occurs after 12 to 24 hours despite vigorous supportive therapy. In rabbits,² cattle,³ and chimpanzees⁴ the first phase of anthrax septicemia is not apparent clinically and the earliest sign of infection is often the onset of respiratory failure with dyspnea and cyanosis.

Accepted for publication Sept 13, 1966.

From the US Army Biological Center, Fort Detrick, Frederick, Md, and the Department of Pathology, University of North Carolina School of Medicine, Chapel Hill, NC.

Reprint requests to Department of Pathology, School of Medicine, University of North Carolina, Chapel Hill, NC 27515 (Dr. Dalldorf).

Previous work from our laboratory showed that Fischer 344 rats were unusually susceptible to intravenously administered anthrax toxin and were killed much faster by smaller doses of toxin than were guinea pigs or mice.⁵ Anthrax toxin in these rats produces a rapid, predictable, lethal response. Pulmonary edema, respiratory difficulty, and cyanosis develop after a period without signs of illness and the rats die gasping for air. A sequential light and electron microscopic study of the lungs of toxin-treated rats showed that the developing pulmonary edema caused by the toxin was associated with a marked elevation of the thin endothelial cell membranes lining the pulmonary capillaries.⁶ This was followed shortly by widespread pulmonary capillary thrombosis and death. The similarity between the clinical features of terminal anthrax in man and experimental animals and those observed in rats given toxin suggested that a morphologic study of the lungs of animals dying of anthrax might add valuable information about the cause of death in this disease.

Materials and Methods

Necropsies were performed on all animals that died following infection with the virulent Vollum strain (VIB) of *Bacillus anthracis* in the experiments summarized below.

Rats.—Twenty-seven male Fischer 344 rats,⁷ weighing 200-250 gm, were injected intraperitoneally with 5×10^8 spores in 1 ml of distilled water. Seventeen died from 9 to 65 hours afterward, two were sacrificed at 20 hours, and eight survived.

Guinea Pigs.—Fifteen male Hartley guinea




Fig 1.—Routine histologic section of the lung of an infected rat that was injected with India ink following the onset of signs of respiratory failure. All of the black spots in this photograph represent pulmonary capillaries that contain ink particles (methylene blue, $\times 80$).

pigs, weighing 230-280 gm, were given 5×10^8 spores intraperitoneally and another 15 were inoculated subcutaneously with 200 spores in 0.1 ml distilled water. All of the former group and 9 of the latter group died in 23 to 100 hours.

Rabbits.—Four male albino rabbits, weighing 1,400-1,800 gm, were inoculated subcutaneously with 5×10^7 spores and died in 58 to 85 hours.

Eight rats, nine guinea pigs, and one rabbit were under continuous observation from the first signs of illness until death. India ink, diluted in saline, was administered to some of the sick animals. At 20 hours after they had been inoculated with spores, 1 ml of a 1:20 dilution of ink was injected intravenously into two rats with signs of respiratory difficulty and into two rats without signs of illness. The two sick rats died 20 minutes later and the two asymptomatic ones were killed at the same time. The same dose of India ink was administered intracardially to four sick guinea pigs from 3 to 45 minutes before they died. Eighteen minutes before death, one rabbit was given 2 ml of a 1:10 dilution of ink intravenously. These doses of ink did not cause vascular staining in normal uninfected rabbits of similar age and weight. Tissues from ten rats, nine guinea pigs, and two

rabbits were examined by light and electron microscopy. One of the rabbits was necropsied within an hour after death; in each of the other animals processing of tissues was begun within 2 minutes after death.

The lungs of all animals were removed immediately after death and were perfused through the trachea with an 8% solution of phosphate-buffered formalin (pH 7). The lungs were then submerged in additional 8% buffered formalin. The entire brain and small pieces of tissue from the kidneys, spleen, liver, heart, and skeletal muscle were also fixed in 8% buffered formalin. When kidney tissue was prepared for electron microscopy, it was cut into 1-mm blocks in a drop of cold 2% osmium tetroxide in Millonig's buffer and then placed in additional fixative for 30 minutes. Formalin-fixed tissues were cut and processed for routine histology. In addition small pieces of formalin-fixed lung tissue were cut into 1-mm blocks and placed in 2% osmium tetroxide in Millonig's buffer for 30 minutes. The small blocks of lung and kidney tissue were dehydrated and embedded in Epon 812. Ultrathin sections were cut, using a diamond knife with an ultramicrotome (Porter-Blum), placed on grids, stained with uranyl acetate, and examined with an electron microscope (RCA EMU-3G).

Results

Terminal Respiratory Failure.—Following the inoculation of spores there was a period during which the animals did not appear to be sick. The terminal phase of the disease in all species began with the sudden onset of signs of respiratory difficulty. The respiratory movements appeared to be labored and the rabbit and the rats began to breathe faster. The severity of respiratory distress increased; eventually all animals became cyanotic and died gasping for air, usually within an hour after labored respiration was discernible.

Morphological Findings.—At necropsy an enlarged spleen and hyperemic lungs were observed in all animals. There was no gross evidence of pulmonary edema; the lungs collapsed when the chest was opened and were of normal size. Routine microscopic examination revealed that the spleens were congested and hemorrhagic, with necrosis at the centers of the lymph follicles; there was some evidence of minimal pulmonary edema. Large numbers of anthrax bacilli were seen

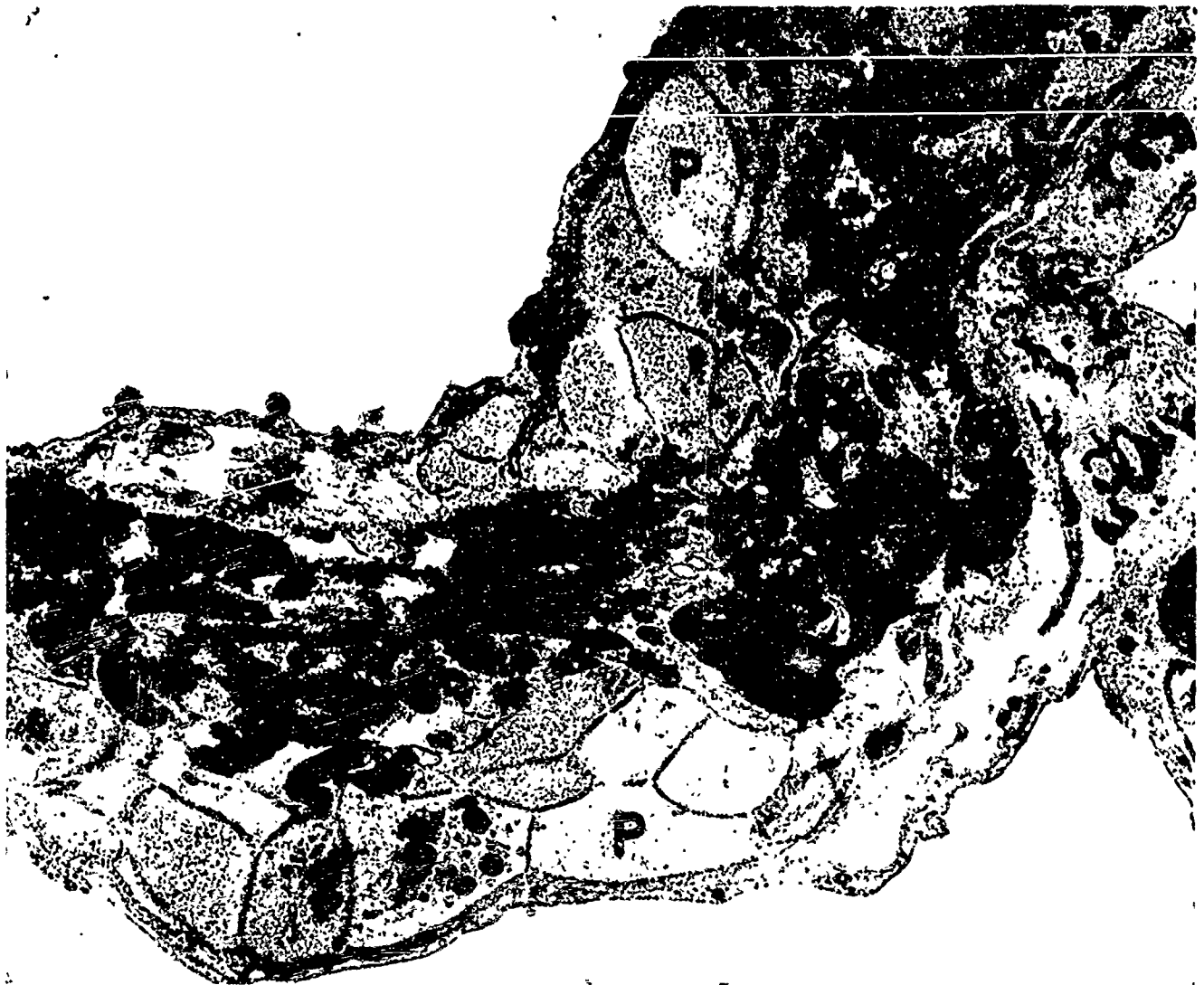

Fig 2.—Electron micrograph of a pulmonary capillary from the lung of a rat that died of anthrax. The wall of the capillary is intact but the lumen is filled with a thrombus composed of an outer layer of swollen, degranulated platelets (p) and a central core of dense fibrillar fibrin (f) (uranyl acetate, $\times 12,600$).

in the blood, the sinusoids of the liver and spleen, the pulmonary capillaries, and the renal glomeruli of the rabbits and guinea pigs; only an occasional bacillus was encountered in similar specimens from the rats. Other observations in the several species are described below.

Rats.—The peritoneal cavities of the rats contained 0.5 to 1.0 ml of cloudy fluid and, in most cases, there was a similar volume of clear fluid in the pleural cavities. In several rats the chest cavities appeared to be unusually moist but there was no accumulated fluid.

The lungs and kidneys of the two rats given India ink during the terminal phase of the disease were dark gray. The routine sections of the lungs of these rats contained many carbon-stained capillaries (Fig 1).

Electron microscopic examination of the pulmonary capillaries revealed that the carbon particles were trapped within small capillary thrombi composed of platelets and fibrin. Many similar capillary thrombi were also found in the lungs of rats that had not been injected with India ink before death (Fig 2). In addition to the many thrombosed capillaries, others were not completely occluded but contained leucocytes and strands of dense fibrin (Fig 3).

Most of the glomeruli in the routine sections of the kidneys from the two rats injected with India ink during the terminal phase of the disease contained deposits of carbon particles (Fig 4). Electron microscopic examination of these glomeruli showed that the carbon was trapped in thrombi composed of granular material. The glomerular capillaries of rats that had not been injected with

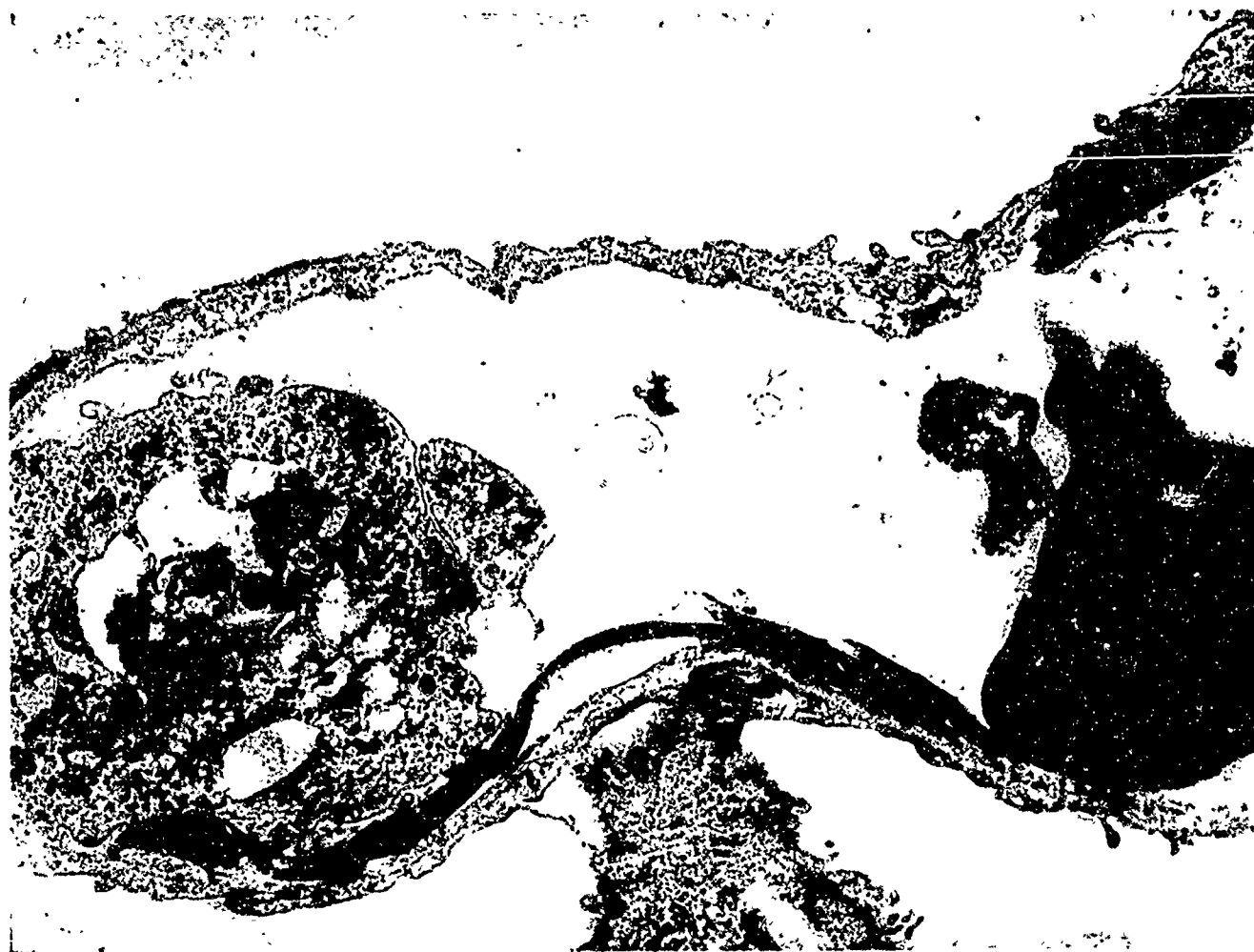

Fig 3.—Electron micrograph of a pulmonary capillary from the lung of a rat that died of anthrax. It had been injected with India ink after the onset of signs of respiratory failure. The lumen is not occluded but contains a leucocyte (leu), an erythrocyte (rbc), and several strands of dense fibrillar fibrin (f) with a few electron-dense carbon particles (uranyl acetate, $\times 12,600$).

ink often contained strands of dense fibrillar fibrin.

The lungs and kidneys of the two rats that showed no signs of illness at the time they were injected with India ink were of normal color and microscopic examination revealed no evidence of capillary thrombosis.

Guinea Pigs.—From 0.5 to 1.5 ml of clear pleural fluid was present in about two thirds of the guinea pigs; the others had no fluid in the pleural cavities. The site of injection in the guinea pigs that had been inoculated subcutaneously was marked by an area of gelatinous edema. From 1 to 2 ml of cloudy ascitic fluid was present in the animals that had been inoculated intraperitoneally.

The lungs of the sick guinea pigs that had been given India ink before death were gray; the kidneys were of normal color. Routine microscopic examination of the lungs revealed many carbon-filled capillar-

ies. The number of pulmonary capillaries containing carbon particles was less than in the rats but larger vessels were occluded. These vessels, which appeared to be large capillaries, were occluded by layered thrombi composed of an outer ring of platelets and a central core of fibrin, platelets, and carbon particles (Fig 5). Many pulmonary capillaries were not occluded but were dilated and contained bacilli and clusters of granular fibrin.

There was no carbon staining of the glomeruli in the guinea pigs that were injected with India ink before death. The renal tubules in all the guinea pigs appeared to be normal. Although there was no definite evidence of capillary thrombosis, electron microscopic examination of the renal glomeruli revealed that many capillaries contained bacilli and coarse, granular material.

Rabbits.—The rabbit that was necropsied within an hour after death had 15 ml of

fluid in the pleural cavities; no pleural fluid was present in the other rabbit. The lungs of the latter rabbit, which had been injected with India ink before death, were gray; the kidneys were normal in color. As in the rats and guinea pigs, routine microscopic examination showed that many pulmonary capillaries contained carbon particles. In this rabbit, more pulmonary capillaries were occluded than in the guinea pigs but fewer than in the rats. The thrombi were similar to those found in the pulmonary capillaries of the guinea pigs; similarly, many of the capillaries that were not occluded contained clusters of granular fibrin. In some cases the clumps of granular fibrin had central strands of mature fibrillar fibrin (Fig 6).

There was no carbon staining of the renal glomeruli in the rabbit given India ink before death. Many of the renal glomeruli in both rabbits were partially destroyed by colonies of anthrax bacilli and the convoluted tubules were often lined by degenerating epithelial cells with eosinophilic cytoplasm and pyknotic nuclei. The latter changes are similar to those found by Nordberg² in the kidneys of rabbits killed by anthrax. The rabbit kidneys were not examined with the electron microscope.

In these studies, no alterations were observed in the endothelial cells lining the pulmonary or renal capillaries in any of the animals. In all cases the cytoplasmic membranes appeared to be intact and the intercellular junctions appeared normal.

Comment

There are several theories concerning the mechanism of death in anthrax.⁸ The most widely accepted of these was proposed by Smith and his associates who studied the terminal phase of anthrax in guinea pigs injected subcutaneously with spores.^{9,10} The guinea pigs developed marked subcutaneous edema and had decreased circulating blood volume, hemoconcentration, prolonged clotting time, lowered body temperature, decreased plasma pH and bicarbonate concentration and evidence of acute renal failure with oliguria and nitrogen retention. Smith and his colleagues interpreted these findings as indicating that anthrax killed guinea pigs

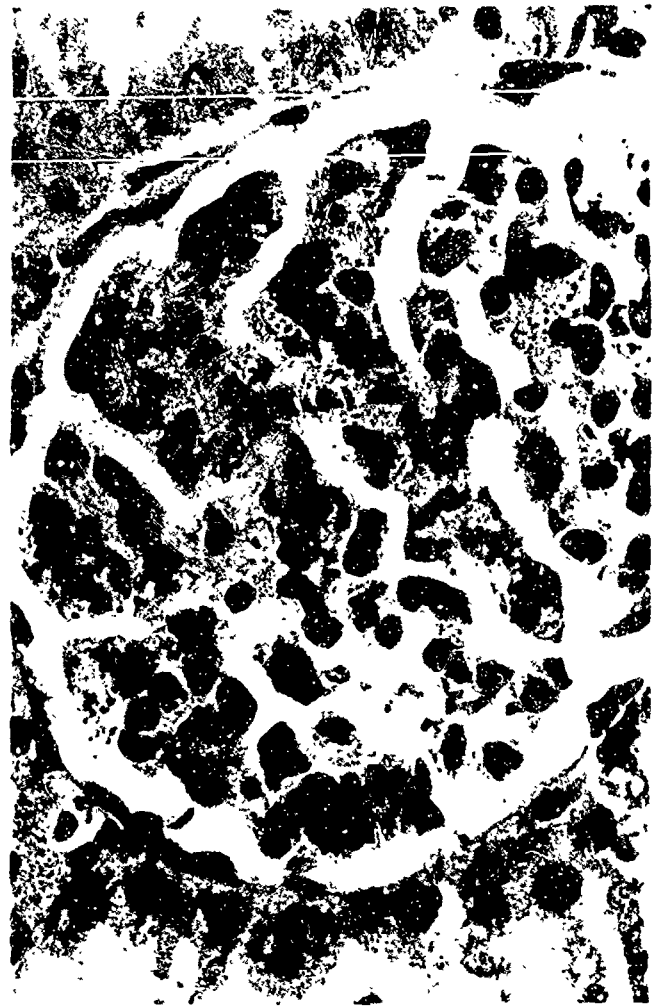

Fig 4.—Routine histologic section of a glomerulus from the kidney of an infected rat that was injected with India ink shortly after the development of signs of respiratory failure. Glomerular capillaries are distended with material containing clusters of ink particles (hematoxylin and eosin, $\times 800$).

by causing increased vascular permeability with marked edema, diminished circulating blood volume, and secondary shock. The impaired renal function and degenerative tubular changes described by Ross¹¹ were felt to represent lower nephron nephrosis resulting from secondary shock.

One objection to this theory of the mechanism of death in anthrax is that many animals die of the disease without evidence of massive edema. For example, if guinea pigs and rabbits are inoculated with spores intraperitoneally there is no subcutaneous edema and only minimal ascites. Another objection is that this theory does not explain adequately the signs of acute respiratory failure that are so prominent in the terminal phase of the disease.

The results of our morphologic studies of the lungs of rats dying of anthrax toxin⁶

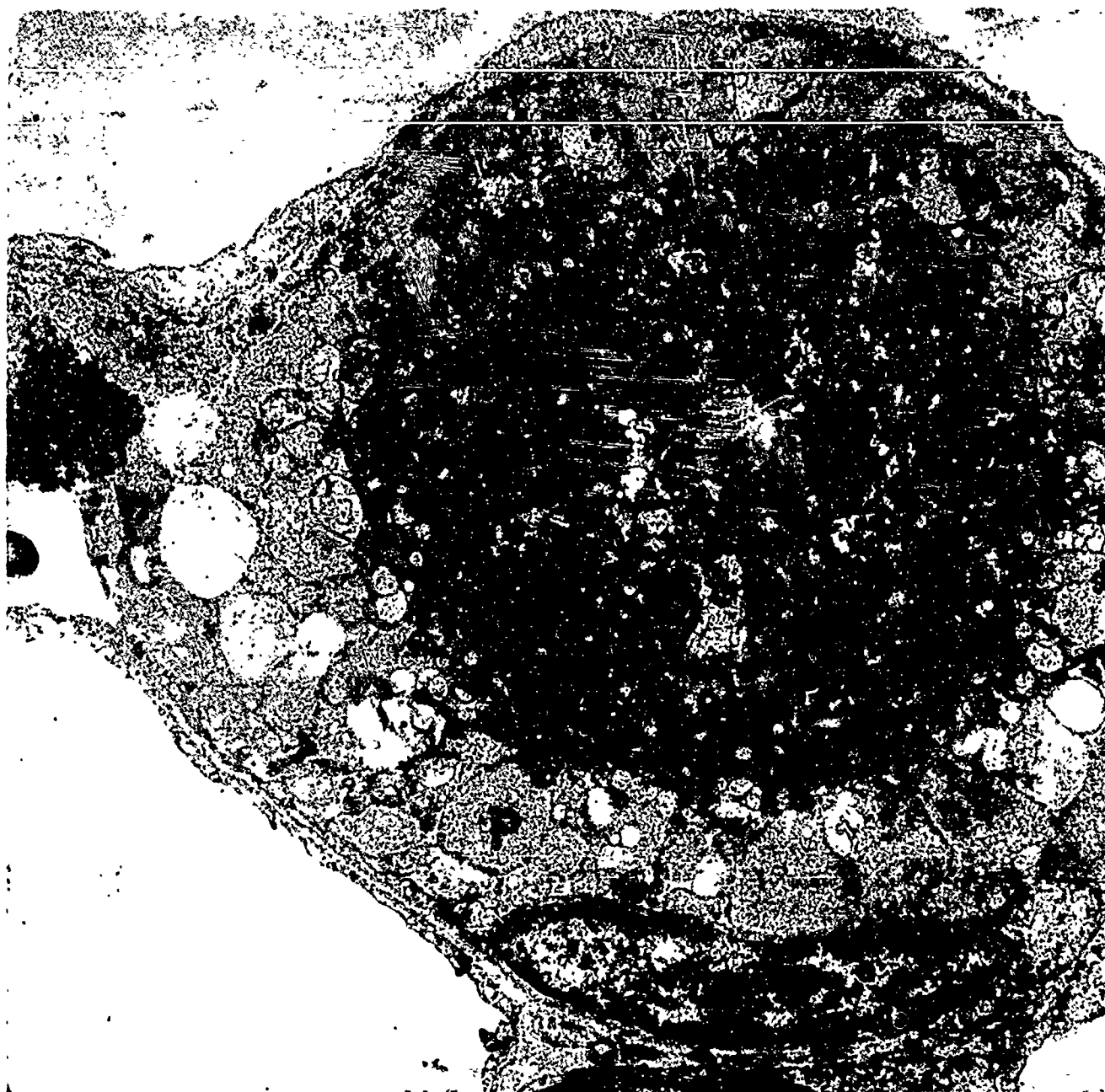

Fig 5.—Electron micrograph of a large pulmonary capillary from the lung of an infected guinea pig that had been injected with india ink after the onset of respiratory distress. The nucleus (n) of an endothelial cell is seen at the bottom of the photograph. The endothelial cell membrane lining the capillary is intact but the lumen is occluded by a large thrombus composed of an outer ring of swollen, degranulated platelets (p) and a central core of dense fibrin (f), platelets and carbon particles (c). A cross section of an anthrax bacillus is present (uranyl acetate, $\times 7,000$).

and our present clinical and morphologic studies of anthrax septicemia in rats, guinea pigs and rabbits suggest that anthrax toxin acts directly upon the membranes of the capillary endothelial cells to cause increased permeability and capillary thrombosis. In rats, guinea pigs, and rabbits the pulmonary capillary bed is chiefly involved in this process during anthrax septicemia, and the appearance of widespread pulmonary capillary thrombosis coincides with the development of acute respiratory failure and death. Similar morphologic changes were also ob-

served in the lungs of monkeys that died of experimental respiratory anthrax (unpublished work).

Definite evidence of renal glomerular thrombosis was obtained only with the rat. When India ink was injected into sick rats there was staining of the glomerular capillaries as well as of the pulmonary capillaries. Electron microscopic photographs of the glomeruli showed strands of mature fibrin within the capillary lumen. There was no carbon staining of the glomeruli in the rabbit and guinea pigs that were injected

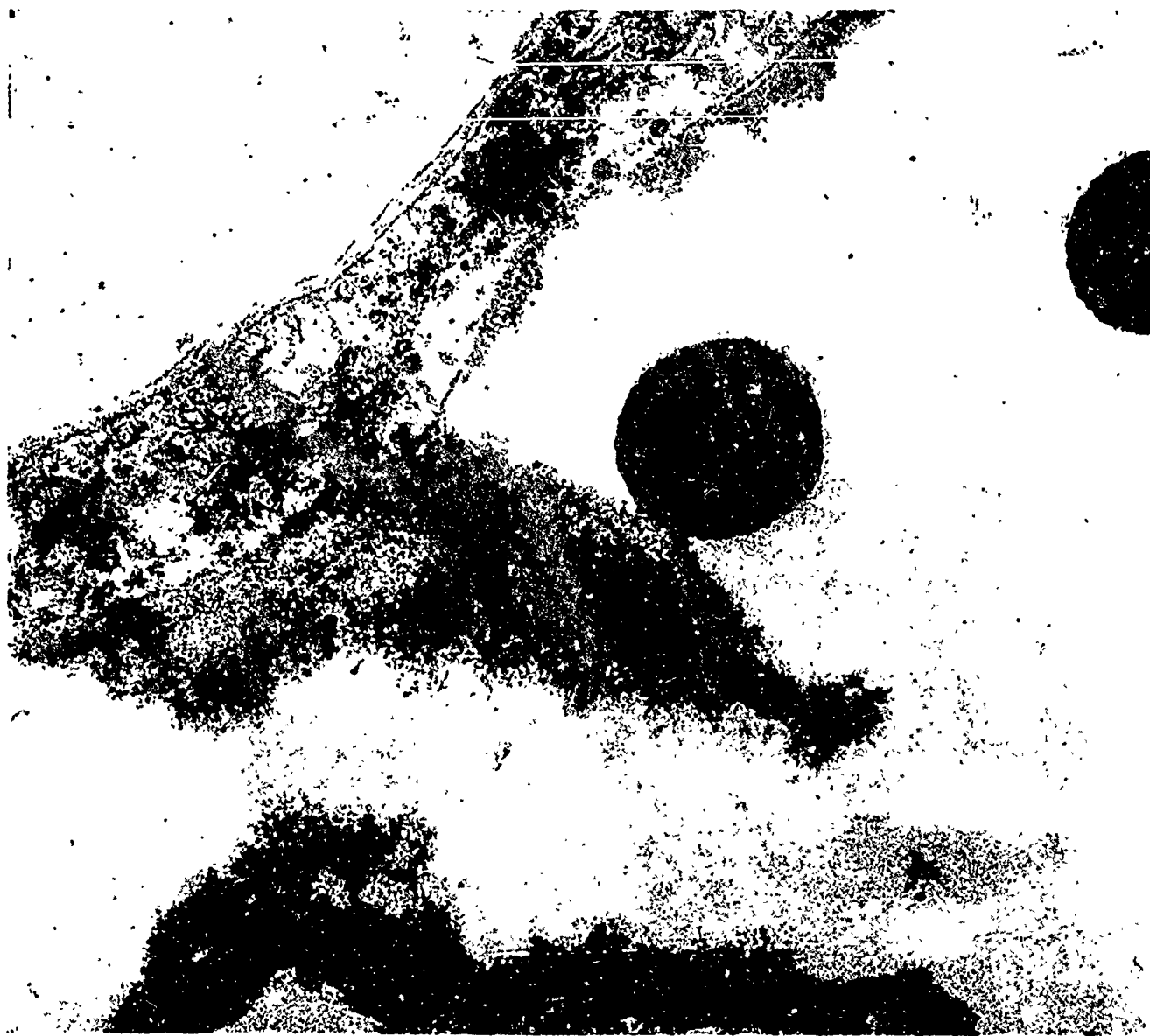


Fig 6.—Electron micrograph of a portion of a capillary from the lung of a rabbit that died of anthrax. The capillary lumen contains two anthrax bacilli and clusters of granular fibrin (f), one of which has a central core of dense fibrillar fibrin with prominent cross striations. The capillary wall appears normal (uranyl acetate, $\times 51,000$).

with India ink during the terminal stage of anthrax, and electron micrographs of the glomerular capillaries in guinea pigs showed only granular material not conclusively identifiable as fibrin. Further investigation is required to determine whether glomerular thrombosis preceded the kidney damage reported in these species.^{2,11}

One of the interesting aspects of this study in relation to the basic pathology of altered capillary function is the lack of ultrastructural change in the walls of the pulmonary capillaries. An alteration in capillary endothelial cells was observed in Fischer 344 rats given lethal doses of anthrax toxin.⁶ Associated with the increased vascular permeability and massive pulmonary

edema in those rats one might have expected to find such changes as destruction of endothelial cells or separation of intercellular junctions.^{12,13} Instead, the only alteration was an elevation of the thinnest portion of the cytoplasmic processes of the endothelial cells away from the underlying basement membrane. This change, which probably results from an accumulation of fluid between the cell and the basement membrane, occurs as pulmonary edema develops, and was followed terminally by the appearance of widespread pulmonary capillary thrombosis. In the present study, the animals dying of anthrax infection had very little pulmonary edema and the changes of the endothelial cell membranes described above were not ob-

served. Instead, the signs of respiratory failure were associated only with widespread pulmonary capillary thrombosis. The layered or ring structure of the capillary thrombi suggests that they were formed in situ. However, there is no apparent morphological explanation for the thrombosis because the involved capillaries were lined by intact endothelial cells that appeared normal. These findings suggest that the increased capillary permeability and thrombosis caused by anthrax toxin are the result of some subtle changes in the physical properties of the endothelial cell membranes.

The results of our study indicate that pulmonary capillary thrombosis is the immediate cause of death in anthrax of rats, rabbits, and guinea pigs. The similarity between the clinical features of terminal anthrax septicemia in our experimental animals and in patients¹ suggests that pulmonary capillary thrombosis might also be a mechanism of death in human anthrax. There have been a few recent reports of fatal anthrax in hu-

mans.¹⁴⁻¹⁷ In some of these reports the cause of death was felt to be due to massive hemorrhagic mediastinitis which is so often seen in cases of inhalation anthrax, but in other reports there was no morphologic explanation for the mechanism of death of these individuals.¹⁸ None of these case reports contain electron microscopic studies of human material but one possible morphologic clue to the presence of microthrombi in the lungs of patients dying of anthrax is the occasional description of numerous dilated pulmonary capillaries^{15,20} and the presence of leukocyte thrombi in small pulmonary blood vessels.¹⁷ Dilated capillaries filled with bacilli are such a common morphologic feature of fatal anthrax septicemia that for many years before the discovery of anthrax toxin⁹ pathologists believed the mechanical obstruction of capillaries by the bacilli was the mechanism of death in anthrax septicemia.¹⁸

Mrs. Frances G. Shirey and Mr. Richard W. Hill provided technical assistance.

References

1. Plotkin, S.A., et al: An Epidemic of Inhalation Anthrax, the First in the Twentieth Century: I. Clinical Features *Amer J Med* 29:992-1001, 1960.
2. Nordberg, B.K.; Schmitterlow, C.G.; and Hansen, H.J.: Pathophysiological Investigations Into the Terminal Course of Experimental Anthrax in the Rabbit, *Acta Path Microbiol Scand* 53:295-318, 1961.
3. Jackson, F.C.; Wright, G.G.; and Armstrong, J.: Immunization of Cattle Against Experimental Anthrax With Alum-Precipitated Protective Antigen or Spore Vaccine. *Amer J Vet Res* 18:771-777, 1957.
4. Berdjis, C.C., and Gleiser, C.A.: Experimental Subcutaneous Anthrax in Chimpanzees, *Exp Molec Path* 3:63-75, 1964.
5. Beall, F.A.; Taylor, M.J.; and Thorne, C.B.: Rapid Lethal Effect in Rats of a Third Component Found Upon Fractionating the Toxin of *Bacillus anthracis*, *J Bact* 83:1274-1280, 1962.
6. Beall, F.A., and Dalldorf, F.G.: The pathogenesis of the lethal effect of Anthrax Toxin in the Rat, *J Infect Diseases* 116:377-389, 1966.
7. Taylor, M.T.; Kennedy, G.H.; and Blundell, G.P.: Experimental Anthrax in the Rat: I. The Rapid Increase of Natural Resistance Observed in Young Hosts, *Amer J Path* 38:469-480, 1961.
8. Lincoln, R.E., et al: Anthrax, *Adv Vet Sci* 9:327-368, 1964.
9. Keppie, J.; Smith, H.; and Harris-Smith, P.W.: The Chemical Basis of the Virulence of *Bacillus anthracis*: III. The Role of the Terminal Bacteremia in Death of Guinea Pigs From Anthrax, *Brit J Exp Path* 36:315-322, 1955.
10. Smith, H.; et al: The Chemical Basis of the Virulence of *Bacillus anthracis*: IV. Secondary Shock as the Major Factor in Death of Guinea Pigs From Anthrax, *Brit J Exp Path* 36:323-335, 1955.
11. Ross, J.M.: On the Histopathology of Experimental Anthrax in the Guinea Pig, *Brit J Exp Path* 36:336-339, 1955.
12. Cotran, R.S.: The Delayed and Prolonged Vascular Leakage in Inflammation: II. An Electron Microscopic Study of the Vascular Response After Thermal Injury, *Amer J Path* 46:589-620, 1965.
13. Cotran, R.S., and Majno, G.: A Light and Electron Microscopic Analysis of Vascular Injury, *Ann NY Acad Sci* 116:750-763, 1964.
14. Albrink, W.S.: Human Inhalation Anthrax: A Report of Three Fatal Cases, *Amer J Path* 36:457-472, 1960.
15. Gold, H.: Studies on Anthrax: Clinical Report of Ten Human Cases, *J Lab Clin Med* 21:134-152, 1935.
16. Cowdery, J.S.: Primary Pulmonary Anthrax With Septicemia, *Arch Path* 43:396-399, 1947.
17. Shennan, T., and Miller, J.: Bronchial Anthrax, *J Path Bact* 14:556-562, 1909.
18. Albrink, W.S.: Pathogenesis of Inhalation Anthrax, *Bact Rev* 25:268-273, 1961.