

## CARBON TETRACHLORIDE-INDUCED HEPATOTOXICITY IN RATS - PROTECTIVE ROLE OF AQUEOUS LEAF EXTRACTS OF *COCCINIA GRANDIS*

P. VINOTH KUMAR<sup>1</sup>, A. SIVARAJ<sup>1</sup>, EK.ELUMALAI<sup>2</sup>, B. SENTHIL KUMAR<sup>1\*</sup>

<sup>1</sup>P.G. & Research department of Zoology, C.Abdul Hakeem College, Melvisharam- 632 509, Vellore-Dt, T.N. India.

<sup>2</sup>P.G. & Research department of Zoology, Voorhees college, Vellore-Dt, T.N. India.

\*Corres. Author: [senthil\\_cahc@yahoo.co.in](mailto:senthil_cahc@yahoo.co.in)

**ABSTRACT:** The present study was conducted to evaluate the hepatoprotective effects of an aqueous leaf extract of *Coccinia grandis* on carbon tetrachloride (CCl<sub>4</sub>) induced liver damage in *albino* rats. Wistar *albino* rats weighing around 180-200g were used. Toxicity was induced by using 30% CCl<sub>4</sub> suspended in olive oil (1.0 ml/kg body wt intraperitoneal) after every 72 hrs for 3doses. The aqueous leaf extract at a dose of 250mg/kg was administered orally by intragastric tube for 10 days. Blood and liver tissue were collected for the assessment of serum marker enzymes such as ALT, AST and ALP. The liver tissue was used for histopathological assessment.

**Keywords:** *Coccinia grandis*, CCl<sub>4</sub>, Alkaline phosphatase (ALP), Alanine amino transaminase (ALT), Aspartate aminotransaminase (AST).

### INTRODUCTION

The liver disorders are one of the world problems. Despite its frequent occurrence, high morbidity and high mortality, its medical management is currently inadequate, so far not yet any therapy has successfully prevented the progression of hepatic disease, even though newly developed drugs have been used to treat chronic liver disorders, these drugs have often side effects. Therefore, that is an essential research about suitable herbal drugs that could replace the chemical ones<sup>1</sup>.

Liver injury due to chemicals (or) infectious agents may lead to progressive liver fibrosis and ultimately cirrhosis and liver failure<sup>2</sup>. However, no effective treatment that delays disease progression and complications has yet been found. Several recent studies

suggest that traditional herbs and micronutrients such as carotenoids and selenium may be useful for this purpose<sup>3,4</sup>. Carbon tetrachloride CCl<sub>4</sub> is widely used for experimental induction of liver damage<sup>5</sup>. The principle causes of carbon tetrachloride (CCl<sub>4</sub>) is induced hepatic damage in lipid peroxidation and decreased activities of antioxidant enzymes and generation of free radicals<sup>6,7</sup>. Various medicinal plants have been used to treat for various diseases in all over the world. Nowadays, Indian medicinal plants are belonging to about 40 families were investigated as liver protective drugs<sup>8</sup>.

*C. grandis* commonly known as "Ivy gourd" is a tropical plant belonging to the family Cucurbitaceae. It has been found in many countries in Asia and Africa. The roots, stems, leaves and whole plant of *C. grandis* are used in the treatment of jaundice, bronchitis, skin eruptions, burns, insect bites, fever, indigestion, nausea, eye infections, allergy, syphilis, gonorrhoea, etc.<sup>9</sup>. The leaves of this plant are widely used in Indian folklore medicine for reducing the amount of sugar in urine of diabetes patients suffering from diabetes mellitus. Literature suggests that the use of this plant is in the treatment of diabetes<sup>10</sup>. The crude hydromethanolic extract of the leaves of *C. grandis* has been reported for

---

\*Corres author:

**Dr. B. Senthil kumar M.Sc., Ph.D. FAEB.**

**Post Graduate and Research department of Zoology.**

**C.Abdul Hakeem college, Melvisharam, 632 509. Tamilnadu .India.**

**Email- [senthil\\_cahc@yahoo.co.in](mailto:senthil_cahc@yahoo.co.in)**

**Phone - 09442378655**

---

its xanthine oxidase inhibitory and hypouricaemic activities<sup>11</sup>.

## MATERIALS AND METHODS

### Plant material

The *Coccinia grandis* (Family: Cucurbitaceae) leaves were collected during Nov-Jan of 2008 in and around Vellore, Tamilnadu were authenticated by department of botany. The voucher specimens were kept in the department of botany in C.Abdul Hakeem College, Melvisharam, Vellore, Tamilnadu, India.

### Plant extracts preparation

The shade dried plant materials of *Coccinia grandis* L., leaves were powdered separately in an electrical blender and stored at 5°C until further use. 100 gram of the dried plant powder was taken separately and mixed with 500ml of distilled water and then magnetically stirred in a separate container overnight at room temperature. The residue was removed by filtration and the aqueous extracts were lyophilized and concentrated under vacuum to get solid yield 10% (leaves). It was used for the experiment work.

### Animal

Wistar albino rats weighing 180-200g were collected from the Institute of Veterinary Preventive Medicine (IVPM) at Ranipet in Vellore District, Tamilnadu. Animals were housed in clean polypropylene cages with 12±1 hr light/dark schedule and fed with normal pellet (Hindustan Lever Ltd., Bangalore., India) rat chow diet and water ad libitum. The study protocol was approved by the Institutional Animals Ethics Committee (IAEC).

### Experimental design:

The rats were randomly divided into 4 groups of 6 rats each.

Group I: Animals served as normal control and received distilled water (1ml/kg body wt.) orally for 10 days. Group II: Animals received as olive oil 1ml/kg body wt i.p after every 72 hrs 3 doses. Group III: Animals constituted the hepatotoxic group, which received 30% CCl<sub>4</sub> in olive oil (1 ml/kg body wt i.p) after every 72 hrs 3 doses. Group IV: CCl<sub>4</sub> treated groups administered with *Coccinia grandis* L., aqueous leaf extracts orally 250 mg/kg body wt for 10 days to the CCl<sub>4</sub> induced animal.

### Estimation of biochemical parameters:

At the end of the experimental period, animals were sacrificed by cervical decapitation. Blood were collected and serum was separated for biochemical analysis. Liver marker enzymes such as Asparate amino transaminase (AST), Alanine amino transaminase (ALT) and Alkaline phosphatase (ALP) were estimated<sup>12,13</sup>. The liver tissue was excised in 10% neutral buffered formalin for histopathological studies<sup>14</sup>.

### Histopathological studies

Anatomy of the liver was studied immediately after sacrificing the animals. A small portion was fixed in 10% neutral buffered formalin as described by Luna<sup>14</sup>.

Thin sections of 4-5 µm were taken, stained with Haematoxylin and Eosin and histology was studied. The results were expressed in Mean ± SEM, Student's 't' test was used for statistical significance between groups.

## RESULTS

The results showed in the table - 1 exhibit the significant hepatoprotective effects of the plant *Coccinia grandis*. The levels of serum Asparate amino transaminase (AST), Alanine amino transaminase (ALT) and Alkaline Phosphate (ALP) were taken as an index for hepatotoxicity induced by CCl<sub>4</sub>. The levels of AST, ALT and ALP were analyzed in serum samples of different groups of albino rats shown in table 1. Serum marker enzymes such as ALT, AST and ALP were analyzed for the control and experimental animals. In the group II (control) olive oil treated animals, showed the level of marker enzymes were not significantly elevated when compared to the normal group I animals. The level of marker enzymes of group III CCl<sub>4</sub> induced animals were significantly increased (P<0.05) when compared to the normal and control animals. But there was a significant decrease of the enzyme level (P<0.001) in the aqueous leaf extract of *coccinia grandis* L., treated animals (group IV). Carbon tetrachloride is reported to produce free radicals, which affect the cellular permeability of hepatocytes leading to elevated levels of serum biochemical parameters like ALT, AST, and ALP.

Histopathological studies of the liver section of control and experimental animals were shown in (fig.1-4), was carried out to test the hepatoprotective effect of the aqueous leaf extracts of *Coccinia grandis*.

The fig-1 shows the liver section of Group 1 (normal Control) animals which has normal architecture, where the central veins, portal tracts, hepatocytes and sinusoids appear normal. The lobular unit is also well identified. Fig-2 shows Group-II (olive oil control) animals liver section has no significant pathological changes when compared to the normal. Group-III (CCl<sub>4</sub> induced) animals liver section (fig-3) showed the damage of the liver cells. There are extensive areas of patchy and confluent hepatocyte necrosis and lobular inflammation, Sinusoidal spaces are flooded with inflammatory cells and RBC's.

The aqueous leaf extracts (*C. grandis*) treated animals of Group-IV: showed complete reversal of toxic effects in the liver cells (fig-4) No necrosis seen. The central vein and portal triads appear normal. Some of the hepatocytes showed binucleation suggesting regenerative activity with feathery degeneration of hepatocytes.

The improved histology of the liver as seen in histopathological observation on animals treated with the plant material as compared to that seen in animals administered only CCl<sub>4</sub> indicated in possibility of the plant material being able to induce accelerated regeneration of the liver.

## DISCUSSION

This study was undertaken to demonstrate the protective ability of aqueous leaf extracts of *Coccinia grandis* on liver damage induced by CCl<sub>4</sub> and the toxic effects of the similar doses in rats. The damage of the liver caused by CCl<sub>4</sub> was evident by the alteration in serum marker enzymes concentration beside the clinical signs and histopathology. The use of aqueous leaf extracts of *Coccinia grandis* protects the liver from damage by CCl<sub>4</sub> as evident by improved histologic picture and biochemical markers of liver damage. The mechanism of the hepatoprotective action of the plant is uncertain but may be related to the ability of the plant to inhibit lipid peroxidation in the liver. The CCl<sub>4</sub> induced hepatotoxicity produced in rats leading to hepatic injury triggers the generation of toxic radicals which can be masked by using a correct antioxidant in adequate amount. The presence of flavonoids, tannins, saponins and terpenoids in *Coccinia grandis* explain its role in

hepatoprotection by inhibiting the free radicals mediated damage<sup>15,16</sup> claimed that flavonoids, triterpens and tannin were antioxidant agent and may interfere with free radicals formation<sup>17</sup> stated that hepatoprotective activities of certain flavonoids are known.

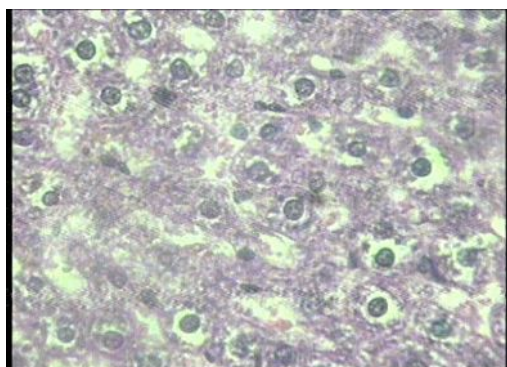
The hemorrhage caused by CCl<sub>4</sub> in the liver was minimized by use of plant extract as flavonoids are known to be vasculo protector. On the basis of results obtained it can be concluded that the aqueous leaf extract of *Coccinia grandis* leaves seems to possess hepatoprotective activity in *albino* rats. Further studies are needed to evaluate the potential usefulness of this extract in clinical conditions associated with liver damage.

In conclusion, the results of the present study indicated that under the present experimental conditions, aqueous leaf extract of *Coccinia grandis* L. showed hepatoprotective effects against carbon tetrachloride induced liver damage in albino rats.

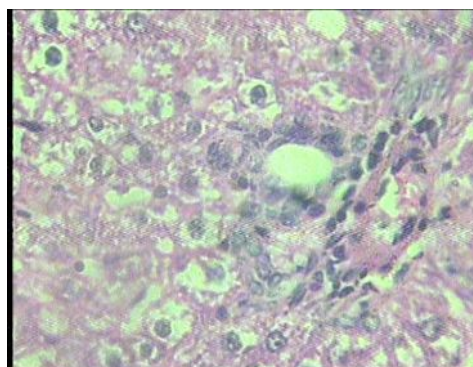
**Table 1: Effect of *Coccinia grandis* aqueous leaf extract on liver marker enzymes in normal and experimental animals.**

Parameters	Normal (Group I)	Olive oil (Group II)	CCl <sub>4</sub> induced (Group III)	<i>C. grandis</i> treated (250 mg/kg) (Group IV)
ALT(Units/ml)	45.20±6.22	48.20±2.09	119.20±10.79**	61.73±3.91**
AST (Units/ml)	53.20±5.02	55.10±2.25	171.05±11.0**	47.51±1.90**
ALP (KAUnits)	50.10±8.12	51.60±2.61	103.63±7.69**	57.57±9.7**

**Keys:** Values are mean ± SEM for 6 animals in each observation, P denotes statistical significance P\* < 0.01; \*\* P < 0.001; the experimental animals were compared to normal groups.



**Fig-1: Normal hepatic cells.**



**Fig-2: Olive oil treated hepatic cells**

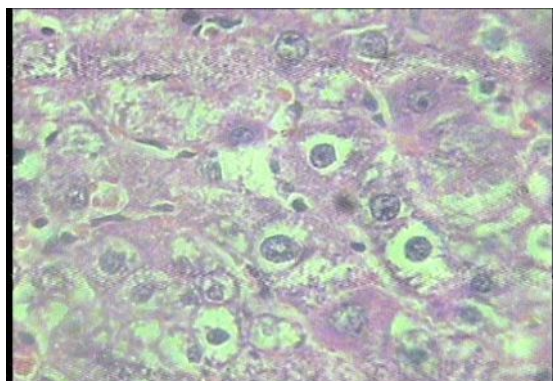


Fig-3: CCl<sub>4</sub> induced damaged hepatic cells

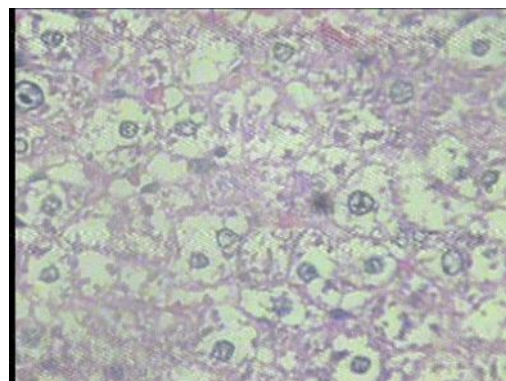


Fig-4: *Coccinia grandis* treated hepatic cells

#### ACKNOWLEDGEMENTS

The author thankfull to C. Abdul Hakeem College for providing facilities to carry out of the experimental work. Our sincere thank to Dr. K.Devi, Department of Zoology, DKM College, Vellore, Tamilnadu for his valuable suggestion and constant encouragement.

#### REFERENCES

1. Bruck, RR, Hershkoviz, O, Lider, H, Aeed, L, Zaidel, Z, Matas, J, Berg, Helpem, Z. Inhibition of experimentally induced liver cirrhosis in rats by a nonpeptidic mimetic of the extracellular matrix associated Arg-Gly-Asp epitope. *J Hepatol.* 1996; 24:731-738.
2. Anand, BS. Cirrhosis of liver. *West L Med.* 1999;171:110-115.
3. Hinds, TS, Wesk, WL, Knight, EM. Carotenoids and retinoids: A review of research, clinical and public health applications. *clin pharmacol.* 1997;37: 551-8.
4. We YT, Liu DW, Ding LY, Liq, Xiao YH. Therapeutic effects and molecular mechanical of antifibrosis herbs and selection on rats with hepatic fibrosis. *World. J Gastroenterol.* 2004; 10:703-6.
5. Parola, M, Leonarduzz, G, Biasi, F, Albono, M, Biocca, G, Polic, Dianzani, MU. Vitamin E dietary Supplementation. Protects against CCl<sub>4</sub> induced chronic liver damage and cirrhosis. *Hepatology.* 1992;16:1014-1021.
6. Castro, JA, De Ferreyra, EC, De castro, CR, Fenoos, OM, Sasame, H, Gillette, JR. Prevention of carbon tetrachloride-induced necrosis by inhibitors of drug metabolism-further studies on their mechanism of action. *Biochem pharmacol.* 1974; 23:295-302.
7. Poli, G. Liver damage due to free radicals. *Br Med bull.* 1993; 49:604-20.
8. Handa, SS, Sharma, A, Chakraborti, KK. Natural products and plants as liver protecting drugs. *Fitoterapia.* 1986; 57:307-45.
9. Wasantwisut, E, Viriyapanich, T. Ivy gourd (*Coccinia grandis* Voigt, *Coccinia cardifolia*, *Coccinia indica*) in human nutrition and traditional applications. In: Simopoulous, A.P, Gopalan, C., eds. *Plants in Human Health and Nutrition Policy*: Karger, Basel, World Reviews of Nutrition and Dietics.2003; pp. 60-66.
10. Venkateswaran, S, Pari, L. Effect of *Coccinia indica* leaves on antioxidant status in streptozotocin induced diabetic rats. *J Ethnopharmacol.* 2003; 84(2-3):163-168
11. Umamaheswari, M, Ashokkumar, K, Somasundaram, A, Sivashanmugam, T, Subhadradevi, V, Ravi, TK. Xanthine oxidase inhibitory activity of some Indian medical plants. *J Ethnopharmacol.* 2007;109:547-551.
12. Bergmeyer, H, Bernt, E, In; Varley, H, Gowenlock, AH, Bell, M. *Practical Clinical Biochemistry*, 5<sup>th</sup> Edn., Willian Heinmann Medical Books Ltd, London 1980;pp 741.
13. King, EJ, Armstrong, AR, Method of King and Armstrong In; Varley, H, Gowenlock, AH, Bell, M. *Practical Clinical Biochemisty*, 5<sup>th</sup> Edn., William Heinmann Medical Books Ltd, London 1980; 897.
14. Luna, LG. *Manual of histology, staining methods of Armed Forces Institute of Pathology.* 3<sup>rd</sup> Edn., New York, Mc Graw Hill, 1968.
15. Banskota, AH, Tezuka, Y, Adnyaa, IK. Hepatoprotective effect of commbretum quadrang, ulare and its constituents. *Biol Pharm Bul.* 2000; 23:456-460.
16. Takeoka, GR, Dao, LT. Antioxidant constituent of almond (*Ptunus dulicis* (mill) D.A. Webb.) huls. *J Agric Food Chem.* 2003; 51: 496-501.
17. Babu, BH, Shylesh, BS, Padikkala, J. Antioxidant and hepatoprotective effect of *Acanthus ilicifolius*. *Fitatherapia.* 2001; 72: 272-277.

\*\*\*\*\*