



Case Report

Carcinosarcoma of lung

Neupane S¹, Pathak T¹, Bastola S¹, Shrestha S¹, Pun CB¹

¹Department of Pathology, B. P Koirala Memorial Cancer Hospital, Bharatpur, Nepal

Keywords:

Carcinosarcoma;
Lung;
Malignant;
Spindle cells

ABSTRACT

Primary carcinosarcoma of the lung is exceedingly rare. It is described as malignancy composed of a mixture of carcinoma and sarcoma elements. The sarcomatous element is usually spindle cell but may contain cartilage, bone or skeletal muscle. We report a case of pulmonary carcinosarcoma in a 66 years male who presented with cough, chest pain on exertion, anorexia and weight loss. Brush cytology revealed poorly differentiated non-small cell carcinoma. Histopathological examination showed proliferation of malignant spindle cells containing bone and malignant cartilage admixed with areas of keratinized squamous cells with few foci of ill-defined glandular structure. On immunohistochemistry, carcinomatous component of tumor showed positivity for cytokeratin AE1/AE3 and spindle cell component were positive for vimentin. These findings led to diagnosis of carcinosarcoma.

INTRODUCTION

Primary carcinosarcoma of the lung is exceedingly rare.¹⁻⁴ In the recent World Health Organization (WHO) classification of lung tumors, it is described as malignancy composed of a mixture of carcinoma and sarcoma elements. The sarcomatous component is usually spindle cell but may contain cartilage, bone or skeletal muscle. However, controversy exists in the classification of this tumor and some authors may include sarcomatoid carcinoma in this category.⁵ The prognosis of pulmonary carcinosarcoma is unfavorable.⁶ It is reported that the mean age of patients with pulmonary carcinosarcoma is about 65 years; males who are heavy smokers more frequently develop this tumor than light smokers or nonsmokers. It arises from the central airway in 2/3 of patients, and it exhibits the morphology of polypoid airway lesions.⁷ We herein report a rare surgical

case of primary pulmonary carcinosarcoma involving right upper lobe.

CASE REPORT

Clinical Summary

A 66 year-old male came to the hospital with history of cough for 4 month, shortness of breath on exertion, anorexia and weight loss. Chest x-ray followed by CT scan showed an irregular mass lesion involving right upper lobe with satellite lesions with infiltrations into the upper lobe parenchyma with focal pleural effusion. The bronchoscopy examination showed a mass protruding from upper lobar bronchus with obstruction of B1, B2 and B3 by the mass. Brush cytology revealed poorly differentiated non-small cell carcinoma after which he underwent right upper lobectomy. Gross examination revealed a large ovoid shaped, irregularly bordered and grayish white mass partially filled with necrosis measured 9x8x5 cm (fig.1). The mass was 2 cm away from bronchial resection margin. Histopathological examination showed proliferation of short interlacing

Correspondence:

Dr. Sameer Neupane, MD

Department of Pathology, B. P Koirala Memorial Cancer Hospital,
Bharatpur, Nepal

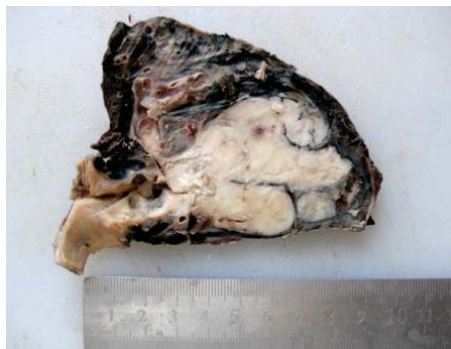

Figure 1: Gross picture of carcinosarcoma of right upper lobe showing ovoid mass of 9 cm maximum dimension having greywhite cut surface and partially filled with necrosis.

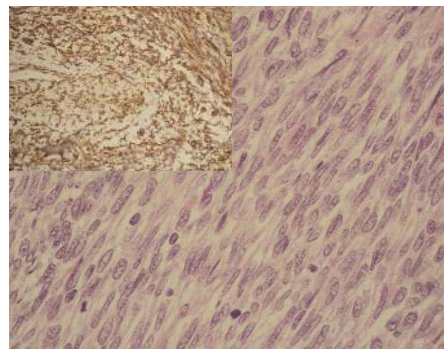


Figure 2: Histology of tumor demonstrated malignant spindle cell component and mitotic figures. (HE Stain, X200). Inset showing Sarcoma component of tumor showing spindle tumor cells positive for vimentin.

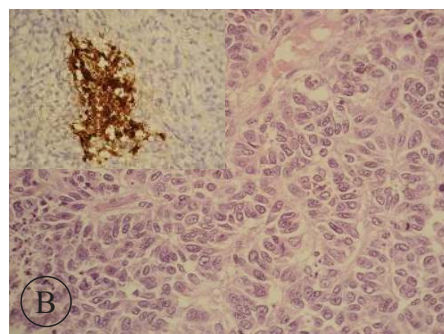
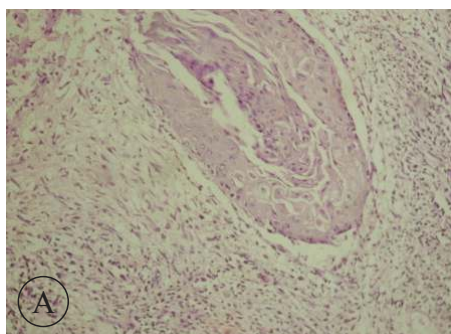


Figure 3: A) Histology of tumor demonstrated Keratinized squamous epithelium (HE Stain, X100); B) Histology of tumor demonstrated ill defined glandular structure. (HE Stain, X200). Inset showing Epithelial carcinoma component of tumor positive for cytokeratin AE1/AE3.

malignant spindle tumor cells (fig.2) intermingled with areas of well-differentiated squamous cell carcinoma and few foci of ill-defined glandular structures (fig.3A,3B). Areas of bone and malignant cartilage were observed in the spindle-cell components of the tumor. Panels of immunostains were performed for further classification and more precise diagnosis. The epithelial carcinomatous tumor cells showed strong immunoreactivity with pan cytokeratin AE1/AE3 (fig.3), while, vimentin stain was strongly positive in the malignant spindle cell component but not in the carcinomatous component (fig.2).

DISCUSSION

Pulmonary carcinosarcoma is a rare malignant tumor containing epithelial and mesenchymal components, and reportedly accounts for 0.1%–0.3% of all lung cancers.³ The male:female ratio is approximately 7 with a mean and median age of approximately 65 years.¹ In our case the age of patient is 65 years old. A strong association with smoking history has been found.¹ In the present case, patient was also heavy smoker as well as alcoholic in the past. Most lung carcinosarcomas exceed 5 cm in diameter, and some lesions as large as 15 cm or more have been reported.¹ In our case, the size of tumor was 9 cm

in largest dimension. Metastases are common and can be carcinomatous, sarcomatous, or both. Survival of patients with pulmonary carcinosarcoma is reported to be poor, with a 5-year survival rate of 21.3%.⁷ According to study by Rainosek DE et al.⁸ the most frequent epithelial component is reported to be squamous cell carcinoma, followed by adenocarcinoma and adenosquamous carcinoma. In a study of Mayall FG et al.⁹ sarcomatous elements most frequently included rhabdomyosarcoma, chondrosarcoma, osteosarcoma, or combinations of these elements. In our case, the carcinomatous element was also keratinized squamous epithelium and sarcomatous elements composed of malignant spindle cells with heterologous elements of mature bone and malignant cartilage as seen in their studies.

The study of Olobatoke et al.⁵ concluded that when heterologous sarcoma elements such as cartilage or skeletal muscle are present, it is easier to confirm the biphasic nature of the tumor, although immunostains can be of further help. We, in our case, also applied immunostains for confirmation and more precise diagnosis.

The proposed pathogenesis of carcinosarcoma includes (a) malignant transformation of hamartoma, (b) simultaneous malignant transformation of epithelial elements and stromal

component, (c) malignant transformation of cancer-derived stroma, (d) sarcomatous change of carcinoma, and (e) carcinomatous change of sarcoma. The prevailing theories suggest that a single stem-cell lineage exhibits multipotency and differentiates across germ layers into both epithelial and mesenchymal lineages.¹⁰

REFERENCES

1. Koss MN, Hochholzer L, Frommelt RA. Carcinosarcomas of the lung: A clinicopathologic study of 66 patients. *Am J Surg Pathol* 1999;23:1514-26.
2. Kalweit G, Straub U, Feindi P, Volkmer I, Gams E. Pulmonary carcinosarcoma: diagnostic problems and determinants of the prognosis. *Eur J Cardiothorac Surg* 1996;10:403-7.
3. Davis MP, Eagan RT, Weiland LH, Pairolero PC. Carcinosarcoma of the lung: Mayo Clinic experience and response to chemotherapy. *Mayo Clinic Proc* 1984;59:598-603.
4. Ishida T, Tateishi M, Kaneko S et al. Carcinosarcoma and spindle cell carcinoma of the lung: clinicopathologic and immunohistochemical studies. *J Thoracic Cardiovascular Surg* 1990;100:844-852.
5. Olobatoko AO, David D, Hafeez W, Van T, Sakh HA. Pulmonary carcinosarcoma initially presenting as invasive aspergillosis: a case report of previously unreported combination. *Diagn pathol* 2010;5:11.
6. DB Petrov, Vlassov VI, Kalaydiev GT et al. Primary pulmonary sarcomas and carcinosarcomas: postoperative results and comparative survival analysis. *Eur J Cardiothorac Surg* 2003;23:461-6.
7. Koss MN, Hochholzer L, Frommelt RA. Carcinosarcomas of the lung: A clinicopathologic study of 66 patients. *Am J Surg Pathol* 1999;23:1514-26.
8. Rainosek DE, Ro JY, Ordonez NG, Kulaga AD, Ayala AG. Sarcomatoid carcinoma of the lung: a case with atypical carcinoid and rhabdomyosarcomatous components. *Am J Clin Pathol* 1994;102:360-4.
9. Mayall FG, Gibbs AR. Pleural and pulmonary carcinosarcomas. *J Pathol* 1992;167:305-11.
10. Dacic S, Finkelstein SD, Sasatomi E, Swalsky PA, Yousem SA. Molecular pathogenesis of pulmonary carcinosarcoma as determined by microdissection based allelotyping. *Am J Surg Pathol* 2002;26:510-6.

CONCLUSION

Pulmonary carcinosarcoma is a rare neoplasm; diagnosis of which is based on morphological features aided by immunohistochemistry.