



Cardiorespiratory evaluation of brachycephalic syndrome in dogs¹

Raphaella A.M. Canola^{2*}, Marlos G. Sousa³, Jaislane B. Braz²,
Wilmer Alejandro Z. Restan², Diego I. Yamada², Jorge C. Silva Filho²
and Aparecido A. Camacho²

ABSTRACT.- Canola R.A.M., Sousa M.G., Braz J.B., Restan W.A.Z., Yamada D.I., Silva Filho J.C. & Camacho A.A. 2018. **Cardiorespiratory evaluation of brachycephalic syndrome in dogs.** *Pesquisa Veterinária Brasileira* 38(6):1130-1136. Departamento de Clínica e Cirurgia Veterinária, Faculdade de Ciências Agrárias e Veterinárias, Via de acesso Prof. Paulo Donato Castelane, Jaboticabal, SP 14884-900, Brazil, E-mail: raphaelamarques@hotmail.com

Brachycephalic syndrome (BS) in dogs is characterized by the combination of primary and secondary upper respiratory tract abnormalities and may result in significant upper airway obstruction. It can trigger inspiratory dyspnea, culminating in secondary respiratory distress, soft tissue edema, upper airway obstruction, turbulent airflow, inspiratory noise, and even death. These changes lead to increased resistance of the air passages, which can cause elevation of pulmonary pressure and clinical manifestations attributable to pulmonary hypertension. The consequence is right-sided cardiac remodeling (*Cor pulmonale*) with possible progression to right congestive heart failure. To investigate the effects of BS on the cardiovascular system, 28 animals were recruited for a prospective study and assigned to either the Brachycephalic Group (BG), composed of 22 French bulldogs with BS or the Control Group (CG), which was composed of 6 healthy Beagle dogs. All animals underwent a detailed physical examination, as well as laboratory analyses, electrocardiography, echocardiography, chest radiography and indirect measurement of systemic arterial blood pressure. The most relevant finding was a lower PaO₂ (90.6±12.9mmHg) in BG as compared to CG (104.9±5.2), (p≤0.05), possibly attributable to hypoventilation due to anatomical alterations.

INDEX TERMS: Cardiorespiratory evaluation, brachycephalic syndrome, dogs, *Cor pulmonale*, pulmonary hypertension, heart failure, French Bulldog, hypoxemia, clinics.

RESUMO.- [Avaliação cardiorespiratória da síndrome braquiocefálica em cães.] A síndrome braquiocefálica (BS) é caracterizada pela combinação de anormalidades primárias e secundárias do trato respiratório superior em cães, podendo resultar em obstrução significativa das vias aéreas superiores. Pode desencadear dispneia inspiratória, culminando em dificuldade respiratória secundária, edema de tecidos moles, obstrução das vias aéreas superiores, fluxo de ar turbulento, ruído inspiratório e até morte. Essas

alterações levam ao aumento da resistência da passagem do ar, o que pode causar elevação da pressão pulmonar e manifestações clínicas atribuídas à hipertensão pulmonar. A consequência é o remodelamento cardíaco do lado direito (*Cor pulmonale*) com possível progressão para insuficiência cardíaca congestiva direita. A fim de averiguar os efeitos da BS sobre o sistema cardiovascular, 28 animais foram recrutados para um estudo prospectivo e distribuídos em Grupo Braquiocefálico (GB), composto por 22 Bulldogs franceses com síndrome braquiocefálica ou Grupo Controle (GC), composto por 6 cães Beagles saudáveis. Todos os animais foram submetidos a exame físico detalhado, bem como análises laboratoriais, eletrocardiografia, ecocardiografia, radiografias torácicas e mensuração indireta de pressão arterial sistêmica. Os achados mais relevantes foram relacionados ao GB (90,6±12,9mmHg) com menor PaO₂ em relação ao GC (104,9±5,2), (p≤0,05), possivelmente atribuível à hypoventilação, em decorrência das alterações anatômicas.

¹ Received on May 22, 2017.

Accepted for publication on June 8, 2017.

² Departamento de Medicina Veterinária e Cirurgia, Faculdade de Ciências Agrárias e Veterinária, Universidade Estadual Paulista (Unesp), Via de acesso Prof. Paulo Donato Castelane, Jaboticabal, SP 148804-900, Brazil.

³ Departamento de Medicina Veterinária, Universidade Federal do Paraná (UFPR), Rua dos Funcionários 1540, Cabral, Curitiba, PR 80035-050, Brazil.

*Corresponding author: raphaelamarques@hotmail.com

TERMOS DE INDEXAÇÃO: Avaliação cardiorrespiratória, síndrome braquiocefálica, cães, *Cor pulmonale*, hipertensão pulmonar, insuficiência cardíaca, Bulldog Francês, hipoxemia, clínica.

INTRODUCTION

Brachycephalic syndrome (BS) is characterized by the combination of primary abnormalities such as stenotic nares (58-85%), soft palate thickening (87-96%), excessive nasopharyngeal turbinates and tracheal hypoplasia (46%). However, when negative pressure (required to maintain adequate ventilation in the face of increased resistance in air passages) significantly exceeds atmospheric pressure, tissue inflammation occurs, which may induce secondary changes in the upper respiratory tract of dogs. Such changes include eversion of laryngeal sacs and laryngeal collapse, with possible progression to significant upper airway obstruction (Brdecka et al. 2007, Krebs & Marks 2007, Lodato & Hedlund 2012, Meola 2013, Caccamo et al. 2014, Emmerson 2014).

BS is commonly diagnosed in young dogs (2 to 3 years of age) and is more common in breeds such as Shih Tzu, Pekingese, English Bulldog, French Bulldog, Lhasa Apso, Boxer, Pug and Boston terrier breeds (Trostel & Frankel 2010). The popularity of these breeds in Brazil has increased considerably over the past 10 years (Lodato & Hedlund 2012). With the exception of BS-related respiratory disorders, there are few studies on the effects of this syndrome on other organs and systems (Emmerson 2014) and the vast majority of studies of BS primarily address surgical correction of the condition (Brdecka 2007, Riecks et al. 2007, Huck et al. 2008, Trostel & Frankel 2010).

Morphofunctional changes due to anatomical abnormalities of the upper respiratory system increase resistance to air flow, which may trigger elevation of pulmonary pressure due to hypoxic vasoconstriction. In addition, there is an imbalance of vasodilating and vasoconstricting endothelial agents, which reduce production of vasopressin and antiproliferative agents, such nitric oxide and prostacyclin, and stimulate greater expression of vasoconstricting and proliferative substances such as thromboxane A₂ and endothelin-1, resulting in clinical manifestations attributed to pulmonary hypertension (Galiè et al. 2009, Lumb & Slinger 2015). The presumed consequence of this hypertension would be remodeling of the right side of the heart (*Cor pulmonale*), with possible progression to right congestive heart failure (Fleming & Ettinger 2006, Galiè et al. 2009). The aim of this research was to investigate the cardiorespiratory alterations in brachycephalic dogs with BS.

MATERIALS AND METHODS

Animals. Approval for the study was granted by the Ethics Committee for Animal Use (CEUA # 12079/15). Twenty-two brachycephalic dogs (Brachycephalic group) and six healthy non-brachycephalic dogs (Control group) were recruited for a prospective and cross-sectional study. The animals were screened based on anamnesis and physical examination, as well as radiographic examinations of the thoracic and cervical regions. Laboratory evaluation, including hemogram, serum biochemistry: alanine transaminase (ALT), alkaline phosphatase (ALP), urea, creatinine, total protein and albumin and arterial blood gas analysis, as well as a cardiovascular evaluation composed of blood pressure, electrocardiography and transthoracic echocardiography

was performed in all patients. Dogs were excluded if any primary cardiopathies or other systemic conditions were identified, as well as animals with body condition score equal to or greater than 8 (Laflamme 1997). Dogs being treated with any systemic medications were also excluded.

Hematology, serum biochemistry and blood gas analysis.

Venous blood samples (5ml) were collected by jugular venipuncture to perform a blood count (ABX Micros ESV 60 - Horiba) and serum biochemical analysis (LABQUEST-Labtest semiquantitative biochemical analyzer). Hemogasometer (OMNI C - Roche Diagnostic GmbH, Mannheim, Germany) was used to determine arterial blood gases, using 1.0mL of blood obtained from the femoral artery with a pre-heparinized needle aspirated syringe (Hemofol® Sodium Heparin 5000 IU/mL).

Systemic systolic blood pressure. Indirect systemic systolic blood pressure was measured using a Doppler device. The patient was positioned in right lateral or ventral recumbency and a cuff, with a diameter of approximately 40% of animal's limb circumference, was positioned and five measurements were performed (Brown et al. 2007, Mucha & Camacho 2007).

Radiographic evaluation. Radiographic evaluation of the cardiac silhouette was based on right laterolateral projections (rLL), using the cardiac vertebral scale system (VHS) (Buchanan & Bucheler 1995). From the same rLL image the presence/absence of tracheal hypoplasia was assessed (Ettinger 2010, Meola 2013), using the ratio of the tracheal diameter (TD) to the width of the thoracic inlet (TI). The TD was defined as the width of the tracheal lumen, perpendicular to its long axis, at the level of the first thoracic vertebra, while TI was defined as the distance between the ventral aspect of the first thoracic vertebra and the dorsal aspect of the narrowest point of the manubrium. In addition, rLL projection of the cervical region was performed to identify the presence of elongation of the soft palate (Krebs & Marks 2007).

Electrocardiography. Electrocardiographic evaluation was performed using a computerized device (ECG-PC, TEB, São Paulo/SP), which allowed simultaneous six lead recording (DI, DII, DIII, aVL, aVR and aVF), and minimum and maximum HR. The tracing was recorded at a speed of 50mm/s, with sensitivity adjusted to one centimeter equal to 1.0mV. Variables were recorded and interpreted as proposed by Tilley (1992) and Wolf et al. (2000).

Echocardiography. Echocardiography was performed using an Acuson X300 Premium Edition (Siemens Medical Solutions, USA) with a multifrequency (7.5 to 10 MHz) transducer. The echocardiographic parameters were quantified as described by Gupta et al. (2008), Rudski et al. (2010), Boon (2011a) and Visser (2014).

For evaluation of the left side of the heart, interventricular septum (IVS), left ventricle internal diameter (LVID) and left ventricle posterior wall (LVPW) parameters were obtained both in systole and diastole, and measured from M mode images through transverse sections of the LV at the level of the chordae tendinae. The left atrium to aortic ratio (LA/Ao), maximal mitral flow velocities in early (E_m) and late (A_m) diastole and the relationship between E_m and A_m , as well as LV myocardial performance index (Tei_{LV}) were recorded.

The right ventricular (RV) morphological evaluation included measurement of RV internal diameter in systole ($RVID_s$) and diastole ($RVID_d$) in two-dimensional images. These parameters were obtained at the base and at the intersection of the papillary muscle. In addition, the RV length was obtained in systole (RVL_s) and diastole (RVL_d). The systolic function of the RV was evaluated from the change in fractional area (FAC), tricuspid annular plane systolic excursion (TAPSE), tricuspid ring systolic excursion velocity

(S'), RV myocardial performance index (Tei_{RV}). Finally, the diastolic function of the RV was studied from systolic excursion velocities of the tricuspid ring in early (E'_t) and late (A'_t) diastole.

Statistical analysis. The normal distribution of the results was investigated by the Shapiro-Wilk test. For data with normal (parametric) distribution, differences between groups were evaluated using t test, whereas non-parametric data were compared through Mann-Whitney test. The pre-established significance level for all tests was 5% ($P \leq 0.05$) and the analyses were performed using SigmaPlot 12 software (Systat Software Inc. (SSI), San Jose, USA).

RESULTS

Twenty-two French Bulldogs were enrolled in the Brachycephalic group (BG), with 11 males and 11 females, from one year and two months to five years of age and weighing between 10.5 and 16.6 kg. Of the 22 brachycephalic dogs, 19 (86.4%) had variable degrees of stenotic nares. The control group (CG), comprised six healthy Beagles, with four females and two males, all animals were two years old and weighed between 9.1 and 12.7 kg. All brachycephalic animals were recruited from the clinical caseload of the veterinary hospital at the Universidade Estadual Paulista, campus of Jaboticabal/SP, or from a kennel located in Jaboticabal city, while healthy dogs were selected from the kennel of the Nutrition Clinic Laboratory from the same university.

There was no difference between groups ($P \geq 0.05$) for red blood cell, hemoglobin and packed cell volume (PCV) parameters (Table 1). Although all biochemical values were within reference ranges, there were statistical differences for creatinine, ALP and total protein, between groups (Table 2). There was a significant difference between groups for Partial Pressure of Oxygen in Arterial Blood (P_aO_2) ($P \leq 0.05$), (Table 3, Fig. 1).

There was no difference ($p \geq 0.05$) in systolic blood pressure (SBP) between groups. However, mean SBP (134.2 ± 15.1) was greater in animals in BG than in CG animals (129.3 ± 7.2).

On radiographic evaluation, only 2/22 (9.1%) brachycephalic dogs had elongated soft palates, while an increase in thickness was observed in 21/22 animals (95.4%) (Fig. 2). Similarly, VHS was significantly higher (11.8 ± 0.9) in brachycephalic dogs compared to CG (10.9 ± 0.2) (Table 4). However, there was no difference between groups with respect to TD/ TI ratio (Table 4).

On electrocardiographic examination, 16/22 from BG had sinus arrhythmia (72.7%), while 6/22 (27.3%) had sinus rhythm. In the control group, 5/6 animals had sinus arrhythmia (92.3%) and one (7.69%) sinus rhythm. The minimum and maximum mean HR and other electrocardiographic parameters, are shown in Table 5. There was a higher mean HR (112.4 ± 31.7), in the BG, although there was no statistical difference compared to the CG (88.3 ± 20.1). However, there was a significant difference between the mean HR of brachycephalic patients (142.8 ± 25.4) and control dogs (111.3 ± 19.9). In relation to waves and intervals, there were no differences between groups ($p > 0.05$) except for the PR interval ($P \leq 0.05$), and all parameters evaluated were within the reference ranges for the species.

The echocardiographic evaluation showed no differences between groups ($P \geq 0.05$) for $LVID_d$ (Table 6). However, $LVID_s$ of brachycephalic dogs were lower ($P \leq 0.05$) (32.0 ± 6.6) than the control dogs (38.5 ± 6.2). The left atrium to aortic ratio (LA/Ao) was higher ($P \leq 0.05$) in BG (1.40 ± 0.15) compared

Table 1. Mean values (standard deviations) or medians (interquartiles) of the erythrogram-related parameters obtained in healthy non-brachycephalic dogs (n=6) or brachycephalic dogs (n=22)

	Control group	Brachycephalic group
RBC ^a	7.3 (0.4)	6.8 (0.6)
Hb ^b	15.5 (14.6-16.2)	16.7 (15.2-18.0)
PCV ^a	44.0 (2.4)	47.4 (4.2)

RBC = Red Blood Cells ($\times 10^6/\text{mL}$), Hb = hemoglobin (g/dL), PCV = Packed Cell Volume (%); ^a Shapiro-Wilk test, ^b Mann-Whitney test.

Table 2. Median values (interquartiles) for biochemical parameters obtained in healthy non-brachycephalic dogs (n=6) or brachycephalic dogs (n=22)

	Control group	Brachycephalic group
Urea*	38.5 (32.7-43.7)	28.0 (26.0-43.0)
Creatinine*	0.8 (0.8-0.9) ^A	1.1 (1.0-1.2) ^B
ALT*	51.1 (29.7-66.0)	33.5 (26.0-53.2)
ALP*	74.0 (61.7-88.2) ^A	49.0 (41.0-66.0) ^B
Total protein*	6.4 (6.2-7.1) ^A	7.4 (7.1-8.3) ^B
Albumin*	3.2 (3.0-3.3)	3.1 (2.8-3.3)

Urea (mg/dL), Creatinine (mg/dL), ALT = alanine aminotransferase (UL), ALP = alkaline phosphatase (UL), Total protein (g/dL), Albumin (g/dL); ^{A,B} different letters differ statistically by the t test, $p \leq 0.05$; * Mann-Whitney test.

Table 3. Mean values (standard deviations) or medians (interquartiles) for blood gas parameters obtained in healthy non-brachycephalic dogs (n=6) or brachycephalic dogs (n=22)

	Control group	Brachycephalic group
pH*	7.41 (0.02)	7.40 (0.03)
P_aO_2 *	104.9 (5.2) ^A	90.6 (12.9) ^B
P_aCO_2 *	32.4 (1.7)	34.4 (2.3)
S_aO_2 *	97.5 (0.4)	95.3 (3.1)
HCO_3^- *	19.7 (0.8)	20.4 (1.8)
BE**	-3.1 (-3.9 a -2.5)	-2.4 (-3.4 to -1.5)

pH = Hydrogen ionic potential, P_aO_2 = partial pressure of oxygen in arterial blood (mmHg), P_aCO_2 = partial pressure of carbon dioxide gas in arterial blood (mmHg), S_aO_2 = saturation of oxygen in arterial blood (%), HCO_3^- = bicarbonate (mmol/L), BE = base excess (mmol/L); ^{A,B} different letters indicate statistical differences by the t test, $p \leq 0.05$; * Shapiro-Wilk test, ** Mann-Whitney test.

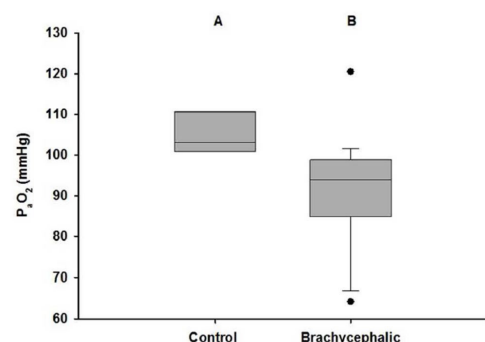


Fig. 1. Box plot containing the median, interquartile range and minimum and maximum partial pressure of oxygen in arterial blood (P_aO_2) values of six Beagles (CG) compared to 22 French Bulldogs (BG). Different letters indicate statistical difference by the t test, $p \leq 0.05$.

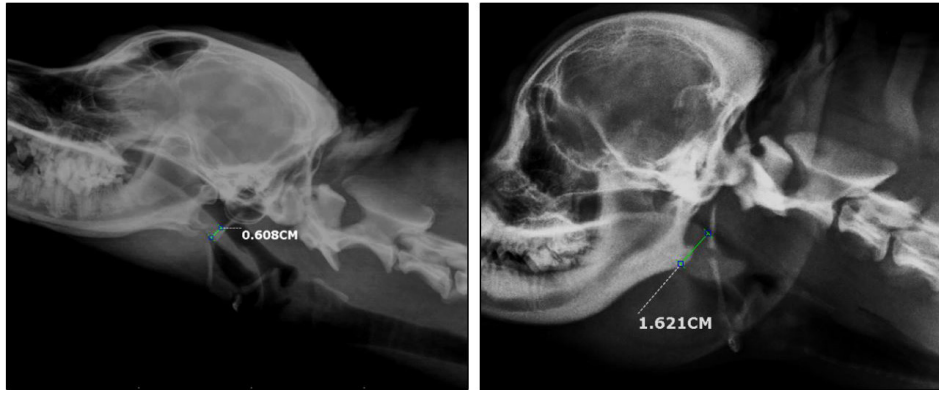


Fig.2. Radiographic image of cervical region in right laterolateral projection. On the left, a soft palate (marked green) is observed in a Beagle (CG), compared to the right image, in which the soft palate, in a French Bulldog (BG), is visibly thicker (bordered in green).

Table 4. Mean values (standard deviations) or medians (interquartiles) of radiographic parameters obtained from cardiac silhouette evaluation in healthy non-brachycephalic dogs (n=6) or brachycephalic dogs (n=22)

	Control group	Brachycephalic group
VHS ^b	10.9 (10.8-11.0) ^A	11.8 (11.2-12.2) ^B
TD/TI ^a	0.16 (0.02)	0.14 (0.02)

VHS = vertebral heart scale, TD/TI = relationship between tracheal diameter and thoracic inlet; ^{A,B} different letters indicate statistical differences by the t-test, p≤0.05; ^a Shapiro-Wilk test, ^b Mann-Whitney test.

Table 5. Mean values (standard deviations) or medians (interquartiles) of electrocardiographic parameters obtained in healthy non-brachycephalic dogs (n=6) or brachycephalic dogs (n=22)

	Control group	Brachycephalic group
HR _{min} ^b	91.0 (67.0-107.0)	98.0 (91.0-139.0)
HR _{max} ^a	111.3 (19.9) ^A	142.8 (25.4) ^B
P duration ^a	45.7 (4.6)	44.7 (5.7)
P amplitude ^a	0.18 (0.07)	0.18 (0.06)
PR interval ^a	110.0 (13.6) ^A	89.4 (11.5) ^B
QT interval ^b	211.0 (208.2-218.5)	203.0 (190.0-220.0)
QRS ^b	60.0 (4.8)	59.0 (7.7)
R ^a	1.0 (0.3)	1.1 (0.3)

HRmin = minimum heart rate (bpm), HRmax = maximum heart rate (bpm), duration of wave P = (ms), wave amplitude P = (mV), PR interval (ms), QT interval (ms), QRS = QRS complex duration (ms), R = wave amplitude R (mV); ^{A,B} different letters indicate statistical differences by the t-test, p≤0.05; ^a Shapiro-Wilk test, ^b Mann-Whitney test.

Table 6. Mean values (standard deviations) of some echocardiographic parameters related to morphological evaluation of left atrium and left ventricle in non-brachycephalic healthy dogs (n = 6) or brachycephalic dogs (n = 22)

	Control group	Brachycephalic group
LVID _d (index.) [*]	55.1 (6.5)	54.9 (6.6)
LVID _s (index.) [*]	38.5 (6.2) ^A	32.0 (6.6) ^B
LA/Ao [*]	1.26 (0.14) ^A	1.40 (0.15) ^B

LVID_d (index.) = Internal diameter of the left ventricle in diastole (indexed by the body surface area), LVID_s (index.) = internal diameter of the left ventricle in systole (indexed by body surface area), LA/Ao = relationship between left atrial and aortic diameters (cm); ^{A,B} different letters indicate statistical differences by the t-test, p≤0.05; ^{*} Shapiro-Wilk Test.

Table 7. Mean values (standard deviations) or medians (interquartiles) of some echocardiographic parameters related to functional evaluation of LV in healthy non-brachycephalic dogs (n=6) or brachycephalic dogs (n=22)

	Control group	Brachycephalic group
FS _{LV} ^b	34.4 (28.7-37.0) ^A	40.0 (36.7-45.0) ^B
V _{max} Ao ^a	1.15 (0.10)	1.30 (0.25)
Tei _{LV} ^b	0.51 (0.50-0.58)	0.59 (0.48-0.70)
E/A ^b	1.7 (1.4-1.8) ^A	1.3 (1.2-1.4) ^B
TRIV _{LV} ^b	51.5 (43.5-58.5)	54.0 (48.0-64.0)
E/TRIV _{LV} ^a	0.02 (0.0)	0.02 (0.0)
E' ^a	0.12 (0.01)	0.11 (0.02)
A' ^a	0.07 (0.02)	0.08 (0.02)
E'/A' ^a	1.8 (0.4) ^A	1.4 (0.2) ^B
E/E'	6.3 (0.7-7.3) ^A	7.6 (6.4-8.4) ^B

FS = fraction shortening (%), Vmax Ao = maximum flow velocity of the aorta (m/s), Tei_{LV} = left ventricular myocardial performance index, E' = mitral annular velocity quantified at the lateral annulus in initial diastole (ms), A' = mitral annular velocity quantified at the lateral annulus in late diastole (m/s), E'/A' = relation between E' and A', E/E' = relation of the maximum velocities of mitral flow in early diastole and E', TRIV_{LV} = isovolumetric relaxation time of the left ventricle (m/s), TRIV/E = relationship between left ventricular isovolumetric relaxation time and maximal mitral flow velocity in early diastole; ^{A,B} different letters indicate statistical differences by the t-test, p≤0.05; ^a Shapiro-Wilk test, ^b Mann-Whitney test.

to CG (1.26±0.14), although the values were within the reference ranges (Table 6). Fractional shortening (FS_{LV}) was significantly higher (41.7±8.3) in brachycephalic animals compared to the control animals (33.2±4.7). In contrast, the groups did not differ in terms of maximum pulmonary and aortic flow velocity and LV myocardial performance index (Tei_{LV}) (Table 7).

For LV diastolic function only the ratio between the E' and A' waves obtained by tissue Doppler positioned near the lateral mitral annulus differed between groups (P≤0.05). The averages obtained for this parameter were also within the reference ranges (Table 7). No significant differences between groups (P≥0.05) were identified in morphological and functional evaluations of the RV, the RVID_d and RVID_s obtained at the base and in the middle of the chamber, nor

Table 8. Mean values (standard deviations) or medians (interquartiles) of echocardiographic parameters for morphological and functional evaluation of right ventricle in healthy non-brachycephalic dogs (n=6) or brachycephalic dogs (n=22)

	Control group	Brachycephalic group
RVID _d base ^a	14.9 (2.4)	15.5 (3.5)
RVID _s base ^a	9.8 (1.7)	10.9 (3.3)
RVID _d middle ^a	15.5 (2.4)	16.0 (2.4)
RVID _s middle ^a	8.3 (1.7)	10.6 (3.4)
RVL _d ^a	31.4 (4.6)	29.9 (3.1)
RVL _s ^b	24.7 (21.4-27.3)	24.7 (21.4-25.9)
FS _{RV} ^a	45.8 (11.9)	34.3 (16.6)
Tei _{RV} ^a	0.58 (0.14)	0.50 (0.11)
FAC (index.) ^a	114.5 (27.4)	97.6 (27.7)
TAPSE (index.) ^b	20.0 (17.3-22.4)	23.0 (19.0-27.5)
S' tricuspid (index.) ^a	0.3 (0.1)	0.3 (0.1)

RVID_d base = right ventricle internal diameter in diastole measured at the base (mm), RVID_s base = right ventricle internal diameter in systole measured at the base (mm), RVID_d middle = right ventricle internal diameter in diastole measured at the middle third (mm), RVID_s middle = right ventricle internal diameter in systole measured at the middle third (mm), RVL_d = internal length of the right ventricle in diastole (mm), RVL_s = internal length of the right ventricle in systole (mm), FS_{RV} = right ventricular fractional shortening (%), Tei_{RV} = right ventricular myocardial performance index, FAC (index.)n = Fractional area change (indexed by the body surface area), TAPSE (index.) = Systolic excursion of the annular plane of tricuspid (indexed by the body surface area), S' tricuspid (index.) = Velocity of systolic excursion of the tricuspid ring (indexed by the body surface area). Different letters indicate statistical differences by the t-test, p<0.05; ^a Shapiro-Wilktest, ^b Mann-Whitney test.

in the measurements relating to the RVL_d and RVL_s. Likewise, there was no difference between groups (P≥0.05) when FS_{RV}, RV myocardial performance index (Tei_{RV}), fractional area change (FAC), TAPSE and tricuspid ring systolic excursion velocity (S') were compared (Table 8).

DISCUSSION

In this study, stenotic nares were the most commonly observed primary alteration (86.4%) in French Bulldogs, while elongation of soft palate was documented in only 9.1% of the brachycephalic dogs. This finding contrast with data from the literature, which suggest that soft palate elongation is the most frequent primary abnormality in BS (Fasanella et al. 2010, Dias et al. 2016). The methodology used for the diagnosis of soft palate elongation adopted in this study did differ from cited studies, a fact that may have directly influenced the incidence of this alteration. While in the present study the evaluation was performed by radiographic examination of the cervical region (Krebs & Marks 2007), most of previously published studies employed direct inspection of the oropharynx, with an animal in a superficial plane of anesthesia, to diagnose palatal elongation (Fasanella et al. 2010, Hoareau et al. 2012, Dias et al. 2016).

Despite the small number of animals with elongated soft palate, 95.4% of dogs from the BG had thickened soft palates on radiographic examination. One possible explanation may be the numbers of cases with stenotic nares. According

to Poiseuille's Law, a 50% decrease in the diameter of a tube increases its resistance to flow 16 fold (Meola 2013). Therefore, with stenosis of the nostrils, there is an increase in the intraluminal pressure, with consequent increase in resistance to passage of air and exacerbation of the inspiratory effort. When negative pressure exceeds atmospheric pressure, adjacent tissues become inflamed and enlarged (Lodato & Hedlund 2012, Emmerson 2014).

Despite the lack of statistical differences between groups, brachycephalic dogs had a higher PCV when compared with control dogs. The values obtained were similar to those found by Hoareau et al. (2012), although those authors documented a statistical difference between brachycephalic and non-brachycephalic dogs. The higher PCV in brachycephalic dogs may represent a natural compensatory mechanism to maintain normal O₂ levels despite lower P_aO₂, since hypoxemia stimulates red cell production. Such responses are managed by hypoxia inducible factors (HIF) through changes in the gene expression of specific cells that result in increased production of erythropoietin by the kidneys and liver (Haase 2013).

The difference of P_aO₂ between the groups corroborates the results obtained by Hoareau et al. (2012), but contrasts with the data from Dias et al. (2016). The lower P_aO₂ in French bulldogs may be related to respiratory distress caused mainly by stenotic nares. Nevertheless, the French Bulldogs evaluated were young adults. With animal maturity, and chronicity and progression of the clinical condition, respiratory distress presumably becomes more severe, to the point of causing hypoxemia (even lower P_aO₂ values) thus triggering consequences such as increased pulmonary artery pressure and RV cardiac remodeling. On the other hand, P_aCO₂ did not differ between groups, contrasting with results cited by Hoareau et al. (2012).

There was no difference in the SAP values between the groups evaluated, contrary to the findings of Hoareau et al. (2012). However, it should be noted that different methods were used to measure blood pressure in the studies in question. Another factor to consider is the effects of stress (Brown et al. 2007), since control dogs, unlike the brachycephalic patients, are conditioned to handling for procedures. The highest systolic pressures were identified in the dogs with the most severe changes relating to BS.

Non-brachycephalic dogs had a mean TD/TI ratio (0.16) below the standard reference ranges (0.20±0.03), as described by Ettinger (2010) and Meola (2013), although no difference between groups was documented. In the BG the TD/TI ratio was 0.14. Tracheal hypoplasia is diagnosed when the TD / TI ratio is less than 0.16; however, as reported by Kneller (2002) and Meola (2013), Bulldog has a ratio lower than 0.16±0.03. Thus, it cannot be said that the animals in this study had tracheal hypoplasia. It is worth mentioning that there are reports of Bulldogs in which the TD/TI ratio was 0.09 (Harvey & Fink 1982, Alexander 2013).

The cardiac silhouette, measured by VHS, was larger in brachycephalic dogs (11.8±0.9) compared to Beagles (10.9±0.2). However, there is considerable breed variation with respect to the sizes and shapes of normal hearts, and it is prudent to consider specific values for each breed whenever the heart is evaluated (Gugjoo et al. 2013). In that respect, Jepsen-Grant et al. (2012) found that Bulldogs had mean VHS of 12.7±1.7. An important factor that should be

considered when calculating this variable in bulldogs is the high incidence of hemivertebra, which directly influence the vertebral scale index. For this reason it is not possible to conclude that BG animals had a larger cardiac silhouette due to cardiac remodeling attributable to BS. In contrast, Dias et al. (2016) found no difference between brachycephalic and non-brachycephalic dogs in a study that included several breeds, establishing mean VHS of 9.6 ± 0.7 specifically for brachycephalic dogs.

A possible explanation for a higher prevalence of sinus arrhythmia in dogs from CG compared to BG is the action of autonomic nervous system. Dogs with primary alterations of the BS (obstructive respiratory disease) would be expected to have respiratory sinus arrhythmia due to vagal activation, since greater inspiratory resistance increases intrathoracic pressure fluctuations (Doxey & Boswood 2004). However, the increased prevalence of sinus rhythm in brachycephalic dogs may have been the result of stress and increased activation of the sympathetic nervous system. Again, it is important to emphasize that the animals from CG belonged to the university kennel and were accustomed to handling for procedures, unlike the brachycephalic dogs. Both minimum and maximum HR in BG were higher than in CG, a fact that suggests a stress effect. The evaluation of electrocardiographic waves also showed a greater PR interval in CG compared to BG dogs. This difference, although within the reference limits, may be related to variation in heart rate, increasing with bradycardia and decreasing with tachycardia (Feldman & Goldwasser 2004).

Both left ventricular diameter at systole and fractional shortening are useful in assessing systolic function (Boon 2011b). In this study, these parameters suggest an increase in the mechanical activity of the LV in brachycephalic dogs. One possible explanation for these findings is stress, with consequent activation of the sympathetic nervous system, since the most vigorous response of the French Bulldogs' LV during systole occurred in the absence of volume overload. The differences in left atrial size between groups, despite values within the reference range, are probably related to breed.

Finally, although remodeling of the RV in the face of chronic hypoxia was expected, we did not demonstrate any statistically significant difference between groups with regard to right ventricular morphology. It is possible that the brachycephalic dogs included in this study were too young to show significant echocardiographic remodeling. It is speculated that more sensitive RV assessment techniques, such as magnetic resonance imaging (Galea et al. 2013), may be required to document early morphofunctional changes in RV.

CONCLUSIONS

Young adult French Bulldog breed, despite the presence of BS, does not show severe cardiorespiratory changes that can be attributed to the syndrome.

It is possible that changes may not become evident until dogs are older when the condition is more chronic.

REFERENCES

Alexander K. 2013. The pharynx, larynx, and trachea, p.496. In: Thrall D.E. (Ed.), *Textbook of Veterinary Diagnostic Radiology*. 6th ed. Elsevier Saunders, St Louis.

- Boon J.A. 2011a. Acquired heart disease, p.101-151. In: Boon J.A. (Ed.), *Manual of Veterinary Echocardiography*. 2nd ed. Williams and Wilkins, Baltimore.
- Boon J.A. 2011b. Acquired heart disease p.153-265. In: Boon J.A. *Manual of Veterinary Echocardiography*. 2nd ed. Williams and Wilkins, Baltimore.
- Brdecka D., Rawlings C., Howerth E., Cornell K. & Stiffler K. 2007. A histopathological comparison of two techniques for soft palate resection in normal dogs. *J. Am. Anim. Hosp. Assoc.* 43(1):39-44. <http://dx.doi.org/10.5326/0430039>. PMID:17209084.
- Brown S., Atkins C., Bagley R., Carr A., Cowgill L., Davidson M., Egner B., Elliott J., Henik R., Labato M., Littman M., Polzin D., Ross L., Snyder P. & Stepien R. 2007. Guidelines for the identification, evaluation, and management of systemic hypertension in dogs and cats. *J. Vet. Intern. Med.* 21(3):542-558. <http://dx.doi.org/10.1111/j.1939-1676.2007.tb03005.x>. PMID:17552466.
- Buchanan J.W. & Bücheler J. 1995. Vertebral scale system to measure canine heart size in radiographs. *J. Am. Vet. Med. Assoc.* 206(2):194-199. PMID:7751220.
- Caccamo R., Buracco P., La Rosa G., Cantatore M. & Romussi S. 2014. Skull indices in canine brachycephalic airway obstructive syndrome. *BMC Vet. Res.* 10(1):12-18. <http://dx.doi.org/10.1186/1746-6148-10-12>. PMID:24410902.
- Dias M.L.M., Morris C.F.M., Moreti B.M., Santo A.V.E., McManus C.M., Almeida R.M. & Galera P.D. 2016. Anatomical, cardiovascular, and blood gas parameters in dogs with brachycephalic syndrome. *Acta Scient. Vet.* 44:1-6.
- Doxey S. & Boswood A. 2004. Differences between breeds of dog in a measure of heart rate variability. *Vet. Rec.* 154(23):713-717. <http://dx.doi.org/10.1136/vr.154.23.713>. PMID:15214514.
- Emmerson T. 2014. Brachycephalic obstructive airway syndrome: a growing problem. *J. Small Anim. Pract.* 55(11):543-544. <http://dx.doi.org/10.1111/jsap.12286>. PMID:25352108.
- Ettinger S.J. 2010. Diseases of the trachea and upper airways, p.25-26. In: Ettinger S.J. & Feldman E.C. (Ed.), *Textbook of Veterinary Internal Medicine*. Vol.2. 7th ed. Elsevier Saunders, Missouri.
- Fasanella F.J., Shivley J.M., Wardlaw J.L. & Givaruangawat S. 2010. Brachycephalic airway obstructive syndrome in dogs: 90 cases (1991-2008). *J. Am. Vet. Med. Assoc.* 237(9):1048-1051. <http://dx.doi.org/10.2460/javma.237.9.1048>. PMID:21034343.
- Feldman J. & Goldwasser G.P. 2004. Eletrocardiograma: recomendações para a sua interpretação. *Revta SOCERJ* 17:251-256.
- Fleming E. & Ettinger S.J. 2006. Pulmonary hypertension. *Compendium* 28:720-733
- Galea N., Carbone I., Cannata D., Cannavale G., Conti B., Galea R., Frustaci A., Catalano C. & Francone M. 2013. Right ventricular cardiovascular magnetic resonance imaging: normal anatomy and spectrum of pathological findings. *Insights Imaging* 4(2):213-223. <http://dx.doi.org/10.1007/s13244-013-0222-3>. PMID:23389464.
- Galiè N., Hoepfer M.M., Humbert M., Torbicki A., Vachier J., Barbera J.A., Beghetti M., Corris P., Gaine S., Gibbs J.S., Gomez-Sanchez M.A., Jondeau G., Klepetko W., Opitz C., Peacock A., Rubin L., Zellweger M. & Simonneau G. 2009. Guidelines for the diagnosis and treatment of pulmonary hypertension: the task force for the diagnosis and treatment of pulmonary hypertension of the European Society of Cardiology (ESC) and the European Respiratory Society (ERS), endorsed by the International Society of Heart and Lung Transplantation (ISHLT). *Eur. Heart J.* 30(20):2493-2537. <http://dx.doi.org/10.1093/eurheartj/ehp297>. PMID:19713419.
- Gugjoo M.B., Hoque M., Saxena A.C., Zama M.M. & Amaral S. 2013. Vertebral scale system to measure heart size in dogs in thoracic radiographs. *Adv. Anim. Vet. Sci.* 1:1-4.
- Gupta S., Khan F., Shapiro M., Weeks S.G., Litwin S.E. & Michaels A.D. 2008. The associations between tricuspid annular plane systolic excursion (TAPSE), ventricular dyssynchrony, and ventricular interaction in heart

- failure patients. *Eur. J. Echocardiography* 9(6):766-771. <http://dx.doi.org/10.1093/ejehocard/jen147>. PMID:18490286.
- Haase V.H. 2013. Regulation of erythropoiesis by hypoxia-inducible factors. *Blood Reviews* 27(1):41-53. <http://dx.doi.org/10.1016/j.blre.2012.12.003>. PMID:23291219.
- Harvey C. & Fink E. 1982. Tracheal diameter: analysis of radiographic measurements in brachycephalic and nonbrachycephalic dogs. *J. Am. Anim. Hosp. Assoc.* 18:570.
- Hoareau G.L., Jourdan G., Mellema M. & Verwaerde P. 2012. Evaluation of arterial blood gases and arterial blood pressures in brachycephalic dogs. *J. Vet. Intern. Med.* 26(4):897-904. <http://dx.doi.org/10.1111/j.1939-1676.2012.00941.x>. PMID:22574946.
- Huck J.L., Stanley B.J. & Hauptman J.G. 2008. Technique and outcome of nares amputation (Trader's technique) in immature shih tzus. *J. Am. Anim. Hosp. Assoc.* 44(2):82-85. <http://dx.doi.org/10.5326/0440082>. PMID:18316444.
- Jepsen-Grant K., Pollard R.E. & Johnson L.R. 2012. Vertebral heart scores in eight dog breeds. *Vet. Radiol. Ultrasound* 35(10):1-6. PMID:22994206.
- Kneller S.K. 2002. The larynx, pharynx and trachea. In: Thrall D.E. (Ed.), *Textbook of Veterinary Diagnostic Radiology*. 4th ed. W.B. Saunders, Philadelphia.
- Krebs A.I. & Marks S.L. 2007. Brachycephalic airway syndrome. *Standards of Care* 9:9-15.
- Laflamme D. 1997. Development and validation of a body condition score system for dogs. *Canine Practice* 22:10-15.
- Lodato D.L. & Hedlund C.S. 2012. Brachycephalic airway syndrome: pathophysiology and diagnosis. *Compendium* 34(7):E1-E5. PMID:22847322.
- Lumb A.B. & Slinger P. 2015. Hypoxic pulmonary vasoconstriction. physiology and anesthetic implications. *Anesthesiology* 122(4):932-946. <http://dx.doi.org/10.1097/ALN.0000000000000569>. PMID:25587641.
- Meola S.D. 2013. Brachycephalic airway syndrome. *Topics Compan. Anim. Med.* 28(3):91-96. <http://dx.doi.org/10.1053/j.tcam.2013.06.004>. PMID:24182996.
- Mucha C.J. & Camacho A.A. 2007. Determinación de la presión arterial, p.179-183. In: Belerenian G.C., Mucha C.J., Camacho A.A. & Grau J.M. (Eds), *Afecciones Cardiovasculares em Pequenos Animales*. 2ª ed. Inter-Médica, Buenos Aires.
- Riecks T.W., Birchard S.J. & Stephens J.A. 2007. Surgical correction of brachycephalic syndrome in dogs: 62 cases (1991-2004). *J. Am. Vet. Med. Assoc.* 230(9):1324-1328. <http://dx.doi.org/10.2460/javma.230.9.1324>. PMID:17472557.
- Rudski L.G., Lai W.W., Afilalo J., Hua L., Handschumacher M.D., Chandrasekaran K., Solomon S.D., Louie E.K. & Schiller N.B. 2010. Guidelines for the echocardiographic assessment of the right heart in adults: a report from the American Society of Echocardiography endorsed by the European Association of Echocardiography, a registered branch of the European Society of Cardiology, and the Canadian Society of Echocardiography. *J. Am. Soc. Echocardiography* 23(7):685-713. <http://dx.doi.org/10.1016/j.echo.2010.05.010>. PMID:20620859.
- Tilley L.P. 1992. *Essentials of Canine and Feline Electrocardiography*. Lea and Febiger, Philadelphia. 4703p.
- Trostel C.T. & Frankel D.J. 2010. Punch resection alarplasty technique in dogs and cats with stenotic nares: 14 cases. *J. Am. Anim. Hosp. Assoc.* 46(1):5-11. <http://dx.doi.org/10.5326/0460005>. PMID:20045831.
- Visser L.C. 2014. Echocardiographic assessment of right ventricular systolic function in conscious healthy dogs. MSc. Dissertation, Ohio State University, Ohio State.
- Wolf R., Camacho A.A. & Souza R.C.A. 2000. Eletrocardiografia computadorizada em cães. *Arq. Bras. Med. Vet. Zootec.* 52(6):610-615. <http://dx.doi.org/10.1590/S0102-09352000000600010>.